



LUND UNIVERSITY

Histologic characterization of stem cells in mammary epithelium and stroma

Isfoss, Björn

2017

Document Version:

Publisher's PDF, also known as Version of record

[Link to publication](#)

Citation for published version (APA):

Isfoss, B. (2017). *Histologic characterization of stem cells in mammary epithelium and stroma*. [Doctoral Thesis (compilation)]. Lund University: Faculty of Medicine.

Total number of authors:

1

Creative Commons License:

Unspecified

General rights

Unless other specific re-use rights are stated the following general rights apply:

Copyright and moral rights for the publications made accessible in the public portal are retained by the authors and/or other copyright owners and it is a condition of accessing publications that users recognise and abide by the legal requirements associated with these rights.

- Users may download and print one copy of any publication from the public portal for the purpose of private study or research.
- You may not further distribute the material or use it for any profit-making activity or commercial gain
- You may freely distribute the URL identifying the publication in the public portal

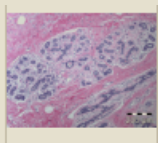
Read more about Creative commons licenses: <https://creativecommons.org/licenses/>

Take down policy

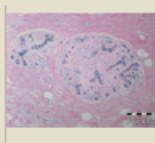
If you believe that this document breaches copyright please contact us providing details, and we will remove access to the work immediately and investigate your claim.

LUND UNIVERSITY

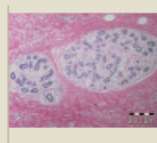
PO Box 117
221 00 Lund
+46 46-222 00 00



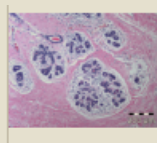
Age_20_011



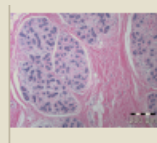
Age_20_024



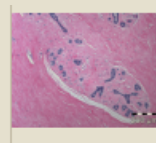
Age_20_031



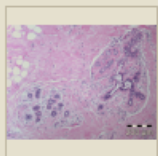
Age_20_034



Age_20_040



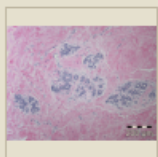
Age_21_007



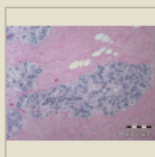
Age_23_005

Histologic characterization of stem cells in mammary epithelium and stroma

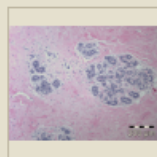
BJÖRN LOGI ISFOSS | FACULTY OF MEDICINE | LUND UNIVERSITY



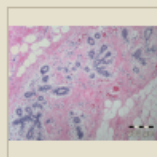
Age_29_104



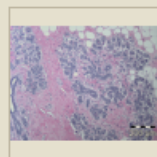
Age_31_073



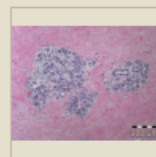
Age_31_084



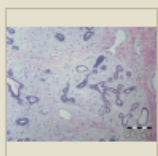
Age_31_091



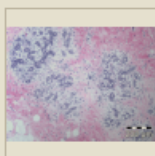
Age_32_046



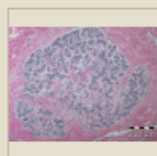
Age_32_085



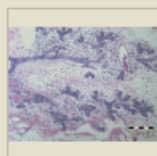
Age_34_099



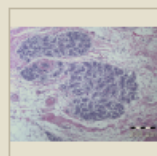
Age_34_110



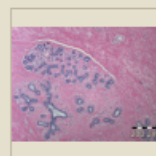
Age_35_058



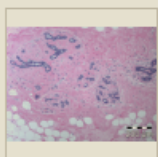
Age_35_118



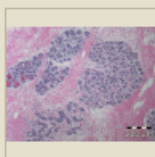
Age_35_126



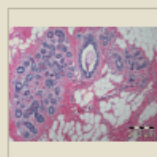
Age_36_030



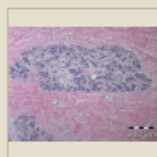
Age_37_062



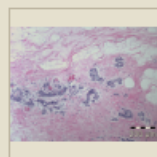
Age_37_086



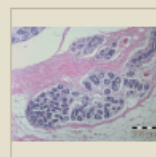
Age_38_065



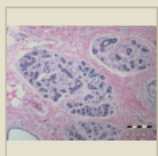
Age_38_066



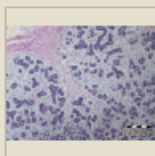
Age_38_122



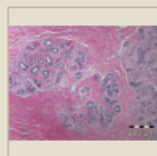
Age_39_097



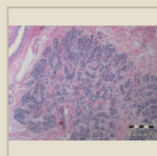
Age_41_021



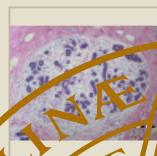
Age_41_049



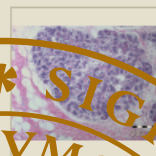
Age_42_015



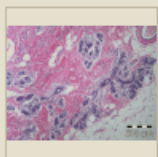
Age_42_112



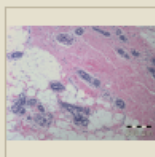
Age_43_093



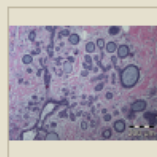
Age_43_059



Age_44_038

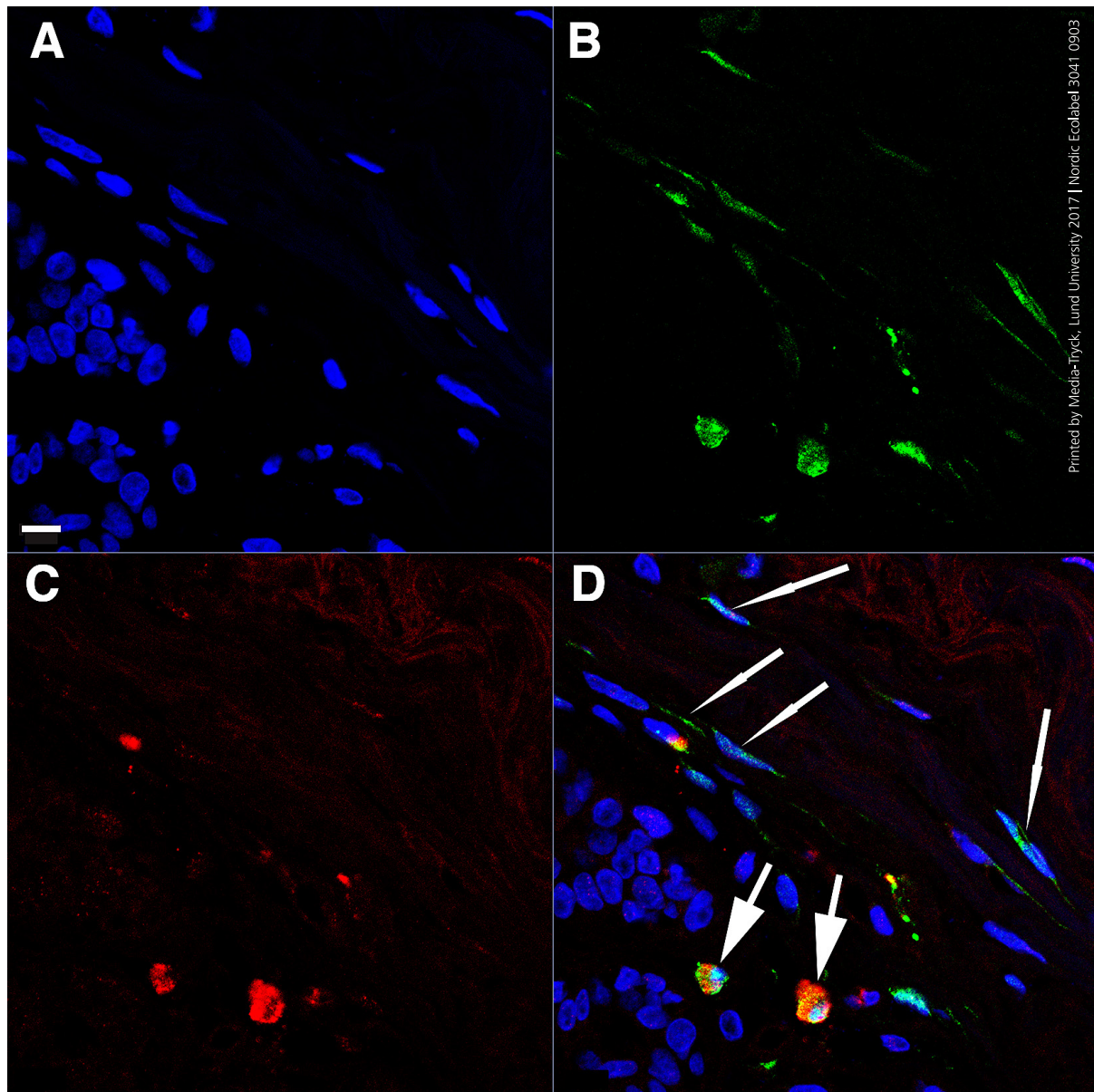


Age_44_068



Age_44_125





Histologic characterization of stem cells in mammary epithelium and stroma

Histologic characterization of stem cells in mammary epithelium and stroma

Björn Logi Isfoss



LUND
UNIVERSITY

DOCTORAL DISSERTATION


by due permission of the Faculty of Medicine, Lund University, Sweden.
To be defended at Segerfalksalen, Biomedicinskt centrum, 28 April 2017 at 09:00.

Faculty opponent

Professor Jorma Isola, MD PhD, Tampere, Finland

Organization LUND UNIVERSITY	Histological characterization of stem cells in mammary epithelium and stroma	
	28 April 2017	
Björn Logi Isfoss	Skåne University Hospitals	
Histologic characterization of stem cells in mammary epithelium and stroma		
<p>Abstract</p> <p>It is unknown whether native cells in benign breast tissue mediate risk of cancer. We therefore aimed to identify cell types in benign human mammary tissue immunohistologically using markers of stemness and differentiation, and to investigate their possible associations with clinical risk factors for breast cancer.</p> <p>We found that cells that are integrated in benign epithelium and are immunoreactive for the stem cell marker ALDH1 are negative for markers of glandular differentiation, proliferation, and estrogen receptor. High numbers of these cells were associated with the risk factors family history of breast cancer, <i>BRCA1/2</i> carrier status, low parity, and hormone use.</p> <p>Stromal ALDH1+ cells are either spindle-shaped/polygonal (s/p) or round/oval (r/o), and the latter are positive for the contractile protein marker SMMHC. ALDH1+ s/p cells are positive for the stellate cell marker vinculin. Low numbers of these cells were associated with family history, and when negative for the stem cell marker CD44 they were associated with nulliparity. Low numbers of ALDH1+ CD44+ CD24- r/o cells were associated with family history. ALDH1+ r/o cells were positively or negatively associated with low parity depending on the patients' <i>BRCA1/2</i> status.</p> <p>High numbers of r/o cells that are positive for the mesenchymal stem cell marker SSEA3 were associated with low parity, family history, and hormone use after menopause.</p> <p>This study describes novel stromal cells in breast that were associated with risk factors for breast cancer. If confirmed in independent cohorts, they may be used for stratification of women with regard to risk of breast cancer.</p>		
<p>Key words Breast. Neoplasia. Stem cells. Aldehyde dehydrogenase. Histology. Immunohistochemistry.</p>		
Classification system and/or index terms (if any)		
Supplementary bibliographical information		English
ISSN and key title 1652-8220		ISBN 978-91-7619-439-3
Recipient's notes	Number of pages 59	Price
	Security classification	

I, the undersigned, being the copyright owner of the abstract of the above-mentioned dissertation, hereby grant to all reference sources permission to publish and disseminate the abstract of the above-mentioned dissertation.

Signature  Date March 22, 2017

Histologic characterization of stem cells in mammary epithelium and stroma

Björn Logi Isfoss



LUND
UNIVERSITY

Coverphoto (front) by Björn Logi Isfoss
and (back) by Bo Holmqvist, ImaGene-iT AB

Copyright Björn Logi Isfoss

Faculty of Medicine
Department of Oncology and Pathology, Clinical Sciences Lund

ISBN 978-91-7619-439-3

ISSN 1652-8220

Printed in Sweden by Media-Tryck, Lund University
Lund 2017



To my family

Content

Summary	11
Abbreviations	13
Introduction	15
Prologue	15
Aim.....	16
Anatomy	16
Breast cancer	17
Risk factors for breast cancer	18
Hormonal risk factors	18
Genetic risk factors.....	19
Effects of risk factors on tumor characteristics	20
Histopathology, histology, immunohistology, and cell types	20
Stem cells and progenitor cells.....	22
Potential clinical benefits	23
Scientific study approach	23
Materials and methods.....	25
Patients and tissue	25
Immunological laboratory techniques	26
Control tissue.....	26
Primary antibodies relevant to clinical immunohistochemistry	27
Primary antibodies relevant to experimental pathology	27
Microscopy.....	27
Light microscopy.....	28
Fluorescence microscopy	28
Confocal microscopy.....	29
Quantitative assessment	29
Statistics	29
Results	31
Ductular cells	31

Cell characterization.....	32
Quantitative data and clinical correlation.....	33
Spindle-shaped or polygonal cells.....	33
Cell characterization.....	33
Quantitative data and clinical correlation.....	34
Round or oval cells.....	34
Cell characterization.....	34
Quantitative data and clinical correlation.....	35
Summary of associations and correlations between cell types and risk factors.....	35
Discussion	37
Aims	37
Investigative tools	37
Hypotheses	37
General conclusions	38
Potential clinical utilities.....	38
Relevance	38
Novel cell types described in this study	39
Methodological considerations	41
Conclusion and future perspective	43
References	45
Acknowledgement.....	57
Appendix	59

Summary

It is unknown whether native cells in benign breast tissue mediate risk of cancer. We therefore aimed to identify cell types in benign human mammary tissue immunohistologically using markers of stemness and differentiation, and to investigate their possible associations with clinical risk factors for breast cancer.

We found that cells that are integrated in benign epithelium and are immunoreactive for the stem cell marker ALDH1 are negative for markers of glandular differentiation, proliferation, and estrogen receptor. High numbers of these cells were associated with the risk factors family history of breast cancer, *BRCA1/2* carrier status, low parity, and hormone use.

Stromal ALDH1+ cells are either spindle-shaped/polygonal (s/p) or round/oval (r/o), and the latter are positive for the contractile protein marker SMMHC. ALDH1+ s/p cells are positive for the stellate cell marker vinculin. Low numbers of these cells were associated with family history, and when negative for the stem cell marker CD44 they were associated with nulliparity. Low numbers of ALDH1+ CD44+ CD24- r/o cells were associated with family history. ALDH1+ r/o cells were positively or negatively associated with low parity depending on the patients' *BRCA1/2* status.

High numbers of r/o cells that are positive for the mesenchymal stem cell marker SSEA3 were associated with low parity, family history, and hormone use after menopause.

This study describes novel stromal cells in breast that were associated with risk factors for breast cancer. If confirmed in independent cohorts, they may be used for stratification of women with regard to risk of breast cancer.

Abbreviations

ALDH1	Aldehyde dehydrogenase (synonym: retinaldehyde dehydrogenase) 1 A1
dIF	Double immunofluorescence
FFPE	Formalin-fixed and paraffin-embedded
H&E	Hematoxylin and eosin
HRT	Hormonal replacement therapy
IHC	Immunohistochemistry
R/o cell	Round or oval cell
S/p cell	Spindle-shaped or polygonal cell
SMMHC	Smooth muscle myosin heavy chain
SSEA3	Stage-specific embryonic antigen-3
TDLU	Terminal duct-lobular unit

Introduction

Prologue

This project began in 2004 motivated by a simple desire to understand normal tissue in breast cancer specimens, because its histologic appearance varies so greatly between patients (as seen on the front cover of this thesis). The pilot work started with single chromogenic immunohistochemistry (IHC) using a score of antibodies that were in common use for diagnosis of breast disease, with the help of benign surplus operation material retrospectively available from 14 women with breast cancer (7 premenopausal and 7 postmenopausal). When analyzing the IHC results for each antibody and interpreting this according to currently known cell types, the numbers didn't add up. There appeared to be relatively rare cells, located in the adluminal and intermediate levels of ductular epithelium, that were non-reactive to the antibodies that together with cell morphology and location defined the two known cell types in breast ductules at that time: epithelial cells and myoepithelial cells (reactive to the Cam5.2 cytokeratin antibody and reactive to smooth muscle myosin heavy chain [SMMHC], respectively). Double immunofluorescence (dIF) experiments confirmed this.

We therefore concluded in 2006 that our data provided indirect evidence of a novel cell type in normal breast ductules, and that this population might include stem cells or progenitor cells. In 2006 there was no single IHC marker known for stem cell or progenitor cell identification, so further work was temporarily put on ice. Happily, in late 2007 a journal article appeared from a team led by Dr. Wicha in Ann Arbor, Michigan, presenting results using the bioassay Aldefluor™ [Ginestier 2007]. According to functional studies described in that article the assay is effective in identifying live cells, benign and malignant, that possess stem qualities. According to the aforementioned publication cells with stem qualities are also detectable by IHC using an antibody for aldehyde dehydrogenase 1 A1 (ALDH1). Our work could therefore be commenced in 2008, using the same ALDH1 antibody product as Wicha's group used.

The work described here resulted in the definition of three cell types that are novel for benign female breast tissue, and that according to this study are associated with risk factors for breast cancer.

Aim

The aim for this doctoral thesis was to determine identities of cells in the human female mammary gland including stroma, and the tissue distribution of these cells according to patient characteristics, in order to elucidate possible roles for these cells concerning hormonal and genetic risk factors for breast cancer.

Anatomy

The milk-producing work-units of the female breast gland are composed of so-called lobules, where the most proximal parts (distant from the nipple) are acinar in lactating women but tubular and blunt-ended in non-lactating women [Russo 2000]. Imagine a thin microscopic section through a tight, tree-like "crown" consisting only of branches. The cross-section would look like a cluster of grapes. This gives the false impression of balloon-shaped structures, but these are in fact tubular in shape except in lactating women (and all the time in mice) where the ends are acinar. To distinguish the smallest-caliber ducts in the lobule from the first collection structures, the former are termed ductules and the second are called terminal ducts. The lobule together with its primary collecting tubular structure is often called the terminal duct-lobular unit (TDLU), and this is where the majority of breast cancers originate [Wellings 1975]. Further out towards the nipple these gland units drain into a smaller number of wider collecting ducts (milk ducts).

Until very recently, histology books taught that the ducts and ductules of breast are composed of only two cell types: epithelial cells and myoepithelial cells. Most epithelial cells are adluminal, but some of them extend all the way down to the basement membrane [Stirling 1976, Villadsen 2007, Isfoss 2012]. Myoepithelial cells constitute the cell population that lines the periphery of ducts and ductules. But now there is evidence that ducts and ductules also contain stem cells and/or progenitor cells [Ginestier 2007, Villadsen 2007].

The TDLU areas do not only contain ductules and ducts, they also contain specialized connective tissue including vessels and cells, collectively termed TDLU stroma. But in between the TDLUs and this specialized stroma, there are variable areas of generic stroma, which is collagen-dense and/or fatty but not very cellular, thus histologically resembling deep parts of skin. TDLUs vary enormously in total size and complexity, generally increasing along the time axis from prepuberty to pregnancy, with involution (atrophy) after menopause [Russo 1994].

Breast cancer

Breast cancer is the most commonly diagnosed malignant disease in women worldwide, and it is the 5th most common cause of death from cancer in men and women combined [IARC]. About 20% of breast cancers in women are detected before the age of 50 [Cancer Research UK]. Of all U.S. women who are 50 years of age, 2.4% have breast cancer [SEER]. In the Nordic countries the peak incidence is at 65 years of age, and in these countries more than 275 000 women are alive with a breast cancer diagnosis [NORDCAN].

By far most breast cancers are carcinomas, i.e. malignant tumors with epithelial differentiation. Invasive types of carcinoma, i.e. those that are potentially life-threatening, are traditionally classified according to their cellular and histological appearance, mainly into "no special type" (previously termed ductal type) and lobular type, and into less common types according to special morphological features [Lakhani 2012]. There are two recognized pre-invasive epithelial malignancies in breast: ductal carcinoma *in situ*, and lobular neoplasia. Each of these types of non-invasive lesions has a high – but importantly not full – potential to evolve into clinically detectable invasive carcinomas [Yen 2003]. In addition to the malignant tumors mentioned above, rarely tumors of non-epithelial differentiation arise in the breast, such as connective tissue tumors (sarcomas) of various types. Also metastases to the breast, such as from malignant melanoma, occur. Remarkably, there is today no consensus on the possible existence of a malignancy arising from the basally located myoepithelial cells [Ellis I, personal communication, 2014].

The purpose of the histological classification of cancers is to communicate information to the patient and her physician about the nature of the disease, i.e. the prognosis, and thereby appropriate choices of treatment. However, there is room for improvement in the histological classification and tumor grading, in light of the many treatment options available today. Also, some treatment choices are today dependent on further routine molecular testing of the cancer cells in pathology laboratories. The minimum standard laboratory test requirement at the time of this writing is analysis of hormone sensitivity according to IHC for estrogen and progesterone receptors, and cell proliferation testing using the immunohistochemical marker Ki67, and tests for amplification of the *HER2* oncogene according to IHC and/or DNA analysis. This is routinely done in order to help select appropriate medical therapies before and/or after breast cancer operation.

A new way of classifying carcinoma of the breast has been developing during the last one or two decades [Sørli 2001], promising better prognostication and better therapy guidance than was available before. This system was designed using multi-gene expression profiling, and re-classifies breast carcinoma principally into

Luminal A, Luminal B, *HER2*-enriched, and Basal-like types. These intrinsic subclasses of breast carcinomas can be roughly determined by the four types of IHC tests mentioned above, although there are important exceptions that require molecular genetic tests. However, with regard to multi-gene expression profiles, there are disagreements between the various sets of proposed tests, and their cost is high, so none are yet widely recommended for routine use [Natrajan 2016].

Risk factors for breast cancer

This study investigated the relation between histologically characterized cell types in normal female breast tissue and hormonal and genetic risk factors for breast cancer, via correlations with clinical data obtained from patient records in connection with breast operations performed from the year 1983 to 2010.

In addition to hormonal and genetic risk factors, there is also some evidence for increased risk associated with lifestyle-related factors such as smoking [Olsson 2003, Catsburg 2015], and body mass index [Munsell 2014]. Not surprisingly, ionizing radiation after atomic bomb explosion causes a severalfold increased risk of breast cancer, peaking at a relative risk of 8.7 for adolescents (age 10-19 years) who received high radiation doses in Hiroshima and Nagasaki [McGregor 1977]. Recently, also tissue density as detected by mammography was described to be a strong predictor of breast cancer [Engmann 2017]. It is not the intention to downplay the importance of any of these risk factors, but this study focused on hormonal and genetic risk factors.

Hormonal risk factors

Nulliparity, oligoparity, and late 1st parity. Multinational data were reported in 1970 suggesting that nulliparity is a risk factor for breast cancer, and that the protective effect of parity resides with the 1st pregnancy, and that women with early pregnancy (age ≤ 18 years) have only about 1/3 of the cancer risk that is associated with late 1st pregnancy (age ≥ 35 years) [MacMahon 1970]. In Sweden, where the patients investigated in the here presented study reside, nulliparity has been associated with a relative risk of 1.35 [Adami 1980]. A more recent study on more than 50 000 teachers in California confirmed these associations, and also demonstrated a decreasing risk of breast cancer with increasing number of pregnancies [Ma 2010]. Recent investigations into the mechanisms behind risk reduction with parity have indicated that human chorionic gonadotropin (hCG) secreted by the placenta in the 1st trimester causes a protective effect, and that high hCG levels in pregnant women during the 1st trimester are associated with

lower incidence of postmenopausal cancers [Russo 2011]. Also, in that study experimental data from virgin rats showed that those who received hCG treatment were resistant to chemical induction of mammary tumors.

Hormonal replacement therapy. There is no doubt that exogenous hormone use after menopause; commonly called hormonal replacement therapy (HRT) increases the risk for breast cancer. According to a review of 51 studies involving over 100 000 women with breast cancer and over 50 000 women without breast cancer as controls, HRT is associated with breast cancer risk in a dose-dependent manner, and the effect is transient [Collaborative Group 1997]. This was confirmed in the Million Women Study (UK), with average follow-up of 2.6 years, where any prior or current use of HRT containing estrogen and/or progesterone was associated with a relative risk of 1.43. [Million Women 2003, Olsson 2003]. Also, for compounds with estrogen plus progestagen there was a dose-dependent effect, with relative risk rising from 1.45 for users < 1 year, up to 2.31 for users \geq 10 years. Estrogen-only HRT use was also associated with increased relative risk, but less so than with progestagen-containing treatment.

Contraceptive pill. It was reported from a Swedish-Norwegian cohort of more than 100 000 women that any type of oral contraceptives, used before or while the women were surveyed in 1991, was associated with a 1.6 relative risk of breast cancer (96% CI 1.2-2.1) [Kumle 2002]. In a study of 4816 women who were diagnosed with breast cancer between 2000 and 2013 in the United States, combined estrogen and progestin oral contraceptives increased the risk of breast cancer mortality (hazard ratio 1.61, 95% CI 1.14-2.28), while progestin-only oral contraceptives were associated with a lowered risk of breast cancer mortality [Samson 2017]. Also, combined pills increased overall mortality more than they increased breast cancer mortality, as reflected in a hazard ratio of 1.83. Importantly, rather frightening data have been presented from Southern Sweden regarding the effect of pill use for women younger than 20 years, or more than 5 years of use for women younger than 25 years: these had odds ratios of 5.8 and 5.3 for developing breast cancer, respectively [Olsson 1989]. Especially early cancers (in women < 36 years of age) have been shown to be associated with contraceptive pill use, in a dose-dependent manner [Jernström 2005]. Notwithstanding all these historic data, it remains to be investigated if also the most modern oral contraceptive pills are associated with risk.

Genetic risk factors

Family history. It is estimated that hereditary factors account for 5 - 10% of breast cancers. The epidemiological hallmarks of hereditary breast cancer are 1)

multiple family members affected, especially 1st degree relatives, 2) family members that were diagnosed at an early age, 3) family members with male breast cancer, and 4) family members with bilateral breast cancer [Fackenthal 2007]. It is estimated that for patients with family history of breast cancer a predisposing gene is identified in approximately 25% of cases. The major genes that are known to predispose to breast cancer via mutation include: *BRCA1*, *BRCA2*, *PTEN*, *TP53*, *CDH1*, and *STK11*. Additional genes exhibit less penetration, but are associated with about a twofold risk: *CHEK2*, *BRIP1*, *ATM*, and *PALB2* [Shiovitz 2015].

***BRCA1* and *BRCA2* mutations.** Of all risk factors for breast cancer, mutations in the tumor suppressor genes *BRCA1* and *BRCA2* are the strongest, as they are 40 - 80% predictive [Szabo 1997, Fackenthal 2007]. Reported frequencies of mutation carriers are dependent on molecular genetic methods used, and are higher with more advanced methods. For example in Western Sweden, families referred to genetic counseling revealed a 36% rate of *BRCA1* or *BRCA2* mutations, using complementing molecular genetic screening techniques [Bergman 2005]. *BRCA1/2* mutations are diverse; there are typically point mutations, or small insertion and/or deletions, with missense and truncating effects. Also larger genomic rearrangements occur, and these can be more difficult to detect.

Effects of risk factors on tumor characteristics

In addition to the above mentioned clinical factors carrying risk of breast cancer, they are also associated with different tumor characteristics that in turn are associated with different patient outcomes. Carcinomas that arise in proliferating breast glands or in breast glands that are not fully developed, such as in young women, nulliparous women, those that used contraceptive pills before adulthood, and *BRCA1* carriers, tend to be poorly differentiated, estrogen receptor negative, and *HER2* positive. It has been hypothesized that poorly differentiated carcinoma subtypes arise in these women because of their relatively high proportion of progenitor cells as opposed to terminally differentiated cells [Olsson 2000].

Histopathology, histology, immunohistology, and cell types

Histopathology (*histo* = tissue; *pathologia* = study of disease), often-called just pathology, is the medical discipline that describes abnormalities in cells and tissues. The biomedical meaning of the word "tissue" refers to a particular assembly of cells, and substances in between cells, arranged in some kind of order.

During microscopic examination a pathologist always analyzes the architectural inter-arrangement of cells in the tissue, even within malignant tumors that on first appearance seem to be chaotic. Pattern recognition is important, and this takes years to learn under the supervision of experienced specialists. The evaluation of tissue specimens from living patients represents the bulk of clinical pathologists' work.

A pathologic diagnosis is a standardized word or more often a string of words suited to express the nature of a disease, for example: "Breast tissue (resection from left side) with ductal carcinoma *in situ*, grade 3, with comedonecrosis." Following the diagnosis the pathologist adds other information that may become necessary to plan further treatment, such as the presence or absence of malignant cells in the outer edge of the surgical specimen. Because of scientific evidence that both pathologists and the treating physicians are aware of, the diagnosis and supplementary data provided in the pathology report is translatable into valuable prognostic information.

Most pathologic analysis is sufficiently done by the use of a standard light microscope, after laboratory treatment of the tissue with chemical and physical methods that make the cells visible to the eye in surprising detail. Apart from the microscope, the pathologist's major work instrument is professional knowledge. The basis of this knowledge is histology, the discipline that describes normal tissues and cells at the microscopic level. The histology textbooks that most medical doctors have read during their early years in university – and in fact most or all histology books available in the bookshelves of pathology departments at the time of this writing – describe cells as visualized microscopically with the help of routine histochemical stains in variations of blue and red colors.

But the world has now changed, and the protein expression of cells, in addition to their morphology, increasingly defines cell types. The method by which proteins are made visible in the microscope is termed immunohistochemistry (IHC), or immunohistology, or immunocytology. This technology has resulted in ever increasing numbers of known cell types, and different functional states of cells. Due to these advancements propelled by biomedical science, histology must be rewritten to include immunohistochemical details. The original work presented here claims to be a part of this revolution.

In experimental research, but less often in clinical work, double or triple immunolabeling is used to assess the detailed morphological relation of tissue structures and specifically targeted molecules, including the cellular co-existence of specifically targeted molecules. Our work applied immunofluorescence labeling for simultaneous visualization of two or three stem and/or differentiation markers, and included the use of confocal microscopy, which further extended the possibilities for cell-specific characterizations.

Stem cells and progenitor cells

Stem cells are primarily defined as cells that are pluripotent i.e. can give rise to more than one adult cell type [Pittenger 1999, Rust 2011]. Evidence indicates that each stem cell can give rise to two identical cells (symmetric cell division), or one stem cell and one progenitor cell committed to one or few lineages [Morrison 2006]. Stem cells can survive dormant for a long time, possibly throughout the lifespan of the organism [Kurzrock 2008]. Contributing to assure long-term integrity of stem cells, they are equipped with mechanisms to resist cell damage, including a very low proliferation rate [Kurzrock 2008], and detoxification systems such as the ATP-binding cassette transporters [de Jonge-Peeters 2007] and aldehyde dehydrogenases [Yoshida 1998]. Somatic (i.e. non-embryonic) stem cells serve to regenerate tissues of persons by providing new cell progenies when old ones have expired after a finite number of cell divisions [Hayflick 1961].

Cancer stem cells, also termed stem-like cancer cells or tumor initiating cells, are malignant cells that exhibit stem-like qualities such as multipotency (ability to give rise to both mesenchymal and epithelial cell types), dormancy, resistance to cell toxins, ability to produce identical cell offspring, and longevity [Clarke 2006]. These cells have the potential to re-initiate tumors, also at distant sites (metastases), even decades after conventional anti-tumor therapy is completed with apparent success. The present project did not involve investigation of tumor tissue, and thus did not address cancer stem cells.

The concept of stem cells originated within the field of botany centuries ago, and was first published in the medical literature in 1905 with hematopoiesis in mind [Pappenheim 1905]. Detailed functional description of somatic stem cells in humans was however first published in 1988, for hematopoietic tissue in bone marrow [Spangrude 1988].

Progenitor cells are stem cells that are not yet differentiated, but are committed to differentiate into one or only a few cell lineages i.e. progenies. Some studies that claim to involve stem cells are actually addressing progenitor cells. These two terms, stem cells and progenitor cells, cannot always be held strictly separated. One reason for this is that not all research methods are capable of differentiating between stem and progenitor cells. Importantly, there is also evidence that progenitor cells can revert to stem cell state [Gupta 2009, van Es JH 2012].

The research data shown in the present work do not involve experiments directly relevant to the field of regenerative medicine, but they may still provide that branch with important histological understanding of stem and progenitor cells. The field of regenerative medicine holds enormous potential for alleviating or curing disease through the use of stem and progenitor cells. The first successful example of this was bone marrow transplantation, which is a potentially life-saving treatment for cancer patients [Thomas 1975]. Also, recently it has been

shown that it is possible to modify the function of differentiated somatic cells so that they become capable of serving as stem or progenitor cells in the rebuilding of defective human tissue, and such cells are termed induced stem cells [Yu 2007].

Potential clinical benefits

If confirmed in independent cohorts, the original study data presented here may be exploited to develop a biopsy-based laboratory test for stratifying women who are at risk for breast cancer into better-defined risk groups.

Because our study identified cells that are independently associated with risk factors for breast cancer, the presence or absence of these cells in a biopsy sample from a healthy woman could help predict the risk of breast cancer later in her life. If such a test would be developed, it would be done using a needle biopsy involving either a tissue core or a cell sample (fine needle aspiration). Importantly, this type of testing could not be widely recommended until and unless the presence or absence of these cells has been investigated in a larger number of tissue samples from cancer-free women, preferably without any breast disease, with subsequent follow-up of several years duration to detect any possible new cancers. It is theoretically possible to perform such a study on prospectively collected tissue material from healthy volunteers. An example of such an initiative is the Komen Tissue Bank of Susan G. Komen for the Cure [Oh 2016].

Scientific study approach

The here described original studies utilized material from operation specimens from women with benign or malignant breast disease, for identifying cells in morphologically normal tissue, using immunohistological methods, and for investigating associations between cell types *versus* hormonal and genetic risk factors for breast cancer. The study was retrospective, based on surplus archival tissue material, and information available from patient records was supplemented with more detailed clinical data from previous studies performed on breast patients at the same institution. Permissions from the regional ethical committee were obtained for performing a study of this type beforehand, *via* the aforementioned previous studies.

It may be argued that immunohistological methods alone are not capable of defining whether or not a cell is a stem cell or progenitor cell. This is true. However, at some point in time it is necessary to exploit cellular protein markers gained from functional studies of stem cells, and to apply these markers in clinical

tissue material. This was done in the present study, and represents bridging between basic science and clinical science.

Note: It is not possible to point at an immunochemically labeled cell, or even a cell labeled with three stem-relevant antibodies, and claim: "This is a stem cell". The cell is denatured and its functions can therefore not be tested. However, there are protein markers that have been confirmed to label stem or progenitor cells and can be used in situ, and – together with histological and morphological characteristics – these markers can make it possible to visualize particular cell populations that include stem cells.

Materials and methods

Patients and tissue

We elected to study women and not men, since we had access to a statistically sufficient number of only women in-house. Part-study I (Paper I) can be described as a qualitative pilot study, and was made possible using material from 28 patients from the Skåne University Hospitals in Southern Sweden. Half of these patients were randomly selected from the population of cancer-operated women, and half were mammoplasty-operated. The latter group was selected randomly from a cohort that had previously been characterized with regard to hormonal and genetic risk factors [Olsson 1996].

Part-study II (Paper II) included the above patient set. To provide a larger number of cancer patients we selected additional cancer patients to a total of 30, all operated between 1999 and 2006. Also, to include a higher number of non-risk patients and to improve the possibility of comparing cancer and non-cancer patients, the number of mammoplasty patients was increased to 35. These had undergone plastic operations of their breasts, typically for mammary hypertrophy, at the same hospitals in 1993-1994. Then patients who had been diagnosed with *BRCA1* or *BRCA2* mutation (all with family history of breast cancer) were included in the study in order to make it possible to characterize cell types and cell distribution among persons with these genetic risk factors. The *BRCA1/2* carriers had either been operated for cancer or they had received preventive mastectomy at the Skåne University Hospitals between 1983 and 2010. The *BRCA1/2* patient groups totaled 61 women, bringing the total number of patients eligible for the study to 126.

Then all archived breast tissue material from all eligible patients was examined by means of microscopy using the original hematoxylin and eosin (H&E) stained slides, with the aim to select one tissue block from each patient based on maximum amount of histologically normal glandular tissue. A few patients had been treated with neoadjuvant chemotherapy, which often disturbs the histology, and therefore their surgical specimens were rejected. A number of specimens were no longer available in the archive, and still other specimens contained an inadequate number of TDLUs in any one block (in part-study II [Paper II] and onward we arbitrarily required at least 10 TDLUs for valid analysis of ductular

cell types). The final set of patients eligible for analysis in part-study II was thus $n=106$. The clinical data available for these patients allowed us to re-group them according to hormonal and genetic characteristics such as age, menopause, parity, family history (also in patients that had no *BRCA1/2* mutation), use of contraceptive pills, hormonal replacement therapy (HRT), and for some patient groups also menarche.

The amount of tissue examined for each patient varied by the total size of the tissue fragments enclosed in the block chosen for analysis, from approximately 50 to approx. 600 sq mm (median 255). The number of TDLUs found in the H&E slides representing the index blocks that were chosen for the total study varied from 10 to 360 (average 93).

For part-study III (Paper III) we elected to focus on premenopausal patients, because this was the patient group that according to part-studies I & II appeared to exhibit the majority of the significant associations found between cell types and risk factors. Also, we chose to include *BRCA1* but not *BRCA2* carriers for part-study III, because the first-mentioned patient group exhibited the most interesting associations. The reason why we thus limited the number of patient groups entered into part-study III was that this study was designed to be technically more demanding for each case, and we expected that qualitative rather than quantitative investigations would be the most important contribution of that work.

For part-study IV (Paper IV), we came back to the whole $n=126$ patient set, and looked at all the original H&E slides once again with the intention to select two blocks from each case. This was done to secure surplus material in the case that blocks had been cut down beyond salvage during the foregoing studies. After the same exclusion procedures as were done for part-studies II & III the number of patients eligible for final analysis was 101, although for some of the more technically demanding analyses the tissue material was adequate in only 90 patients. This last-mentioned attrition occurred largely among the oldest archival specimens, because of tissue friability and poor adhesion to microscopic slides.

Immunological laboratory techniques

Control tissue

To ensure cell type-specific immunohistochemical and immunofluorescence labelings (immunophenotype) we included a wide range of positive human tissue controls, as recommended by the manufacturers, in each run. To ensure specific labelings of the used antibodies, in each labeling experiment adjacent tissue sections were treated in the same way but without primary antibodies. These

control sections were also used to ensure that only specific immunoreactivity above "background" labeling was recorded as positive (no grading of immunoreactivity was used).

Primary antibodies relevant to clinical immunohistochemistry

During the planning stages of part-study I we applied a broad range of antibodies that were routinely used for diagnostic breast pathology, in order to pre-screen the identities of cells in different locations of the breast. The results for some of these antibodies (cytokeratin 5/6, E-cadherin, CD34) did not appear to provide essential information for cell-identification purposes, so these were not used in the study. Antibodies obtained from the routine pathology laboratory menu that were ultimately used were the following: Cam5.2 (polyclonal, principally against cytokeratin 8) for identifying glandularly differentiated epithelial cells, CD45 for leukocytes, estrogen receptor for hormonal cell differentiation, Ki67 for cell proliferation, smooth muscle myosin heavy chain (SMMHC) for myoepithelial cells, and Tryptase for mast cells. The actual antibody products chosen for the study were recommended for clinical use by the non-profit external quality assurance organization NordiQC. The author of this thesis successfully performed the single chromogenic and the double immunofluorescence reactions for the first 14 patients in part-study I, and highly qualified laboratory scientists performed the remaining histochemical and immunohistochemical laboratory work for the study.

Primary antibodies relevant to experimental pathology

Antibodies that were used in the study, but were typically not used for diagnostic pathology purposes at that time, were the following: Aldehyde dehydrogenase 1 A1 (various host species), CD44, CD24, stage-specific embryonic antigen 3 (SSEA3), and Vinculin. The antibody clones used were carefully chosen to match the products that seminal prior studies [Al-Hajj 2003, Ginestier 2007, Kuroda 2010, Van Rossen 2009] had applied for identifying the same cells.

Microscopy

All the laboratory data recorded in this project were generated by the use of various types of wide-field, transmission-light, and epifluorescence microscopes. The PhD student performed the majority of these evaluations, while other study participants with extensive experience within experimental histology performed

the remaining evaluations. Computerized image analysis was not used, for reasons discussed in Methodological considerations.

Light microscopy

One of the benefits of histochemical stains and chromogenic IHC is that the colored signals are permanent, and the slides can be examined for extended periods of time without any degradation of signals. The major drawback is that chromogenic IHC can be less sensitive for low antibody signals than immunofluorescence is. However, in recent years the improved molecular amplification systems used in chromogenic IHC have increased the signal-to-noise ratios to the extent that interpretation has become much more consistent. For this reason we used chromogenic IHC for cell quantification purposes, whereas evaluations of molecular relations were performed by means of double immunofluorescence labelings. The salient features of each type of IHC and immunofluorescence results were imaged by digital documentation.

Fluorescence microscopy

Immunofluorescence can prove more sensitive than chromogenic IHC for detection of low levels of antigens and is supreme for simultaneous labeling of more than one antigen. For immunofluorescence, in one and the same section, the different colored fluorescent signals are easily separated, visually and digitally, and the relation of labeling can be determined at cellular levels. Therefore, double or triple immunofluorescence was the main method used for the evaluation of immunophenotypically-based cell identities, including specific combined stem cell-indicating immunophenotypes (CD44+ CD24-; ALDH1+ CD44+ CD24-). Drawbacks of immunofluorescence reading include practical difficulties working in a semi-dark room, and gradual reduction of signals with exposure to light and time of storage. For these reasons, we digitally imaged important immunofluorescence findings from most cases.

Confocal microscopy

Because epifluorescence microscopy is performed on tissue sections with a certain thickness (paraffin-embedded sections are usually 3-5 micrometers thick), there is a risk that visualization detects signals from two cells that overlap, causing the erroneous interpretation that signals from one cell was observed. To lower this risk when evaluating cellular double labeling (in two colors), we performed quality controls by means of confocal laser scanning microscopy (CLSM). In fluorescence labeled sections CLSM can be used to selectively view and document a so-called optical section that only detects signals from one thin "focal plane" that can be down to 300-400 nm (Z-level). Via co-detection of organelles such as cell nuclei, the immunolabeling can be evaluated as being localized intra- and/or extracellular, and they can be detected as being present on or in the same cell, or not. CLSM analyses were performed in a limited number of samples for each type of double immunofluorescence experiment to confirm the presence or absence of double-labeled cells.

Quantitative assessment

Immunoreactivity was not graded. To ensure objective and clear criteria for the assessment most of the IHC labeling analyses were documented as positive or negative for the given cell type for each examined TDLU, without attempting to count the number of positive cells for each TDLU. However, for the most frequently observed cell types, also the numbers of IHC positive cells within each examined TDLU were counted.

Statistics

The variables used were first tabulated and summarized using Microsoft Excel®, and were then evaluated for statistical significance using IBM SPSS®. Assessments of possible associations between cell types and clinical characteristics were done with regression analysis methods, logistic for discrete variables and linear for continuous variables. This made it possible to evaluate whether associations between individual groups of variables were independent of the other variables that were being assessed. For some association analyses Fisher's exact test was used. For correlations, Pearson's correlation coefficient and Spearman's rank correlation coefficient tests were used. For all the above tests, two-tailed analysis was applied, and $p < 0.05$ was considered significant.

Results

The study was performed in four logical part-study steps, as represented in the four papers, chronologically as follows:

1. Detailed morphological and immunohistological characterization of ALDH1+ cells in benign epithelium and stroma, including their distribution in the tissue and reactivity to selected cell differentiation and cell function antibodies, in a limited patient material ($n=28$). Cell data and apparent associations with regard to risk factors for breast cancer generated hypotheses, which were then tested in the subsequent part-studies.
2. Analysis of associations between ALDH1+ ductular cells and risk factors for breast cancer, using immunohistological methods on a larger patient material ($n=106$).
3. *In situ* characterization of ALDH1+ stromal cells in histologically normal tissue according to their immunolabeling for this marker and the alternative stem/progenitor cell marker combination CD44 and CD24, and correlations between the various resulting combined immunophenotypes and risk factors for breast cancer. The material consisted of premenopausal women only, $n=40$.
4. Immunohistological characterization of benign ALDH1+ stromal cells with regard to stem/progenitor and cell differentiation markers, using tissue from pre- and postmenopausal patients ($n=101$).

The following description of the total study results will be made across these part-studies, according to cell locations, cell morphologies, and risk factors.

Ductular cells

Because cells in ductules are believed to give rise to the majority of breast carcinomas, these anatomic structures were studied in detail with regard to cell types and distribution.

Cell characterization

ALDH1+ cells were present in only rare ductules, and then typically in more than one ductule within the same TDLU. The immunoreactivity was strong and widely distributed in the cytoplasm. These cells were most often located in the adluminal layer of the ductular epithelium (6% of TDLUs), or in the area defined as intermediate between the rows of adluminal cells and basally located cells (6% of TDLUs), and were least common in the basal layer (2% of TDLUs). Focally in some ductules ALDH1+ cells occupied the entire thickness of the epithelium, including the basal layer. In occasional ductular bifurcations, cells composing the carina consisted of ALDH1+ cells, thus constituting the bridge between the two o-shapes in an 8-figure. These cells, which were clearly adluminal, were observed only in women less than 50 years of age. In general ALDH1+ epithelial cells did not appear to have a different morphology from ALDH1- cells.

The differentiated glandular cell-marker Cam5.2 labeled all adluminal cells, with the exception of Ki67+ cells and the vast majority of ALDH1+ cells. Exceptionally, in the two youngest women (28 & 31 years of age) examined in the patient sample selected for this analysis, we detected very rare groups of cells with co-labeling of Cam5.2 and ALDH1 in adluminal parts of ductules. One of these women was a *BRCA1* carrier while the other was not and had no family history of breast cancer. Neither of these women had had full-term pregnancies.

An antibody for smooth muscle myosin heavy chain (SMMHC) decorated cells encircling ductules. Also, in immunofluorescence, some ductules contained weakly or focally SMMHC-reactive cells at the adluminal or intermediate levels of the epithelium (thus not consistent with myoepithelial cells). These cells were negative for Cam5.2. Basally located SMMHC+ cells, presumed to be myoepithelial cells, were in no cases positive for the proliferation marker Ki67, nor were any of these cells positive for ALDH1.

Cells positive for Ki67 occurred in relatively few TDLUs, and never in the TDLUs where ALDH1+ cells were present. Epithelial cells that were Ki67+ were typically found clustered in individual ductules, and in groups of ductules within the same TDLU. Nuclear Ki67 positivity was most common in adluminal cells, and was very rare in basally located cells.

In immunofluorescence preparations almost all epithelially located cells were judged as estrogen receptor *alpha* positive, with exception of the occasional cells that were either Ki67+ or ALDH1+.

Ductular SSEA3 positive cells were not detected at all in IHC, although specimens from two of the patients examined with immunofluorescence contained vaguely SSEA3+ cells in ductules.

Quantitative data and clinical correlation

According to single chromogenic IHC, ALDH1+ ductular cells were detected in 87% of patients, including the youngest premenopausal woman and the oldest postmenopausal woman. In the noncarrier premenopausal subgroup, ALDH1+ cells increased significantly with age. In premenopausal patients the presence of these cells was significantly associated with family history of breast cancer, independent of *BRCA1/2* carrier status and parity.

ALDH1+ ductular cells were more frequent in *BRCA1* than in *BRCA2* carrier patients. For premenopausal patients, *BRCA1* carrier status exhibited borderline association ($p=0.06$) with high numbers of ALDH1+ cells in the basal layer of ductules, whereas *BRCA2* carrier status was significantly associated with ALDH1+ cells within non-basal ductular levels.

Low parity was significantly associated with high presence of ALDH1+ ductular cells, for premenopausal patients, when adjusted for age.

HRT, ongoing at the time of operation in postmenopausal patients, was significantly associated with high numbers of ALDH1+ ductular cells, independent of the other investigated risk factors.

Spindle-shaped or polygonal cells

Cell characterization

The most numerous ALDH1+ s/p cells in TDLU stroma (and in breast tissue in general) were very thin and elongated, in some tissue planes exhibiting triangular (polygonal) cell bodies. Their nuclei were not detectable in all tissue planes. The immunoreactivity was cytoplasmic, of moderate or high intensity, and relatively homogenous. These cells were seen in specimens from all patients, located typically in the majority of TDLUs. In some areas they were tightly arranged around ducts or ductules, entire TDLUs, or small vessels. ALDH1+ s/p cells were in all cases negative for CD24 but appeared as either positive or negative for CD44. No ALDH1+ s/p cells exhibited immunoreactivity for Cam5.2, SMMHC, ER, or Ki67.

In double immunofluorescence experiments using antibodies for ALDH1 and Vinculin, s/p cells with reactivity for both markers were found in specimens from all examined patients. Intermingled with these cells, there were ALDH1+ Vinculin- s/p cells and ALDH1- Vinculin+ s/p cells. In other stromal areas there were groups of cells positive for only one of these markers.

S/p cells exhibited no immunoreactivity for SSEA3.

Quantitative data and clinical correlation

According to the part-study on premenopausal patients (Paper III), which evaluated the putatively potent stemness immunophenotype ALDH1+ CD44+ CD24–, and other variants of positivity for these markers, s/p cells only with the immunophenotype ALDH1+ CD44– CD24– were associated with risk factors. These cells were present in significantly low numbers in nulliparous patients. Then, single chromogenic IHC showed that TDLUs containing ALDH1+ cells were about half as common in premenopausal patients with family history of breast cancer, compared with premenopausal patients with no family history. This relative lack of ALDH1+ s/p cells in TDLU stroma patients with family history was statistically significant for the group with all patients, and for the group consisting of premenopausal patients only. However, when use of hormones at the time of operation was included in the model, this effect was canceled.

S/p cells with SSEA3 or Tryptase reactivity were not detected.

Round or oval cells

Cell characterization

ALDH1+ cells of round or oval shapes, focally with a bit distorted contours and occasionally with degranulation, occurred individually in TDLU stroma, containing distinctly granular cytoplasm and small, round nuclei. In histological terms, this morphology corresponds to that of mast cells. Often these cells were present in relatively high numbers in the generic stroma just outside TDLU areas, thus appearing to show affinity to TDLUs, and in such areas they were usually also present within the TDLU stroma. ALDH1+ r/o cells were observed in specimens from 65% of patients, but were sparsely distributed (present in 5% of TDLUs, median). Such cells, when positive also for the alternative stem cell marker CD44, were present in 30-60% of patients depending on the different risk groups. Very few ALDH1+ r/o cells were CD24+.

In the great majority of patients we detected r/o cells with combined ALDH1 and SSEA3 immunoreactivity, and in fewer patients ALDH1+ SSEA3– cells were present. All patients had r/o cells with Tryptase reactivity, and ALDH1+ Tryptase+ cells were present in all patients. Regarding immunoreactivity for each of these three markers, irrespective of the other markers, significant correlations were found between the occurrence of all the immunophenotypes with the notable exception of ALDH1+ cells and Tryptase+ cells, which showed very low and non-significant correlation.

Quantitative data and clinical correlation

ALDH1+ r/o cells. Using correlation analysis, ALDH1+ CD44+ CD24- r/o cells were less commonly observed in patients with family history of breast cancer, and in a regression model this association was just below statistical significance. According to single chromogenic IHC, the numbers of TDLUs with ALDH1+ cells were significantly high with decreasing parity in *BRC1/2* carriers, but the reverse was true for noncarrier patients (borderline significance $p = 0.057$). Also, for premenopausal patients a high presence of ALDH1+ r/o cells was associated with family history (borderline significance $p = 0.058$), and this effect was canceled when hormonal use at the time of operation was included in the model.

SSEA3+ r/o cells. Multiple significant associations were found between the SSEA3+ r/o cell type and risk factors: 1) high numbers with family history for all patients; 2) high numbers with family history for premenopausal patients when hormone use was included in the model; 3) high numbers with low parity; 4) low numbers with nulliparity for premenopausal patients but only when ongoing hormone use was included in the model; 5) high numbers with hormone use for postmenopausal patients.

Tryptase+ r/o cells. No associations were found between this cell type, presumed mast cell, and the investigated risk factors for breast cancer.

Summary of associations and correlations between cell types and risk factors

The listing below briefly describes associations and correlations between cell types and risk factors, according to original data from part-studies I-IV, as described in the published articles and the submitted manuscript in Appendix. All analyses were done using two-tailed testing. Regression models, linear or logistic, were used to adjust for other included risk factors. Where noted, correlation analyses with Fisher's exact test and Spearman's rho were used. P values indicating borderline significance ($p = 0.05-0.06$) are also included for the purposes of this summary.

Ductular ALDH1+ cells:

1. High ALDH1+ with increasing age, for noncarrier premenopausal patients. $P = 0.01$.
2. High ALDH1+ with low parity, for premenopausal patients. $P \leq 0.03$.

3. High ALDH1+ with family history, for premenopausal patients. $P \leq 0.01$.
4. High ALDH1+ basally with *BRCA1* carrier status. $P = 0.06$.
5. High ALDH1+ non-basally with *BRCA2* carrier status. $P = 0.03$.
6. High ALDH1+ with ongoing HRT. $P \leq 0.03$.

Stromal ALDH1+ s/p cells:

7. Low ALDH1+ CD44– CD24– and nulliparity, for premenopausal patients. Fisher's exact $P = 0.021$; Spearman's rho $P = 0.009$.
8. Low ALDH1+ and family history, for all patients. $P = 0.001$.
9. Low ALDH1+ and family history, for premenopausal patients. $P = 0.001$.

Stromal ALDH1+ r/o cells:

10. High ALDH1+ and parity, for *BRCA1/2* carriers. $P = 0.022$.
11. Low ALDH1+ and parity, for non-*BRCA1/2*-carriers. $P = 0.057$.
12. Low ALDH1+ CD44+ CD24– and family history. Fisher's exact $P = 0.055$; Spearman's rho $P = 0.028$.
13. High ALDH1+ and family history, for premenopausal patients. $P = 0.058$.

Stromal SSEA3+ r/o cells:

14. High SSEA3+ and low parity. $P = 0.015$.
15. Low SSEA3+ and nulliparity, for premenopausal patients when adjusted for ongoing hormone use. $P = 0.042$.
16. High SSEA3+ and family history. $P = 0.021$.
17. High SSEA3+ and family history, for premenopausal patients when adjusted for ongoing hormone use. $P = 0.009$.
18. High SSEA3+ and ongoing hormone use, for postmenopausal patients. $P = 0.032$.

Discussion

Aims

The aims of this study were: 1) to identify cells in morphologically normal female breast tissue according to previously defined characteristics of cell stemness *versus* cell differentiation, using histological and immunohistological methods, and 2) to describe possible associations between the presence and distribution of the identified cells and risk factors for breast cancer. The study completed both aims.

Investigative tools

The investigative tools used for this study of patient tissue samples were twofold, and their results were linked together with statistical methods: 1) *in situ* visualization of cell-specific proteins, with cytological and histological reference, and 2) data from clinical records regarding hormonal and genetic risk factors for breast cancer.

Hypotheses

The hypotheses generated before and during the study were: 1) the population of ductular cells that does not exhibit immunophenotypical characteristics of epithelial or myoepithelial cell differentiation includes stem cells, 2) ALDH1+ spindle-shaped/polygonal (s/p) cells in TDLU stroma include Stellate cells, and 3) ALDH1+ round/oval (r/o) cells in TDLU stroma include mesenchymal stem cells. The study results did not contradict any of these hypotheses.

General conclusions

The general conclusions of the study are: 1) We describe novel cell types in normal female breast stroma defined by their morphology, their tissue localization and their immunophenotypes. 2) The population of ALDH1+ s/p cells in breast stroma includes Stellate cells (also known as vitamin A-storing cells), and we show that local deficiency of these cells is associated with genetic and hormonal risk factors for breast cancer. 3) ALDH1+ r/o cells have characteristics that are common with SSEA3+ mesenchymal stem cells, and the distributions of both cell types, especially of the latter, are associated with genetic and hormonal risk factors for breast cancer. 4) Associations between the numbers of ALDH1+ stromal r/o cells and SSEA3+ stromal cells, respectively, *versus* risk factors, are influenced by ongoing use of hormones.

Potential clinical utilities

Direct, potential clinical utilities of the knowledge generated by the study include: 1) a possibility of a biopsy test for the stratification of healthy or predisposed women for breast cancer risk, 2) awareness of normally occurring cell types that are important for the maintainance of adult tissue but may be adversely affected by anti-cancer stem cell treatments [Danishefsky 2015], and 3) elucidation of stem/progenitor cell types that may be relevant for tissue augmenting therapy.

In addition, the study contributes to the next generation of histology literature, which should include cell immunophenotypes that are linkable to specific cell functions. Lastly, the study provides data regarding cell types that are affected by exogenous hormones, which may help selecting lower-risk strategies for hormonal medications in the future.

Relevance

Breast cancer in women is not uncommon, and sometimes causes morbidity and mortality that results in personal and familial disasters. Health care authorities have taken measures to reduce the effects of this epidemic by providing mammography screening, but now such screening has been linked to overdiagnosis and limited effect on population basis [Kalager 2010, Jørgensen 2017]. This has resulted in the question whether breast cancer screening can be done in a better way than mammography has provided. According to the review of

risk factors for breast cancer that is provided in Introduction above, clinical traits such as use of exogenous hormones and family history can raise the risk by *cirka* 50 to 500%.

Regarding family history as a risk factor, molecular genetic research has identified genes that explain about 25% of the familial risk. This raises the question: where to look for mechanisms behind the remaining 75% of the familial burden? Gene alterations have been looked for, but this has not resulted in very large breakthroughs. We therefore investigated if cell types and the distribution of cell types in histologically normal breast gland and stroma could reveal links with hormonal and genetic risk factors for breast cancer.

Novel cell types described in this study

For ductular epithelium, the clinical material and methods used here confirmed previously published findings that indicated immunohistologically identifiable stem or progenitor cells [Ginestier 2007, Villadsen 2007]. Then we identified three novel cell types in breast stroma, which according to this study are linked with clinical risk factors for breast cancer: 1) ALDH1+ s/p cells, 2) ALDH1+ r/o cells, and 3) SSEA3+ r/o cells. According to the cellular morphologies, tissue distributions and immunophenotypes, ALDH1+ s/p cells are proposed to be Stellate cells, and SSEA3+ cells are proposed to be mesenchymal stem cells. Although the identity of ALDH1+ r/o cells is less clear, their morphology is the same as that of SSEA3+ r/o cells, and both cell types exhibit similar but not identical associations with family history. It is thus possible that these two cell types have the same origin, or even represent the same cell type in different states of function.

ALDH1+ stromal cells

Villadsen *et al.* (2007) described characteristics of sparsely distributed candidate stem and progenitor cells in ductules and ductules, using markers other than ALDH1 [Villadsen 2007]. Stroma was not investigated. Also Ginestier *et al.* (2007) described candidate stem cells in the epithelial compartment, characterized by ALDH1 positivity, without addressing stroma [Ginestier 2007]. Resetkova *et al.* (2010), in an investigation of breast tumors, mentioned ALDH1 expression in the cytoplasm of stromal cells in normal tissue without describing cell morphology or cell distribution [Resetkova 2010]. In a study of breast cancer tissue, Heerma van Voss (2011) reported epithelial and peritumoral ALDH1 expression, and mentioned that also non-tumoral stroma contained ALDH1 positivity, without

description of cells [Heerma van Voss 2011]. Also Kang *et al.* (2014) recorded ALDH1 positivity in breast tumor stroma without mentioning cells [Kang 2014].

In 2012 we reported that the most commonly observed ALDH1+ cell type in benign breast tissue is stromal, and spindle-shaped, and that the second most common ALDH1+ cell type, also in stroma, is round or oval [Isfoss 2012]. Furthermore, in our 2013 publication, which focused specifically on ductular tissue, we provided a micrograph depicting ALDH1+ spindle-shaped stromal cells, one of which exhibited thin strands of cytoplasm extending in different directions (effectively a star-like *i.e.* stellate cell shape) [Isfoss 2013]. Also Schwartz *et al.* (2013) reported ALDH1+ stromal expression in benign breast tissue, but without providing a description of cells [Schwartz 2013].

A study reported in 2015 by Bednarz-Knoll *et al.* focused specifically on ALDH1+ expression in breast stroma, although the subject of investigation was malignant tumor tissue. In intratumoral stroma, they described, "spindle- and/or polygonal-like shaped stromal cells located between and/or around tumor cells" [Bednarz-Knoll 2015]. They cited our 2012 work. In our 2016 publication we modified the morphological description of the population of ALDH1+ spindle-shaped cells as also containing cells with polygonal cell bodies [Isfoss 2016].

Thus, to our knowledge, both of the ALDH1+ cell types that we describe in benign breast stroma, the s/p and the r/o, appeared first in the here presented study.

SSEA3+ stromal cells

We have been unable to find any previous reports of mammary stromal cells with regard to stage-specific embryonic antigen 3 (SSEA3). A research group in Taiwan reported complete absence of SSEA3+ cells in human mammary stroma, based on flow-cytometry [Chang 2008, Cheung 2016]. Their data were derived from surface cell marker methods, and therefore do not contradict our results which were based on morphological assessment of cells *in situ* indicating primarily cytoplasmic immunoreactivity for the SSEA3 antibody. Furthermore, an IHC image provided in one of the early publications that defined SSEA3 as a stem cell marker clearly show widespread cytoplasmic immunoreactivity for this marker [Shevinsky 1982]. Also, the cellular immunoreactivity for SSEA3 in stroma that we describe is identical to reports from the group that established SSEA3 as an immunophenotype characteristic of mesenchymal stem cells of the Muse type [Kuroda 2010, Wakao 2011, Dezawa 2016]. Although pluripotent SSEA3+ stromal cells are according to Dezawa *et al.* (2016) present in "nearly every organ" (without specific information provided in this regard), SSEA3+ stromal cells are to our knowledge only reported for skin [Kuroda 2010], adipose tissue [Heneidi 2013], and colon [Suzuki 2013].

The work presented here therefore appears to be the first describing SSEA3+ cells in stroma of breast.

Methodological considerations

The experimental techniques used in this study were chosen to visualize cells *in situ* by means of IHC techniques, with their morphology and spatial relations with neighboring structures retained. Cell identification was based on assessment of cell location, cell morphology including shape and cytoplasmic character, together with visualization of immunolabeled proteins that characterize specific cell identities according to peer-reviewed reports from more than one researcher groups. Cell-specific immunolabeling was assured by using appropriate positive and negative control tissue, and by antibody specificity controls of labelings and of labeling quality, and by analyses of cellular co-localization through confocal microscopy. Thus, although IHC is in general limited by possible confounding effects of a number of laboratory variables, our methods sought to minimize such effects.

Non-cancer and non-*BRCA1/2*-carrier women who were in need of mastectomy represented the most “normal” patient subgroup in this study. Thereby, the whole study was limited in that it was performed using tissue specimens from patients that were not entirely free of breast conditions. Obviously, it would be desirable to assess the applicability of a biopsy-based test for the stratification of risk for breast cancer using samples from women without any symptoms or signs from their breasts. However, breast tissue specimens from live women without any breast disease or genetic predisposition are exceedingly rare, and are certainly not available as whole tissue sections.

The reason that we preferred full-size tissue sections rather than tissue microarrays was that some of the cell types that we investigated are sparsely distributed in tissue. The material investigated from each patient had a median area of 255 (range 48 - 621) sq mm – which is about 900 times larger than a single tissue microarray sample. It is still possible that a tissue microarray study could be performed effectively for assessing links between the identified rare cell types and cancer risk, if very many specimens are included.

The tissue used in this study originated from FFPE blocks that had been archived for up to 33 years, admittedly leading to quality problems with the oldest specimens in terms of friability and poor adhesion to microscopic slides. The latter resulted in rejection of up to 10% of specimens from some analyses due to less than 10 TDLUs being represented in IHC slides. Still, this is unlikely to have affected the results greatly, since 85% of the specimens that were more than 20 years old were from mastectomy patients, who served as normal control subjects.

Immunoreactivity was, as expected, detected with greater sensitivity by dIF experiments than by IHC. This was most evident with ALDH1+ r/o cells, which were documented in the TDLU stroma of all patients in the subset investigated

with dIF, but only in 65% of the total patient material using IHC. Also, regarding the different microscope methods, we noted higher sensitivity for double positive cells in confocal microscopy than with epifluorescence microscopy, due to better visual separation of signals. In general, this is not considered to reduce the validity of chromogenic IHC to detect differences in specific cell occurrences between clinical subgroups.

In many cases IHC positive cells were observed in or just outside the border between TDLU stroma and surrounding generic stroma. This provided a challenge when localizing cells exactly in relation to TDLU stroma *versus* generic stroma. However, we observed that when the cells of interest were present in high numbers just outside TDLU stroma, they were typically present also within the TDLU stroma, so this did not appear to present a considerable source of bias.

Finally, it may be argued that quantification of IHC positive cells is more objective if done with computerized image analysis (morphometry) than with subjective quantification. A recent study of cancer tissue comparing subjective and computer assessment of IHC, including grading of staining intensity, revealed analytic discrepancies for some stem cell markers [Miller 2017]. However, the present study investigated IHC in benign tissue, which is more regular and repetitive than heterogenous cancer tissue. Also, we abstained from grading immunoreactivity and instead recorded any cellular staining above background level as positive, which reduces the risk of IHC interpretation discrepancies.

Conclusion and future perspective

The work presented in this thesis aimed to characterize in histological and subcellular detail epithelial and stromal cells in benign female breast tissue using *in situ* immunolabeling for epitopes previously shown to indicate cell differentiation, cell functions, or stemness. The study also aimed to identify associations between the immunolabeled cells and hormonal and genetic risk factors for breast cancer. Both aims were met, and through hypothesis testing in the laboratory this resulted in the discovery of three benign stromal cell types that have never before been described in breast, all of which were demonstrated to be associated with hormonal and/or genetic risk factors for breast cancer.

If these findings are confirmed in an independent cohort, they can provide a foundation for a needle biopsy-based test to stratify women with regard to risk of breast cancer.

References

- Adami HO, Hansen J, Jung B, Rimsten AJ. Age at first birth, parity and risk of breast cancer in a Swedish population. *Br J Cancer*. 1980;42:651-658.
- Alvi AJ, Clayton H, Joshi C, Enver T, Ashworth A, d M Vivanco M, Dale TC, Smalley MJ: Functional and molecular characterisation of mammary side population cells. *Breast Cancer Res* 2003, 5:R1-R8.
- Al-Hajj M, Wicha MS, Benito-Hernandez A, Morrison SJ, Clarke MF. Prospective identification of tumorigenic breast cancer cells. *Proc Natl Acad Sci USA* 2003, 100:3983-3988.
- Albanes D, Winick M: Are cell number and cell proliferation risk factors for cancer? *J Natl Cancer Inst*. 1988;80:772-774.
- Anderson GL, Judd HL, Kaunitz AM, Barad DH, Beresford SA, Pettinger M, Liu J, McNeeley SG, Lopez AM, Women's Health Initiative Investigators: Effects of Estrogen Plus Progestin on Gynecologic Cancers and Associated Diagnostic Procedures: The Women's Health Initiative Randomized Trial. *JAMA*. 2003;290:1739-1748.
- Ashworth A, Weber BL, Domchek SM: Inherited genetic factors and breast cancer. In *Diseases of the breast*. Edited by Harris JR, Morrow M, Lippman ME, Osborne CK. Philadelphia: Wolters Kluwer; 2010:209-220.
- Bednarz-Knoll N, Nastaly P, Zaczek A, Stoupiec M, Riethdorf S, Wikman H, Müller V, Skokowski J, Szade J, Sejda A, Welnicka-Jaskiewicz M, Pantel K. Stromal expression of ALDH1 in human breast carcinomas indicates reduced tumor progression. *Oncotarget*. 2015;29:26789-26803.
- Bánkfalvi A, Ludwig A, de-Hesselle B, Buerger H, Buchwalow IB, Boecker W: Different proliferative activity of the glandular and myoepithelial lineages in benign proliferative and early malignant breast diseases. *Mod Pathol* 2004, 17:1051-1061.
- Beral V, Reeve G, Bull D, Green J, Million Women Study Collaborators. Breast cancer risk in relation to the interval between menopause and starting hormone therapy. *J Natl Cancer Inst*. 2011;103:296-305.
- Bergman A, Flodin A, Engwall Y, Arkblad EL, Berg K, Einbeigi Z, Martinsson T, Wahlström J, Karlsson P, Nordling M. A high frequency of germline BRCA1/2 mutations in western Sweden detected with complementary screening techniques. *Fam Cancer*. 2005;4:89-96.
- Bhargava R, Dabbs DJ: Immunohistology of metastatic carcinomas of unknown primary. Step 2: The cytokeratins, an overview. *Diagnostic immunohistochemistry*. Third

- edition. Edited by Dabbs DJ. Philadelphia, USA, Saunders Elsevier, 2010, pp. 210-221.
- Boecker W, Bier B, Freytag G, Brömmelkamp B, Jarasch ED, Edel G, Dockhorn-Dworniczak B, Schmid KW: An immunohistochemical study of the breast using antibodies to basal and luminal keratins, alpha smooth muscle actin, vimentin, collagen IV and laminin. Part I: Normal breast and benign proliferative lesions. *Virchows Arch A Pathol Anat Histopathol* 1992, 421:315-322.
- Boecker W, Weigel S, Heindel W, Stute P: The normal breast. Preneoplasia of the breast: A new conceptual approach to proliferative breast disease. Munich, Elsevier Saunders, 2006, pp. 1-27.
- Briskin C, Heineman A, Chavarria T, Elenbaas B, Tan J, Dey SK, McMahon JA, McMahon AP, Weinberg RA: Essential function of Wnt-4 in mammary gland development downstream of progesterone signaling. *Genes Dev* 2000, 14:650-654.
- Cancer Research UK. Breast cancer incidence (invasive) statistics 2012-2014, cancerresearchuk.org, accessed 2017-02-06.
- Catsburg C, Miller AB, Rohan TE. Active cigarette smoking and risk of breast cancer. *Int J Cancer*. 2015;136:2204-2209.
- Chang WW, Lee CH, Lee P, Lin J, Hsu CW, Hung JT, Lin JJ, Yu JC, Shao LE, Yu J, Wong CH, Yu AL. Expression of Globo H and SSEA3 in breast cancer stem cells and the involvement of fucosyl transferases 1 and 2 in Globo H synthesis. *Proc Natl Acad Sci U S A*. 2008;105:11667-11672.
- Chepko G, Slack R, Carbott D, Khan S, Steadman L, Dickson RB: Differential alteration of stem and other cell populations in ducts and lobules of TGFalpha and c-Myc transgenic mouse mammary epithelium. *Tissue Cell* 2005, 37:393-412.
- Cheung SKC, Chuang PK, Huang HW, Hwang-Verslues WW, Cho CHH, Yang WB, Shen CN, Hsiao M, Hsu TL, Chang CF, Wong CH. Stage-specific embryonic antigen-3 (SSEA-3) and β GalT5 are cancer specific and significant markers for breast cancer stem cells. *Proc Natl Sci U S A*. 2016;113:960-965.
- Chiavegato A, Bochaton-Piallat ML, D'Amore E, Sartore S, Gabbiani G: Expression of myosin heavy chain isoforms in mammary epithelial cells and in myofibroblasts from different fibrotic settings during neoplasia. *Virchows Arch* 1995, 426:77-86.
- Clarke MF, Dick JE, Dirks PB, Eaves CJ, Jamieson CHM, Jones DL, Visvader J, Weissman IL, Wahl GM. Cancer stem cells – Perspectives on current status and future directions: AACR workshop on cancer stem cells. *Cancer Res*. 2006;66:9339-9344.
- Collaborative Group on Hormonal Factors in Breast Cancer. Breast cancer and hormone replacement therapy: collaborative reanalysis of data from 51 epidemiological studies of 52,705 women with breast cancer and 108,411 women without breast cancer. *Lancet*. 1997;350:1047-1059.
- Collins LC, Schnitt SJ: Breast. Histology for pathologists. Third edition. Edited by Mills SE. Philadelphia, USA, Lippincott Williams & Wilkins, 1997, pp. 57-71.
- Coombs CC, Tallman MS, Levine RL. Molecular therapy for acute myeloid leukemia. *Nat Rev Clin Oncol*. 2016;13:305-318.

- Costello RT, Mallet F, Gaugler B, Sainty D, Arnoulet C, Gastaut JA, Olive D: Human acute myeloid leukemia CD34+/CD38- progenitor cells have decreased sensitivity to chemotherapy and Fas-induced apoptosis, reduced immunogenicity, and impaired dendritic cell transformation capacities. *Cancer Res* 2000, 60:4404-441.
- Danishefsky SJ, Shue YK, Chang MN, Wong CH. Development of Globo-H cancer vaccine. *Acc Chem Res* 2015;17:643-652.
- Dao TL: Mammary cancer induction by 7,12-dimethylbenz(a)anthracene: Relation to age. *Science* 1969, 165:810-11.
- de Jonge-Peters SD, Kuipers F, de Vries EG, Vellenga E. ABC transporter expression in hemoatopoietic stem cells and the role in AML drug resistance. *Crit Rev Oncol Hematol*. 2007;62:214-226.
- Deville P, Tavassoli FA: Tumours of the Breast. World Health Organization Classification of Tumors: Pathology and Genetics of Tumors of the Breast and Female Genital Organs. Edited by Deville P and Tavassoli FA. Lyon, IARC Press, 2003, pp. 9-112.
- Dezawa M. Muse cells provide the pluripotency of mesenchymal stem cells: direct contribution of Muse cells to tissue regeneration. *Cell Transplant*. 2016;25:849-861.
- Duester G. Retinoic acid synthesis and signaling during early oncogenesis. *Cell*. 2008;134:921-931.
- Eirew P, Kannan N, Knapp DJ, Valliant F, Emerman JT, Lindeman GJ, Visvader JE, Eaves CJ: Aldehyde dehydrogenase activity is a biomarker of primitive normal human mammary luminal cells. *Stem Cell*. 2012;30:344-348.
- Engmann NJ, Gilmakani MK, Miglioretti DL, Sprague BL, Kerlikowske K, Breast Cancer Surveillance Consortium. Population-attributable risk proportion of clinical risk factors for breast cancer. *JAMA Oncol*. 2017; doi:10.1001/jamaoncol.2016.6326.
- Erkan M, Adler G, Apte MV, Bachem MG, Buchholz M, Detlefsen S, Esposito I, Friess H, Gress TM, Habisch HJ, Hwang RF, Jaster R, Kleeff J, Klöppel G, Kordes C, Logsdon GD, Masamune A, Michalski CW, Oh J, Phillips PA, Pinzani M, Reiser-Erkan C, Tsukamoto H, Wilson J. StellaTUM: current consensus and discussion on pancreatic Stellate cell research. *Gut*. 2012;61:172-178.
- Fackenthal JD, Olopade OI. Breast cancer risk associated with BRCA1 and BRC2 in diverse populations. *Nat Rev Cancer*. 2007;7:937-948.
- Friedman SL. Hepatic Stellate cells: protean, multifunctional, and enigmatic cells of the liver. *Physiol Rev*. 2008;88:125-172.
- Gerdes J, Lelle RJ, Pickartz H, Heidenreich W, Schwarting R, Kurtsiefer L, Stauch G, Stein H: Growth fractions in breast cancers determined in situ with monoclonal antibody Ki-67. *J Clin Pathol* 1986, 39:977-980.
- Ginestier C, Hur MH, CHarafe-Jauffret E, Monville F, Dutcher J, Brown M, Jacquemier J, Viens P, Kleer CG, Liu S, Schott A, Hayes D, Birnbaum D, wicha MS, Dontu G. ALDH1 is a marker of normal and malignant human mammary stem cells and a predictor of poor clinical outcome *Cell Stem Cell*. 2007;1:555-567.
- Gupta PB, Chaffer CL, Weinberg RA. Cancer stem cells: mirage or reality? *Nat Med*. 2009;15:1010-1012.

- Hähnel R, Twaddle E, Vivian AB: Estrogen receptors in human breast cancer. 2. In vitro binding of estradiol by benign and malignant tumors. *Steroids* 1971; 18:681-708.
- Harvey JA, Santen RJ, Petroni GR, Bovbjerg VE, Smolkin ME, Sheriff FS, Russo J. Histologic changes in the breast with menopausal hormone therapy use: correlation with breast identity, estrogen receptor, progesterone receptor, and proliferation indices. *Menopause*. 2008;15:67-73.
- Hayflick L, Moorhead PS. The serial cultivation of human diploid cell strains. *Exp Cell Res*. 1961;25:585-621.
- Heerma van Voss MR, van der Groep P, Bart J, van der Wall E, van Diest PJ. Expression of the stem cell marker ALDH1 in the normal breast of BRCA1 mutation carriers. *Breast Cancer Res Treat*. 2010;123:611-612.
- Heneidi S, Simerman AA, Keller E, Singh P, Li X, Dumesic DA, Chazenbalk G. Awakened by cellular stress: isolation and characterization of a novel population of pluripotent stem cells from human adipose tissue. *PLoS One* 2013;8:e64752.
- Honeth G, Lombardi S, Ginestier C, Shinoiya I, Marlow R, Buchupalli B, Gazinska P, Brown J, Catchpole S, Liu S, Barkan A, Wicha M. Aldehyde dehydrogenase and estrogen receptor define a hierarchy of cellular differentiation in the normal human mammary epithelium. *Breast Cancer Res*. 2014;16:R52.
- Hori E, Hayakawa Y, Hayashi T, Hori S, Okamoto S, Shibata T, Kubo M, Horie Y, Sasahara M, Kuroda S. Mobilization of pluripotent multilineage-differentiating stress-enduring cells in ischemic stroke. *J Stroke Cerebrovasc Dis*. 2016;25:1473-1481.
- Huang M, Yuqing L, Huanle Z, Feifei N: Breast cancer stromal fibroblasts promote the generation of CD44+CD24- cells through SDF-1/CXCR4 interaction. *J Exp Clin Cancer Res* 2010, 29:80.
- IARC. Cancer today, International Agency for Research on Cancer, World Health Organization, gco.iarc.fr, accessed 2017-02-05.
- Isfoss BL, Holmqvist B, Alm P, Olsson H. Distribution of aldehyde dehydrogenase 1-positive stem cells in benign mammary tissue from women with and without breast cancer. *Histopathology*. 2012;60:617-633.
- Isfoss BL, Holmqvist B, Jernström H, Alm P, Olsson H. Women with familial risk for breast cancer have an increased frequency of aldehyde dehydrogenase expressing cells in breast ductules. *BMC Clin Pathol*. 2013;13:28.
- Isfoss BL, Busch C, Hermelin H, Vermedal AT, Kile M, Braathen GJ, Majak B, Berner A. Stem cell marker-positive Stellate cells and mast cells are reduced in benign-appearing bladder tissue in patients with urothelial carcinoma. *Virchows Arch*. 2014;464:473-488.
- Isfoss BL, Holmqvist B, Jernström H, Alm P, Olsson H. The absence of aldehyde dehydrogenase 1 A1-positive cells in benign mammary stroma is associated with risk factors for breast cancer. *Breast Cancer (Dove Med Press)*. 2016;8:117-124.
- Jernström H, Leman C, Ghadirian P, Lynch HT, Weber B, Garber J, Daly M, Olopade OI, Foulkes WD, Warner E, Brunet JS, Narod SA. Pregnancy and risk of early breast cancer in carriers of BRCA1 and BRCA2. *Lancet*. 1999;354:1846-1850.

- Jernström H, Bendahl PO, Lidfeldt J, Nerbrand C, Agardh CD, Samsioe G. A prospective study of different types of hormone replacement therapy use and the risk of subsequent breast cancer: the women's health in the Lund area (WHILA) study (Sweden). *Cancer Causes Control*. 2003;14:673-680.
- Jernström H, Loman N, Johannsson OT, Borg A, Olsson H. Impact of teenage oral contraceptive use in a population-based series of early-onset breast cancer cases who have undergone BRCA mutation testing. *Eur J Cancer*. 2005;41:2312-2320.
- Johansson O, Loman N, Borg A, Olsson H. Pregnancy-associated breast cancer in BRCA1 and BRCA2 germline mutation carriers. *Lancet*. 1998;352:1359-1360.
- Jørgensen KJ, Gøtsche PC, Kalager M, Zahl PH. Breast cancer screening in Denmark: a cohort study of tumor size and overdiagnosis. *Ann Intern Med*. 2017;doi 10.7326/M16-0270.
- Kalager M, Zelen M, Langmark F, Adami HO. Effect of mammography on breast-cancer mortality in Norway. *N Engl J Med*. 2010;363:1203-1210.
- Kang EJ, Jung H, Woo OH, Park KH, Woo SU, Yang DS, Kim AR, Lee JB, Kim YH, Kim JS, Seo JH. Association of aldehydehydrogenase 1 expression and biologically aggressive features in breast cancer. *Neoplasma*. 2014;61:352-361.
- Keeling JW, Ozer E, King G, Walker F: Oestrogen receptor alpha in female fetal, infant, and child mammary tissue. *J Pathol* 2000, 191:449-451.
- Kelsey JL, Gammon MD, John EM. Reproductive factors and breast cancer. *Epidemiol Rev*. 1993;15: 36-47.
- Kumle M, Weiderpass E, Braaten T, Persson I, Adami HO, Lund E. Use of oral contraceptives and breast cancer risk: The Norwegian-Swedish women's lifestyle and health cohort study. *Cancer Epidemiol Biomarkers Prev*. 2002;11:1375-1381.
- Kunju LP, Cookingham C, Toy KA, Chen W, Sabel MS, Kleer CG: EZH2 and ALDH-1 mark breast epithelium at risk for breast cancer development. *Mod Pathol*. 2011; 24:786-793.
- Kuroda Y, Kitada M, Wakao S, Nishikawa K, Tanimura Y, Makinoshima H, Goda M, Akashi H, Inutsuka A, Niwa A, Shigemoto T, Nabeshima Y, Nakahata T, nabeshima Y, Fujiyoshi Y, Dezawa M. Unique multipotent cells in adult human mesenchymal cell populations. *P N A S*. 2010;107:8639-8643.
- Kurzrock EA, Lieu DK, deGraffenried LA, Chan CW, Isseroff RR. Label-retaining cells of the bladder: candidate urothelial stem cells. *Am J Physiol Renal Physiol*. 2008;294:F1415-1421.
- Kotsopoulos J, Lubinski J, Lynch HT, Klijn J, Ghadirian P, Neuhausen SL, Kim-Sing C, Foulkes WD, Moller P, Isaacs C, Domchek S, Randall S, Offit K, Tung N, Ainsworth P, Gershoni-Baruch R, Eisen A, Daly M, Karlan B, Saal HM, Couch F, Pasini B, Wagner T, Friedman E, Rennert G, Eng C, Weitzel J, Sun P, Narod SA, Garber J, Osborne M, Fishman D, McLennan J, McKinnon W, Merajver S, Olsson H, Provencher D, Pasche B, Evans G, Meschino WS, Lemire E, Chudley A, Rayson D, Bellati C. Age at first birth and the risk of breast cancer in BRCA1 and BRCA2 mutation carriers. *Breast Cancer Res Treat*. 2007 Oct;105(2):221-228.
- Kinoshita K, Kuno S, Ishimine H, Aoi N, Minoda K, Kato H, Doi K, Kanayama K, Feng J, Mashiko T, Kurisaki A, Yoshimura K. Therapeutic potential of adipose-derived

- SSEA-3-positive Muse cells for treating diabetic skin ulcers. *Stem Cells Transl Med.* 2015;4:146-155.
- Kristiansen G, Winzer K-J, Mayordomo E, Bellach J, Schlüns K, Denkert C, Dahl E, Pilarsky C, Altevogt P, Guski H, Dietel M: CD24 expression is a new prognostic marker in breast cancer. *Clin Cancer Res* 2003, 9:4906-4913.
- Lakhani S, Ellis IO, Schnitt SJ, Tan PH, van de Vijver MJ. WHO Classification of Tumours of the Breast, Fourth Edition. Lyon: IARC Press; 2012.
- Kumle M, Weierpass E, Braaten T, Persson I, Adami HO, Lund E. Use of oral contraceptives and breast cancer risk. The Norwegian-Swedish Women's lifestyle and Health Cohort Study. *Cancer Epidemiol Biomarkers Prev* 2002;11:1375-1382.
- Lazard D, Xavier S, Frid MG, Glukhova MA, Thierry J-P: Expression of smooth muscle-specific proteins in myoepithelium and stromal myofibroblasts of normal and malignant human breast tissue. *Proc Natl Acad Sci USA* 1993:999-1003.
- Lerwill MF. Current practical applications of diagnostic immunohistochemistry in breast pathology. *Am J Surg Pathol* 2004, 28:1076-1091.
- Liu S, Ginestier C, Charafe-Jauffret E, Foco H, Kleer CG, Merajver SD, Dontu G, Wicha MS: BRCA1 regulates human mammary stem/progenitor cell fate. *Proc Natl Acad Sci USA* 2008; 105:1680-1685.
- Liu S, Wang D, Sun Y, Deng L, Liu Y, Martin-Trevino R, Shang L, McDermott SP, Landis MD, Hong S, Adams A, D'Angelo R, Ginestier C, Charafe-Jauffret E, Clouthier SG, Bimbaum D, Wong ST, Zhan M, Chang JC, Wicha MS. Breast cancer stem cells transition between epithelial and mesenchymal states reflective of their normal counterparts. *Stem Cell Reports.* 2014;2:78-91.
- Ma H, Henderson KD, Sullivan-Halley J, Duan L, Marshall SF, Ursin G, Horn-Ross PL, Largent J, Deapen DM, Lacey JV, Bernstein L. Pregnancy-related factors and the risk of breast carcinoma in situ and invasive breast cancer among postmenopausal women in the California Teachers Study cohort. *Breast Cancer Res.* 2010;12:R35.
- Ma I, Allan AL: The role of human aldehyde dehydrogenase in normal and cancer stem cells. *Stem Cell Rev and Rep.* 2011;7:292-306.
- MacMahon B, Cole P, Lin TM, Lowe CR, Mirra AP, Ravnihar B, Salber EJ, Valaoras VG, Yuasa S. *Bull World Health Organ.* 1970;43:209-221.
- Makin CA, Bobrow LG, Bodmer WF: Monoclonal antibody to cytokeratin for use in routine histopathology. *J Clin Pathol* 1984, 37:975-983.
- Marchitti SA, Brocker C, Stagos D, Vasiliou V. Non-P450 aldehyde oxidizing enzymes: the aldehyde dehydrogenase superfamily. *Expert Opin Drug Metab Toxicol.* 2008;4:697-720.
- McGregor DH, Land CE, Choi K, Tokuoka S and Liu PI: Breast cancer incidence among atomic bomb survivors, Hiroshima and Nagasaki, 1950-69. *J Natl Cancer Inst* 1977, 59:799-811.
- Mercato P, Dean CA, Pan D, Araslanova R, Gillis M, Joshi M, Helyer L, Pan L, Leidal A, Gujar S, Giacomantonio CA, Lee PWK. Aldehyde dehydrogenase activity of breast cancer stem cells is primarily due to isoform ALDH1A3 and its expression is predictive of metastasis. *Stem Cells.* 2011;29:32-45.

- Miller TJ, McCoy MJ, Hemmings C, Bulsara MK, Iacopetta B, Platell CF. Objective analysis of cancer stem cell marker expression using immunohistochemistry. *Pathology*. 2017;49:24-29.
- Million Women Study Collaborators. Breast cancer and hormone-replacement therapy in the Million Women Study. *Lancet*. 2003;362:419-427.
- Morrison SJ, Kimble J. Asymmetric and symmetric stem-cell divisions in development and cancer. *Nature*. 2006;441:1068-1074.
- Morsing M, Klitgaard MC, Jafari A, Villadsen R, Kassem M, Petersen OW, Rønnov-Jessen L. Evidence of two distinct functionally specialized fibroblast lineages in breast stroma. *Breast Cancer Res*. 2016;18:108.
- Munsell MF, Sprague BL, Berry DA, Chrisholm G, Trentham-Dietz A. Body mass index and breast cancer risk according to postmenopausal estrogen-progestin use and hormone receptor status. *Epidemiol Rev*. 2014;36:114-136.
- Nakane PK. Ito's "fat storing cell" of the mouse liver. *Anat Rec*. 1963;145:265-266.
- Natrajan R, Weigelt B. Risk stratification and intrinsic subtype classification of breast cancer: a multi-parameter test to rule them all? *J Natl Cancer Inst*. 2016;108:djw118. doi: 10.1093/jnci/djw118.
- NORDCAN. Faktablad cancerstatistik. www-dep.iarc.fr, accessed 2017-02-06.
- Nalwoga H, Arnes JB, Wabinga H, Akslen LA: Expression of aldehyde dehydrogenase (ALDH1) is associated with basal-like markers and features of aggressive tumours in African breast cancer. *Br J Cancer*. 2010;102:369-375.
- Nordlinder H, Eriksson U, Busch C. Identification of extrahepatic stellate cells and the cell specific regulation of cellular retinol binding protein. *In*: Distribution of cytoplasmic retinol- and retinoic acid-binding proteins: identification of an interstitial vitamin A-storing cell system. Doctoral thesis 1991 No. 284 (Paper 5). Uppsala: Acta Universitatis Upsaliensis.
- Oh H, Bodelon C, Palakal M, Chatterjee N, Sherman ME, Linville L, Geller BM, Vacek PM, Weaver DL, Chicoine RE, Papathomas D, Patel DA, Xiang J, Clare SE, Visscher DW, Mies C, Hewitt SM, Brinton LA, Storniolo AMV, He C, Garcia-Closas M, Chanock SJ, Gierach GL, Figueroa JD. Ages at menarche- and menopause-related genetic variants in relation to terminal duct lobular unit involution in normal breast tissue. *Breast Cancer Res Treat*. 2016;158:341-350.
- Olsson H. Risk for malignant tumors after oral contraeptive use: is it related to organ size while taking the pill? *Med Oncol Tumor Pharmacother*. 1990;7:61-64.
- Olsson H. Tumour biology of a breast cancer at least partly reflects the biology of the tissue/epithelial cell of origin at the time of initiation – a hypothesis. *J Steroid Biochem Mol Biol*. 2000;74:345-350.
- Olsson H, Jernström H, Alm P, Kreipe H, Ingvar C, Jonsson PE, Rydén S. Proliferation of the breast epithelium in relation to menstrual cycle phase, hormonal use, and reproductive factors. *Breast Cancer Res Treat*. 1996;40:187-196.
- Olsson HL, Ingvar C, Bladstrom A. Hormone replacement therapy containing progestins and given continuously increases breast carcinoma risk in Sweden. *Cancer*. 2003;97:1387-1392.

- Olsson H, Möller TR, Ranstam J. Early oral contraceptive use and premenopausal breast cancer - Final report from a study in southern Sweden. *J Natl Cancer Inst.* 1989;81:1000-1004.
- Olsson H, Ingvar C, Bladström A. Hormonal replacement therapy containing progestins and given continuously increases breast carcinoma risk in Sweden. *Cancer.* 2003;97:1387-92.
- Pappenheim A. *Atlas der Menschlichen Blutzellen.* Jena, Gustav Fischer, 1905.
- Park SY, Hee EL, Hailun L, Shipitsin M, Gelman R, Polyak K: Heterogeneity for stem cell-related markers according to tumor subtype and histologic stage in breast cancer. *Clin Cancer Res* 2010, 16:876-87.
- Petersen OW, Polyak K: Stem cells in the human breast. *Cold Spring Harb Perspect Biol* 2010, 2:a003160.
- Pittenger MF, Mackay AM, Beck SC, Jaiswal RK, Douglas R, Mosca JD, Moorman MA, Simonetti DW, Craig S, Marshak DR. Multilineage potential of adult human mesenchymal stem cells. *Science.* 1999;284:143-147.
- Retsekova E, Reis-Filho JS, Jain RK, Mehta R, Thorat MA, Nakshatri H, Badve S. Prognostic impact of ALDH1 in breast cancer: a story of stem cells and tumor microenvironment. *Breast Cancer Res Treat.* 2010;123:97-108.
- Reya T, Morrison SJ, Clarke MF, Weissmann IL: Stem cells, cancer, and cancer stem cells. *Nature.* 2001;414:105-111.
- Rudland PS. Epithelial stem cells and their possible role in the development of the normal and diseased human breast. *Histol Histopathol* 1993, 8:385-404.
- Russo J, Russo IH: Development of the human mammary gland. *The mammary gland.* Edited by Neville MC, Daniel C. New York, Plenum Publishing Inc, 1987, pp 67-93.
- Russo J, Gusterson BA, Rogers AE, Russo IH, Welling Sr, Van Zwieten MJ: Comparative study of human and rat mammary tumorigenesis. *Lab Invest* 1990, 62:244-278.
- Russo J, Russo IH. Toward a physiological approach to breast cancer prevention. *Cancer Epidemiol Biomarkers Prev.* 1994;3:353-364.
- Russo J, Ao X, Grill C, Russo IH: Pattern of distribution of cells positive for estrogen receptor α and progesterone receptor in relation to proliferating cells in the mammary gland. *Breast Cancer Res Treat* 1999, 53:217-227.
- Russo J, Hu YF, Yang X, Russo IH. Developmental, cellular, and molecular basis of human breast cancer. *J Natl Cancer Inst Monogr.* 2000;27:17-37.
- Russo IH, Russo J. Pregnancy-induced changes in breast cancer risk. *J Mammary Gland Biol Neoplasia.* 2011;16:221-233.
- Rust W, Pollok B. Reaching for consensus on a naming convention for pluripotent cells. *Cell Stem Cell.* 2011;8:607-608.
- Samson ME, Adams SA, Mulataya CM, Zhang J, Bennett CL, Hebert J, Steck SE. Types of oral contraceptives and breast cancer survival among women enrolled in Medicaid: A competing-risk model. *Maturitas.* 2017;95:42-49.
- Schackleton M, Vaillant F, Simpson KJ, Stingl J, Smyth GK, Asselin-Labat ML, Wu L, Lindeman GJ, Visvader JE: Generation of a functional mammary gland from a single stem cell. *Nature* 2006, 439:84-88.

- Schwartz T, Stark A, Pang J, Awuah B, Kleer CG, Quayson S, Kingman S, Aitpillah F, Jiagge E, Oppong JK, Osei-Bonsu E, Martin I, Yan X, Toy K, Adjei E, Wicha M, Newman LA: Expression of aldehyde dehydrogenase 1 as a marker of mammary stem cells in benign and malignant breast lesions of Ghanaian women. *Cancer*. 2013;119:488-494.
- Shevinsky LH, Knowles BB, Damjanov I, Solter D. Monoclonal antibody to murine embryos defines a stage-specific embryonic antigen expressed on mouse embryos and human teratocarcinoma cells. *Cell*. 1982;30:697-705.
- Shiovitz S, Korde LA. Genetics of breast cancer: a topic in evolution. *Ann Oncol*. 2015;26:1291-1299.
- SEER. Breast cancer risk in American women, data from SEER reports, cancer.gov, accessed 2017-02-06.
- Schonfeld SJ, Pfeiffer RM, Lacey JV, Berrington de Gonzalez A, Doody MM, Greenlee RT, Park Y, Schairer C, Schatzkin A, Sigurdson AJ, Hartge P, Visvanathan K: Hormone-related risk factors and postmenopausal breast cancer among nulliparous versus parous women: an aggregated study. *Am J Epidemiol*. 2011;173:509-517.
- Sinn HP, Elsayaf Z, Helmchen B, Aulmann S: Early breast cancer precursor lesions: lessons learned from molecular and clinical studies. *Breast Care*. 2010;5:218-226.
- Sørle T, Perou CM, Tibshirani R, Aas T, Geisler S, Johnsen H, Hastie T, Eisen MB, van de Rijn M, Jeffrey SS, Thorsen T, Quist H, Matese JC, Brown PO, Botstein D, Lønning PE, Børresen-Dale AL, PNAS, 2001;98:10869-10874.
- Spangrude GJ, Heimfeld S, Weissman IL. Purification and characterization of mouse hematopoietic stem cells. *Science*. 1988;241:58-62.
- Stingl J, Eaves CJ, Zandieh I, Emerman JT. Characterization of bipotent mammary epithelial progenitor cells in normal adult human breast tissue. *Breast Cancer Res Treat* 2001, 67:93-109.
- Stingl J. Detection and analysis of mammary gland stem cells. *J Pathol* 2009, 217:229-241.
- Stirling JW, Chandler JA. The fine structure of the normal, resting terminal ductal-lobular unit of female breast. *Virchows Arch A Pathol Anat Histo*. 1976;372:205-226.
- Suzuki Y, Haraguchi N, Takahashi H, Uemura M, Nishimura J, Hata T, Takemasa I, Mizushima T, Ishii H, Doki Y, Mori M, Yamamoto H. SSEA-3 is a novel amplifying cancer cell surface marker in colorectal cancers. *Int J Oncol*. 2013;42:161-167.
- Szabo CI, King MC. Population genetics of BRCA1 and BRCA2. *Am J Hum Genet*. 1997;60:1013-1020.
- Tanei T, Morimoto K, Shimazu K, Kim SJ, Tanji Y, Taguchi T, Tamaki Y, Noguchi S: Association of breast cancer stem cells identified by aldehyde dehydrogenase 1 expression with resistance to sequential paclitaxel and epirubicin-based chemotherapy for breast cancers. *Clin Cancer Res*. 2009;15:4234-4241.
- Tavassoli FA: Myoepithelial lesions of the breast. Myoepitheliosis, adenomyoepithelioma, and myoepithelial carcinoma. *Am J Surg Pathol* 1991, 15:554-68.
- Thomas ED, Storb R, Clift RA, Fefer A, Johnson L, Neiman PE, Lerner KG, Glucksberg H, Buckner CD. Bone-marrow transplantation (first & second parts). *N Engl J Med*. 1975;292:832-843 & 895-902.

- Tsai YC, Lu Y, Nichols PW, Zlotnikov G, Jones PA, Smith HS. Contiguous patches of normal human mammary epithelium derived from a single stem cell: implications for breast carcinogenesis. *Cancer Res.* 1996;56:402-404.
- van Es JH, Sato T, van de Wetering M, Lyubimova A, Gregorieff A, Zeinstra L, van den Born M, Korving J, Martens ACM, van den Oudenaarden A, Clevers H. Dll1 marks early secretory progenitors in gut crypts that can revert to stem cells upon tissue damage. *Nat Cell Biol.* 2012;14:1099-1104.
- Van Rossen E, Vander Borgh S, van Grunsven LA, Reynaert H, Bruggeman V, Blomhoff R, Roskams T, Geerts A. Vinculin and cellular retinol-binding protein-1 are markers for quiescent and activated hepatic stellate cells in formalin-fixed paraffin embedded human liver. *Histochem Cell Biol.* 2009;131:313-324.
- Vandenberg LN, Hauser R, Marcus M, Olea N, Weishons MV. Human exposure to bisphenol A (BPA). *Reprod Toxicol.* 2007;24:139-177.
- Villadsen R, Fridrikdottir AJ, Rønnov-Jessen L, Gudjonsson T, Rank F, LaBarge MA, Bissell MJ, Petersen OW. Evidence for a stem cell hierarchy in the adult human breast. *J Cell Biol.* 2007;177:87-101.
- Wakao S, Kitada M, Kuroda Y, Shigemoto T, Matsuse D, Akashi H, Tanimura Y, Tsuchiyama K, Kikuchi T, Goda M, Nakahata T, Fujiiyoshi Y, Dezawa M. Multilineage-differentiating stress-enduring (Muse) cells are a primary source of induced pluripotent stem cells in human fibroblasts. *Proc Natl Acad Sci U S A.* 2011;108:9875-9880.
- Wake K. Perisinusoidal Stellate cells (fat-storing cells, interstitial cells, lipocytes), their related structure in and around the liver sinusoids, and vitamin A-storing cells in extrahepatic organs. *Int Rev Cytol.* 1980;66:303-353.
- Wellings SR, Jensen HM, Marcum RG. An atlas of subgross pathology of the human breast with special reference to possible precancerous lesions. *J Natl Cancer Inst.* 1975;55:231-273.
- Werling RW, Hwang H, Yaziji H, Gown AM:Immunohistochemical distinction of invasive from noninvasive breast lesions: A comparative study of p63 versus calponin and smooth muscle myosin heavy chain. *Am J Surg Pathol*, 2003. 27:82-90.
- Yang Z, Liu J, Liu H, Qiu M, Liu Q, Zheng L, Pang M, Quan F, Zhang Y. Isolation and characterization of SSEA3(+) stem cells derived from goat skin fibroblasts. *Cell Reprogram.* 2013;15:195-205.
- Yen MF, Tabar L, Vitak B, Smith RA, Chen HH, Duffy SW. Quantifying the potential problem of overdiagnosis of ductal carcinoma in situ in breast cancer screening. *Eur J Cancer.* 2003;39:1746-1754.
- Yoshida A, Rzhetsky A, Hsu LC, Chang C. Human aldehyde dehydrogenase gene family. *Eur J Biochem.* 1998;251:549-557.
- Yoshioka T, Umekita Y, Ohi Y, Souda M, Sagara Y, Sagara Y, Sagara Y, Rai Y, Tanimoto A. Aldehyde dehydrogenase 1 expression is a predictor of poor prognosis in node-positive breast cancers: a long-term follow-up study. *Histopathology.* 2011;58: 608-616.

Yu J, Vodyanik MA, Smuga-Otto K, Antosiewicz-Bourget J, Frane JL, Tian S, Nie J, Jonsdottir GA, Ruotti V, Stewart R, Slukvin II, Thomson JA. Induced pluripotent stem cell lines derived from human somatic cells. *Science*. 2007;318:1917-1920.

Acknowledgement

I wish to thank my principal supervisor professor Håkan Olsson for encouragement and solid support from inception to completion of this study. His knowledge of breast cancer is exceptional. My assistant supervisor, associate professor Bo Holmqvist, generously provided the very detailed guidance necessary to handle scientific questions, laboratory techniques, and writing. Very early, professor Per Alm generously provided facilities, know-how, manpower, reagents, and critical views on the subject, all of which were necessary to explore the questions that sparked my interest in this field. This trio served as conversation partners and cheerleaders during the transformation of the project from idea to scientific testing. I also wish to thank associate professor Helena Jernström, a valued co-researcher during the mid- and late parts of the project, who provided sharp scientific analysis, and important advice during the writing stages.

Although my motivation for this study was was histological curiosity, with no intention to become a researcher, the people mentioned above made me one. This environment could not have been better for a practitioner of routine medicine who posed critical questions about the current state of knowledge.

I also thank all those at the Department of Pathology in Lund who helped us anchoring the project clinically and who performed impeccable technical work. I offer special thanks to the staff at ImaGene-iT AB in Lund, which was almost my second home during these eventful years. The professionalism exhibited by the people mentioned above was exemplary, and ensured results. For me as a non-Swede living outside Sweden, I am impressed by how people in this country pave the way for science as a matter of course.

This research would never have happened without true enthusiasm and concrete support from my wife Katarina, and her parents Barbro and Gunnar. Our little children Arna Elisabet and Gunnar Logi patiently endured hours, days and weeks with a very absent-minded father. All my five children's relentless curiosity, sense of humor and playfulness are a constant inspiration for me – perhaps this effort will inspire them!

I offer my deepest thanks to my colleagues and to my family.
We did this together.

Appendix

Distribution of aldehyde dehydrogenase 1-positive stem cells in benign mammary tissue from women with and without breast cancer

Björn L Isfoss,^{1,2} Bo Holmqvist,³ Per Alm² & Håkan Olsson⁴

¹Department of Pathology, Telemark Hospital, Skien, Norway, ²Department of Pathology, ³Department of Oncology and Lund Bioimaging Centre, and ⁴Departments of Oncology and Cancer Epidemiology, Clinical Sciences, Lund University, Lund, Sweden

Date of submission 14 December 2010
Accepted for publication 16 August 2011

Isfoss B L, Holmqvist B, Alm P & Olsson H

(2012) *Histopathology*

Distribution of aldehyde dehydrogenase 1-positive stem cells in benign mammary tissue from women with and without breast cancer

Aims: Aldehyde dehydrogenase 1 (ALDH1) in female breast tissue has been linked to stem cells, but little is known about the benign cellular organization *in situ*. We investigated the distribution of ALDH1-immunoreactive (ALDH1+) cells in histomorphologically benign breast tissue from 28 women with or without breast cancer.

Methods and results: ALDH1+ cells were detected in benign tissue of women aged 20–72 years, located most commonly at the luminal and intermediate ductular levels and in the stroma. ALDH1+ cell populations and Ki67+ cell populations were present in separate ductules, both cell types rarely showing epithelial differentiation. ALDH1+ cells were non-reactive to Ki67 and oestrogen receptor. Stromal

round/oval ALDH1+ non-leukocyte cells in both age groups expressed contractile protein. There was a lower concentration of luminal and intermediate ductular ALDH1+ cells in postmenopausal women than in premenopausal women, and in cancer patients than in non-cancer patients, and a higher concentration in women receiving exogenous hormones.

Conclusions: This study provides further evidence for the stem cell character of ALDH1+ cells, here in benign breast tissue of cancer and non-cancer patients throughout non-lactating adult life, and contributes evidence of benign stromal ALDH1+ cells. The distribution of ductular ALDH1+ stem cells appears to be influenced by hormonal status.

Keywords: ALDH1, breast, histology, immunohistochemistry, stem cells

Abbreviations: ALDH1, aldehyde dehydrogenase 1; DAB, 3,3'-diaminobenzidine; DAPI, 4',6-diamidino-2-phenylindole; ER, oestrogen receptor; FITC, fluorescein isothiocyanate; HRP, horseradish peroxidase; HRT, hormone replacement therapy; IUD, intrauterine device; PBS, phosphate-buffered saline; PBS-TX, phosphate-buffered saline containing Triton X-100; SC, stem cell; SMMHC, smooth muscle myosin heavy chain; TBS, Tris-buffered saline; TLDU, terminal ductal-lobular unit; TX, Triton X-100; WHO, World Health Organization

Introduction

Adult somatic stem cells (SCs) possess self-renewal capacity and can divide into either two identical SCs,

i.e. two daughter cells committed to a particular differentiation route, or, through asymmetrical division, one SC and one committed cell (progenitor cell).¹ A single mouse mammary breast SC can develop into a complete mammary gland.² The prevailing theory is that cancer SCs reside in a non-proliferative state, and that they can act as a cancer reservoir that is poorly targeted by currently used cancer therapies.³ The

Address for correspondence: B L Isfoss, Department of Pathology, Telemark Hospital, 3715 Skien, Norway. e-mail: isfoss@mac.com

expression of antigens (molecular identity) and functional qualities of SCs in benign adult human breast tissue have been partially described.^{4,5} However, the molecular expression and the histological and temporal distribution of breast SCs, benign or malignant, are still not well understood. The prediction and treatment of breast cancer could possibly be improved by further characterization of SCs.

Stem cell populations have been identified in human and murine breast,⁴ and antigens expressed by cancer SCs have subsequently been identified, characterized as CD44+, CD24+, and $\text{lin}^{-/\text{low}}$.⁵ The *in-situ* locations of SCs have been partly investigated in both benign and cancerous breast tissue, with CD44 and CD24 and other recently proposed molecular markers, often in combination.^{6,7} Recently, it was suggested that aldehyde dehydrogenase 1 (ALDH1) expression alone is a powerful marker of both benign and malignant SCs in breast tissue,⁶ although there are recent data questioning whether the particular isoform (A1) used in that study is the most effective isoform for identifying cancer SCs in the breast.⁸ The discussion on SCs in the breast has focused on the glandular and myoepithelial cell types and their putatively common (bipotential) SC/progenitor cell.^{9,10} It has recently been demonstrated that SCs can occur in a luminal ductular location in the adult female breast,⁶ in contrast to the prevailing theory that SCs have a basal location.¹¹

In breast cancer tissue, ALDH1+ cells of both the epithelial and stromal type have recently been reported.¹² Furthermore, ALDH1 positivity has recently been reported by Heerma van Voss *et al.*^{13,14} in morphologically benign breast stroma in *BRCA1* mutation carriers undergoing prophylactic mastectomies or surgery for invasive carcinoma. To our knowledge, our data are the first to show the cellular identity and location of ALDH1+ cells in morphologically benign breast stroma and ductules of cancer and non-cancer patients.

The major susceptibility to breast carcinogenicity in women has been proposed to occur between 10 and 19 years of age. Experimental data from mice support a prepubertal induction of susceptibility to cancer.¹⁵ In young women, a third ductular, non-epithelial and non-myoepithelial cell, a putative SC or progenitor cell, has been localized in the end buds.¹⁶ This cell population is composed of closely packed cells that are separate from luminal cells and purely myoepithelial cells. Together, these data suggest an age-related susceptibility to breast cancer via early life effects on SCs or progenitor cells, causing clinically detectable cancer in adults. However, there are so far no descriptions of benign breast SC occurrence and orga-

nization throughout the course of adult, non-lactating female life. Our present study addresses this need.

In the current study using ALDH1 immunohistochemistry we investigated the spatiotemporal organization of breast SCs in benign breast tissue from different age groups, in patients diagnosed with cancer and in healthy women. We performed detailed investigations on benign tissue from cancer patients, and compared the distribution of ALDH1+ cells in this patient group with that of a non-cancer patient group.

This study aimed to improve SC identification in benign breast tissue by means of descriptions of the SC character of ALDH1-expressing cells in ductules and stroma, including their morphology, differentiation, proliferation status, and relationships with other cell types.

Materials and methods

TISSUE AND HISTOMORPHOLOGICAL ASSESSMENT

The tissue used for this investigation was taken from formalin-fixed paraffin-embedded blocks. These were selected randomly from a large series of healthy women who had undergone mastoplasia ($n = 14$), and selectively from women with histologically documented invasive breast cancer, procured in the periods 1993–1994 (non-cancer) and 2002–2004 (cancer) at Lund University Hospital ($n = 14$). The selection of tissue blocks from women with cancer was based on the maximum availability of benign epithelial structures in the tissue block 'representative of tissue stored in frozen tumour bank' from a large series of consecutive breast cancer operation specimens.

The women were premenopausal ($n = 14$), perimenopausal ($n = 3$) or postmenopausal ($n = 11$). Perimenopausal and postmenopausal women (aged 48 years and older) were combined in the same age group (as 'postmenopausal') for purposes of data analysis. The clinical characteristics of the patients and corresponding breast tissue pathology are shown in Tables 1 and 2. The original histopathology diagnosis was verified by one of the pathologists (B.L.I.), guided by the World Health Organization (WHO) classification of tumours.¹⁷ The definition of histology and the terminology used were originally from Wellings *et al.*¹⁸ and Stirling and Chandler.¹⁹ The term terminal ductal-lobular unit (TDLU) was used for all breast lobules, and in reference to intralobular stroma²⁰ as TDLU stroma irrespective of lobule type,^{21,22} as adopted by the WHO.¹⁷ When the distributions of cells within ductules were determined, cells whose nuclei were aligned at the luminal aspect were defined

Table 1. Aldehyde dehydrogenase 1-immunoreactive (ALDH1+) cells in benign tissue, correlated with clinical data

Hormonal, gestational, genetic and cancer history					Morphologically benign breast tissue data				
					Fraction of TDLUs showing any ALDH 1+ cells at each ductular level (%)			Mean number of round/oval ALDH1+ cells/mm ²	
Breast cancer	Menopausal status	Exogenous hormones	Gestational history	Family history	Age (years)	Luminal level	Intermediate level	Basal level	TDLU stroma
Premenopausal women with breast cancer									
Yes	Pre	Pill	OG	BRCA1	28	20	9	8	5
Yes	Pre	Pill	OG	No	31	16	9	0	9
Yes	Pre	No	5G1P	Yes	36	4	0	0	13
Yes	Pre	No	3P	No	37	4	2	0	4
Yes	Pre	No	3P	No	38	2	1	0	13
Yes	Pre	No	2P	No	38	0	0	0	11
Yes	Pre	No	2P	Yes	40	1	1	1	3
Mean					35	7	3	1	8
Perimenopausal or postmenopausal women with breast cancer									
Yes	Peri	No	3P	Yes	48	0	0	0	9
Yes	Peri	Prog	3P	No	50	4	4	2	5
Yes	Peri	No	5G3P	No	52	*	*	*	*
Yes	Post	No	3P	Yes	54	1	1	0	7
Yes	Post	HRT	OG	No	61	8	2	0	2
Yes	Post	Oestr	4P	No	66	0	0	0	11
Yes	Post	No	3P	No	72	0	0	0	5
Mean					58	2	1	0	6
Premenopausal women with no breast cancer									
No	Pre	Pill	OG	No	20	25	15	3	15

Table 1. (Continued)

Hormonal, gestational, genetic and cancer history						Morphologically benign breast tissue data				
						Fraction of TDLUs showing any ALDH 1+ cells at each ductular level (%)			Mean number of round/oval ALDH1+ cells/mm²	
Breast cancer	Menopausal status	Exogenous hormones	Gestational history	Family history	Age (years)	Luminal level	Intermediate level	Basal level	TDLU stroma	
No	Pre	No	3P	No	27	33	29	2	8	
No	Pre	No	4G3P	No	36	20	12	2	7	
No	Pre	No	OG	No	36	16	12	0	11	
No	Pre	No	3P	No	40	0	0	0	3	
No	Pre	No	3G2P	Yes	41	4	4	1	11	
No	Pre	No	3P	No	50	10	8	3	6	
Mean					36	15	11	2	9	
Postmenopausal women with no breast cancer										
No	Post	No	4G3P	No	48	30	5	5	17	
No	Post	No	3P	No	53	3	3	0	5	
No	Post	No	4G3P	No	57	0	0	0	11	
No	Post	HRT	3P	No	57	13	9	0	4	
No	Post	No	2P	No	57	13	7	13	4	
No	Post	No	1P	No	64	0	0	0	5	
No	Post	No	2P	No	67	6	6	0	9	
Mean					58	9	4	3	8	

G, Pregnancy; HRT, hormone replacement therapy with a progestin component; Oestr, transcutaneous oestrogen; P, parity; Peri, perimenopausal; Pill, contraceptive pill; Post, postmenopausal; Pre, premenopausal; Prog, progestin intrauterine device; TDLU, terminal ductal-lobular unit.

Clinical characteristics, including hormonal therapy, are of patients at the time of surgery. All examined tissue from patients with breast cancer was from histomorphologically normal areas of breast cancer specimens. Tissue from women without breast cancer was from mammoplasties without atypia. The table demonstrates the recorded presence and distribution of ALDH1+ cells in the studied benign breast tissues in relation to the individual patient hormonal status, exogenous hormones, and family history. These data suggest a decrease in the number of ductular ALDH1+ cells after menopause, which appears to be counteracted in two women aged 61 and 57 years by exogenous progestin. The stromal ALDH1+ cell concentration does not appear to be influenced by menopausal status.

*This experiment could not be conducted, owing to a lack of remaining tissue in the block.

Table 2. Clinical histopathology data for patients from whom benign tissues were selected for this study (see text for criteria)

Case	Tumour size (mm)	Histological type of invasive cancer, grade	ER α	PR	Lymph node metastasis
1	15	Ductal, 3	–	+	No
2	14	Ductal, 3	+	+	No
3	15	Ductal, 2	+	+	No
4	15	Medullary, 3	+	+	No
5	9	Ductal, 2	–	–	No
6	13	Ductal, 2	+	–	Yes
7	12	Ductal, 2	+	+	No
8	16	Ductal, 2	+	+	No
9	27	Lobular, 2	+	+	No
10	15	Lobular, 2	+	+	No
11	14	Ductal, 3	–	–	No
12	10	Ductal, 2	+	+	No
13	16	Ductal, 1	+	+	No
14	25	Ductal, 2	+	–	Yes

ER, Oestrogen receptor; PR, progesterone receptor; +, positive; –, negative.

The first seven cases were premenopausal, and the last seven cases were postmenopausal.

as located at a luminal level, cells whose nuclei were aligned towards the periphery of ductules were defined as located at a basal level, and cells whose nuclei were located in between the luminal and basal nuclear 'rows' were defined as located at an intermediate level. Adjoining ductules that shared a ductular wall resulting in an eight-figure structure were defined as a ductular bifurcation.

IMMUNOHISTOCHEMISTRY AND IMMUNOHISTOFLUORESCENCE

Immunohistochemistry was performed for epitope detection of ALDH1A1 (ALDH1) in all specimens. In cancer patients, further investigations were made of ALDH1 and CD24 and/or CD44 (expression pattern proposed for SCs), of Ki67 (expressed by dividing/proliferating cells), of Cam5.2 and smooth muscle myosin heavy chain (SMMHC), and of oestrogen receptor (ER) α (induced expression). Cells expressing Cam5.2 or SMMHC represent the two differentiated ductular cell types. For details of the antibodies used, see Table 3. Single immunolabelling and various combinations of

double immunolabelling were performed in adjacent sections. Analyses were performed of both chromogenic and fluorescently immunolabelled epitopes to identify breast cell types and their histological relationships, and to elucidate cellular coexpression of antigens (or lack thereof).

Consecutive 3 μ m tissue sections were cut from tissue blocks, and mounted on glass slides (Super Frost Plus; Menzel, Braunschweig, Germany). Sections were dried at 37°C for 15–20 min prior to de-paraffinisation in xylene 2 \times 5 min; this was followed by rehydration in a series of decreasing ethanol concentrations, ending in distilled water. For antigen retrieval of tissue epitopes, sections were immersed in citrate buffer (0.01 M, pH 6.0) containing 0.05% Tween (Sigma Aldrich, St Louis, MO, USA), and were then heated in a microwave oven 2 \times 5 min, to 95°C. The sections were then allowed to cool to room temperature, whereupon they were immersed in distilled water.

For immunolabelling with chromogenic or fluorescence detection, sections were incubated in bovine serum albumin or in normal serum (goat and/or donkey, depending on the secondary antibody used; see

Table 3. Primary antibodies against different epitopes used for immunohistochemistry (IHC) and/or immunofluorescence (IF) in the studied breast tissues

Epitope	Host species	Application	Dilutions	Manufacturer
ALDH1 (amino acids 7–128, N-terminal)	Mouse IgG (mAb)	IHC/IF	1:100	BD Transduction Laboratories, Franklin Lakes, NJ, USA
ALDH1 (amino acids 488–501, C-terminal)	Goat (pAb)	IF	1:50	AbCam, Cambridge, UK
ALDH1 (C-terminal)	Rabbit (mAb)	IF	1:100	AbCam
Cam5.2	Mouse IgG (mAb)	IHC/IF	1:20	BD Transduction Laboratories
CD24 Ab2 (SN3b)	Mouse IgM (mAb)	IF	1:200	Thermo Scientific, Lab Vision (Neomarkers), Kalamazoo, MI, USA
CD44	Mouse IgG (mAb)	IF	1:500	Novocastra, Leica Microsystems, Heidelberg, Germany
CD45	Mouse (mAb)	IF	1:600	Dako, Glostrup, Denmark
ER α (1D5)	Mouse (mAb)	IF	1:35	Dako
Ki67 (MIB-1)	Mouse (mAb)	IHC	1:500	Dako
Ki67 (MIB-1)	Rabbit (mAb)	IF	1:100	Lab Vision (Neomarkers)
SMMHC (SMMS-1)	Mouse (mAb)	IHC/IF	1:100	Dako
SMMHC	Rabbit (pAb)	IF	1:500	Gift from Robert Adelstein, NIH, USA

ALDH1, Aldehyde dehydrogenase 1 (human); ER, oestrogen receptor; mAb, monoclonal antibody; pAb, polyclonal antibody; SMMHC, smooth muscle myosin heavy chain.

below) (Jackson ImmunoResearch, West Grove, PA, USA) for 10 min. These, and all other antibody incubations, were performed in moisture chambers at room temperature. Sections were then incubated with primary antibodies (Table 3) for 90–120 min, either with antibodies against one epitope (single chromogenic visualization), or with antibodies against two or more epitopes (fluorescence visualization). Incubations with two antibodies were performed simultaneously (as a mixture) or in sequence. All primary antibodies were diluted in phosphate-buffered saline (PBS) containing Triton X-100 (TX) (PBS-TX) at varying concentrations (Table 3). Sections were then rinsed 2 \times 5 min in PBS-TX prior to single labelling for chromogenic visualization or multiple labelling for fluorescence visualization.

For chromogenic visualization with peroxidase reactions, sections were placed in 0.5% H₂O₂ solution in methanol for 5 min at room temperature. The slides were then rinsed 2 \times 5 min in 0.1 M (pH 7.4) PBS containing 0.3% TX (Dow Chemical Company, Midland, MI, USA). Sections were processed for a horse-radish peroxidase (HRP)-based (non-biotin) labelling procedure designed for primary antibodies made in rabbit or mouse (Envision+ System-HRP [3,3'-diam-

inobenzidine (DAB)]; Dako, Glostrup, Denmark), with the protocol provided by the manufacturer. Sections were rinsed 2 \times 5 min in Tris (0.05 M, pH 7.4; Sigma Aldrich)-buffered saline (TBS; 0.15 M) containing 0.3% TX (TBS-TX). Sequential incubations were performed with secondary antibodies and HRP-conjugated antibodies (Envision+; Dako) for 30–40 min, with rinses 3 \times 5 min (in TBS-TX). Sections were then preincubated in a DAB-PBS-TX solution for 5 min, after which they were incubated for 10 min in a fresh DAB-PBS-TX solution containing 0.03% H₂O₂ (Sigma Aldrich). Sections were then rinsed twice in PBS-TX 2 \times 5 min, immersed in distilled water, dehydrated in increasing concentrations of ethanol, finishing with 2 \times 5 min in 100% xylene, and counterstained with Mayer's haematoxylin. The chromogenically labelled sections were coverslipped and mounted in Mountex medium (Histolab Products AB, Göteborg, Sweden).

Immunofluorescence techniques were used for simultaneous visualization of two or more epitopes, and of cell nuclei. Secondary antibodies were made in goat or donkey (from Invitrogen, Life Technologies, Carlsbad, CA, USA, and from Jackson ImmunoResearch) against rabbit, mouse or goat IgG (all

affinity-purified and species cross-reactivity tested), conjugated with fluorophores [Alexa Fluor 488 and 568 from Invitrogen, and fluorescein isothiocyanate (FITC) and Texas Red from Jackson ImmunoResearch] with clear separations between emission and excitation wavelength spectra. Sections were incubated separately in sequence or in a mixture of secondary antibodies (diluted 1:100 to 1:200) for 40 min, and this was followed by rinses (2×10 min) in PBS-TX. Nuclear staining was then performed by incubation of sections in 4',6-diamidino-2-phenylindole (DAPI) (0.05–0.1 μ M) or propidium iodide (0.05 μ M), both from Invitrogen. Sections were mounted and coverslipped in *p*-phenyldiamine glycerol.

The epitope specificity for the primary antibodies used has been well documented previously in scientific publications and by antibody manufacturers, and the cell-specific labelling pattern in our tested tissues corresponded to these descriptions and to histology. The epitope specificity for the antibodies made against ALDH1 in the tissues used was further demonstrated by the corresponding immunoreactive sites produced by two monoclonal antibodies (mouse or rabbit) and one polyclonal antibody (goat), against C-terminal and N-terminal regions of the epitope (Table 3), and by the correlation with the immunoreactive sites partly described previously.⁶

The specificity of the secondary antibodies used and the absence of cross-reactivity between them were ensured in every individual experiment, comprising adjacent sections in which the primary antibody incubation was omitted but the protocol was otherwise the same as in the adjacent sections. For the microscopy analyses, the adjacent control sections were used to determine the level of background signal caused by endogenous tissue autofluorescence or peroxidase activity and/or by non-specific antigen binding of the antibodies. This ensured detection of only specific signals exclusively from the immunoreactive sites (see below).

MICROSCOPY EQUIPMENT AND ANALYSIS

An Olympus AX 60 microscope was used for most of the analyses, equipped for both light and epifluorescence detection (Olympus Corporation, Tokyo, Japan) and with a digital colour camera (Olympus DP70). The background signal levels for each channel in control sections were used as the minimum detection levels, and images from each channel were grabbed separately, and overlaid onto single projections (Olympus DP70 software). For the immunofluorescence multiple labelling, appropriate filter sets were used for visualization of the separate wavelengths from fluorophores represented as blue (for

DAPI), green [for Alexa Fluor 488 and fluorescein (for FITC)], and red (for propidium iodide, Alexa Fluor 568, and Texas Red). The thin tissue sections (3 μ m) allowed cell-specific localization, including membrane, cytoplasmic or nuclear labelling and cellular colocalization of fluorescence signals, confirmed in a subset of cases by means of optical sectioning by confocal laser scanning microscopy [BioRad 1024; BioRad, Hemel Hempstead, UK (Zeiss, Oberkochen, Germany)].

Visual microscope-aided analyses were performed throughout all benign tissue areas available in microscopy slides from the selected tissue block from each patient. Areas containing morphologically benign breast epithelium with well-preserved histology were selected for analyses. A minimum of five benign-appearing TDLUs containing both lobules and stroma immediately surrounding lobules were analysed in every case, and were used for comparisons between the cases. At least 10 visual fields of about 0.30 mm² each in the total set of TDLUs (minimum of five) from each patient were assessed for the detailed cellular organization of immunolabelling. The quantities, rate and/or frequencies of cellular single labelling and/or co-labelling of different epitopes were evaluated within TDLUs, demonstrating the absolute cellular occurrence or relative cellular density and co-labelling between patients. Microscope-aided analyses were performed by an experienced clinical histopathologist (B.L.I.). The presented images have been corrected for labelling intensity and background (signal-to-noise ratio) by adjustment of brightness and contrast, with DP70 software.

STATISTICAL ANALYSIS

The concentrations of ALDH1+ cells at various levels of the ductular epithelium and in stroma were analysed by regression analysis with the independent variables age/menopausal status, parity, cancer/non-cancer patient, exogenous hormones [contraceptive pill or hormone replacement therapy (HRT), progestin intra-uterine device (IUD)], family history, using SPSS 18 (IBM, Armonk, NY, USA). All significance values were two-tailed, and a *P*-value <0.05 was considered to be significant.

Results

HISTOLOGICAL FINDINGS

Histopathological evaluation of selected tissues from haematoxylin and eosin-stained sections ensured that all specimens satisfied the set morphological requirement of at least five benign TDLUs without any atypia

or hyperplasia (Figure 1A). The average number of immunohistochemically examined TDLUs varied by specimen size, TDLU concentration, and technical quality, from eight to 100 (mean 42). For some of the immunohistochemical analyses, a tissue section from a case was not of adequate technical quality (noted in the text as less than a full set of samples).

DISTRIBUTION OF ALDH1-EXPRESSING CELLS

The three different antibodies against ALDH1 showed the same distribution of ALDH1+ cells with chromo-

genic and fluorescence visualization, localized in ductules and stroma (Figure 1B–D).

COMMON FEATURES IN BENIGN TISSUE FROM BOTH CLINICAL GROUPS (WITH OR WITHOUT CANCER)

The epithelial level at which most ALDH1+ cells occurred was luminal, with fewer cells occurring at an intermediate level, and very few cells at a basal level. ALDH1+ cells occupied the full thickness of ductules within rare TDLUs, in several of the premenopausal women of both clinical groups as well as in a

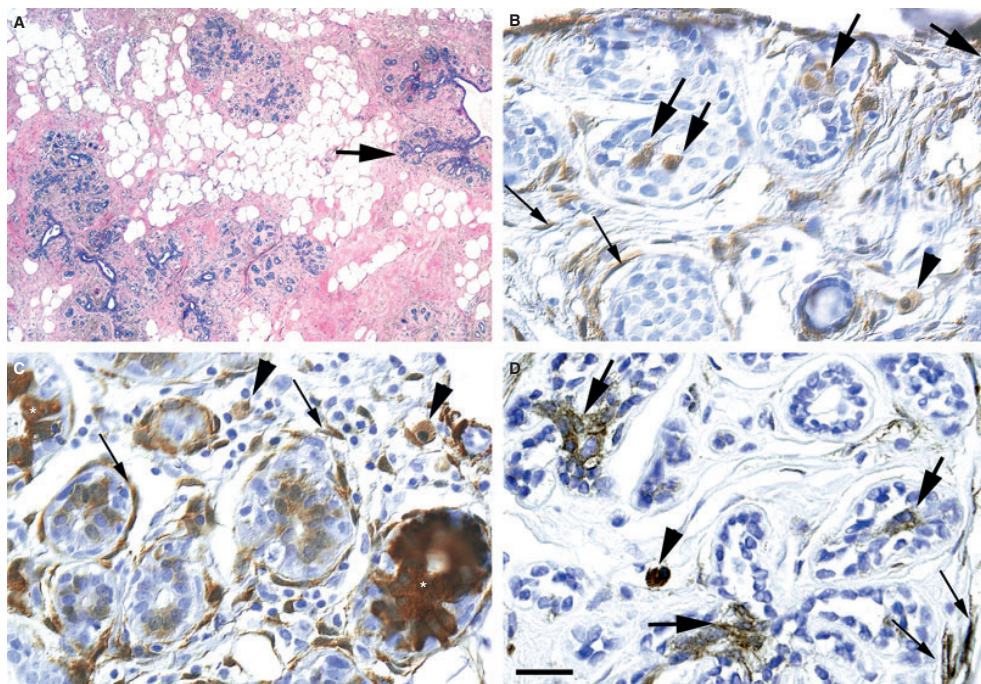


Figure 1. Benign breast tissue and distribution of aldehyde dehydrogenase 1-immunoreactive (ALDH1+) cells. A, Tissue paraffin section stained with haematoxylin and eosin. The image is an overview of a representative tissue area with no atypia or hyperplasia, as used for analyses in this study. The area contains several terminal ductal-lobular units (TDLUs). Each cluster of terminal ductules (lobule) is immediately surrounded by specialized stroma, these components together composing a TDLU (one example is indicated with an arrow). TDLUs are separated by intervening non-specialized stroma with varying fat content. The tissue is from a 28-year-old woman with cancer in the same breast. B–D, Tissue demonstrating ALDH1 immunoreactivity (brownish) in women without (B,C) and with (D) cancer. Sections are counterstained with haematoxylin. Arrows and arrowheads indicate the three main types of detected ALDH1+ cells, each with a distinct morphology and location. Large arrows indicate intraepithelial cells, sometimes located at bifurcations and focally bridging the lumen (large arrows in B and D). Thin arrows indicate stromal, thin, spindle-shaped cells with small or non-visible nuclei, sometimes surrounding ductules. Arrowheads indicate the stromal, round/oval ALDH1+ cells. Asterisks (in C) denote confluent immunoreactive ductal cells at the luminal and intermediate levels, focally extending to the basal level. B,C, Tissue from women without cancer: a 36-year-old premenopausal woman and a 48-year-old postmenopausal woman. D, Tissue from a cancer patient with cancer in the same breast: 28-year-old premenopausal woman. Scale bar in (C) represents 50 μ m in (B) and (C).

relatively young (age 48 years) postmenopausal woman. ALDH1+ cells were noted bridging ductular bifurcations (i.e. forming the carina of an 8-shaped structure) (Figure 1B,D) in seven of the youngest women, irrespective of clinical group, aged 20–36 years. ALDH1+ cells also occurred in breast stroma, inside and outside of the TDLU perimeter, in all examined women. The average density of stromal ALDH1+ cells was very similar between the two age groups, and between the two clinical groups. Two distinct ALDH1+ cell types were present in the TDLU stroma (Figure 1B–D). The most common type, which was widely distributed in the TDLU stroma in all cases, was an ALDH1+ elongated, spindle-shaped cell, usually with a small nucleus, morphologically corresponding to a fibrocyte or, in some areas, a fibroblast. These cells were difficult to quantify exactly, owing to their often extremely slender phenotype. The less common stromal ALDH1+ cell type was round or oval with a relatively large nucleus. The relative numbers of the round/oval cells were similar in the premenopausal (mean of eight cells per mm²) and postmenopausal (mean of six cells per mm²) groups. The concentration of round/oval ALDH1+ stromal cells appeared to fall with increasing age, with one exception: a postmenopausal woman aged 66 years showed a relatively high number of round/oval stromal ALDH1+ cells (11 cells per mm²). She was receiving transcutaneous oestrogen treatment.

ALDH1+ CELLS AND RISK FACTORS FOR BREAST CANCER

ALDH1+ cells were detected in the ductules of most (21 of 27 examined) women throughout the age range (Table 1), occurring in an average of 14% of TDLUs. However, postmenopausal women had a lower fraction of TDLUs containing ALDH1+ cells at luminal and intermediate levels of ductules than premenopausal women ($P = 0.06$ and $P = 0.02$, respectively). Within the postmenopausal groups, four exceptions were noted, in that the fraction of TDLUs containing ductular ALDH1+ cells was unusually high, and similar to that of the premenopausal group. Three of these women were the only women in the study population who were receiving HRT with progestin. When hormonal exposures were combined (oral contraceptives, HRT, and IUD), the concentration of ALDH1+ cells was again significantly higher at luminal and intermediate levels in hormonally exposed than in non-exposed women ($P = 0.03$ and $P = 0.04$, respectively), after adjusting for menopause and cancer/non-cancer patient. Similarly, the percentage of TDLUs that contained ALDH1+ cells was significantly higher at

luminal levels (12%) and intermediate levels (8%) in women without cancer undergoing mammoplasty, than in cancer patients (5% and 2%) ($P = 0.006$ and $P = 0.003$, respectively). No association was seen between family history or parity and luminal or intermediate ALDH1+ cells. For basal or stromal ALDH1+ cell concentrations, no significant associations were found with regard to age/menopause, hormone exposures, type of patient, or family history. The stromal ALDH1+ cell concentration showed a weak positive association with women having four or more pregnancies ($P = 0.05$).

MORE DETAILED ANALYSIS OF TISSUE FROM PATIENTS WITH BREAST CANCER

In the benign ductules of patients with cancer, ALDH1+ cells were detected in six of seven specimens from premenopausal women and in three of six specimens from postmenopausal women. The ALDH1+ cells had a relatively plump morphology, and occurred preferentially in groups within the epithelial cell mass, especially at ductular bifurcations (Figure 1D). ALDH1+ cells were, however, present at all ductular epithelial levels (Table 1), with the majority located at luminal levels (present in ~4% of all TDLUs), relatively few at intermediate levels (present in ~2% of all TDLUs), and few at basal levels (present in ~1% of all TDLUs). In premenopausal women, a relatively large number of TDLUs contained ALDH1+ cells (present in ~7% of all TDLUs) compared with those of postmenopausal women (present in ~2% of all TDLUs). Within the postmenopausal group, two exceptions were noted: one HRT-treated woman aged 61 years and one progestin IUD-treated woman aged 50 years had higher frequencies of ALDH1+ cells in the ductular epithelium (present in ~8% and ~4% of TDLUs, respectively) than the other postmenopausal women.

In the TDLU stroma, scattered ALDH1+ cells were detected in all investigated patients ($n = 13$) (Table 1).

ALDH1+ cells and cell proliferation

Immunofluorescent labelling for ALDH1 (Figure 2A–D) showed the occurrence of the same cell types in ductules and stroma as shown by chromogenic labelling. Cell proliferation (Ki67+ cells) was present only in some TDLUs, being sparsely distributed (Figure 2D) or occurring at high densities in some ductules (Figures 3B and 4A), whereas the majority of TDLUs lacked proliferation activity altogether. ALDH1+ cells and Ki67+ cells did not coincide in the same ductules, and nor did cells coexpress ALDH1 and Ki67 (Figure 3B).

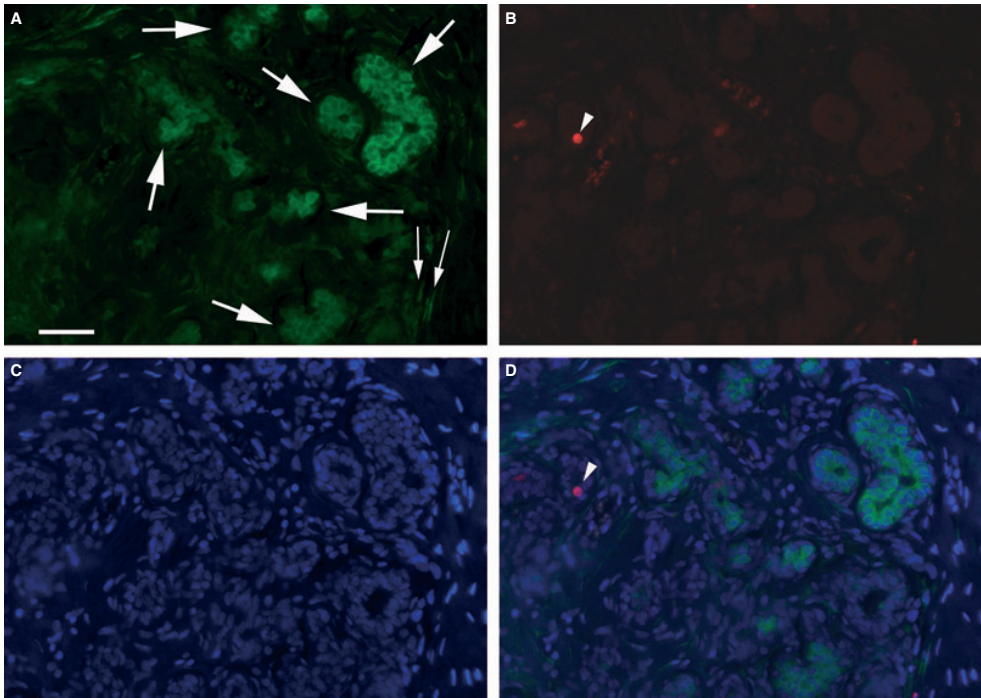


Figure 2. Aldehyde dehydrogenase 1 (ALDH1) immunofluorescence in benign tissue of cancer patients. A–D. A tissue section that has been immunofluorescently double labelled for ALDH1 (green in A) and Ki67 (red in D), and has been counterstained with 4',6-diamidino-2-phenylindole (blue nuclei in C). The visualized labelling is combined as a single projection in (D), as used for the analysis of double immunolabelling. The same ALDH1 cell types are detected as with ALDH1 immunohistochemistry (see Figure 1), i.e. the epithelially located ALDH1 cells (large arrows in A) and the stromal, thin, spindle-shaped cells (thin arrows in A). Few proliferating cells (Ki67+) are present in most TDLUs, as in the demonstrated case (arrowheads in B and D). This complete separation of ALDH1+ and Ki67+ cells was observed in all cases (see also Figures 3B and 4A,B).

In premenopausal women, Ki67+ cells in the ductular epithelium were mainly organized in cell groups. The same organization of Ki67+ cell groups was present in postmenopausal women, although with approximately one-half of the number of positive cells per TDLU compared to that of premenopausal women. One major exception was noted within the postmenopausal group: a woman with a relatively high number of Ki67+ cells per TDLU, comparable with the numbers present in the premenopausal group. This woman had a family history of breast cancer, and was not receiving hormonal treatment. The ductular epithelium in the youngest premenopausal women contained particularly dense Ki67+ cell populations at luminal and intermediate levels (Figure 4A).

In premenopausal women, the highest number of Ki67+ cells were located at the luminal level, somewhat fewer at the intermediate level, and few at the basal level. A similar distribution of Ki67+ was present in postmenopausal women, with the exception that very few Ki67+ cells were located at the intermediate level (possibly reflecting the lower number of intermediately located cells in postmenopausal women). In some premenopausal women, Ki67+ cells completely bridged the lumen at ductular bifurcations (Figure 4B).

No Ki67+ cells were detected within the stroma in any of the cases.

ALDH1+ cells and cell differentiation

In the majority of patients, ALDH1+ cells were not co-immunoreactive either with SMMHC or with Cam5.2.

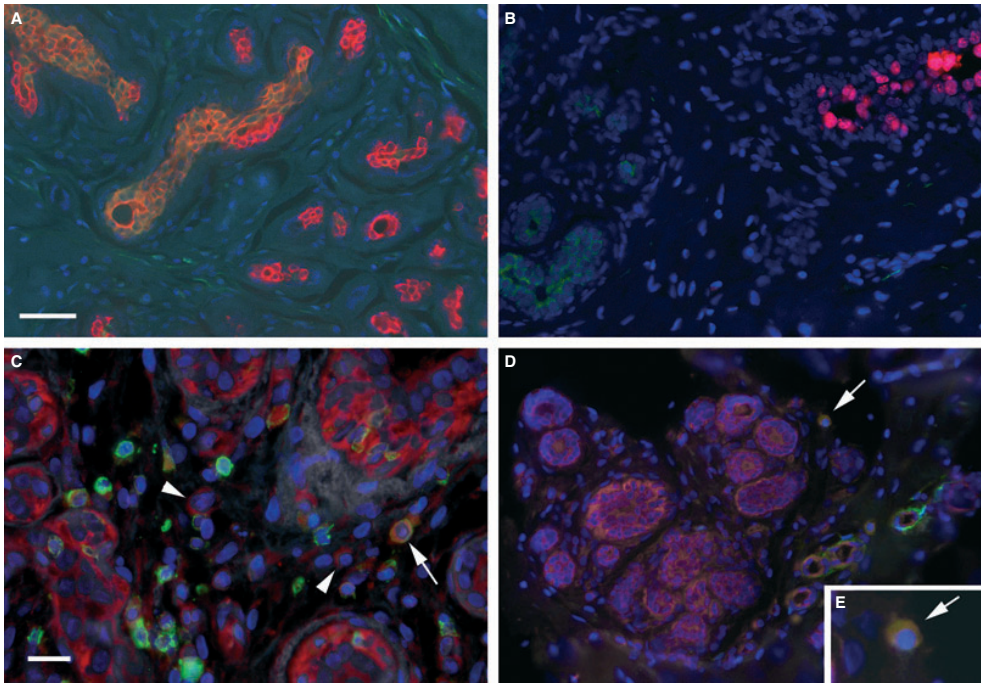


Figure 3. Aldehyde dehydrogenase 1-immunoreactive (ALDH1+) cells, and their relationship to Cam5.2-expressing, Ki67-expressing, CD45-expressing and smooth muscle myosin heavy chain (SMMHC)-expressing cells in tissues from cancer patients. A, A breast tissue section immunofluorescently double labelled for ALDH1 (green cytoplasm) and Cam5.2 (red cytoplasm), and counterstained with 4',6-diamidino-2-phenylindole (DAPI) (blue nuclei). In the terminal ductal-lobular units (TDLUs) on the left side, there is almost complete cellular co-labelling of ALDH1 and Cam5.2 (appearing orange), whereas cells in TDLUs on the (lower) right are only Cam5.2+ (pure red). The tissue is from a 38-year-old woman with breast cancer. Scale bar in (A) represents 50 µm in (A), (B), and (D). B, A breast tissue section immunofluorescently double labelled for ALDH1 (green cytoplasm) and Ki67 (red nuclei), and counterstained with DAPI (blue nuclei). The image demonstrates the clear separation between a TDLU containing ALDH1+ cells and a TDLU containing Ki67+ cells. Note: No ALDH1+ cells with Ki67 were detected in any case. C, A TDLU stromal area with high numbers of round/oval cells, suggestive of chronic inflammation, containing SMMHC+ (red cytoplasm) and CD45+ (green cytoplasm) cells, and all cell nuclei (DAPI, blue nuclei). Cells peripherally located in ducts that have a pure red cytoplasm (SMMHC+ and CD45-) represent myoepithelial cells. Note the single SMMHC+ cells (arrowheads), different from the stromal and epithelial CD45+/SMMHC- cells (green), which are leukocytes with a morphology consistent with lymphocytes. A double-labelled CD45+ and SMMHC+ cell (arrow) may represent a macrophage. The tissue is from a 54-year-old woman. Scale bar represents 20 µm. D, A TDLU immunofluorescently double labelled for SMMHC (red cytoplasm) and ALDH1 (green cytoplasm), counterstained with DAPI (blue nuclei). The arrow points at a single, stromal SMMHC+ and ALDH1+ co-labelled cell, located in the TDLU periphery. The tissue is from a 36-year-old woman. E, The insert, magnified from (D), (see arrow), shows a double-labelled ALDH1+ and SMMHC+ stromal cell, typical of those detected in two premenopausal women. The cell type corresponds to the solely ALDH1+, round/oval cell type identified in all examined patients (see Figure 1B,C).

Like ALDH1+ cells, the majority of Cam5.2+ cells were located at luminal or intermediate ductular levels of the epithelium (Figure 5A,B). Cells with co-immunoreactivity for ALDH1 and Cam5.2 were present only in the two youngest patients (aged 28 and 31 years). In these, co-labelled (ALDH1+ and Cam5.2+) cells comprised most of the ductular cell population of some TDLUs (Figure 3A).

In all women, the majority of basally located cells were SMMHC+, with a strongly SMMHC-immunoreactive cytoplasmic rim that encircled ductular cross-sections (Figure 5A–B,D). Some luminally and intermediately positioned ductular cells with no Cam5.2 immunoreactivity exhibited either weak or focal SMMHC immunoreactivity (Figure 5B), corresponding to ALDH1+ cell populations at these same ductular

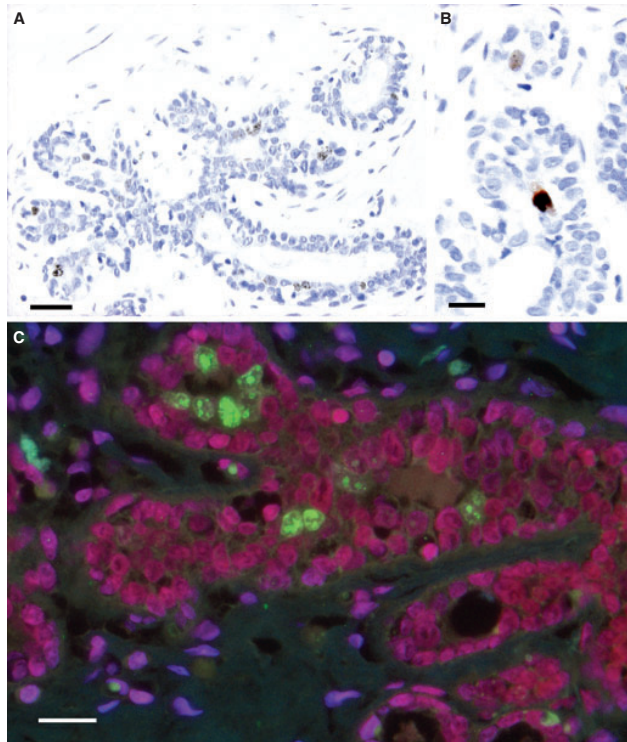


Figure 4. Location of proliferating cells and oestrogen receptor (ER) α + cells in benign breast tissue from cancer patients. A, A terminal ductal-lobular unit (TDLU) from a 31-year-old premenopausal patient, showing an unusually high number of Ki67+ cell nuclei (brown), located at luminal or intermediate levels. Note that no stromal cells are Ki67+, which is representative of all cases studied. Scale bar represents 50 μ m. B, Strongly labelled Ki67+ cells that form a bridge at a ductular bifurcation (brown nuclei). The similar cell bridging at ductular bifurcations was detected for aldehyde dehydrogenase 1-immunoreactive (ALDH1+) cells (see Figure 1B,D), suggesting that these bifurcations are actively growing. This tissue is from a 31-year-old patient. Scale bar represents 20 μ m. C, A tissue section from a TDLU area immunofluorescently double labelled for Ki67 (green nuclei) and ER α (red nuclei), and counterstained with 4',6-diamidino-2-phenylindole (blue nuclei). In general, ER α expression is variable. It is relatively high in ductular cell nuclei lacking Ki67 immunoreactivity (red–purple), whereas it is relatively low or undetectable in cells with strongly labelled Ki67+ nuclei (green nuclei). Note also weakly ER α -expressing stromal cells (blue–purple nuclei). The specimen is from a 39-year-old woman, representative of all examined cases. Scale bar represents 20 μ m.

levels (Figures 1 and 2). These cells occurred in greater numbers in premenopausal women. This cell type was not defined as myoepithelial, owing to its non-basal location. In our experiments, neither these cells nor myoepithelial cells co-expressed ALDH1 and SMMHC in any of the examined cases.

Relatively few patients (4/14) displayed Cam5.2+ ductular cells that were also Ki67+. These cells were located at luminal or intermediate levels only, and occurred in both premenopausal and postmenopausal women (Figure 5C). In only one case (tissue from a 38-

year-old woman) was there an occurrence of extremely rare SMMHC+ ductular cells that were also Ki67+. These cells were exclusively located at luminal or intermediate levels, and were thus not identified as myoepithelial cells. Specimens from other cases showed no SMMHC+/Ki67+ cells (Figure 5D).

Oestrogen receptor- α nuclear immunoreactivity, at varying intensities, was detected in almost all ductular cells in all cases, except for Ki67+ cells, which had very low or no detectable ER α immunoreactivity (Figure 4C).

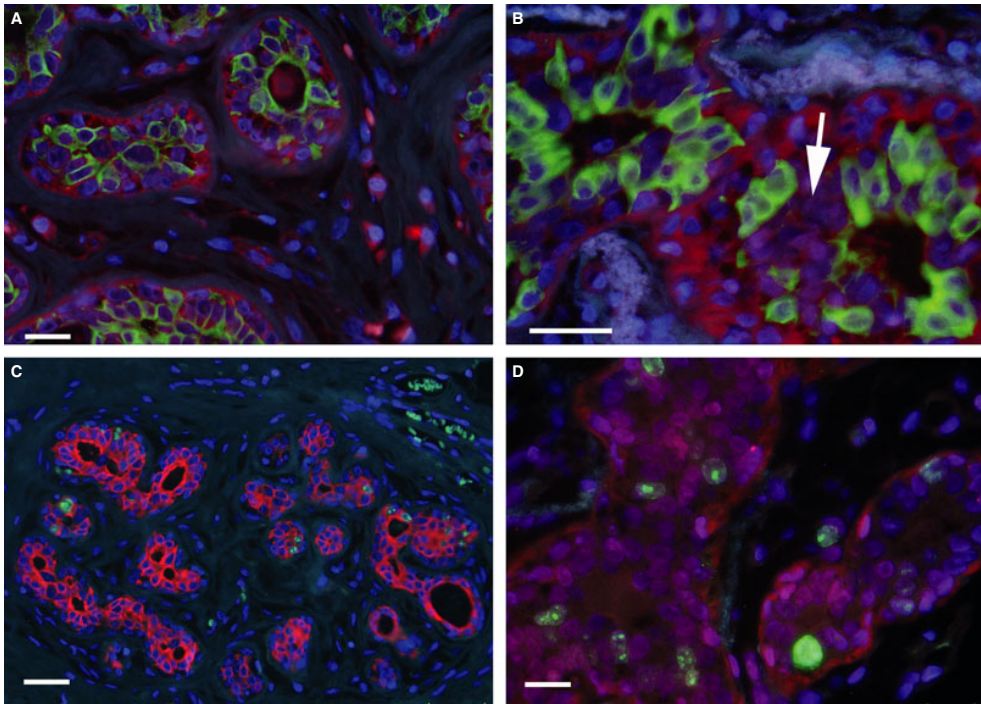


Figure 5. Aldehyde dehydrogenase 1-immunoreactive (ALDH1+) cells in relation to Cam5.2+ and smooth muscle myosin heavy chain-immunoreactive (SMMHC+) differentiated cells and cell proliferation in benign breast tissue from patients with cancer. **A,B.** The distribution of Cam5.2+ (green cytoplasm) and SMMHC+ (red cytoplasm) cells [counterstained with 4',6-diamidino-2-phenylindole (DAPI), blue nuclei]. Like the ALDH1+ cells, Cam 5.2+ cells are mostly located at luminal or intermediate levels of the epithelium, i.e. not in the myoepithelial cell (basal) position, representative of all cases. Note also in (A) the strongly SMMHC+ stromal cells, detected in all cases (see also Figure 3C). Note in (B) the population lacking Cam5.2 and with weak or focal SMMHC labelling (arrow), which may correspond to the ALDH1+ cell populations identified in this position (see Figures 1 and 2). (A) is from a 38-year-old woman, and (B) is from a 54-year-old woman, representative of all cases. Scale bars in (A) and (B) represent 20 μ m. **C.** A terminal ductal-lobular unit (TDLU) area double labelled for Cam5.2 (red cytoplasm) and Ki67 (granular green nuclei). The section was counterstained with DAPI (blue nuclei). All epithelial Ki67+ cells appear to possess Cam5.2+ cytoplasm, indicating differentiation into glandular cell characteristics of newly divided cells. The tissue is from a 31-year-old woman, with the above noted features being representative of both premenopausal and postmenopausal cases. Erythrocytes display autofluorescence (green), confined to blood vessels (in the upper right corner). Scale bar represents 20 μ m. **D.** A tissue section double labelled for Ki67 (green granular nuclei) and SMMHC (red cytoplasm). The image shows, in a TDLU, that the peripherally located SMMHC+ ductular cells are not Ki67+. The tissue is from a 31-year-old woman, with the noted features being representative of all cases. Scale bar represents 20 μ m.

ALDH1+ cells in stroma

In all cases examined for ALDH1 ($n = 13$), the TDLU stroma contained numerous and widely distributed, narrow, spindle-shaped cells with ALDH1 immunoreactivity. These cells had a fibrocyte-like appearance, and were completely non-reactive for SMMHC. Also in the TDLU stroma, there were single, scattered SMMHC+ cells with a round or oval shape in all cases examined ($n = 13$) (Figure 3C). Similarly, round/oval

TDLU stromal cells showed ALDH1 reactivity in all cases examined ($n = 13$) (Table 1). A fraction of the round/oval TDLU stromal cells co-expressed SMMHC and ALDH1, as detected in two of the patients (Figure 3D–E). In the specimen that contained the highest density of round/oval SMMHC+ stromal cells in the TDLU stroma, approximately one-half were CD45+, indicating leukocytes, but the remaining were CD45– (Figure 3C). Round/oval TDLU stromal cells

showed some ER α immunoreactivity, but with a much weaker labelling intensity than ductular cells (Figure 4C). In TDLU stroma, no cells were Ki67+ or Cam5.2+.

To further investigate the character of SMMHC+ stromal cells, we examined their possible CD24 and/or CD44 expression. Round/oval SMMHC+/CD44+ stromal cells were detected in all cases ($n = 13$), with no indication of age-related differences. All stromal SMMHC+ cells were CD24-, with the exception of a minor subpopulation of round/oval SMMHC+/CD24+ cells in the youngest woman (with *BRCA1* abnormality). Spindle-shaped stromal cells of the ALDH1+ type were neither CD44+ nor CD24+.

Discussion

It was recently found by Ginestier *et al.*,⁶ via immunolabelling by flow cytometry and immunohistochemistry, that ALDH1+ (isoform A1) cells in breast ductules possess SC characteristics in both benign and malignant tissue. It was suggested that ALDH1 expression can be used as a single marker of benign breast SCs, with the potential to also act as an important predictor of cancer development.^{6,7} The present immunohistochemical study confirms that ALDH1+ ductular cells in benign breast tissue have several SC characteristics, i.e. signifying non-dividing and mainly non-differentiated cells, together supporting their SC character. Our study also supports indications that ductular ALDH1+ cells constitute a subpopulation of SCs as defined by CD44+/CD24- immunophenotype. The ALDH1+ population constituted a smaller fraction of ductular cells than ductular CD44+/CD24- populations, in keeping with previous proposals.⁶

Our study focused on morphologically benign breast tissue of women with breast cancer. A concern can be raised that morphologically normal breast tissue from cancer specimens may be genetically altered, and may thus not be representative of truly benign tissue.²³ We therefore compared findings from this material with those from women without cancer. The results showed that the occurrence and distribution of ALDH1+ cells in the basal part of the epithelium and stroma of these clinical groups are comparable, with no obvious differences. However, at the luminal and intermediate levels, the specimens from women without cancer (mastectomy) had a higher concentration of ALDH1+ cells. This might imply that such women may have an expansion of the SC population, leading to an increased breast volume, which is the underlying reason for their operation. Alternatively, ALDH1+ cells may be suppressed in the cancer patients outside the

cancer area. However, this is not known from the literature. There is a need to study this further by comparing specimens from women undergoing mastectomy with other control group, e.g. traffic accident autopsy cases, or women with benign breast tumours.

We show here that the ALDH1+ SCs are distributed in both ductules and stroma of morphologically normal female breast tissue, and that they are present throughout non-lactating adult life. Furthermore, our data indicate that some ALDH1+ SCs may differentiate into ductular epithelial cells. ALDH1+ cells at luminal/intermediate ductular levels and, to a lesser degree, stromal levels were generally more numerous in premenopausal women than in postmenopausal women, with some exceptions among postmenopausal women receiving hormonal treatment (see discussion below).

METHODOLOGICAL CONSIDERATIONS

We used immunohistochemistry to detect the detailed distribution of ALDH+ cells in formalin-fixed, paraffin-embedded, histomorphologically defined benign tissue in cancer and non-cancer (mastectomy) patients. Three different antibodies against ALDH1, all against the ALDH1A1 subtype, and two visualization techniques (chromogenic and fluorescence) provided the same results regarding ALDH1 cellular labelling and distribution. The results correspond to a previous study of benign breast tissue⁶ and cancer tissue utilizing immunohistochemistry against the ALDH1 epitope, subtype ALDH1A1 (this choice is discussed in the Introduction). The cell types and cellular distribution of immunolabelled Ki67,²⁴ Cam5.2,²⁵ SMMHC,²⁶ ER α ²⁷ and CD44/CD24⁵ also corresponded to that described previously in breast tissue. Cam5.2 (a monoclonal antibody including a component against cytokeratin 8 that is a low molecular weight simple keratin) was selected because of its specificity for glandularly differentiated epithelial cells.^{28–30} SMMHC was chosen on the basis of its specificity for terminally differentiated smooth muscle cells, including myoepithelial cells, and for its rare expression in myofibroblasts.³¹ For multiple fluorescence labelling, the use of secondary antibodies with well-separated excitation, and emission spectra optimized for the microscope used, provided total separation in the registered fluorescent wavelengths, thus excluding the risk of false co-registration of signals at cellular levels. In addition, tests with confocal microscope analyses showed that the use of a thin section (3 μ m) and nuclear markers provided true intracellular detection of fluorescence.

Thus, it is concluded that the immunolabelling techniques and subsequent analyses provided reliable investigative tools for the study.

ALDH1+ CELL DISTRIBUTION

Ductular ALDH1+ cells were more frequent in premenopausal than in postmenopausal women. This is congruent with the fact that the ductular epithelium is very actively maintained in premenopausal women, whereas it involutes after menopause. In mastoplastic patients, ALDH1+ cells at luminal and intermediate levels of the epithelium were found in a significantly higher percentage of TDLUs than in cancer patients. This may suggest that the relative presence of ductular ALDH1+ cells is related to the development of cancer, and this needs to be studied further in larger populations of age-matched cancer and non-cancer patients. In the majority of cases ($n = 20$), ALDH1+ SCs were present within the ductular epithelial mass, mainly located at luminal and intermediate levels, with very few ALDH1+ SCs being found at basal levels. Some luminally positioned ALDH1+ SCs bridged luminal bifurcations; these were detected only in women between the ages of 20 and 36 years, cellular location corresponding to what was found in a previous study.⁶ These findings indicate that new cells can be added to different levels of the ductules, either for neogrowth of ductules or lactational acini, or for replenishment of injured cells. The primarily non-basal and, in fact, mostly luminal position of ALDH1+ SCs is congruent with the location of ALDH1+ cells coexpressing Cam5.2, consistent with these cells being progenitors of mature glandular differentiation. However, this distribution of SCs does not conform with earlier theories indicating that mammary SCs are located basally.^{10,11,16}

Stromal ALDH1+ cells were detected in all cases. As these cells were relatively frequent in postmenopausal women, who generally have a relatively well-maintained stroma, this could indicate retained formation of new, differentiated stromal cells from ALDH1+ stromal SCs throughout life. However, more studies on ALDH1+ cells in stroma are required before conclusions can be drawn regarding this. It should be pointed out that reports about human stromal SCs in benign TDLUs are limited,^{13,14,32} and the *in-situ* organization and morphology of putative stromal SCs in the breast have not been described previously.

DUCTULAR ALDH1+ SCs IN RELATION TO PROLIFERATION AND DIFFERENTIATION

In ductules, ALDH1+ SCs and proliferating ductular cells were found both scattered and in confluent

groups. No ALDH1+ cells were Ki67+. Although they were always located in separate ductules, the highest densities of Ki67+ cells and ALDH1+ cells were located at the luminal level. This suggests that the individual ductule at any given time can be either in an SC state, in a proliferating state, or in a quiescent and mature state (non-ALDH1+ and non-proliferative).

It has been reported that ALDH1+ SCs can form entire ductules in morphologically benign breast tissue of women with germline *BRCA1* mutations.³³ However, similar to what was reported by Heerma van Voss *et al.*,¹³ our study shows populations of ALDH1+ ductular cells in patients with no *BRCA1* diagnosis or family history, suggesting that the phenomenon might not be attributable to a genetic predisposition to breast cancer.

Among ALDH1+ SCs, we found no evidence of myoepithelial differentiation (basally located cells with SMMHC expression), corresponding with the suggestion of Ginestier *et al.*⁶ Also, basally located, strongly labelled SMMHC+ cells, i.e. myoepithelial cells, never expressed Ki67. This corresponds to the results of a study where basally located smooth muscle actin-reactive cells in benign breast tissue only sporadically expressed Ki67,³⁴ and is in line with the fact that myoepithelial cancers are exceptionally rare.³⁵

STROMAL ALDH1+ SCs IN RELATION TO PROLIFERATION AND DIFFERENTIATION

For the first time, the present study describes two morphologically distinct stromal ALDH1+ cell types.

The most numerous and widely distributed stromal cell type, present in both premenopausal and postmenopausal women, is a spindle-shaped, fibrocyte-like cell with slender cytoplasm and a small, elongated nucleus. This cell type is ALDH1+, but Cam5.2-, SMMHC-, CD44-, and CD24-. Thus, it does not meet the CD44+ criterion previously set for SCs in the breast,⁵ although it has the ALDH1+ quality more recently set for breast SCs.⁶

The other ALDH1+ stromal cell type was found in low to moderate numbers in TDLUs of all examined women. It has a round or oval shape, with a relatively large nucleus. This cell type is a CD45-, i.e. non-leukocyte, subset of SMMHC+ round/oval stromal cells found in all of the examined patients. The CD44+/CD24- status of individual, round/oval stromal cells and the relative lack of differentiation (Cam5.2-, ER α^{low} i.e. $\text{In}^{-/\text{low}}$) is concordant with an SC character, supporting the SC nature of these cells.⁵ The true identity of the two stromal ALDH1+ cell types (spindle-shaped and round/oval), whether SCs or other, is unclear and needs to be elucidated in a larger specimen set.

Individual, stromal SMMHC+/Cam5.2- cells in benign and malignant breast tissue have previously been described and characterized as myofibroblasts,³⁶ although myofibroblasts are considered to be somewhat poorly reactive to SMMHC.³⁷ At least some of the TDLU stromal cells previously identified as myofibroblasts may be the cells that we identified as SMMHC+/ALDH1+ cells (the immunophenotype of which suggests contractile or migrating stromal cells). The true identity of the two stromal ALDH1+ cell types (spindle-shaped and round/oval) is unclear and needs to be further investigated.

ALDH1+ CELLS, HORMONAL REGULATION, AND AGE DIFFERENCES

Although they had similar ductular level distributions, there were clear differences in the presence and number of ALDH1+ cells and dividing (Ki67+) cells between the cases studied, in an apparently age-related and hormonally-influenced (both endogenous and exogenous) pattern. This supports the involvement of ALDH1+ SCs in the formation of new cells and in cell replenishment. ALDH1+ cells and dividing cells were present in the ductular epithelium of the majority (6/7) of premenopausal cancer patients. In contrast, only one-half (3/6) of postmenopausal cancer patients had ductular ALDH1+ SCs, and the number of dividing cells in the ductular epithelium was clearly decreased, probably reflecting involution of TDLUs.

A possible exogenous hormone influence on the presence of ALDH1+ SCs was indicated by three exceptional cases in the present series: three of the four postmenopausal patients in the total patient set showing relatively high densities of ALDH1+ cells in ductules were those receiving progestin medications (IUD and HRT). Also, a postmenopausal patient using an oestrogen-only medication had a much higher density of ALDH1+ SCs in the stroma than other postmenopausal women. Other studies have shown that ALDH1+ SCs do not contain ER α .^{38,39} In comparison, in the present study, the vast majority of cells in both ductules and TDLU stroma had some degree of ER α positivity. In addition to possible variations in expression rates, this difference may be attributable to differences in the labelling protocols, in detection sensitivity, and/or in preservation of epitopes. In addition to an ER α -mediated influence, progesterone and/or ER β receptor-mediated hormone mechanisms may influence SC density and function.

Although our study was limited in the number of cases, it can be concluded that the presence and concentration of ALDH1+ cells in morphologically

benign tissue in women with breast cancer did not show any relation to the characteristics of the tumours that these patients had, i.e. histological type, grade, or hormonal receptor status. It should also be noted that the vast majority of breast cancers are of epithelial cell origin, and extremely few cancers are myoepithelial.³⁵ In concordance with this, we found that Cam5.2+ epithelial cells, ALDH1+ SCs and Ki67+ cells were present at the highest concentrations at non-basal ductular levels, whereas no myoepithelial cells are ALDH1+ or Ki67+. The presence of cells co-expressing Cam5.2 and Ki67 in the ductular epithelium of four cases (premenopausal and postmenopausal), together with the absence of SMMHC+/Ki67+ cells, is consistent with the glandular differentiation of the majority of breast malignancies. This and the ductular location of ALDH1+ cells at non-basal levels may suggest a role in breast cancer development.

Conclusions

Our study demonstrates ALDH1+ cells in benign ductular epithelium, at predominantly non-basal levels, and stroma. Their concentration varies with age and hormonal exposure, and appears to be higher in women without cancer undergoing mastoplasty than in cancer patients. Two types of ALDH1+ cell in stroma are described that need to be investigated further for possible SC properties.

Acknowledgements

We thank Dr. Robert Adelstein (National Institute of Health, USA) for the gift of SMMHC antibody from rabbit host, Anna Ebbesson for laboratory assistance, and ImaGene-iT for technical and scientific research support. Funding for this research was provided by Swedish Research Council, Swedish Cancer Society, and regional funds of Region Skåne and Lund University Hospital, Sweden.

References

- Clarke MF, Dick JE, Dirks PB *et al.* Cancer stem cells—perspectives on current status and future directions: AACR workshop on cancer stem cells. *Cancer Res.* 2006; **66**: 9339–9344.
- Schackleton M, Vaillant F, Simpson KJ *et al.* Generation of a functional mammary gland from a single stem cell. *Nature* 2006; **439**: 84–88.
- Costello RT, Mallet F, Gaugler B *et al.* Human acute myeloid leukemia CD34+/CD38- progenitor cells have decreased sensitivity to chemotherapy and Fas-induced apoptosis, reduced immunogenicity, and impaired dendritic cell transformation capacities. *Cancer Res.* 2000; **60**: 4404–4411.

4. Alvi AJ, Clayton H, Joshi C *et al.* Functional and molecular characterisation of mammary side population cells. *Breast Cancer Res.* 2003; **5**: R1–R8.
5. Al-Hajj M, Wicha MS, Benito-Hernandez A, Morrison SJ, Clarke MF. Prospective identification of tumorigenic breast cancer cells. *Proc. Natl Acad. Sci. USA* 2003; **100**: 3983–3988.
6. Ginestier C, Hur MH, Charafe-Jauffret E *et al.* ALDH1 is a marker of normal and malignant human mammary stem cells and a predictor of poor clinical outcome. *Cell Stem Cell* 2007; **1**: 555–567.
7. Park SY, Hee EL, Hailun L, Shipitsin M, Gelman R, Polyak K. Heterogeneity for stem cell-related markers according to tumor subtype and histologic stage in breast cancer. *Clin. Cancer Res.* 2010; **16**: 876–887.
8. Mercatò P, Dean CA, Pan D *et al.* Aldehyde dehydrogenase activity of breast cancer stem cells is primarily due to isoform ALDH1A3 and its expression is predictive of metastasis. *Stem Cells* 2011; **29**: 32–45.
9. Briskin C, Duss S. Stem cells and the stem cell niche in the breast: an integrated hormonal and developmental perspective. *Stem Cell Rev.* 2007; **3**: 147–156.
10. Stingl J. Detection and analysis of mammary gland stem cells. *J. Pathol.* 2009; **217**: 229–241.
11. Chepko G, Slack R, Carbott D, Khan S, Steadman L, Dickson RB. Differential alteration of stem and other cell populations in ducts and lobules of TGF α and c-Myc transgenic mouse mammary epithelium. *Tissue Cell* 2005; **37**: 393–412.
12. Retsekova E, Reis-Filho JS, Jain RK *et al.* Prognostic impact of ALDH1 in breast cancer: a story of stem cells and tumor microenvironment. *Breast Cancer Res. Treat.* 2010; **123**: 97–108.
13. Heerma van Voss MR, van der Groep P, Bart J, van der Wall E, van Diest PJ. Expression of the stem cell marker ALDH1 in the normal breast of BRCA1 mutation carriers. *Breast Cancer Res. Treat.* 2010; **123**: 611–612.
14. Heerma van Voss MR, van der Groep P, Bart J, van der Wall E, van Diest PJ. Expression of the stem cell marker ALDH1 in BRCA1 related breast cancer. *Cell Oncol. (Dordr.)* 2011; **34**: 3–10.
15. Dao TL. Mammary cancer induction by 7,12-dimethylbenz(a)anthracene: relation to age. *Science* 1969; **165**: 810–811.
16. Rudland PS. Epithelial stem cells and their possible role in the development of the normal and diseased human breast. *Histol. Histopathol.* 1993; **8**: 385–404.
17. Deville P, Tavassoli FA. Tumours of the breast. In Deville P, Tavassoli FA eds. *World Health Organization classification of tumor. Pathology and genetics of tumors of the breast and female genital organs*. Lyon: IARC Press, 2003; 9–112.
18. Wellings SR, Jensen HM, Marcum RG. An atlas of subgross pathology of the human breast with special reference to possible precancerous lesions. *J. Natl Cancer Inst.* 1975; **55**: 231–273.
19. Stirling JW, Chandler JA. The fine structure of the normal, resting terminal ductal-lobular unit of the female breast. *Virchows Arch. A Pathol. Anat. Histol.* 1976; **372**: 205–226.
20. Collins LC, Schnitt SJ. Breast. In Mills SE ed. *Histology for pathologists*, 3rd edn. Philadelphia, PA: Lippincott Williams & Wilkins, 1997; 57–71.
21. Russo J, Russo IH. Development of the human mammary gland. In Neville MC, Daniel C eds. *The mammary gland*. New York: Plenum Publishing, 1987; 67–93.
22. Russo J, Gusterson BA, Rogers AE, Russo IH, Welling SR, Van Zwieten MJ. Comparative study of human and rat mammary tumorigenesis. *Lab. Invest.* 1990; **62**: 244–278.
23. Tsai YC, Lu Y, Nichols PW, Zlotnikov G, Jones PA, Smith HS. Contiguous patches of normal human mammary epithelium derived from a single stem cell: implications for breast carcinogenesis. *Cancer Res.* 1996; **56**: 402–404.
24. Gerdes J, Lelle RJ, Pickartz H *et al.* Growth fractions in breast cancers determined *in situ* with monoclonal antibody Ki-67. *J. Clin. Pathol.* 1986; **39**: 977–980.
25. Makin CA, Bobrow LG, Bodmer WF. Monoclonal antibody to cytokeratin for use in routine histopathology. *J. Clin. Pathol.* 1984; **37**: 975–983.
26. Chiavegato A, Bochaton-Piallat ML, D'Amore E, Sartore S, Gabbiani G. Expression of myosin heavy chain isoforms in mammary epithelial cells and in myofibroblasts from different fibrotic settings during neoplasia. *Virchows Arch.* 1995; **426**: 77–86.
27. Hähnel R, Twaddle E, Vivian AB. Estrogen receptors in human breast cancer. 2. *In vitro* binding of estradiol by benign and malignant tumors. *Steroids* 1971; **18**: 681–708.
28. Boecker W, Bier B, Freytag G *et al.* An immunohistochemical study of the breast using antibodies to basal and luminal keratins, alpha smooth muscle actin, vimentin, collagen IV and laminin. Part I: normal breast and benign proliferative lesions. *Virchows Arch. A Pathol. Anat. Histopathol.* 1992; **421**: 315–322.
29. Bhargava R, Dabbs DJ. Immunohistology of metastatic carcinomas of unknown primary. Step 2: the cytokeratins, an overview. In Dabbs DJ ed. *Diagnostic immunohistochemistry*, 3rd edn. Philadelphia, PA: Saunders Elsevier, 2010; 210–221.
30. Boecker W, Weigel S, Heindel W, Stute P. *Preneoplasia of the breast: a new conceptual approach to proliferative breast disease*. Munich: Elsevier Saunders, 2006.
31. Werling RW, Hwang H, Yaziji H, Gown AM. Immunohistochemical distinction of invasive from noninvasive breast lesions: a comparative study of p63 versus calponin and smooth muscle myosin heavy chain. *Am. J. Surg. Pathol.* 2003; **27**: 82–90.
32. Huang M, Yuqing L, Huanle Z, Feifei N. Breast cancer stromal fibroblasts promote the generation of CD44+ CD24– cells through SDF-1/CXCR4 interaction. *J. Exp. Clin. Cancer Res.* 2010; **29**: 80.
33. Liu S, Ginestier C, Charafe-Jauffret E *et al.* BRCA1 regulates human mammary stem/progenitor cell fate. *Proc. Natl Acad. Sci. USA* 2008; **105**: 1680–1685.
34. Bánkfalvi A, Ludwig A, de-Hesselle B, Buerger H, Buchwalow IB, Boecker W. Different proliferative activity of the glandular and myoepithelial lineages in benign proliferative and early malignant breast diseases. *Mod. Pathol.* 2004; **17**: 1051–1061.
35. Tavassoli FA. Myoepithelial lesions of the breast. Myoepitheliosis, adenomyoepithelioma, and myoepithelial carcinoma. *Am. J. Surg. Pathol.* 1991; **15**: 554–568.
36. Lazard D, Xavier S, Frid MG, Glukhova MA, Thiery J-P. Expression of smooth muscle-specific proteins in myoepithelium and stromal myofibroblasts of normal and malignant human breast tissue. *Proc. Natl Acad. Sci. USA* 1993; **90**: 999–1003.
37. Lerwill MF. Current practical applications of diagnostic immunohistochemistry in breast pathology. *Am. J. Surg. Pathol.* 2004; **28**: 1076–1091.
38. Briskin C, Heineman A, Chavarria T *et al.* Essential function of Wnt-4 in mammary gland development downstream of progesterone signaling. *Genes Dev.* 2000; **14**: 650–654.
39. Keeling JW, Ozer E, King G, Walker F. Oestrogen receptor alpha in female fetal, infant, and child mammary tissue. *J. Pathol.* 2000; **191**: 449–451.

Paper II

RESEARCH ARTICLE

Open Access

Women with familial risk for breast cancer have an increased frequency of aldehyde dehydrogenase expressing cells in breast ductules

Björn L Isfoss^{1,2,3*}, Bo Holmqvist^{1,4}, Helena Jernström¹, Per Alm⁵ and Håkan Olsson^{1,6}

Abstract

Background: Knowledge is limited regarding the association between stem cells in histologically benign breast tissue and risk factors for breast cancer, and hence we addressed this issue in the present study. Recently, we assessed the histology of benign breast tissue from cancer and non-cancer patients for cells positive for the putative stem cell marker aldehyde dehydrogenase 1 A1 (ALDH), and the findings indicated an association between expression of ALDH and the hormonal factors menopause and hormone therapy. The current investigation examined possible associations between various known clinical and genetic risk factors for breast cancer and cellular expression of ALDH in ductules in benign human breast tissue.

Methods: The study included breast surgery patients that were *BRCA1/2* mutation carriers without breast cancer ($n = 23$), had *BRCA1/2* ($n = 28$) or sporadic ($n = 21$) breast cancer, or required non-cancer-related mastoplasmy ($n = 34$). The distribution and frequency of ALDH-immunolabelled cells were correlated to patient subgroups with different risk factors, using mastoplasmy patients as a control group. Statistical analyses comprised linear and logistic regression, Spearman's rank test, Pearson's test, and Fisher's exact test. In two-tailed tests, $p < 0.05$ was considered significant.

Results: A strong association was found between family history of breast cancer and a high frequency of ALDH+ cells ($p = 0.001$) at all ductular levels in all groups, regardless of *BRCA* status, age, parity, or occurrence of cancer. In pre-menopausal non-*BRCA* cancer patients, the frequency of ALDH+ cells increased with age ($p < 0.01$) but decreased with increasing parity ($p < 0.03$). High frequencies of ALDH+ cells were found in the non-basal ductular levels in *BRCA1* mutation carriers ($p = 0.03$), but in the basal ductular level in *BRCA2* cancer patients ($p = 0.02$). Among post-menopausal patients, only on-going hormone replacement therapy was correlated with a high number of ALDH+ cells ($p < 0.03$).

Conclusion: In histologically normal breast tissue, we found a positive association between the frequency of ductular ALDH+ cells and several breast cancer risk factors, particularly family history of this disease, which supports previous evidence that ALDH plays a role in breast cancer.

Keywords: Stem cells, Aldehyde dehydrogenase, Breast neoplasia, Familial cancer, *BRCA1*, *BRCA2*, Histology, Immunohistochemistry, Breast ductules

* Correspondence: isfoss@mac.com

¹Department of Oncology, Clinical Sciences Lund, Lund University, SE-221 85 Lund, Sweden

²Department of Pathology, Telemark Hospital, 3710 Skien, Norway

Full list of author information is available at the end of the article

Background

A stem-like cancer cell is defined as a cell with the capacity for self-renewal and the ability to generate different cell types that form a tumor [1]. In 2003, the presence of benign stem cells in non-histological breast tissue preparations was identified on the basis of functional cell characteristics [2,3], and a brief histological description of these cells was published in 2007 [4]. It has been proposed that aldehyde-dehydrogenase-expressing (ALDH+) breast cells include malignant stem-like cell populations that maintain and cause progression of cancer [4,5]. ALDH catalyzes oxidation and is necessary for retinoic acid synthesis, and it has been suggested that this enzyme is also involved in stem cell preservation and initiation of differentiation [6]. Normal mammary stem cells and stem-like cancer cells were recently shown to express an alternative isoform of ALDH [7], but the stem cell properties or cancer-related functions of cells that are positive for any isoform still remain unclear.

Several clinical and molecular factors predict the risk of developing breast cancer. For example, the presence of *BRCA1* and *BRCA2* gene mutations confers a 40–80% lifetime risk [8], and exogenous hormone exposure is associated with relative risks of 1.5 to 2.0 [9]. Furthermore, non-malignant histological changes such as atypical ductal hyperplasia are associated with a 28% risk of breast cancer [10].

ALDH+ cells are found in up to 48% of breast cancer tumors and are believed to cause late recurrence, and these cells are also associated with an adverse prognosis and poor outcome after conventional anti-cancer drug treatment [5,11,12].

To assess the potential of ALDH as a predictive marker for subsequent development of breast cancer, it is necessary to define the normal ranges of frequencies and distribution of ALDH+ cells in histologically benign breast tissue in women with and without breast cancer. Such data are limited at present, although a small case-control study showed elevated levels of ALDH+ cells in epithelium and stroma of patients who later developed cancer [13], and an investigation of African women revealed a higher frequency of ALDH+ cells in breast cancer tissue compared to benign breast tissue [14]. It is also essential to determine whether the frequency or distribution of ALDH+ putative stem cells in histologically normal breast tissue is related to risk factors for breast cancer. We recently described in detail the distribution of ALDH+ cells in terminal duct lobular units (TDLUs) and stroma in benign breast tissues [15]. The correlations with risk factors that were observed in the small group of patients assessed in that investigation suggested that density and distribution of ALDH+ cells are associated with menopausal state and hormone replacement therapy. Therefore, our aim in the present study was to

examine ALDH expression in ductular cells in a larger patient group and to elucidate the relationship between such expression and various risk factors for breast cancer, including *BRCA1/2* mutation status, familial breast cancer history, hormone intake, parity, and age at menarche.

Methods

Patient material

The patients considered for inclusion in this study were female patients who had been treated with breast surgery in Skåne County and met the criteria for one of the following groups:

Group A ($n = 30$): breast cancer patients without *BRCA1/2* mutation; surgery during the period 1999–2006.

Group B ($n = 19$): breast cancer patients with *BRCA1* mutation; surgery during the period 1984–2009.

Group C ($n = 16$): breast cancer patients with *BRCA2* mutation; surgery during the period 1984–2009.

Group D ($n = 13$): *BRCA1* mutation carriers without breast cancer; prophylactic mastectomy during the period 1996–2010.

Group E ($n = 13$): *BRCA2* mutation carriers without breast cancer; prophylactic mastectomy during the period 1996–2010.

Group F ($n = 35$): patients without breast cancer or *BRCA1/2* mutations; mastoplasty during the period 1993–1994.

Thus a total of 126 patients were reviewed for inclusion in our study. An experienced histopathologist (BLI) examined the original hematoxylin and eosin (H&E) stained microscope slides from each patient without knowledge of the clinical parameters. The tissue blocks containing the largest number of histologically normal TDLUs for each patient were selected for the investigation. Exclusion criteria were any of the following: patient received neoadjuvant therapy; no tissue blocks available in the archives; no tissue block contained ≥ 10 morphologically benign TDLUs. Based on the mentioned criteria, a total of 106 patients were included in the study (see Table 1).

Data on the following clinical parameters were available for the majority of the patients: indication for surgery, age at time of surgery, current or previous use and total duration of use of oral contraceptives or hormone replacement therapy (HRT), age at menarche, number of live childbirths (parity), family history of breast cancer (1st or 2nd degree relative), and *BRCA1/2* mutation status. Table 1 presents information on the age, hormonal exposure, and reproductive status of the women included in the study.

Sixty-seven of the women were pre-menopausal, 35 were post-menopausal, and data were missing for four. The median age at onset of menopause was 49 years

Table 1 Patient groups in the study

Patient group	Breast cancer and mutation status	Number of patients	Age in years, median (range)	Genetic predisposition			Parity				Hormone use at time of surgery		
				Family history	BRCA1	BRCA2	0	1 or 2	3 or 4	Data lacking	HRT	OC	Data lacking
A	Cancer, non-BRCA1/2	21	50 (31–77)	4	NA	NA	8	4	9	0	3	1	0
B	Cancer, BRCA1	17	43 (23–81)	17	17	NA	4	10	0	3	4	1	3
C	Cancer, BRCA2	11	51 (33–74)	11	NA	11	0	7	3	1	0	1	2
D	Prophylactic mastectomy, BRCA1	12	37 (23–54)	12	12	NA	0	6	4	1	0	4	1
E	Prophylactic mastectomy, BRCA2	11	37 (31–51)	11	NA	11	0	5	5	1	0	0	1
F	Mammoplasty, non-cancer, non-BRCA	34	31 (20–68)	5	NA	NA	19	7	8	0	0	8	1

Patient groups included in the study and subsequently re-grouped according to the listed parameters for analysis of ALDH+ cells. The table presents selected clinical, genetic, and hormonal characteristics of patients.

NA, not applicable; HRT, hormone replacement therapy; OC, oral contraceptive.

(range, 35–55 years). The numbers of live births among the women were as follows: para 0 in 32, para 1 in 11, para 2 in 28, para 3 in 25, and para 4 in four. The median age at menarche was 13 years (range, 10–18 years; data missing for 32 women). Data regarding exogenous hormone treatment status at the time of surgery were as follows: 70 women had no such treatment, 15 used oral contraceptives, seven received HRT, and six had a progestin intrauterine device. Sixty-five women had used oral contraceptives at sometime during their lives (median duration, 7.1 years), and 11 had received HRT at some point (median duration, 5.0 years). Clinical data and breast tissue samples representing 25 of the 28 patients in our previous study [15] were included in the present analysis.

Histology and immunohistochemistry

If two tissue blocks from the same patient were of similar superior quality, both (from the same or both breasts) were analyzed in the same manner for quality assurance purposes. New sections were obtained from all relevant paraffin tissue blocks, and consecutive sections were H&E stained and used for immunohistochemistry, as described previously in detail [15]. Briefly, after antigen retrieval, the sections were incubated with mouse monoclonal antibodies directed against human ALDH1 A1 (aa 7–128, N-term, diluted 1:100; Becton, Dickinson and Company, Franklin Lakes, NJ, USA). Detection of immunoreactive sites was performed using a system based on horseradish peroxidase (HRP) and di-aminobenzidine (DAPI) labelling of primary antibodies raised in mice (Envision+ System-HRP, Dako, Glostrup, Denmark). Sequential incubations were performed with secondary antibodies and HRP-conjugated antibodies. Following the peroxidase reaction in DAPI and H₂O₂, the sections were rinsed and counterstained with hematoxylin, and then dehydrated and coverslipped in Mountex medium (Histolab Products AB,

Göteborg, Sweden). To confirm the specificity of ALDH labelling, slides that were not incubated with the primary antibodies were included in each immunohistochemistry run.

The tissue sections selected for ALDH immunolabelling were assessed regarding the following features: tissue fragment size, epithelial atypia or hyperplasia, invasive carcinoma, and total number of TDLUs. The tissue areas available in each chosen block ranged in size from 48 to 621 mm² with a median value of 254 mm². Areas displaying ductular or lobular hyperplasia, atypia, carcinoma *in situ* (four cases), or invasive carcinoma (10 cases) were excluded from further analysis. To evaluate the distribution and number of immunolabelled ALDH+ cells, 50 TDLUs were examined, guided by a grid, at evenly spaced intervals in each tissue section; if fewer than 50 TDLUs were present in a section, all the TDLUs were evaluated. The number of TDLUs found to be available for analysis of ALDH immunoreactivity in each patient ranged from 13 to 50 (mean, 45 TDLUs). Only ductules (i.e., no ducts or stroma) were evaluated. In our previous study [15], we described ALDH+ cells as being in a basal, luminal, or intermediate location. For each patient in the present study, the number of TDLU cross sections with ductular ALDH+ cells was recorded for each ductular level (luminal, intermediate, or basal) in relation to the total number of TDLU cross sections examined.

ALDH immunoreactive cells that were labelled either strongly or weakly were considered to be positive for ALDH. Furthermore, cells found in luminal and intermediate ductular locations were defined as non-basal (luminal plus intermediate) in some analyses, as indicated in the text. This was done because determination of cell location by ductular level is less accurate when ductules lack microscopically discernible lumina.

Blind testing of ALDH+ cell frequency in duplicate tissue samples from 13 patients yielded correlation

coefficients of 0.45 (Pearson) and 0.53 (Spearman), indicating similarity between independent observations ($r_s = 0.65$, $p = 0.01$). These results confirmed the robustness of the analysis and demonstrated similarity between different areas of breast tissue in the same patient.

Statistical analysis

The number of TDLUs with detectable ALDH+ cells and basal and non-basal localization of those cells were analyzed by linear regression using occurrence of ALDH+ cells in the mastectomy group as the independent variable. Logistic regression was used to analyze differences between risk factor groups. Correlation between ALDH findings for duplicate samples from the same patient was analyzed using Spearman's rank test and Pearson's test. Two-tailed tests were performed to assess the level of statistical significance, and results with $p < 0.05$ were considered significant. SPSS 18 software (IBM, Armonk, NY, USA) was used for all statistical analyses.

Ethics

The study was approved by the Research Ethics Committee for Southern Sweden (approval 11-92, 349-00).

Results and discussion

Division of patient inclusion groups A–F into analysis groups

Patients in inclusion groups A–F were divided into relevant groups on the basis of genetic and hormonal status to enable various analyses of ALDH+ cells.

Distribution of ALDH+ cells

ALDH+ cells were detected in TDLUs of 92 patients (87%), including the youngest (aged 20 years) and the oldest (aged 81 years). ALDH+ cells in ductules were morphologically similar to other ductular epithelial cells (Figure 1), and they were observed either as a few scattered cells or organized in groups comprising partial or entire ductular cross sections. The ALDH+ cells occurred primarily in the adluminal and intermediate levels (Figure 1B), and in some cases they were found in the adluminal level only (Figure 1C), or less often in all levels (Figure 1A). In several cases, ALDH+ cells extended across a ductular lumen, indicating the luminal aspect of a bifurcation. ALDH+ cells were located adluminally in 0–74% of TDLUs (median 6%), intermediately in 0–68% (median 6%), and basally in 0–30% (median 2%), thus implying predominantly non-basal localization of ALDH+ cells, as reported previously [4,15].

ALDH+ cells in the six patient groups

ALDH+ cells were present in the epithelium at some ductular level in 90% of the subjects (19/21) in Group A (breast carcinoma with no *BRCA* mutations) and in a similar fraction (94%, 16/17) of the patients in Group B

(breast carcinoma with *BRCA1* mutation), but in a smaller fraction (73%, 8/11) of those in Group C (breast carcinoma with *BRCA2* mutation). Also, ALDH+ ductular cells were detected in 100% (12/12) of the patients in group D (prophylactic mastectomy due to a *BRCA1* mutation) and 100% (11/11) of those in Group E (prophylactic mastectomy due to a *BRCA2* mutation). In Group F (mastectomy patients with neither cancer nor *BRCA1/2* mutations), ALDH+ ductular cells were found in 76% (26/34) of the patients.

There was no statistically significant difference in the frequency of ALDH+ cells among the patient groups ($p = 0.09$), although a higher frequency was noted for patient Groups A–E combined compared to the mastectomy group ($p = 0.06$, Fisher's exact test). This finding, together with previous evidence that ALDH+ cells in different levels of the ductular epithelium are differentially associated with risk factors for breast cancer, [15] prompted a detailed analysis of patient subgroups regarding the occurrence of ALDH+ cells in the various levels of the ductular epithelium (see below).

ALDH+ cells in patients with a family history of breast cancer but no *BRCA1/2* mutations

Pre-menopausal patients with a family history of breast cancer but no *BRCA1/2* mutations were significantly associated with large numbers of ALDH+ cells at all ductular levels ($p \leq 0.01$; Figure 2A). This association was independent of parity, age, and personal history of cancer, which indicates a positive relationship between ALDH expression and familial risk of breast cancer in women without *BRCA1/2* mutations. Notably, such an association with high frequency of ALDH+ cells was not observed at any ductular level in post-menopausal patients. Further information on these results is given in Table 2.

ALDH+ cells in patients with a *BRCA1* or *BRCA2* mutation

Compared to breast tissue from mastectomy patients, such tissue from pre-menopausal women who underwent preventive mastectomy due to *BRCA1* carrier status contained significantly larger numbers of ALDH+ cells at non-basal ductular levels ($p = 0.03$; see Figure 2B). A positive association of borderline significance ($p = 0.06$) was noted for ALDH+ cells located at the basal ductular level in the *BRCA1* mutation carriers. No difference in the occurrence or distribution of ALDH+ cells in breast tissue was observed between women with breast cancer and *BRCA1* gene mutations and those who underwent mastectomy. Larger numbers of ALDH+ cells at non-basal ductular levels were discerned in tissue from pre-menopausal women with breast cancer and *BRCA2* gene mutations than in tissue from mastectomy patients ($p = 0.02$; Figure 2C). The post-menopausal *BRCA1* and *BRCA2* patient subgroups showed no significant

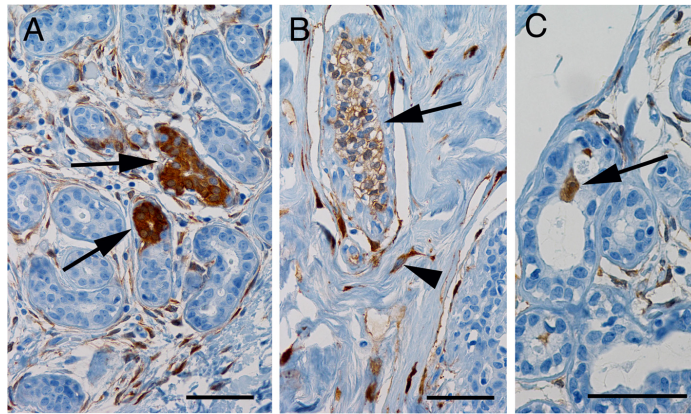


Figure 1 Distribution of ALDH+ cells in benign breast ductules. Brown staining indicates ALDH immunoreactivity. **A**, ALDH+ cell populations (arrows) located at luminal, basal, and intermediate ductular levels (levels described in detail elsewhere [15]). **B**, Micrograph showing an ALDH+ cell population (arrow) and ALDH+ stromal cells (arrowhead; as previously described [15]). **C**, Some ALDH+ cells are located in ductular bifurcations (arrow; cell type described previously [4,15]). All sections were counterstained with hematoxylin; scale bars in all three micrographs represent 50 μ m.

differences compared to the mammoplasty patients. Table 2 gives further information regarding these results.

It should also be mentioned that a higher frequency of ALDH+ cells in ductules was found in patients with *BRCA1* mutations than in those with *BRCA2* mutations. This may reflect the dissimilarities in oncogenesis between different types of *BRCA* mutations that have been described by other investigators [16].

ALDH+ cells in relation to age and menarche

Among pre-menopausal patients without *BRCA* mutations, age was positively associated with the frequency of ALDH+ cells at all ductular levels ($p \leq 0.01$; Figure 3), even after adjusting for parity and family history of breast cancer ($p = 0.01$), which suggests that risk factors have a stronger influence with increasing age. This association was not found within the post-menopausal group.

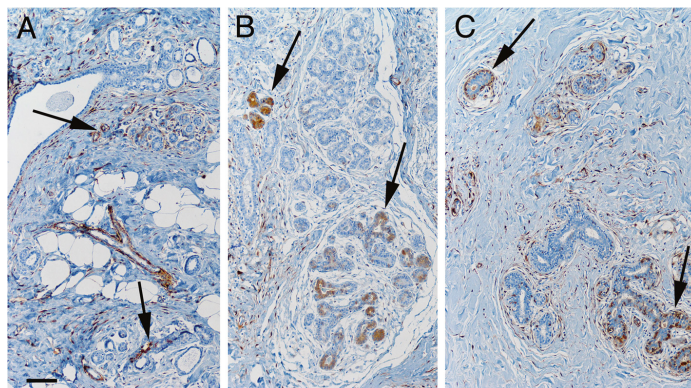


Figure 2 Frequency of ALDH+ cells in ductules of benign breast tissue from pre-menopausal women with a family history of breast cancer. ALDH+ cells were detected significantly more often in tissue from patients in this group than in control patients. **A**, Representative image of ALDH+ cell populations (arrows) in breast tissue from a woman with a family history of breast cancer but no *BRCA1/2* mutation. ALDH+ cells in the periphery of blood vessels, such as in the large Y-shaped structure in the center of this image, were detected in some cases (not analyzed further in this study). **B**, Image demonstrating ALDH+ cell populations (arrows) in benign breast tissue from a woman with a *BRCA1* mutation. **C**, Image showing ALDH+ cell populations (arrows) in benign breast tissue from a woman with a *BRCA2* mutation. Scale bar in A represents 100 μ m in all three images.

Table 2 Immunohistochemistry results

Patients	Median percentage of TDLUs containing ALDH+ cells (range)		
	Luminal ductular level	Intermediate ductular level	Basal ductular level
Pre-menopausal with family history of breast cancer, including patients with BRCA1 or BRCA2 mutation (n = 37)	12 (0–62)**	12 (0–53)**	2 (0–18)
Pre-menopausal with BRCA1 mutation (n = 18)	15 (2–50)*	15 (6–38)*	4 (0–18)
Pre-menopausal with BRCA2 mutation (n = 13)	14 (0–62)*	8 (2–53)*	0 (0–18)
Pre-menopausal without family history of breast cancer (n = 25)	6 (0–29)	6 (0–44)	0 (0–29)
Post-menopausal receiving HRT at the time of surgery (n = 7)	10 (0–38)*	8 (0–38)*	2 (0–21)
Post-menopausal not receiving HRT at the time of surgery (n = 24)	4 (0–32)	4 (0–34)	0 (0–18)
Nocancer, underwent mastoplasmy (n = 34)	6 (0–32)	4 (0–44)	0 (0–29)

A statistical comparison of ALDH immunohistochemistry results for patients with and without a family history of breast cancer, and patients who were or were not receiving HRT at the time of surgery.

* $P \leq 0.05$.

** $P \leq 0.01$.

ALDH, aldehyde dehydrogenase 1 A1; TDLU, terminal duct lobular unit; HRT, hormone replacement therapy.

Age at menarche was not correlated with the frequency or the distribution of ALDH+ cells.

ALDH+ cells in relation to parity

In breast tissue from pre-menopausal patients with or without cancer or *BRCA* mutations, adjusted for age, the frequency of ALDH+ cells at all three ductular levels was significantly lower with increased parity ($p \leq 0.03$; see Figure 4). This relationship was not observed in the post-menopausal group. Thus the lower risk of breast cancer associated with higher parity [17] may be related to the lower frequency of ALDH+ cells in high-parity patients. However, this possibility needs to be further investigated using a larger data set and focusing on mutation status.

ALDH+ cells in relation to HRT and oral contraceptives

No correlation was found between the use of oral contraceptives at the time of surgery and the frequency of ALDH+ cells at any ductular level in breast tissue, indicating that the hormonal impact of oral contraceptives alone is not sufficient to override physiological hormonal

changes. However, compared to post-menopausal women who were not using HRT at the time of surgery, those who were on such therapy had larger numbers of ALDH+ cells in tissue at basal ($p = 0.025$) and non-basal ($p = 0.03$) levels (Figure 5 and Table 2), and this difference was independent of other risk factors. In the post-menopausal group, HRT was the only hormone intake parameter that showed a statistically significant correlation with a high frequency of ALDH+ cells, which agrees with evidence that HRT postpones TDLU involution and increases the risk of cancer [18–21]. This finding also suggests that ongoing HRT may be one of the factors that influence the number of ALDH+ cells.

In contrast, neither the total duration of contraceptive pill usage nor the duration of HRT was associated with the frequency of ALDH+ cells, which suggests that exogenous hormones have only a transient effect on the occurrence of ALDH+ cells in benign breast tissue, and is consistent with previously reported data on sex hormone therapies suggesting that ongoing or recent intake of HRT increases the risk of breast cancer [19].

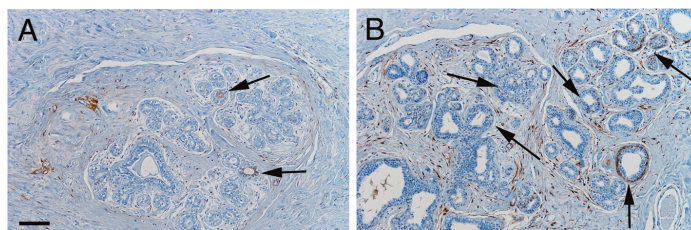


Figure 3 Frequency of ALDH+ cells in benign ductules of pre-menopausal women of different ages. Representative images of benign ductules in breast tissue from a 31-year-old patient (A) and from a 50-year-old patient (B) demonstrating significantly higher frequency of ALDH+ cells (arrows) with increasing age. Scale bar in A represents 100 μ m in both images.

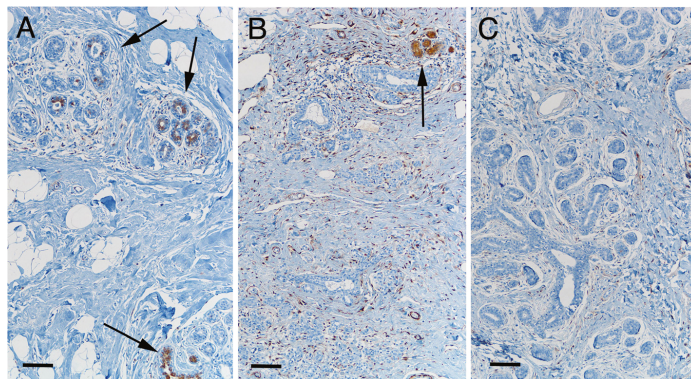


Figure 4 Frequency of ALDH+ cells in benign ductules of pre-menopausal women with different parities. Representative images of benign ductules in pre-menopausal patients demonstrate a significant decrease in frequency of ALDH+ cells (brown) with increasing parity in this patient subgroup. **A**, Image illustrating the relatively large number of ductular ALDH+ cells (arrows) in breast tissue from a 39-year-old nulliparous woman. **B**, Image of breast tissue from a 38-year-old two-parous woman showing the relatively small number of TDLUs containing ductular ALDH+ cells (arrow), and scattered ALDH+ cells in the stroma. **C**, Image revealing the lack of ductular ALDH+ cells in breast tissue from a 41-year-old four-parous woman. Scale bars: 100 μ m.

ALDH+ cells in relation to cancer versus non-cancer

The present findings support the hypothesis that ALDH+ breast cell populations participate in oncogenesis. We found several associations between high frequencies of ALDH+ cells in benign breast tissue and clinical risk

factors for cancer. Also, statistical analysis of subgroups demonstrated significant correlations between ALDH+ cells and family history of breast cancer, parity, and HRT exposure (see Table 2). Larger studies are needed to assess other risk factors for breast cancer in this context.

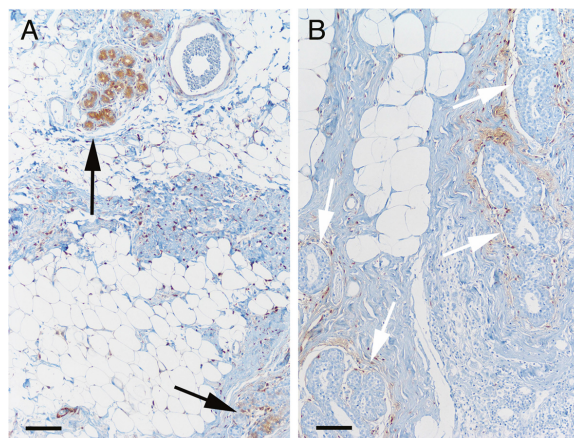


Figure 5 Frequency of ALDH+ cells in benign ductules of post-menopausal women with and without HRT at the time of surgery. Representative images of tissue from post-menopausal women are presented that demonstrate the significantly increased frequency of ALDH+ cells in breast tissue from women receiving HRT treatment at the time of surgery. **A**, Image illustrating the relatively high number of TDLUs containing ALDH+ cells (arrows) in benign breast tissue from a 70-year-old woman receiving HRT at the time of cancer surgery. **B**, Image of benign breast tissue from a 74-year-old woman who was not receiving HRT at the time of surgery, showing the presence of relatively few or complete absence of ALDH+ cells (white arrows indicate ductules with no ALDH+ cells). The benign tissue from this woman also contained ALDH+ stromal cells, as demonstrated in all patient groups. Scale bars: 100 μ m.

Methodological considerations

The patients evaluated in the present study were treated between 1984 and 2010, and the surgical techniques and oncological treatment protocols being applied during that period were subject to changes. However, the potential impact of those modifications on the results of our investigation can be assumed to be negligible for the following reasons: (1) patients who received neoadjuvant therapy were excluded; (2) possible influence of variation in antigenicity related to heterogeneous tissue fixation was reduced to a minimum by using ALDH positivity in stromal cells as internal control, and by considering all cells exhibiting weak or strong immunoreactivity as positive for expression of ALDH.

Our study demonstrated associations between ALDH+ cell frequencies in benign breast tissue and risk factors for breast cancer, but we found no significant relationship between ALDH+ cell frequencies in benign tissue and the co-presence of cancer. This finding might be explained by the influence of temporal and spatial factors of a developing cancer; more specifically, that the cancer is established after the occurrence of a risk factor, and the tumor can overgrow ALDH+ cells.

In our previous study conducted using the same methods [15], a higher frequency of ALDH+ ductular cells was found in mastoplasmy patients than in patients with established breast cancer. In contrast, in the present investigation, data on mastoplasmy patients were used to allow comparison of non-breast cancer and breast cancer patients, the latter group including many individuals with a familial risk of breast cancer. However, inasmuch as increased cell mass in a breast predisposes to cancer [22,23], it would be most suitable to obtain control tissue from patients without breast disease, not from those with breast hyperplasia.

Conclusion

The present study demonstrated a positive association between the frequency of ALDH+ ductular cells in benign female breast tissue and several well-known risk factors for breast cancer. These findings suggest that ALDH cell positivity in microscopically normal breast tissue should be further evaluated as a potential marker for the risk of breast cancer, especially in patients with familial breast cancer with or without BRCA1/2 mutations.

The largest differences in ALDH+ cell frequency between risk groups were observed in the luminal and intermediate (non-basal) ductular locations. Our data indicate that ALDH-expressing cells may play a yet undefined role in the development of female breast cancer, and they also suggest that immunohistochemical analysis of ALDH can aid prediction of the risk of breast cancer. It is conceivable that having a high number of ALDH+ stem cells promotes a high number of progenitor cells,

and that the latter are susceptible to oncogenesis. The current results underline the need for further research to assess the previously proposed stem and/or progenitor qualities of ALDH+ cells in normal breast tissue and their potential role in carcinogenesis.

Competing interests

The authors declare that they have no competing interests.

Authors' contributions

BLI conceived this study, coordinated the laboratory work, examined the microscopic material, participated in the data analysis, and coordinated the writing of the manuscript. BH participated in the experimental design and in the writing of the manuscript. HJ provided clinical data and helped write the manuscript. PA helped design the study and helped write the manuscript. HO helped design the study, was responsible for ethical approval, provided clinical data, performed data analysis, and helped write the manuscript. All authors read and approved the final manuscript.

Acknowledgements

This study was supported by grants from the Swedish Medical Research Council, the Swedish Cancer Society, and local funds at the University Hospital and Region Skane. We acknowledge the support of European Research Council Advanced Grant ERC-2011-294576. We extend many thanks to Cristina Giornei and Lena Tran at the pathology laboratory of the university hospital in Lund for excellent technical assistance.

Author details

¹Department of Oncology, Clinical Sciences Lund, Lund University, SE-221 85 Lund, Sweden. ²Department of Pathology, Telemark Hospital, 3710 Skien, Norway. ³Department of Pathology, Skane University Hospital, SE-221 85 Lund, Sweden. ⁴ImaGene-IT AB, Medicion Village, SE-223 81 Lund, Sweden. ⁵Department of Pathology, Clinical Sciences Lund, Lund University, SE-221 85 Lund, Sweden. ⁶Department of Cancer Epidemiology, Clinical Sciences Lund, Lund University, SE-221 85 Lund, Sweden.

Received: 22 April 2013 Accepted: 30 October 2013

Published: 4 November 2013

References

- Clarke MF, Dick JE, Dirks PB, Eaves CJ, Jamieson CH, Jones DL, Visvader J, Weissman IL, Wahl GM: Cancer stem cells—perspectives on current status and future directions: AACR workshop on cancer stem cells. *Cancer Res* 2006, **66**:9339–9344.
- Alvi AJ, Clayton H, Joshi C, Enver T, Ashworth A, Vivanco M, Dale TC, Smalley MJ: Functional and molecular characterisation of mammary side population cells. *Breast Cancer Res* 2003, **5**:R1–R8.
- Al-Hajj M, Wicha MS, Benito-Hernandez A, Morrison SJ, Clarke MF: Prospective identification of tumorigenic breast cancer cells. *Proc Natl Acad Sci* 2003, **100**:3983–3988.
- Ginestier C, Hur MH, Charafe-Jauffret E, Monville F, Dutcher J, Brown M, Jacquemier J, Viens P, Kleer CG, Liu S, Schott A, Hayes D, Bimbaum D, Wicha MS, Dontu G: ALDH1 is a marker of normal and malignant human mammary stem cells and a predictor of poor clinical outcome. *Cell Stem Cell* 2007, **15**:555–567.
- Tanei T, Morimoto K, Shimazu K, Kim SJ, Tanji Y, Taguchi T, Tamaki Y, Noguchi S: Association of breast cancer stem cells identified by aldehyde dehydrogenase 1 expression with resistance to sequential paclitaxel and epirubicin-based chemotherapy for breast cancers. *Clin Cancer Res* 2009, **15**:4234–4241.
- Ma I, Allan AL: The role of human aldehyde dehydrogenase in normal and cancer stem cells. *Stem Cell Rev* 2011, **7**:292–306.
- Eirew P, Kannan N, Knapp DJ, Valliant F, Emerman JT, Lindeman GJ, Visvader JE, Eaves CJ: Aldehyde dehydrogenase activity is a biomarker of primitive normal human mammary luminal cells. *Stem Cells* 2012, **30**:344–348.
- Fackenthal JD, Olopade OF: Breast cancer risk associated with BRCA1 and BRCA2 in diverse populations. *Nat Rev Cancer* 2007, **7**:937–948.
- Beral V, Reeve G, Bull D, Green J, Million Women Study Collaborators: Breast cancer risk in relation to the interval between menopause and starting hormone therapy. *J Natl Cancer Inst* 2011, **103**:296–305.

10. Sinn HP, Elsayaf Z, Helmchen B, Aulmann S: **Early breast cancer precursor lesions: lessons learned from molecular and clinical studies.** *Breast Care* 2010, **5**:218–226.
11. Reya T, Morrison SJ, Clarke MF, Weissmann IL: **Stem cells, cancer, and cancer stem cells.** *Nature* 2001, **414**:105–111.
12. Nalwoga H, Ames JB, Wabinga H, Aklsen LA: **Expression of aldehyde dehydrogenase (ALDH1) is associated with basal-like markers and features of aggressive tumours in African breast cancer.** *Br J Cancer* 2010, **102**:369–375.
13. Kunju LP, Cookingham C, Toy KA, Chen W, Sabel MS, Kleer CG: **EZH2 and ALDH-1 mark breast epithelium at risk for breast cancer development.** *Mod Pathol* 2011, **24**:786–793.
14. Schwartz T, Stark A, Pang J, Awuah B, Kleer CG, Quayson S, Kingman S, Aitpillah F, Jiagge E, Oppong JK, Osei-Bonsu E, Martin I, Yan X, Toy K, Adjei E, Wicha M, Newman LA: **Expression of aldehyde dehydrogenase 1 as a marker of mammary stem cells in benign and malignant breast lesions of Ghanaian women.** *Cancer* 2013, **119**:488–494.
15. Isfoss BL, Holmqvist B, Alm P, Olsson H: **Distribution of aldehyde dehydrogenase 1-positive stem cells in benign mammary tissue from women with and without breast cancer.** *Histopathology* 2012, **60**:617–633.
16. Ashworth A, Weber BL, Domchek SM: **Inherited genetic factors and breast cancer.** In *Diseases of the breast*. Edited by Harris JR, Morrow M, Lippman ME, Osborne CK. Philadelphia: Wolters Kluwer; 2010:209–220.
17. Schonfeld SJ, Pfeiffer RM, Lacey JV, Berrington de Gonzalez A, Doody MM, Greenlee RT, Park Y, Schairer C, Schatzkin A, Sigurdson AJ, Hartge P, Visvanathan K: **Hormone-related risk factors and postmenopausal breast cancer among nulliparous versus parous women: an aggregated study.** *Am J Epidemiol* 2011, **173**:509–517.
18. Collaborative Group on Hormonal Factors in Breast Cancer: **Breast cancer and hormone replacement therapy. Collaborative reanalysis of data from 51 epidemiological studies of 52 705 women with breast cancer and 108 411 women without breast cancer.** *Lancet* 1997, **350**:1047–1059.
19. Olsson HL, Ingvar C, Bladström A: **Hormone replacement therapy containing progestins and given continuously increases breast carcinoma risk in Sweden.** *Cancer* 2003, **97**:1387–1392.
20. Beral V, Million Women Study Collaborators: **Breast cancer and hormone-replacement therapy in the Million Women Study.** *Lancet* 2003, **362**:419–427.
21. Anderson GL, Judd HL, Kaunitz AM, Barad DH, Beresford SA, Pettinger M, Liu J, McNeely SG, Lopez AM, Women's Health Initiative Investigators: **Effects of estrogen plus progestin on gynecologic cancers and associated diagnostic procedures: the women's health initiative randomized trial.** *JAMA* 2003, **290**:1739–1748.
22. Albanes D, Winick M: **Are cell number and cell proliferation risk factors for cancer?** *J Natl Cancer Inst* 1988, **80**:772–774.
23. Olsson H: **Risk for malignant tumors after oral contraceptive use: is it related to organ size while taking the pill?** *Med Oncol Tumor Pharmacother* 1990, **7**:61–64.

doi:10.1186/1472-6890-13-28

Cite this article as: Isfoss et al.: Women with familial risk for breast cancer have an increased frequency of aldehyde dehydrogenase expressing cells in breast ductules. *BMC Clinical Pathology* 2013 **13**:28.

Submit your next manuscript to BioMed Central and take full advantage of:

- Convenient online submission
- Thorough peer review
- No space constraints or color figure charges
- Immediate publication on acceptance
- Inclusion in PubMed, CAS, Scopus and Google Scholar
- Research which is freely available for redistribution

Submit your manuscript at
www.biomedcentral.com/submit



Paper III

The absence of aldehyde dehydrogenase 1 A1-positive cells in benign mammary stroma is associated with risk factors for breast cancer

Björn Logi Isfoss^{1,3}Bo Holmqvist^{1,4}Helena Jernström¹Per Alm¹Håkan Olsson^{1,5}

¹Department of Oncology and Pathology, Department of Clinical Sciences Lund, Lund University,

²Department of Pathology, Skane University Hospital, Lund, Sweden;

³Department of Pathology, Telemark Hospital, Skien, Norway; ⁴ImaGene-iT AB, Medicin Village, ⁵Division of Cancer Epidemiology, Department of Clinical Sciences, Lund University, Lund, Sweden

Abstract: In this study, aldehyde dehydrogenase 1 (ALDH1)-expressing cells in stroma of histologically normal breast tissue from premenopausal women were investigated in situ regarding cellular morphology, cell distribution, and relation to the additional stem cell markers, CD44 (+) and CD24 (-). These results were correlated with hormonal and genetic risk factors for breast cancer. Triple immunofluorescence labeling was performed on tissues from premenopausal women with a family history of breast cancer, and breast reduction specimens from premenopausal women with no family history of breast cancer were used as a control group. The majority of ALDH1-immunoreactive cells in stroma were spindle-shaped or polygonal, and such cells that were CD44⁺ and CD24⁻ were absent in the breast stroma of a significantly larger number of nulliparous than parous women. A less common morphological type of ALDH1-positive cells in stroma was round or oval in shape, and such cells that were CD44⁺ and CD24⁻ were absent in a significant number of women with a family history of breast cancer. The CD44⁺/CD24⁻ immunophenotype is consistent with stem cells, and the round/oval morphology suggests mesenchymal cells. This study demonstrates that there are two morphologically distinct types of ALDH1-positive cells in histologically benign mammary stroma, and the absence of these cells is correlated with clinical risk factors for breast cancer in premenopausal women.

Keywords: mammary glands, human, neoplasms, *BRCA1* gene, stem cells, immunohistochemistry

Introduction

Numerous cell types are present in normal human breast tissue, but their relationship with the risk of breast cancer has not been clarified. Pluripotent stem cells (SCs) and committed SCs (progenitor cells) are necessary for the establishment and replenishment of differentiated cells. SCs are defined by their functional qualities: potential for multilineage differentiation, self-perpetuation, and longevity.¹ Cell populations with SC features exhibit surface protein antigens that make it possible to identify them by immunophenotype (eg, by flow cytometry and cell sorting or by immunohistochemistry). Al-Hajj et al² used cell surface marker expression to study breast cancer tissue and described the tumorigenic (cancer SC) phenotype CD44⁺/CD24⁻/low lineage-. Ginestier et al³ later reported aldehyde dehydrogenase 1 A1 immunoreactivity (ALDH1⁺) to be a more efficient immunophenotype for identifying both benign and malignant SCs and noted that the combined SC immunophenotype ALDH1⁺ CD44⁺ was even more efficient. ALDH1⁺ cells in breast carcinoma tissue have also been found to be associated with adverse prognosis.^{3,4} However, to date, very few studies

Correspondence: Björn Logi Isfoss
Department of Pathology, Telemark
Hospital, 3710 Skien, Norway
Tel +47 47 65 4101
Email isfoss@mac.com

have provided a cell-level in situ description of SC marker positivity in normal human breast epithelium or stroma.^{3,5-7}

In our earlier study, we have described in detail the distribution of ALDH1⁺ cells in non-neoplastic mammary tissue.⁶ In a subsequent investigation,⁷ we also found statistically significant associations between ALDH1⁺ ductular cells in premenopausal women and the risk of breast cancer in relation to patient age, family history of breast cancer, *BRCA1* mutation status, parity, and hormonal replacement therapy. Although those two studies demonstrated a relationship between ALDH1⁺ cells in ductules and the risk of breast cancer, they were performed using only one SC marker, ALDH1, and hence any associations with SCs could not be determined. Furthermore, it was recently reported that ALDH1 and CD44 express histologically and functionally separate SC populations in breast tissue,⁸ and thus a multi-marker approach is necessary for this research. In our earlier assessments, ALDH1⁺ cell populations in benign mammary stroma were detected but were not evaluated with regard to cancer risk factors. Therefore, in the current study, we investigated associations and correlations between clinical risk factors for breast cancer and ALDH1⁺ cells in histologically benign stroma, and we used triple immunofluorescence labeling to determine whether these cells also express CD44 and/or CD24, primarily to obtain a more detailed histological description of stromal cells and their expression of these SC markers. Quantitative data from these assessments were then analyzed for correlation with patient age, contraceptive pill use, parity, family history of breast cancer, and *BRCA1* mutation.

Patients and methods

Patients

Premenopausal women were selected from our group's earlier investigation of cancer and noncancer patients with or without risk factors for breast cancer.⁷ Patients with an unknown family history and those with insufficient tissue of good histological quality were excluded. The study was

approved by the Research Ethics Committee of Southern Sweden (approvals 11-92 and 349-00). The patients gave written consent to participate in this study.

Histology and immunofluorescence

Only areas of breast tissue that were histomorphologically normal (ie, benign and without hyperplasia or atypia) were chosen. From each patient, one paraffin-embedded block of formalin-fixed tissue was histologically selected based on maximum number of terminal duct-lobular units (TDLUs). The tissue area of the individual specimens ranged from 48 mm² to 621 mm² (median 254 mm²). Each block was cut in 3 µm sections, which were consecutively collected for hematoxylin and eosin staining, and for immunofluorescence triple labeling. The sections were deparaffinized in the following steps: xylene 3 minutes × 2, 100% EtOH 1 minute × 2, 95% EtOH 1 minute, 70% EtOH 1 minute × 2, and distilled water 1 minute × 2. Thereafter, antigen retrieval was performed on the sections in citrate buffer (10 mM sodium citrate containing 0.05% Tween 20, pH 6.0; Sigma-Aldrich Co., St Louis, MO, USA) for 10 minutes at 90°C. The sections were subsequently cooled to room temperature (RT), rinsed twice for 5 minutes in phosphate-buffered saline (PBS; 0.1 M, pH 7.4; AppliChem, Darmstadt, Germany), and immunolabeled using primary and secondary antibodies at the dilutions as specified in Table 1. The tissue sections were incubated for 20 minutes at RT in PBS containing 0.05% Triton X-100 (TX; Sigma-Aldrich Co.) and 1% bovine serum albumin (BSA; Sigma-Aldrich Co.), and then for 3 hours at RT in a mixture of primary antibodies diluted in PBS and 1% BSA containing 0.05% TX. Next, the sections were rinsed in PBS containing 0.05% TX for 5 minutes and then in PBS for 5 minutes, and thereafter incubated for 45 minutes at RT with fluorophore-conjugated secondary antibodies in a mixture diluted in PBS containing 1% BSA. This was followed by rinsing in PBS-TX for 3 minutes and in PBS for 3 minutes, then incubation in 0.1 µM 4',6-diamidino-2-phenylindole (Sigma-Aldrich Co.) in PBS for 15 minutes, and rinsing twice in PBS for 2 min-

Table 1 Antibodies used

Antigen/antibody (product code) and host species	Target species	Clonality (type)	Working dilution	Source
ALDH1 A1 (611194), mouse	Antihuman	Monoclonal IgG1	1:100	BD Biosciences, San Jose, CA, USA
CD24 (MA5-11833), mouse	Antihuman	Monoclonal IgM	1:100	Thermo Fisher Scientific, Waltham, MA, USA
CD44 (PA5-21419), rabbit	Antihuman	Polyclonal IgG	1:100	Thermo Fisher Scientific
AF488 (A11029), goat	Antimouse	Fab ₂ IgG H+L	1:150	Thermo Fisher Scientific
AF568 (A21043), goat	Antimouse	IFab ₂ gMµ	1:200	Thermo Fisher Scientific
AF647 (A21245), goat	Antirabbit	Fab ₂ IgG (H + L)	1:200	Thermo Fisher Scientific

Abbreviations: IgG, immunoglobulin G; IgM, immunoglobulin M.

utes. Finally, the sections were cover slipped and mounted in Pro-Long Gold anti-fade solution (Thermo Fisher Scientific, Waltham, MA, USA).

Immunohistochemical controls

Specificities and absence of cross-reactivity of the secondary antibodies employed were tested by omitting the primary antibodies in the first labeling step. Slides labeled with a single antibody were examined to ascertain that triple immunolabeled tissue appropriately revealed ALDH1 expression. The same protocol was applied to paraffin-embedded sections of spleen and urinary bladder, as positive controls of CD24 and CD44 labeling, respectively. The ALDH1 labeling pattern in immunofluorescence triple labeling was correlated with chromogenic visualization of ALDH1 labeling in adjacent sections (achieved using EnVision + System-HRP-DAB; Dako Denmark A/S, Glostrup, Denmark) and with previously reported ALDH1 labeling of epithelial structures.^{3,6,9}

Microscopy

Representative triple immunofluorescence-labeled sections were analyzed with a confocal laser scanning microscope (Carl Zeiss AG, Jena, Germany). This was performed to ascertain the specificity of multilabeling of individual antigens, and to

determine the location of the antigens in relation to cellular morphology (cell bodies and/or processes) and their possible coexistence in individual cells (Figure 1). Confocal microscopy was used to demonstrate different combinations of cytoplasmic and membrane immunolabeling in cells that had definable morphologies and were located in epithelial and stromal structures. Thereafter, the multilabeling was analyzed in all tissue sections using an epifluorescence microscope (Olympus BX 63, Olympus Corporation, Tokyo, Japan) equipped with specific fluorescence filter cubes for multifluorescence detection. Digital image documentation was achieved with an Olympus DP80 camera and software (Olympus Cellsens Dimension). All immunolabeled sections were screened microscopically in total at a magnification of 200× for each wavelength channel. Multiple areas from each specimen were photographed digitally for all channels, and the images were merged. All cytoplasmic immunolabeling above background of the control was considered positive, regardless of intensity. The tissue compartments analyzed were TDLU stromal areas, and the labeling was recorded for two morphologically defined cell types: round or oval cells and spindle-shaped or polygonal cells. In triple immunolabeling of ALDH1, CD44, and CD24, the labeling was coded for each morphological cell type: 0, not evaluable; 1, not present in the specimen; and 2, present in the specimen.

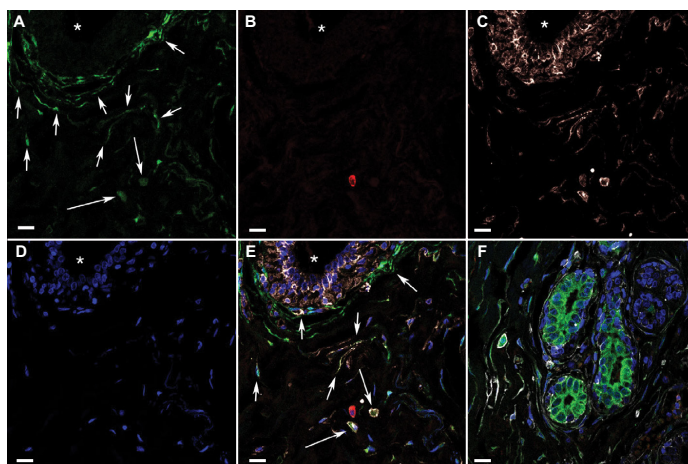


Figure 1 Confocal microscopy images of triple immunofluorescence-labeled histologically normal breast tissue.

Notes: (A)–(E) Images of single optical sections (0.6 µm thick) from a stromal area with a duct visible in the upper left part of the field (* in lumen), demonstrating immunofluorescence multilabeling and DAPI (nuclear stain) in separate channels. (A) ALDH1, green, indicates the different shaped ALDH1⁺ cell types in stroma (round/oval cells [short arrows] and spindle-shaped/polygonal cells [long arrows]). (B) CD24, red, indicates the scarcity of CD24⁺ cells. (C) CD44, white, indicates the relatively large number of CD44⁺ cells, yet many ALDH1⁺ CD44⁺ spindle-shaped cells. (D) DAPI, blue. (E) All four channels merged indicate that many ALDH1⁺ cells are also CD44⁺ but not CD24⁺. Arrows indicate cell types as in (A). (F) Confocal image (merged channels are color coded as in A–E) from a different tissue area showing multilabeled breast tissue containing the stromal cell types as described in A–E, as well as ductules and numerous adjacent ALDH1⁺ CD24⁺ cells with weak membranous CD44 reactivity. Scale bars = 10 µm.

Abbreviation: DAPI, 4',6-diamidino-2-phenylindole.

Statistical analysis

In the statistical evaluations, Fisher’s exact test was used for associations and Spearman’s rho test for correlations, both were two-tailed, and $P<0.05$ was considered significant. The analyses were performed using SPSS 20.0.0 software (IBM Corporation, Armonk, NY, USA).

Results

Patients included in the study

Table 2 provides an overview of the patients who were included in the study, and they were categorized according to risk factors for breast cancer. The material that was ultimately evaluated originated from the following subjects: seven patients with a *BRCA1* mutation who underwent surgery for invasive breast carcinoma; ten noncancer patients who underwent mastectomy due to a *BRCA1* mutation; four noncancer mastoplasmy patients with a family history of breast cancer but no *BRCA1/2* mutation; and 19 noncancer mastoplasmy patients with no family history of breast cancer (served as normal controls).

Distribution and morphology of ALDH1⁺ stromal cells

It was observed that the majority of ALDH1⁺ cells in TDLUs are located in the stroma, not in the epithelial tree (Figure 2). Cells with the following immunophenotypes were identi-

fied most often (given in decreasing order of frequency): ALDH1⁺ CD44⁺ CD24⁻ cells, ALDH1⁺ CD44⁻ CD24⁻ cells, and ALDH1⁻ CD44⁺ CD24⁻ cells. Distribution of these immunophenotypes varied between the patient groups, which has been detailed in later sections.

ALDH1⁺ spindle-shaped/polygonal and round/oval stromal cell types

Most ALDH1⁺ cells located in TDLU stroma were spindle shaped or had a polygonal cell body with one or a few cytoplasmic extensions (Figure 3). In many areas, parallel strands of ALDH1⁺ stromal cells were tightly arranged around a single duct, a ductule, or an entire TDLU. In some areas, these cells encircled the periphery of small blood vessels. The highest density of the ALDH1⁺ spindle-shaped/polygonal cell type was at the border between TDLU stroma and generic stroma adjacent to TDLUs. Large quantities of long and thin ALDH1⁺ cytoplasmic processes were detected in many samples, and inasmuch as this appearance corresponded to

Table 2 Genetic and hormonal characteristics, and cancer status of the patients

Patient characteristics	All patients (n=40)	Patients with a BRCA1 mutation (n=17)	Patients with no BRCA1/2 mutation (n=23)
Age in years, median (range) ^a	28 (20–50)	34 (23–43)	24 (20–50)
Parous			
Yes	18	12	6
No	20	3	17
Unknown	2	2	0
Contraceptive pill at the time of surgery			
Yes	13	5	8
No	25	10	15
Unknown	2	2	0
Family history of breast cancer			
Yes	21	17	4
No	19	0	19
Unknown	0	0	0
Synchronous breast cancer			
Yes	7	7	0
No	21	10	23
Unknown	0	0	0

Note: ^aAll patients were premenopausal.

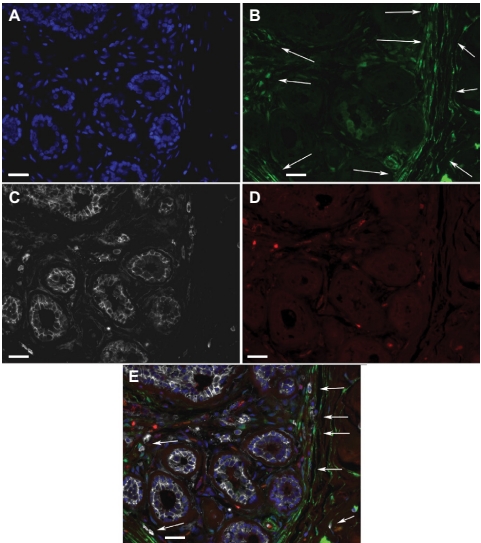


Figure 2 ALDH1⁺ cells in TDLUs.
Notes: Fluorescence microscope images of a triple-labeled TDLU from benign breast tissue with the following color coding: (A) DAPI nuclear staining (blue); (B) ALDH1 (green); (C) CD44 (white); (D) CD24 (red). (E) A digitally composed image showing all channels merged. Most of the cells located basally in ductules are ALDH1⁺ CD44⁺, whereas some adluminal cells are ALDH1⁺ CD44⁺ and none are CD24⁺. In stroma, elongated ALDH1⁺ cells are seen between the ductules, and many such cells are present in the junction between TDLU stroma and generic connective tissue of the breast (arrows). Scale bars = 20 μ m.
Abbreviations: DAPI, 4',6-diamidino-2-phenylindole; TDLUs, terminal duct-lobular units.

the cytoplasmic extensions of cells that exhibited a spindle or polygonal shape, we chose to use the collective term “spindle-shaped/polygonal cells”. ALDH1⁺ spindle-shaped/polygonal cells that were CD44⁺ or CD44⁻, as well as numerous ALDH1⁻ CD44⁺ spindle-shaped/polygonal cells, were identified in one or more TDLUs in almost all the specimens (38/40, 95%). No CD24⁺ spindle-shaped/polygonal cells were detected in any specimen.

The morphological definition of ALDH1⁺ round/oval cells describes cells in stroma which were round or oval in shape and had small round nuclei and granular cytoplasm (Figure 4). These cells were observed in one or more TDLUs in approximately half of the specimens (23/40, 57%). The presence of ALDH1⁺ round/oval cells that were also CD44⁺ varied from 29% to 63% between the different risk-factor patient groups.

CD24⁺ round/oval cells were present in most of the specimens (33/40, 82%), and the majority of these cells were ALDH1⁻ and CD44⁻. CD24⁺ round/oval cells that were negative for the other markers were found in a minority of the specimens (14/40, 35%; Figure 5). ALDH1⁺ round/oval stromal cells that were CD24⁺ were observed in few specimens (3/40, 15%).

Triple immunofluorescence labeling of the two stromal cell types in relation to clinical risk groups

Immunofluorescence data for the individual patient risk groups are presented in Table 3 and are described in the following sections.

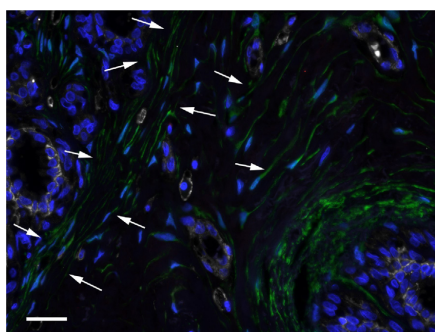


Figure 3 ALDH1⁺ spindle-shaped/polygonal cells in TDLU stroma (arrows).
Notes: DAPI nuclear staining (blue), ALDH1 (green), CD44 (white), and CD24 (red). Scale bar = 20 μ m.
Abbreviations: DAPI, 4',6-diamidino-2-phenylindole; TDLU, terminal duct-lobular unit.

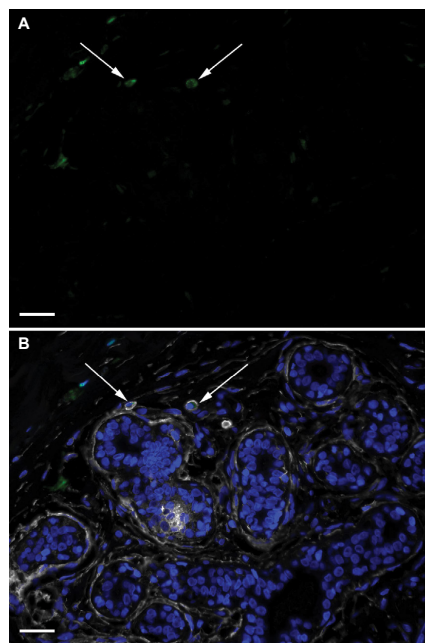


Figure 4 ALDH1⁺ round/oval-shaped cells in TDLU stroma.
Notes: DAPI nuclear staining (blue) and labeling of ALDH1 (green), CD44 (white), and CD24 (red). (A) A single-channel image depicting ALDH1⁺ round/oval cells (arrows). (B) A composite image with all channels demonstrating that the ALDH1⁺ round/oval cells are positive for CD44 but not for CD24 (arrows). Scale bars = 20 μ m.
Abbreviations: DAPI, 4',6-diamidino-2-phenylindole; TDLU, terminal duct-lobular unit.

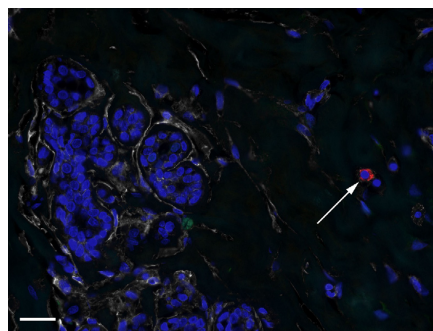


Figure 5 CD24⁺ cells in TDLU stroma.
Notes: DAPI nuclear staining (blue) and labeling of ALDH1 (green), CD44 (white), and CD24 (red). The image depicts a CD24⁺ cell (arrow) exhibiting no CD44 or ALDH1 positivity. Scale bar = 20 μ m.
Abbreviations: DAPI, 4',6-diamidino-2-phenylindole; TDLU, terminal duct-lobular unit.

Table 3 Immunohistological results for the patient groups

Immunophenotype	Spindle-shaped/polygonal cells		Round/oval cells	
	ALDH1 ⁺ CD44 ⁺ CD24 ⁻	ALDH1 ⁺ CD44 ⁻ CD24 ⁻	ALDH1 ⁺ CD44 ⁺ CD24 ⁻	ALDH1 ⁺ CD44 ⁻ CD24 ⁻
Family history (n=21)	19 (90%)	16 (76%)	6 (29%)	2 (11%)
No family history (n=19)	18 (95%)	14 (74%)	12 (63%)	2 (10%)
BRCA1 mutation (n=17)	15 (88%)	12 (71%)	6 (35%)	2 (12%)
No BRCA1 mutation (n=23)	22 (96%)	18 (78%)	12 (52%)	2 (9%)
Nulliparous (n=20)	18 (90%)	12 (60%)	10 (50%)	1 (5%)
Parous (n=18)	17 (94%)	17 (94%)	6 (33%)	3 (17%)
Age <28 years (n=19)	17 (89%)	14 (74%)	9 (47%)	2 (11%)
Age ≥28 years (n=21)	20 (95%)	16 (76%)	9 (43%)	2 (11%)

Note: The table presents the number of patients in each clinical category whose sample contained “any” cells exhibiting the investigated immunophenotypes.

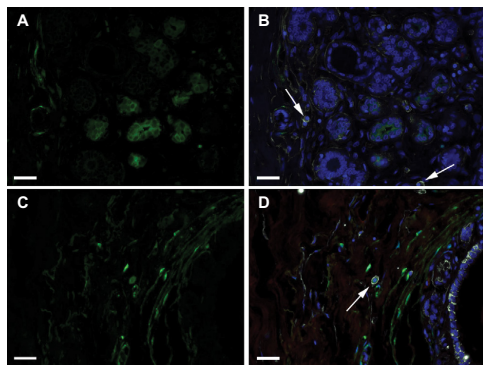


Figure 6 Round/oval cells according to family history.

Notes: DAPI nuclear staining (blue) and labeling of ALDH1 (green), CD44 (white), and CD24 (red). (A)–(B) Images showing the absence of ALDH1⁺ CD44⁺ CD24⁻ round/oval cells in a TDLU from a woman with a family history of breast cancer. Arrows indicate ALDH1⁺ CD44⁺ CD24⁻ cells. (C)–(D) Images illustrate an ALDH1⁺ CD44⁺ CD24⁻ round/oval-shaped cell (arrow) in a TDLU from a woman with no family history of breast cancer. (A) and (C) show only the ALDH1⁺ channel, and (B) and (D) show all four channels merged. Scale bars = 20 μm.

Abbreviations: DAPI, 4',6-diamidino-2-phenylindole; TDLU, terminal duct-lobular unit.

ALDH1⁺/CD44⁺/CD24⁻ cells

Round/oval stromal cells with the ALDH1⁺/CD44⁺/CD24⁻ immunophenotype were present in the TDLU stroma of specimens from six of the 21 women with a family history of breast cancer (Figure 6A and B) and from eleven of the 19 women without a family history (Figure 6C and D; two-tailed Fisher's exact test, $P=0.055$; two-tailed Spearman's rho test, $P=0.028$). Spindle-shaped/polygonal cells with this immunophenotype showed no associations or correlations with risk factors.

ALDH1⁺/CD44⁻/CD24⁻ cells

Spindle-shaped/polygonal stromal cells with the ALDH1⁺/CD44⁻/CD24⁻ immunophenotype (Figures 2, 3, and 6) were present in specimens from 12 of the 20 nulliparous women and from 17 of the 18 parous women (two-tailed Fisher's

exact test, $P=0.021$; two-tailed Spearman's rho test, $P=0.009$). No associations or correlations with breast cancer risk factors were found for round/oval cells with this immunophenotype.

ALDH1⁻/CD44⁺/CD24⁻ cells

Spindle-shaped/polygonal stromal cells with the ALDH1⁻/CD44⁺/CD24⁻ immunophenotype were found in 35 specimens (87%), and round/oval cells with this immunophenotype were observed in 26 specimens (65%). No associations or correlations were found between these cell types and breast cancer risk factors.

Discussion

The current study aimed to morphologically identify ALDH1 cell types in histologically normal breast stroma and to investigate their SC characteristics, ie, their expression of CD24 and CD44. We identified two morphologically different types of ALDH1-expressing cells in the stroma of histologically benign female breast tissue, which we designated spindle-shaped/polygonal cells and round/oval cells. The absence of stromal ALDH1⁺ cells was noted more often in patient groups with risk factors for breast cancer than in the group with no known risk factors for such disease. This indicates that the presence of ALDH1⁺ cells in breast stroma might be a beneficial factor in the context of cancer risk. However, although ALDH1 is a marker for SCs, the mentioned findings should not be interpreted as a suggestion that SCs in stroma protect against breast cancer, because most ALDH1⁺ cells are in fact not SCs.^{3,10,11}

A significant number of specimens from the nulliparous patients lacked ALDH1⁺/CD44⁻/CD24⁻ spindle-shaped/polygonal cells, indicating a relation to cancer risk since nulliparity is a known risk factor for breast cancer.¹² This finding is also interesting considering that it was recently observed that ALDH1⁺ cells of spindle or polygonal shape are frequently absent in stroma of histologically normal mucosa of patients with bladder cancer.¹⁰

The round/oval cells with the putatively stringent SC immunophenotype ALDH1⁺/CD44⁺/CD24⁻ were often absent in TDLU stroma of patients with a family history of breast cancer. Such cells had mononuclear leukocyte-like morphology with a granular cytoplasm and thus resembled mast cells. A previous evaluation of the same material indicated that ~50% of ALDH1⁺ round/oval cells in stroma were negative for the pan-leukocyte marker CD45.⁶ These cell types thus correspond to the recently described morphology of mesenchymal SCs of the multilineage-differentiating stress-enduring (Muse) type,⁵ which was discerned using markers other than those employed in the present study. It remains to be determined whether ALDH1⁺/CD44⁺/CD24⁻ round/oval cells in breast stroma are actually mesenchymal SCs.

It has been observed that stromal ALDH1 expression is lower in malignant breast tumors than in benign conditions,^{13,14} and stromal ALDH1 expression in malignant tumors has been found to be associated with better survival.¹⁵ Our earlier study of ALDH1⁺ ductular cells located in areas of benign breast tissue did not reveal any statistically significant association with concurrent cancer.⁷ The current investigation of benign breast tissue did not address ALDH1 expression in patients with cancer per se due to the low number of subjects.

Conclusion

In this study, spindle-shaped/polygonal and round/oval ALDH1⁺ cells were absent in benign stroma of a significant number of women at risk of breast cancer. The round/oval cell type carried the putatively stringent SC immunophenotype ALDH1⁺/CD44⁺/CD24⁻, whereas the spindle-shaped/polygonal cells did not. The low presence of ALDH1⁺ cells in benign mammary stroma of women at risk of breast cancer agrees with recently reported data indicating that high ALDH1 expression in breast cancer stroma is an independent favorable prognostic marker. The associations and correlations found in the current study of ALDH1⁺ stromal cells are the reverse of what our group has previously observed regarding ALDH1⁺ epithelial cells, which emphasizes the need to address epithelial and stromal cells separately, and also underlines the importance of histological correlation. Clearly, multi-antibody in situ investigations need to be performed to further elucidate the relationship between SC markers and the risk of breast cancer.

Acknowledgments

This study was supported by grants from the Swedish Cancer Society, the Swedish Research Council, and Skåne University Hospitals. The authors also acknowledge financial support

from the European Research Council (Advanced Grant ERC-2011-294576). The authors thank ImaGene-iT AB (Lund, Sweden) for experimental support, LRI AB (Lund, Sweden) for support with microscope equipment, and Patricia Ödman for language editing.

Author contributions

All the authors contributed to conceiving and designing the experiments. HO and HJ contributed to patient data. BLI performed the experiments. BLI analyzed the data. BLI wrote the paper. All the authors contributed to the critical revision of the paper and accepted the final version.

Disclosure

The authors report no conflicts of interest in this work.

References

- Hongbao M, Shen C. Review of stem cell studies. *Nat Sci*. 2007;5:45–65.
- Al-Hajj M, Wicha MS, Benito-Hernandez A, Morrison SJ, Clarke MF. Prospective identification of tumorigenic breast cancer cells. *Proc Natl Acad Sci U S A*. 2003;100(7):3983–3988.
- Ginestier C, Hur MH, Charafe-Jauffret E, et al. ALDH1 is a marker of normal and malignant human mammary stem cells and a predictor of poor clinical outcome. *Cell Stem Cell*. 2007;1(5):555–567.
- Yoshioka T, Umekita Y, Ohi Y, et al. Aldehyde dehydrogenase 1 expression is a predictor of poor prognosis in node-positive breast cancers: a long-term follow-up study. *Histopathology*. 2011;58(4):608–616.
- Wakao S, Kitada M, Kuroda Y, et al. Multilineage-differentiating stress-enduring (Muse) cells are a primary source of induced pluripotent stem cells in human fibroblasts. *Proc Natl Acad Sci U S A*. 2011;108(24):9875–9880.
- Isfoss BL, Holmqvist B, Alm P, Olsson H. Distribution of aldehyde dehydrogenase 1-positive stem cells in benign mammary tissue from women with and without breast cancer. *Histopathology*. 2012;60(4):617–633.
- Isfoss BL, Holmqvist B, Jernström H, Alm P, Olsson H. Women with familial risk for breast cancer have an increased frequency of aldehyde dehydrogenase expressing cells in breast ductules. *BMC Clin Pathol*. 2013;13(1):28.
- Liu S, Wang D, Sun Y, et al. Breast cancer stem cells transition between epithelial and mesenchymal states reflective of their normal counterparts. *Stem Cell Rep*. 2014;2(1):78–91.
- Honeth G, Lombardi S, Ginestier C, et al. Aldehyde dehydrogenase and estrogen receptor define a hierarchy of cellular differentiation in the normal human mammary epithelium. *Breast Cancer Res*. 2014;16(3):R52.
- Friedman SL. Hepatic stellate cells: protean, multifunctional, and enigmatic cells of the liver. *Physiol Rev*. 2010;88(1):125–172.
- Isfoss BL, Busch C, Hermelin H, et al. Stem cell marker-positive stellate cells and mast cells are reduced in benign-appearing bladder tissue in patients with urothelial carcinoma. *Virchows Arch*. 2014;464(4):473–488.
- Kelsey JL, Gammon MD, John EM. Reproductive factors and breast cancer. *Epidemiol Rev*. 1993;15(1):36–47.
- Resetskova E, Reis-Filho JS, Jain RK, et al. Prognostic impact of ALDH1 in breast cancer: a story of stem cells and tumor microenvironment. *Breast Cancer Res Treat*. 2010;123(1):97–108.
- Schwartz T, Stark A, Pang J, et al. Expression of aldehyde dehydrogenase 1 as a marker of mammary stem cells in benign and malignant breast lesions of Ghanian women. *Cancer*. 2013;119(3):488–494.
- Bednarz-Knoll N, Nastaly P, Zaczek A, et al. Stromal expression of ALDH1 in human breast carcinomas indicates reduced tumor progression. *Oncotarget*. 2015;6(29):26789–26803.

Breast Cancer - Targets and Therapy**Dovepress****Publish your work in this journal**

Breast Cancer - Targets and Therapy is an international, peer-reviewed open access journal focusing on breast cancer research, identification of therapeutic targets and the optimal use of preventative and integrated treatment interventions to achieve improved outcomes, enhanced survival and quality of life for the cancer patient.

The manuscript management system is completely online and includes a very quick and fair peer-review system, which is all easy to use. Visit <http://www.dovepress.com/testimonials.php> to read real quotes from published authors.

Submit your manuscript here: <https://www.dovepress.com/breast-cancer--targets-and-therapy-journal>