



LUND UNIVERSITY

PET in the evaluation of head and neck cancer treatment - management of the neck

Sjövall, Johanna

2015

[Link to publication](#)

Citation for published version (APA):

Sjövall, J. (2015). *PET in the evaluation of head and neck cancer treatment - management of the neck*. [Doctoral Thesis (compilation), Otorhinolaryngology (Lund)]. Department of Otorhinolaryngology, Lund University.

Total number of authors:

1

General rights

Unless other specific re-use rights are stated the following general rights apply:

Copyright and moral rights for the publications made accessible in the public portal are retained by the authors and/or other copyright owners and it is a condition of accessing publications that users recognise and abide by the legal requirements associated with these rights.

- Users may download and print one copy of any publication from the public portal for the purpose of private study or research.
- You may not further distribute the material or use it for any profit-making activity or commercial gain
- You may freely distribute the URL identifying the publication in the public portal

Read more about Creative commons licenses: <https://creativecommons.org/licenses/>

Take down policy

If you believe that this document breaches copyright please contact us providing details, and we will remove access to the work immediately and investigate your claim.

LUND UNIVERSITY

PO Box 117
221 00 Lund
+46 46-222 00 00

PET in the evaluation of head and neck cancer treatment

management of the neck

Johanna Sjövall



LUND
UNIVERSITY

DOCTORAL DISSERTATION

by due permission of the Faculty of Medicine, Lund University, Sweden.

To be defended at

The Lecture Hall at the Department of Oncology and Radiation Physics
on September 25, 2015, at 09.00.

Faculty opponent

Professor Remco De Bree

Department of Otolaryngology/Head and Neck Surgery,
VU University Medical Center
Amsterdam, The Netherlands

Organization LUND UNIVERSITY Author(s): Johanna Sjövall	Document name DOCTORAL DISSERTATION	
	Date of issue September 25, 2015	
	Sponsoring organization	
Title and subtitle PET in the evaluation of head and neck cancer treatment – management of the neck		
Abstract <p>The treatment for head and neck squamous cell carcinoma (HNSCC) is surgery or (chemo)radiotherapy +/- surgery. Side effects related to therapy are long lasting and adversely affects quality of life. The incidence of oropharyngeal cancer is increasing and patients commonly present an advanced tumour stage with neck metastases at the time of diagnosis. The treatment protocol previously comprised radical (chemo)radiotherapy and surgery <i>i.e.</i>, neck dissection. However, persistent tumour cells after (chemo)radiotherapy are found in only 20-30% of the neck specimens and a systemic neck dissection have therefore been questioned.</p> <p>The general aim of the present thesis was to explore if positron emission tomography (PET) could be used for radiotherapy response evaluation and adequately determine the need for further therapeutic interventions in patients with HNSCC treated with curative intent. The overall clinical goal with the thesis was to reduce the treatment related morbidity by avoiding unnecessary neck dissection without risking an increase in failures.</p> <p>In studies I and III we evaluated the performance of PET as a tool for assessment of therapy response and the consequences of omitting neck dissections in patients with a complete metabolic response after treatment. Study II focused on therapy response evaluation of the primary site. Lastly, study IV evaluated three different methods for interpreting PET scans in head and neck cancer patients.</p> <p>In conclusion, neither nodal control nor survival is compromised by omitting neck dissection in patients with a complete metabolic response after therapy. A physical examination, preferably supported with a PET scan, is feasible and sufficient for an evaluation of the primary site response. Qualitative interpretation with visual inspection of PET scans is a satisfactory method to assess tumour metabolism and the use of a 5-point Likert scale is a promising tool to reduce the number of scans judged as equivocal to a minimum.</p>		
Key words: Head and neck cancer, positron emission tomography, radiotherapy, treatment evaluation		
Classification system and/or index terms (if any)		
Supplementary bibliographical information	Language: English	
ISSN 1652-8220	ISBN 978-91-7619-161-3	
Recipient's notes	Number of pages 148	Price
	Security classification	

I, the undersigned, being the copyright owner of the abstract of the above-mentioned dissertation, hereby grant to all reference sources permission to publish and disseminate the abstract of the above-mentioned dissertation.

Signature



Date

2015/08/13

PET in the evaluation of head and neck cancer treatment

management of the neck

Johanna Sjövall



LUND
UNIVERSITY

Copyright Johanna Sjövall

Faculty of Medicine, Lund University, Department of Clinical Sciences

ISBN 978-91-7619-161-3

ISSN 1652-8220

Printed in Sweden by Media-Tryck, Lund University

Lund 2015



To whom it may concern

Aime la vérité, mais pardonne à l'erreur

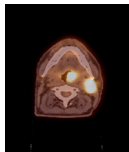

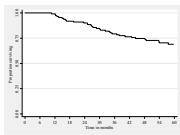
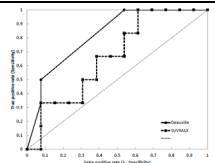
Voltaire

CONTENTS

THESIS AT A GLANCE	7
LIST OF PAPERS	9
Related publication	10
ABBREVIATIONS	11
SUMMARY	13
SUMMARY IN SWEDISH	15
SVENSK SAMMANFATTNING	15
BACKGROUND	17
HEAD AND NECK CANCER	17
Epidemiologic situation	18
Risk factors for OPC	19
Symptoms and work-up	20
Prognostic and predictive factors	21
Primary treatment	22
Assessment of therapy response and surveillance	25
Treatment of residual or recurrent tumour	26
NECK DISSECTION	26
POSITRON EMISSION TOMOGRAPHY	30
Tumour and FDG metabolism	31
PET development	34
The scanning procedure	34
Assessment of PET scans	35
PET in HNSCC	39
Radiotracers for potential use in head and neck cancer	43

THE CLINICAL PROBLEM	45
OBJECTIVES	47
MATERIALS AND METHODS	49
Patients	49
Ethical aspects	49
Methods	50
Therapy and follow-up	52
Statistics	53
RESULTS	57
Paper I	57
Paper II	61
Paper III	63
Paper IV	65
DISCUSSION	69
FUTURE PERSPECTIVES AND FINAL CONCLUSIONS	75
Conclusions based on this thesis	76
ACKNOWLEDGEMENTS	77
REFERENCES	79

THESIS AT A GLANCE

PAPER	QUESTION	METHOD	RESULT		CONCLUSION
I	Does a PET scan, 6 weeks after RT, adequately select patients in whom a neck node dissection can be safely omitted?	RT outcome was evaluated with PET to decide if a posttherapy neck dissection was indicated.	76% of the patients were safely spared a neck dissection. 11% were correctly scheduled for surgery.	 <p>Hypermetabolic primary tumour and node metastasis</p>	PET evaluation of treatment can be used to select patients where surgery is needed. PET should be scheduled later than 6 weeks after therapy.
II	What is the accuracy of PET in assessing primary site response after RT?	PET results regarding the primary tumour was compared with clinical assessment of therapy response.	PET accuracy in evaluation of the primary site was 78%.	 <p>Endoscopy under anaesthesia</p>	A protocol involving routine endoscopy with biopsy under anaesthesia for RT response assessment is superfluous.
III	Is a negative post CRT PET correlated to long-term neck control and justifies omission of neck dissection?	Medical charts from patients previously included in a prospective study were reviewed for long-term outcome	After a median follow-up of 62 months the NPV and PPV for the restaging PET was 97.1% and 77.8% respectively.	 <p>5-year overall survival rate, 69%.</p>	PET-negative neck nodes after CRT can be observed with acceptable nodal control and overall survival.
IV	Does a 5-point Likert scale improve visual inspection of posttreatment PET scans?	PET scans, initially evaluated by visual inspection were revised according to a Likert scale	79% of the equivocal PET scans could be adequately judged as responders or not by using a Likert scale.	 <p>ROC analysis of Likert scale and SUVmax</p>	A 5-point Likert scale is a promising tool to improve the adequacy of PET reports.

Picture paper I with permission from Dept. of nuclear medicine, Skåne University Hospital, Lund, Sweden. Picture paper II with permission from Dr Nilsson, Dept. of ORL-HNS, Skåne University Hospital, Lund. Picture paper III, Sjövall et al. Oral Oncology, 2015, with permission. Picture paper IV, submitted.

LIST OF PAPERS

The thesis is based on the following papers and they will be referred to in the text by their Roman numerals.

- I

Sjövall J, Wahlberg P, Almquist H, Kjellén E, Brun E

A prospective study of positron emission tomography for evaluation of neck node response 6 weeks after radiotherapy in patients with head and neck squamous cell carcinoma

Head and Neck, 2015, Feb 26. Epub ahead of print.

- II

Sjövall J, Brun E, Almquist H, Kjellén E, Wahlberg P

Radiotherapy response in head and neck cancer – evaluation of the primary tumour site

Acta Oto-laryngologica, 2014, June; 134(6):646-651

- III

Sjövall J, Chua B, Pryor D, Burmeister E, Foote M, Panizza B, Burmeister B, Porceddu, S

Long-term results of positron emission tomography-directed management of the neck in node-positive head and neck cancer after organ preservation therapy

Oral Oncology, 2015, March; 51(3):260-266

- IV

Sjövall J, Bitzén U, Kjellén E, Nilsson P, Wahlberg P, Brun E

Qualitative interpretation of positron emission tomography scans using a Likert scale to assess neck node response to radiotherapy in head and neck cancer

Submitted

Reprints were made with permissions from Head and Neck (I), Acta Oto-laryngologica (II) and Oral Oncology (III).

Related publication

- Siikanen J*, Sjövall J*, Forslid A, Brun E, Bjurberg M, Wennerberg J, Ekblad L, Sandell A

*contributed equally

An anesthetic method compatible with ^{18}F -FDG-PET studies in mice

American Journal of Nuclear Medicine and Molecular Imaging, 2015;5(3):270-277

ABBREVIATIONS

ANED	alive no evidence of disease
AUC	area under the curve
AWD	alive with disease
CI	confidence interval, 95% CI are presented in the text
CRT	chemoradiotherapy
CT	computed tomography
CUP	cancer of unknown primary, in this thesis limited to lymph node metastases of the neck
DID	dead of intercurrent disease
DOD	dead of disease
DFS	disease free survival (=failure free survival)
DSS	disease specific survival
EGFR	epidermal growth factor receptor
FDG	2-deoxy-2-[¹⁸ F]fluoro-D-glucose
GLUT	glucose transporters
GTV	gross tumour volume
Gy	Gray, unit for absorbed radiation dose, 1 Gy=1joule/kg
HNSCC	head and neck squamous cell carcinoma
HPV	human papilloma virus
IHC	immunohistochemistry
IJV	internal jugular vein
IMRT	intensity modulated radiation therapy
LRC	locoregional control
MDT	multidisciplinary team

MR _{glu}	metabolic rate of glucose
MRI	magnetic resonance imaging
MTV	metabolic tumour volume
ND	neck dissection
NPV	negative predictive value
OPC	oropharyngeal cancer
OS	overall survival
PCR	polymerase chain reaction
PERCIST	PET Response Criteria in Solid Tumours
PET	positron emission tomography (in this thesis FDG-PET in combination with CT if not specified otherwise)
PF	a chemotherapy regimen, cisplatin 5-fluorouracil
PPV	positive predictive value
RECIST	Response Evaluation Criteria in Solid Tumours
ROC	receiver operating characteristics
ROI	region of interest
RT	radiotherapy
SCC	squamous cell carcinoma
SCM	sternocleidomastoid muscle
SUV	standardized uptake value
TLG	total lesion glycolysis
TNM	a classification system for malignant tumours. T – size and/or extension of primary tumour, N – involvement of regional lymph nodes, M – presence of distant metastases

SUMMARY

Head and neck squamous cell carcinoma (HNSCC) comprises malignancies of the upper aerodigestive tract. A subgroup of tumours, oropharyngeal cancer (OPC), has a rising incidence with an increasing proportion of patients with human papilloma virus (HPV)-associated tumours and without traditional HNSCC risk factors like smoking and excessive alcohol intake. The tumours are usually diagnosed in an advanced stage and neck node metastases are common at the time of diagnosis. The curatively intended treatment for OPC with neck node metastasis is radiotherapy (RT) with or without chemotherapy. Traditionally, the RT has been followed by a neck dissection (ND) but persistent tumour cells after RT are found in only 20 to 30 percent of the neck specimens. The combination of therapies, RT and surgery cause adverse effects and have a negative long-term impact on quality of life. The overall clinical goal with the present thesis was to reduce the treatment related morbidity by avoiding unnecessary ND without risking an increase in recurrences. We aimed to explore if positron emission tomography (PET), a nuclear imaging modality, could be used for RT response evaluation and determine the need for further therapeutic interventions.

In the first study we evaluated neck node response to RT with an early PET, six weeks after the completion of treatment, in 105 eligible patients with HNSCC. The majority of the included patients were diagnosed with HPV-positive OPC. The PET result determined the management of the neck, ND versus observation. We were concerned about persistent tumour cells not being visualized on the PET scan scheduled as early as six weeks after treatment and therefore a second scan was performed 18 weeks posttreatment. The positive predictive value (PPV) and negative predictive value (NPV) for PET six weeks after treatment was 56% and 94%, respectively. With a follow-up period of 3.5 years we experienced five isolated neck node failures and the 3.5-year overall survival (OS) rate was 84%.

Based on the study population from the first study, we aimed to evaluate the diagnostic accuracy of PET in assessing primary tumour site response after therapy. Eighty-two patients were eligible for analysis. The accuracy was 78%, the PPV 6% and NPV 100%. Only one patient turned out to have a residual tumour at the primary site and it makes the interpretation of the PET accuracy difficult. However, our traditional method of evaluating primary tumour site response, endoscopy with biopsies under general anaesthesia, can be considered superfluous.

The third study was a long-term follow-up of PET-guided management of the neck in a study population of 112 eligible patients. The neck node response to chemoradiotherapy (CRT) was evaluated by PET and computed tomography (CT) 12 weeks after therapy. The PET result determined the management of the neck, ND versus observation, regardless of the result from the CT scans. The follow-up time was 62 months and one isolated nodal relapse was diagnosed. PPV and NPV for PET 12 weeks after CRT was 78% and 97%, respectively. The 5-year OS rate was 69%.

Last, we focused on different methods of PET scan evaluations. All PET scans in the studies had been qualitatively interpreted by visual inspection. According to the PET results most patients could be categorized into responders or non-responders to RT. However, 18% of the PET scans had been classified as equivocal. We re-evaluated all PET scans from the 105 patients included in study one. The PET scans were re-assessed according to a 5-point Likert scale and with a semiquantitative method, maximum standardized uptake value (SUVmax). The Likert scale could adequately classify 15/19, 79%, of the equivocal PET scans into groups of responders and non-responders.

In conclusion, PET-guided management of the neck following organ preservation therapy is an appropriate way to spare ND in patients with node-positive HNSCC. Observing PET-negative nodes compromises neither nodal control nor OS but the PET should be scheduled later than six weeks after therapy to optimize accuracy.

To evaluate primary tumour response to RT we can consider planned endoscopy under anaesthesia with biopsies superfluous.

The interpretation of PET scans with visual inspection is a satisfactory way to evaluate tumour response to RT but the use of a Likert scale seems to improve the assessment of PET scans judged as equivocal.

SUMMARY IN SWEDISH

SVENSK SAMMANFATTNING

I gruppen huvudhalscancer ingår tumörer i övre luftvägar och svalg. Riskfaktorer för huvudhalscancer är rökning och alkoholöverkonsumtion. Under de senaste 20-30 åren har det skett en påtaglig ökning av insjuknandet, 4-5% per år, i det som kallas orofaryngeal cancer. Orofaryngeal cancer utgår från mellansvalget; mandlar, tungbas och mjuka gommen. Ökningen sammanfaller med att man ser en uppgång i tumörer som anses associerade med humant papillomvirus och det är ett något yngre patientklientel, utan de ovan nämnda traditionella riskfaktorerna, som insjuknar.

Medianåldern för insjuknande är drygt 60 år. De flesta patienterna har spridning av sin tumör till lymfknotor på halsen vid tidpunkten för diagnos.

Strålbehandling, ibland med samtidig cellgiftsbehandling, ges till både modertumör och sjuka lymfknotor hos patienter där man syftar till bot. Tidigare behandlingsprotokoll inkluderar en utvärdering av strålbehandlingsresultatet. Patienten blir då sövd och man undersöker svalget och tar vävnadsprov. Om det inte finns någon kvarvarande tumör i svalget opereras lymfknotorna på halsen bort. Skulle det finnas tumör kvar i lymfknotorna så har patienten i och med operationen fått sin tilläggsbehandling.

Behandlingen är förknippad med såväl övergående akuta som sena, livslånga biverkningar. Sena biverkningar är sväljningsproblem och muntorrhet av varierande grad samt lokal påverkan på blodcirkulationen vilket kan ge läkningssvårigheter vid exempelvis tandingrepp och kirurgi i det strålade området. Nack/skulderproblem med inskränkt rörlighet och smärta är vanligt efter halsoperationen pga nervpåverkan, kraftig ärrbildning och stram vävnad. Kombinationen av strålbehandling och operation förvärrar problematiken och påverkar livskvalitén negativt.

Efter modern strålbehandling har man sett att i endast 20-30% av fallen finns det kvarvarande tumörceller i lymfknotorna på halsen och således kan man anta att upp till 80% av patienterna opereras utan någon vinst avseende sjukdomskontroll eller överlevnad. De får däremot biverkningar efter ingreppet.

Studierna i den här avhandlingen har primärt fokuserat på utvärdering av strålbehandlingseffekten och om vi på ett säkert sätt kan avstå från halsoperation i de fall där strålbehandlingen har haft fullgod effekt.

Hur ska man då utvärdera strålbehandlingseffekten? Vi har använt oss av en nuklearmedicinsk metod, positron emissions tomografi (PET). Med PET utnyttjar man det faktum att cancerceller har ett högt sockerbehov, högre än omkringliggande normala celler. Inför en PET-undersökning ges en injektion av en radioaktivt märkt sockeranalog till patienten. Cancercellerna tar upp förhållandevis mycket av det radioaktiva sockret och det kan detekteras av en PET-kamera. På PET-bilden ser man tumörer med högt upptag som starkt lysande områden vilket talar för hög aktivitet i tumören. Genom att jämföra PET-undersökningar gjorda före och efter strålbehandling kan man se om tumörområdena har "släckts".

I studierna har vi sett att PET är en bra metod för att detektera och utesluta kvarvarande tumörceller i halslymfknutor efter strålbehandling. Vi kan på ett säkert sätt avstå från halsoperation i de fall där tumörerna är "släckta" efter strålbehandlingen. Det tycks inte påverka risken för att få återfall av tumör i lymfknutorna på halsen och det tycks inte heller påverka överlevnaden på ett negativt sätt jämfört med om man rutinmässigt utför en halsoperation efter strålbehandling. Tidpunkten för utvärdering av strålbehandlingen med PET kan diskuteras och vi anser att man får ett säkrare resultat om man gör den närmare 12 jämfört med sex veckor efter strålbehandling.

Från våra resultat kan man också konstatera att modellen för utvärdering av eventuellt kvarvarande modertumör, sövning av patienten och vävnadsprov, är överdriven. Det är mycket ovanligt med en kvarvarande modertumör efter strålbehandlingen och en vanlig klinisk undersökning, eventuellt ihop med PET-undersökning är fullt tillräckligt. Vid misstanke om kvarvarande tumör kan ytterligare undersökningar genomföras.

Man kan använda olika metoder för att tolka och beskriva PET-bilder. Att göra en visuell bedömning är i de flesta fall fullt tillräckligt. Vi har dock konstaterat att PET-bilder med tumörer som är bedömda som "tveksamt släckta" kan omvärderas med hjälp av en 5-punkts skala. Man tycks med 5-punktsskalan kunna omklassificera bilderna som "släckta" eller "fortsatt förhöjd aktivitet" och således få ett säkrare svar.

BACKGROUND

HEAD AND NECK CANCER

Head and neck cancer comprises malignancies of the upper aerodigestive tract including the nasal cavity and the paranasal sinuses, oral cavity, pharynx, larynx, salivary glands and lymph node metastases in the neck with unknown primary (CUP). The pharynx is further separated in nasopharynx, oropharynx and hypopharynx, see figure 1.

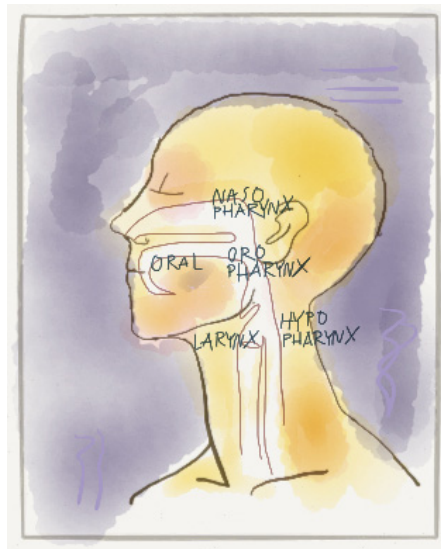


Fig 1

Anatomy of the head and neck (picture by Eva Brun).

In the literature, the definition of head and neck cancer is often limited to the oral cavity, oropharynx, hypopharynx and larynx since they share the same etiologic pattern. Even though the different sites are anatomically very close their prognosis and response to treatment are surprisingly different from one another. More than 85% of the head and neck tumours arise from squamous cells of the mucosal lining [1], thus called squamous cell carcinoma (SCC), see figure 2.

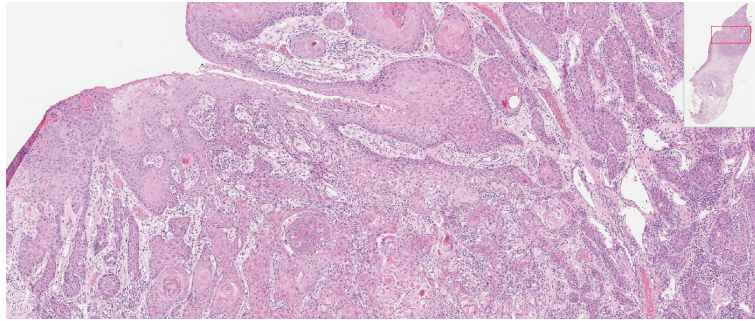


Fig 2

SCC of the oral mucosa. (Picture provided by Dr Andersson, Dept. of Pathology, Skåne University Hospital, Lund.)

The 5-year OS for head and neck cancer patients is quite poor, commonly reported as less than 50% but with heterogeneity between the sites [2]. However, Pulte and Brenner have reported an encouraging change in the overall 5-year relative survival rate over a ten-year span from 54.7% in the beginning of the 1990s to 65.9% in early 2000s. The greatest improvement in relative survival relates to patients with tonsillar cancer which was 39.7% in the beginning of the 1980s and 69.8% in the beginning of the 2000s [3]. According to figures from the Swedish head and neck cancer registry the relative 5-year OS is 61% for oral cavity cancer, 69% for OPC, 70% for nasopharyngeal cancer, 29% for hypopharyngeal cancer and 69% for laryngeal cancer. The present thesis is focusing primarily on patients with OPC, which emanates from oropharynx, the tonsils, base of tongue or the soft palate.

Epidemiologic situation

As an entity, cancer of the head and neck is globally the sixth most common cancer and there is a male to female preponderance [4] probably because of different exposure to known risk factors. The ratio differs between sites *e.g.*, lip/oral cavity the male to female ratio is 2:1 and for OPC it is 4.2:1. Compared with international figures [4], the Swedish male to female ratio is less pronounced. The Swedish National Board of Health and Welfare statistics database, year 2013, shows a male to female ratio for oral cavity SCC of 1.1:1 and 2.5:1 for OPC.

The incidence of OPC has increased substantially, approximately 5% per year, in the last decades, see figure 3.

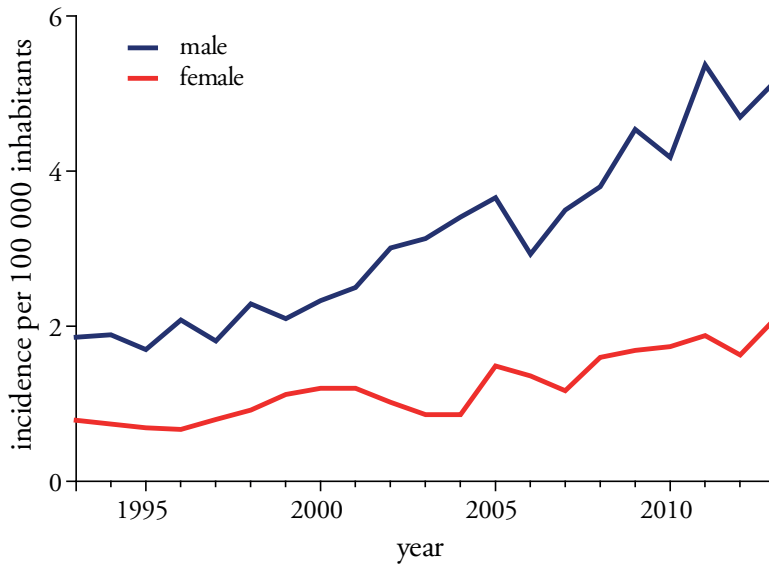


Fig 3

The development of OPC incidence for men and women in Sweden from 1993-2013. Crude rate/100 000 inhabitants. (The Swedish National Board of Health and Welfare, statistics data base 18-05-2015)

In a study from Stockholm, a 2.8-fold increase in the incidence of tonsillar cancer coincided with a 2.9-fold increase in the proportion of HPV-positive tumours between 1970 and 2002 [5]. The prevalence of HPV-positive OPC tumours differs regionally, ranging from 20-90% [6, 7].

Patients with HPV-positive OPC are younger, median age of 55 years at diagnosis compared with the HPV-negative patients, median age of diagnosis 65 years [5].

Risk factors for OPC

Tobacco and excessive alcohol consumption are well-established risk factors for developing HNSCC and the combined use increases the risk in a synergistic rather than additive fashion. With large daily intake, four alcoholic drinks/day and two packs of cigarettes the risk is increased 35-fold [8].

Poor dental hygiene is demonstrated to be an independent risk factor where a 5-fold increase for oral cancer and OPC has been demonstrated [9].

Lower levels of education, even after adjusting for known behavioural risk factors such as smoking and alcohol, pose greater than a 50% increased risk for head and neck cancer due to unidentified risk factors [10].

Inheritable genetic factors may also play a role and a family history of HNSCC increases the risk 1.7-fold if the malignancy is diagnosed in a first degree relative. An additional explanation may of course be similar alcohol and smoking habits [11]. However, different types of epigenetic variations and genetic polymorphism are associated with a modest increase in HNSCC susceptibility but none of them can be used as a single biomarker of genetic predisposition for HNSCC [12].

HPV infection is considered a major risk factor for a subset of oropharyngeal tumours [13]. Only a few of the numerous subtypes of HPV, most commonly HPV 16 and 18, are self-sufficient to induce carcinogenesis even though an infection as such is not sufficient to induce a malignant conversion [14]. HPV promotes dysregulated cell cycle progression and the inhibition of apoptosis by coding for proteins that inactivates p53 and the retinoblastoma protein [15]. A high life time number of vaginal and oral sex-partners is associated with HPV-positive OPC [16].

Symptoms and work-up

Frequently occurring symptoms in HNSCC are sore throat, ulcers, dysphagia, unilateral ear pain, hoarseness and a painless lump in the neck [17]. The symptoms are sometimes mild and also common in infectious diseases and this in combination with a low incidence of HNSCC might explain patient's delay in seeking care and doctor's delay in diagnosis. More than 50% of the patients present an advanced stage of HNSCC at the time of diagnosis [2]. Patients with HPV-positive tumours typically present a lower T classification but a higher nodal classification compared with patients with HPV-negative tumours [18, 19].

To confirm the diagnosis of head and neck cancer a thorough physical examination is performed, sometimes under anaesthesia, followed by biopsies of the primary tumour and fine needle aspiration of suspected lymph nodes for microscopic analysis. Various imaging techniques such as ultrasound, contrast enhanced CT, magnetic resonance imaging (MRI) and PET are used to define and stage the extent of the disease.

Human papilloma virus

Tumours are analysed for the presence of HPV. Several methods are being used which might explain some of the variability in reported prevalence. Real-time polymerase chain reaction (PCR), end-point PCR and DNA detection with in situ hybridization are commonly used. Different methods of sample collection, tissue fixation methods and choice of primer sets are variables that also might influence results. Detection of viral transcripts E6/E7 mRNA with PCR and in situ hybridization is also a possibility. Real-time PCR is considered gold standard in assessing if the HPV virus is etiologically involved in the OPC. P16 is used as a surrogate marker of HPV induced oncogenesis and is up-regulated as an effect of the functional inactivation of the retinoblastoma protein [20, 21].

Immunohistochemistry (IHC) analysis of p16 is a convenient analysis. The concordance between HPV and p16 is excellent in OPC but less so in other sites [22]. The sensitivity of p16 in relation to HPV is reported to be 85 to 97% and the specificity 75 to 100% when a cutoff value of $\geq 70\%$ (cytoplasmic and nuclear staining) is used [23].

Prognostic and predictive factors

Prognostic factors

A prognostic factor provides information on the likely course of a disease in an untreated individual. The most important prognostic factors in HNSCC are the site and the stage based on the tumour, node and metastasis (TNM) classification. Histopathological information such as tumour depth, patterns of invasion and extra nodal spread affect prognosis as well [1, 24]. Furthermore, comorbidity, poor performance status and advancing age are factors associated with decreased OS but not with disease specific survival (DSS) [25-27].

Patients with HPV-positive tumours have better survival compared to patients with HPV-negative tumours [19, 28, 29].

Although a number of prognostic molecular markers are recognized in HNSCC, only p16 is considered a standalone marker for a favourable prognosis including locoregional control (LRC) and DSS [18].

Hypoxic regions are common within solid tumours and are a result of limited perfusion or diffusion. Hypoxia ($<10\text{mmHg}$) induces genes that are associated with a malignant phenotype that promotes stem cell maintenance, angiogenesis and invasion [30, 31].

Socioeconomic deprivation has a large negative effect on survival that could be due to a higher alcohol intake, adverse smoking habits and, hypothetically, patients delay in seeking care [32].

Predictive factors

A predictive factor is a factor able to identify a subpopulation of patients who most likely will respond to a certain kind of therapy.

No molecular marker has gained widespread clinical use for therapeutic decision making in HNSCC. Despite numerous attempts to find biological markers such as p16, expression of the epidermal growth factor receptor (EGFR), mutations of the p53 gene, tumour cell ploidy foretelling RT or chemotherapy response, the results remain disappointing. To date, the most promising marker to select the level of treatment strategy is p16. It is beyond the scope of this introduction to present the

comprehensive number of molecular markers that have been investigated and might be promising predictive markers of RT response either alone or in combination.

HPV/p16 positivity predicts excellent response to RT [33, 34]. Intrinsic mechanisms and the microenvironment including cells of the immune system might increase radiosensitivity [35]. A small subset of patients with HPV/p16 positive tumours does not reach complete tumour remission. Only the HPV induced oncoprotein E6*I isoform has been linked to radiosensitization [36] and one can speculate if HPV/p16 positive non-responders mainly express another isoform of the oncoprotein.

Hypoxia, usually heterogeneously within the tumour, dampens radiation toxicity and is thus a predictor of suboptimal RT response. In addition to decrease radiation sensitivity, hypoxia also contributes to chemoresistance [37, 38].

The prognostic and predictive abilities of PET will be discussed in the PET section.

Primary treatment

The mainstay for head and neck cancer treatment is surgery and/or RT +/- chemotherapy. In patients with early stage HNSCC, single modality treatment with surgery or RT is the therapy of choice but in more advanced cases a combination of therapies is usually recommended. The selected treatment for each patient depends on the tumour site, and an assessment of additional prognostic factors such as tumour stage and comorbidity.

Surgery

Surgery plays a large role in the treatment for HNSCC. The surgical procedures concern the primary tumour site and/or lymph nodes in the neck. Most of the procedures, more or less, influence important functions as swallowing, speech and/or neck and shoulder function. With the goal of maintaining intact organs and quality of life, the treatment paradigm has shifted towards organ preservation therapy, especially for certain diagnoses like OPC where former surgical technique was associated with severe morbidity. However, RT is also associated with long lasting adverse effects. Recent surgical improvements, advances in reconstructive surgery [39], the introduction of transoral robotic surgery [40, 41] and more selective procedures [42] might reintroduce surgical treatment as an option in small oropharyngeal tumours.

From a surgical point of view, the present thesis will focus on ND and specifically ND following organ preservation therapy.

Radiotherapy

In 1896, the year after the discovery of x-rays, the first cancer patients received treatment with ionizing radiation without much knowledge of the radiobiology

causing cell death. Ionizing radiation is “energy on the move” and can be transferred by particles or as electromagnetic radiation (photons). The photons prime interaction with the tissue is by the Compton effect where the photon collides with an electron, lose some of its energy and change direction. Photons are, by far, the most common type of radiation in the field of oncology. The photons interact with electrons in the tissue that cause damage of the DNA by chemical single- or double strand breaks. Complicated double strand breaks are irreparable and cause cell death. The damage is an effect of the direct ionization or by free radicals generated by the radiation of water molecules. Most of the single break DNA damage is rapidly repaired but mutations and other chromosomal aberrations can also cause a delayed cell kill, after a number of cell cycles, due to misrepair [43].

There is a dose-response relationship in radiation therapy of HNSCC. However, within an apparently very similar group of tumours, for example in low differentiated SCC of the oropharynx, the response to RT may vary substantially between patients. Three main mechanisms of resistance at the cellular level counteract tumour response to radiation; hypoxia, repopulation during the course of RT and intrinsic radioresistance [43]. These mechanisms are of great interest in research and clinical trials but are not yet adaptable in the clinical management of HNSCC.

RT is mainly delivered with intensity modulated radiation therapy (IMRT) or volumetric modulated arch therapy. These techniques allow for high dose radiation with steep dose gradients, thus sparing normal adjacent tissue. This is especially attractive in treating head and neck cancers where complex anatomy and the adjacent normal tissue, with great importance for quality of life, make treatment planning particularly difficult [44]. With highly conformal radiation delivery an accurate target definition is of uttermost importance.

Radical RT for HNSCC is administered externally with megavoltage radiation, usually 6MV. There are different types of treatment protocols but a standard regimen for HNSCC is conventional fractionation *i.e.*, 2 Gy/day to an absorbed dose of 66 to 70 Gy to known disease and prophylactic dose of 50 Gy to elective nodes. RT is administered with five to six fractions a week.

Many studies have compared the effect of RT with chemoradiotherapy (CRT) with a survival benefit of 6.5% for concomitant CRT [45]. However, the addition of any additional, potentially toxic, therapy do not compensate for a substandard RT. Peters et al have reported on the importance of RT quality. In an international trial, where the outcome between CRT with or without tirapazamine was compared a review of the RT protocol compliance was performed. In 25% of 820 cases the protocol turned out to be non-compliant. Protracted total treatment time, incorrect target definition, failure in covering the clinical tumour volume, and erroneous dose prescription had major adverse effect on outcome in a total of 97 patients or 12%. The 2-year OS was 20% higher in the group with compliant RT protocols regardless of treatment arm [46].

The cytotoxic effect of radiation is unfortunately not exclusive for tumour cells. Normal tissues within the treated volume suffer from the radiation effect. Radiation sequelae are either acute or chronic. Acute radiation effect mainly affects tissues with a high cell turnover. In patients with HNSCC, it is predominantly the oral mucosa and salivary glands where symptoms with oral ulcers and pain, in particular odynophagia and dysphagia, start after a couple of weeks of RT. The symptoms gradually subside a couple of months after the completion of treatment. Potent painkillers and nutritional support are most often needed during the treatment. RT also causes inflammation, hyperemia, oedema and fatigue. Tissue fibrosis with decreased vascular perfusion, xerostomia and to a certain extent, dysphagia are common late sequelae after RT to the head and neck. More uncommon but severe is osteo- or chondroradionecrosis [43, 47].

Medical tumour therapy

Medical tumour therapy can be given in combination with RT either concomitantly or as neoadjuvant therapy or in the palliative situation as a single modality treatment.

Platinum-containing compounds (*e.g.*, Cisplatin, Carboplatin) cause cross linking of DNA, subsequently impairing DNA repair and DNA synthesis. They are the most commonly used agents concomitantly with radiotherapy and also in recurrent disease. They may also be given in a neoadjuvant setting. Common side effects are ototoxicity, impaired renal function and peripheral neuropathy.

Antimetabolites (*e.g.*, Fluorouracil, Methotrexate) are long used agents in cancer therapy. They interfere with the normal metabolic process in the cell for example by reducing the synthesis of purines and pyrimidines thus inhibiting DNA and RNA synthesis or replacing nucleosides [48].

EGFR inhibitors (*e.g.*, Cetuximab) are monoclonal antibodies and the only molecular targeted therapy in use. EGFR inhibitors in combination with radiation have been studied by Bonner et al who showed an increase in the 5-year OS by 9% compared with RT alone [49]. As the name implies the EGFR-inhibitors are directed against growth factor receptors at the cell surface affecting a cascade of signalling pathways including mitogenesis, cell motility and differentiation and protein secretion [50]. Side effects with, sometimes severe, skin rashes are common but also anaphylactic reactions, electrolytic disturbances and cardiovascular incidences have been reported.

Taxanes (*e.g.*, Docetaxel, Paclitaxel) are a group of cytotoxic agents acting as mitotic inhibitors by disrupting the microtubule function and are mainly used in recurrent or metastatic disease [51].

All agents used in chemotherapy have side effects, more or less pronounced depending on the substance. Patients commonly suffer from gastrointestinal symptoms, arthralgia, low blood count including neutropenia with subsequent susceptibility for infections and fatigue.

Chemoradiotherapy

CRT has gained widespread acceptance as standard of treatment for locally advanced head and neck cancer when the approach is an organ preservation therapy with curative intent. The benefit of concomitant chemotherapy, mainly platinum-containing compounds has been confirmed in a meta-analysis by Pignon et al and results in an improvement of the 5-year OS by 6.5% and disease free survival (DFS) by 8.6% [45]. However, the advantage of the regimen is questioned because of an increase in treatment related toxicity. In patients older than 66 years there is a disadvantageous and significant difference in the frequency of acute toxicity and also a greater long-term need for feeding tubes between patients receiving CRT compared with RT [52, 53]. Older age, ND, hypopharyngeal/laryngeal primary site and advanced T classification are independent risk factors associated with increased toxicity in patients treated with CRT [54]. Furthermore, it has been shown that up to 60% of patients treated with concomitant Cisplatin need to modify or interrupt the prescribed chemotherapy due to side effects [55]. Therefore, the cost-benefit of CRT for the individual patient should be taken into account when planning for an organ preservation treatment.

Aiming for a new era with a more personalized therapy, research is now focusing on targeted therapies and unravelling of abnormal signalling pathways, genomics and proteomics.

Assessment of therapy response and surveillance

The assessment of therapy response varies widely between institutions. It usually comprises a combination of clinical evaluation and imaging. Determined by the primary tumour site and local guidelines, imaging such as MRI, CT or ultrasound can be used. In a review by Manikantan et al, CT or MRI is recommended three to six months after treatment to provide a baseline for later reference. Otherwise, imaging is recommended only if there is a clinical suspicion of recurrence or a new primary [56].

In recent years, functional imaging with PET has gradually been incorporated in the assessment of therapy response and sometimes as part of the surveillance.

The follow-up protocol runs for five years posttherapy and serves as an opportunity to detect recurrent tumour, new primaries and provide care for treatment related side effects. Due to high risk for recurrences during the first and second year, physical examinations are usually scheduled every two to three months during the first two years. The risk steadily subsides and the clinical evaluations continue with decreased frequency during the following three years. Scheduled follow-up physical examination appointments are important in relation to the management of sequelae but asymptomatic recurrences are rarely diagnosed [57].

Treatment of residual or recurrent tumour

The prognosis is poor for patients with residual or recurrent HNSCC. If organ preservation therapy was chosen as first line treatment, surgery is preferred in the salvage situation if the tumour is resectable. Both the initial and recurrent site and stage of the tumour as well as the disease free interval following previous treatment are associated with salvage surgery outcome. Focusing on OPC, approximately 50% of the patients suffering from recurrences have a local or locoregional failure and may be suitable for salvage surgery. Nichols et al have shown a 5-year OS after salvage surgery of 43.4%. The ability to obtain negative margins was significantly associated with improved survival ($p < 0.01$) [58]. Both patients with HPV-positive and negative tumours benefit from salvage surgery but the 3-year OS for HPV-positive patients is reported as high as 66.7% compared with HPV-negative patients, 42.9% [59].

Reirradiation after salvage surgery is an option in patients with high risk for local recurrence after surgery *i.e.*, positive margins. At the expense of higher toxicity, reirradiation is expected to increase local control and DFS but not OS [60]. Reirradiation with curative intent can also be used as a single modality treatment in the recurrent situation with a 5-year OS of 17-93% [61].

Chemotherapy is an option when focus is on palliative care. When possible, a combination of drugs can be used and Peron et al have shown a median OS of 14.2 months when the combination of cisplatin and taxane, as the most efficient combination in their study, was used [51]. However, in a palliative situation quality of life is most important. Chemotherapy adverse effects must be taken into account and pros and cons discussed with the patient.

In situations of a primary site failure that is non-resectable, brachytherapy might be an option and an alternative to external RT [61].

NECK DISSECTION

HNSCC has been shown to spread by the lymphatics and in a fairly predictable manner [62]. However, this rationale is recently questioned in a subgroup of patients with p16-positive tumours where the pattern of distant metastasis is suggesting a haematogenous spread of tumour cells [63].

The lymphatic spread is known from the 19th century when the first surgical lymphadenectomies, ND, were described [64]. The anatomy of the neck is subdivided into six different neck node levels (some refer the superior mediastinal nodes caudal to the suprasternal notch but cranial to the innominate artery to a seventh level). Level I, II and V are subdivided into “a” and “b” [65], see figure 4.

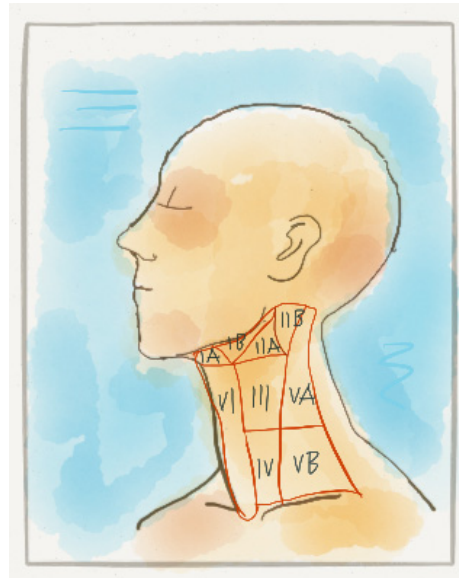


Fig 4
Neck node levels I-VI (picture by Eva Brun).

The surgical procedure has evolved over the last century and surgery modifications have caused a varied, and sometimes confusing, terminology regarding the extent of the surgery. A proposed and appealing classification is a three component description of the surgery composed of side, levels removed and non-lymphatic structures removed [66].

The radical ND (level I-V, sternocleidomastoid muscle (SCM), internal jugular vein (IJV), XIth cranial nerve) for excision of lymph node metastases was introduced during the 19th century. The first successful radical ND was performed by Dr Jawdyski in Poland in 1888 and a larger series first described by Crile in 1906 [64, 67]. Fifty years later, Suarez modified the procedure to “functional ND” by preserving non-lymphatic structures that were rarely involved by cancer *i.e.*, the SCM, the accessory nerve and the IJV (*i.e.*, ND I-V) [66]. No deterioration in oncologic outcome was found [68]. The next step in refining the procedure was to remove only lymph nodes harbouring, or being at greatest risk for harbouring, metastases. The procedure was reported by Byers and later called selective or, if only two levels are removed, super-selective ND (*e.g.*, ND, 2a, III, IV). Equivalent oncologic results with an improved functional outcome are achieved when these techniques are used in proper settings [42, 69].

ND are performed up front or following (C)RT either six to eight weeks before or after RT. Six to eight weeks after RT the tissue starts to recover. The oedema gradually subsides and therapy induced fibrosis, with loss of dissection planes, is not fully developed [43]. Thus, the surgical conditions are as advantageous as possible.

The extent of the ND depends on several variables: the location of the primary tumour, known involved lymph node metastases, the risk of microscopic/occult disease and whether a staging or curative procedure. The ND procedure is performed for a few hours under general anaesthesia, followed by two to four days of hospitalization and a subsequent sick leave of two to three weeks.

Consequences of neck dissections

A ND with clear margins is a safe procedure with good therapeutic results. It is nevertheless associated with a high rate of morbidity. Since risk factors for head and neck cancer includes smoking and drinking that also contributes to comorbidities, a thorough assessment before the operation is necessary in order to avoid cardiovascular events associated with anaesthesia.

The primary tumour itself and/or given radiation might distort the upper airway anatomy and induce trismus, making it important to prepare for a safe airway during induction of anaesthesia.

Immediate surgical complications, though not very common, are intra- or postoperative bleeding, infection, chylous fistulas and flap necrosis, the latter as a complication to previous radiation and surgery.

A partly transient facial and/or submental oedema is to be expected after a ND. The subsequent scarring and sometimes altered contour of the neck, which is bound to change the patients' appearance, can be perceived as a cosmetic problem, see figure 5.

Several cutaneous sensory nerves are per se sacrificed during a ND and can sometimes be the cause of a persistent, dull neck pain. Other nerves might also be sacrificed or accidentally injured depending on the tumour location. Injury to the marginal branch of the facial nerve produces lower lip weakness and sacrificing the cervical sympathetic chain causes Horner syndrome. Bilateral hypoglossal damage causes severe dysphagia but unilateral resection of the nerve is usually well tolerated in that aspect.

The most common nerve damage is to the accessory nerve that causes shoulder impairment with a winged scapula, a shoulder droop, a decreased range of movement and a dull pain. Even though a functional or selective ND is performed, keeping the accessory nerve intact, the sheer manipulation sometimes seems to affect the nerve or nerve compression might be caused by a postoperative related fibrosis. Unfortunately, shoulder morbidity with limitations in work related tasks and daily activities is common even with less radical procedures but the symptoms seem more likely to eventually abate [70-72].

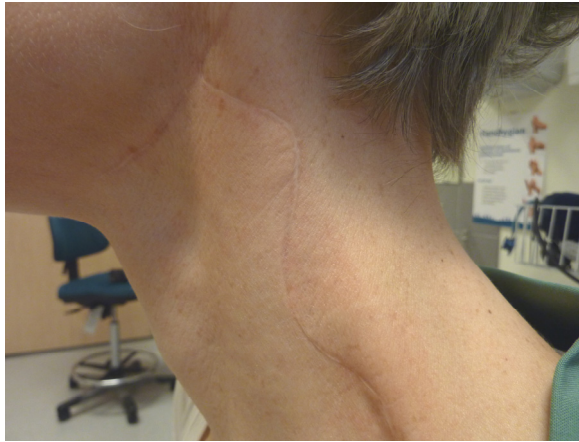

Fig 5

Status two years after treatment with functional ND, level IIa-V and adjuvant RT. (Picture provided by Dr Wahlberg, Dept. of ORL-HNS, Skåne University Hospital, Lund, with permission from the patient.)

Dysphagia, a sequelae usually attributed to RT, is recently linked to ND as well. ND after organ preservation therapy 4-folds the risks of feeding tube dependency 18 months after surgery compared with RT or CRT alone [73]. Dysphagia might lead to aspiration. Silent aspiration is recently shown to be more common in patients that have had a ND after RT than those who were not operated on ($p=0.013$, Lindblom et al, unpublished data). The underlying mechanism is not fully understood but damaged sensory fibres from the vagal nerve might cause a decreased sensibility in the supraglottic and glottic region.

Donatelli Lassig et al have reported that quality of life one year after (C)RT in combination with ND compared with (C)RT alone does not differ significantly, as measured by SF-36. The ND group only reported greater levels of pain [74].

On the other hand, Eickmeyer et al, have looked at 5-year survivors after head and neck cancer treatment. Different quality of life parameters were addressed as well as measurement of shoulder mobility. They could demonstrate a significant adverse long-term effect on shoulder mobility, which naturally was even worse if the accessory nerve was sacrificed. A ND also had negative impact on activity in general, recreation, speech and eating in public [75].

The mentioned consequences and impact on quality of life has caused a debate about the need for a planned ND following (C)RT with curative intent.

POSITRON EMISSION TOMOGRAPHY

PET is a nuclear imaging modality enabling studies of the uptake and metabolism of a radioactive labelled substance. The fate of molecules, labelled with positron emitting radionuclides, can not only be visualized but also quantified. A PET image provides information about the relative body distribution of the administered tracer, see figure 6.

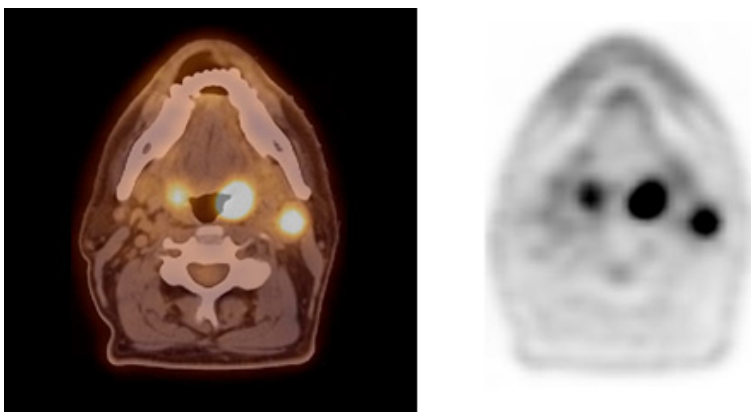


Fig 6

A fused PET/CT image to the left and a plain PET image to the right depicting a high FDG-uptake in a left tonsillar cancer and in an ipsilateral lymph node metastasis.

The most common radionuclide in oncologic imaging is fluorine, ^{18}F . ^{18}F is generated by a powerful accelerator, a cyclotron, in which protons are accelerated and merged with ^{18}O that simultaneously evaporates a neutron. ^{18}F has a half-life of 110 minutes. PET facilities therefore need a certain proximity to the production of the tracer. ^{18}F , as an unstable radionuclide, is attached to deoxyglucose to produce 2-deoxy-2- ^{18}F fluoro-D-glucose (FDG), a glucose analogue.

When ^{18}F emits a positron it returns to a stable ^{18}O nuclide. The positron travels around 1-2 mm, collides with several electrons and loses energy. Almost at rest, it collides with yet another electron and an annihilation phenomenon takes place. In the annihilation process the mass of the positron and electron is extinguished and turned into two photons of 511keV, travelling in opposite directions at an angle of 180° . In a PET camera, gamma detectors register photons that, opposite each other and simultaneously, hit the detectors. That is called a coincidence and a line can be defined along which the positron decay occurred in tissue. See figure 7.

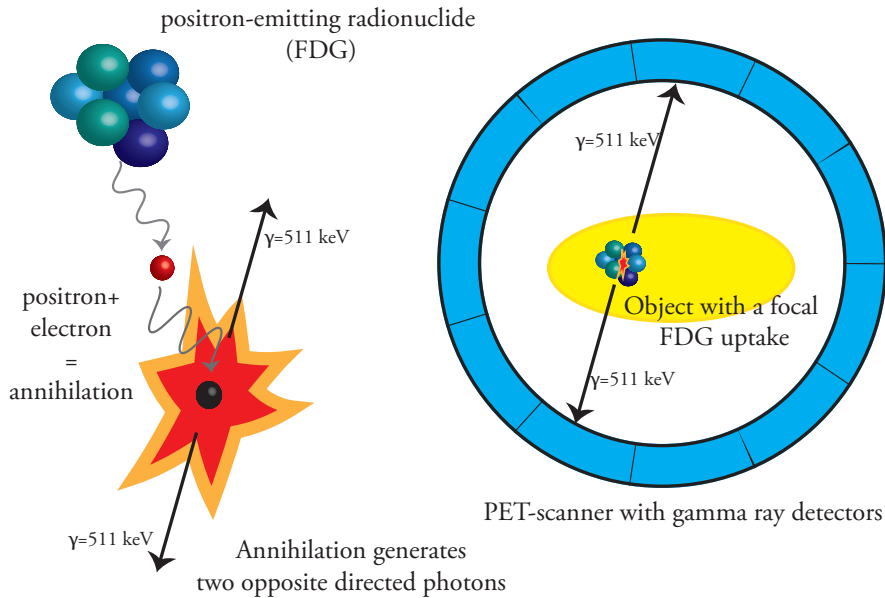


Fig 7
The annihilation process and detection of opposite directed photons in a PET scanner.

Tumour and FDG metabolism

Glucose is transported into cells by facilitative glucose transporters (GLUT) proteins. There are at least 13 isoforms of GLUT possessing different affinities for hexoses. Overexpression of GLUTs, especially GLUT1 occurs early in many types of malignant transformation reflecting an increased glucose demand in tumour cells [76]. Already in the beginning of the 20th century, biochemist Otto Warburg, described how cancer cells avidly consume glucose and produce lactic acid even under aerobic conditions. The phenomenon has been called the Warburg effect or aerobic glycolysis [77]. The reason for this shift to aerobic glycolysis is probably multifactorial and Ngo et al have proposed several reasons. Cancer cells releasing lactate is advantageous for the microenvironment and stimulates tumour growth and the likelihood of metastasis. Furthermore, with a less involved oxidative pathway, the amount of reactive oxygen species is reduced that influences cellular activities affecting apoptosis. Another reason is that the generation of biomass instead of energy is important if the proliferative capacity is to be maintained [78]. Glycolysis refers to a ten-step pathway in which a glucose molecule is converted into two pyruvate molecules, two ATP and two reduced nicotinamide adenine dinucleotide, NADH. In the presence of oxygen, pyruvate can be further metabolized to acetyl-CoA, a major fuel for the citric acid cycle. In anaerobic condition, in cells that lack mitochondria or

if a Warburg effect is present, pyruvate is reduced to lactate that is a less efficient pathway in terms of generating ATP [79], see figure 8.

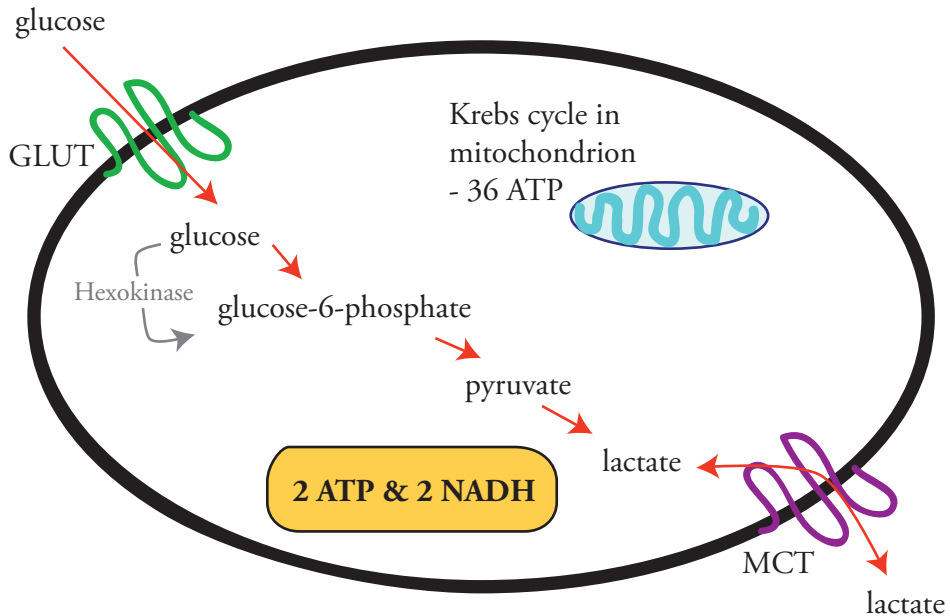


Fig 8

Aerobic glycolysis in the cytosol of the cell with a net gain of 2 ATP molecules.

MCT stands for MonoCarboxylate Transporter.

The augmented urge for glucose, the increased glycolysis in cancer cells compared with normal tissue is a prerequisite for PET.

The cells take up FDG in the same way, by the same GLUTs, as glucose. They also share the first glycolytic step, a phosphorylation, catalysed by hexokinase. Unlike glucose-6-phosphate, phosphorylated FDG is not further metabolized and now being a polar molecule it is trapped in the cell. During the accumulation phase extra glucose demanding cells will accumulate more FDG compared with normal cells and it is the relative difference in FDG accumulation that will be captured on the PET scan, see figure 9. Of importance in oncologic imaging is that the amount of FDG uptake is correlated with the glucose demand and therefore tumour viability.

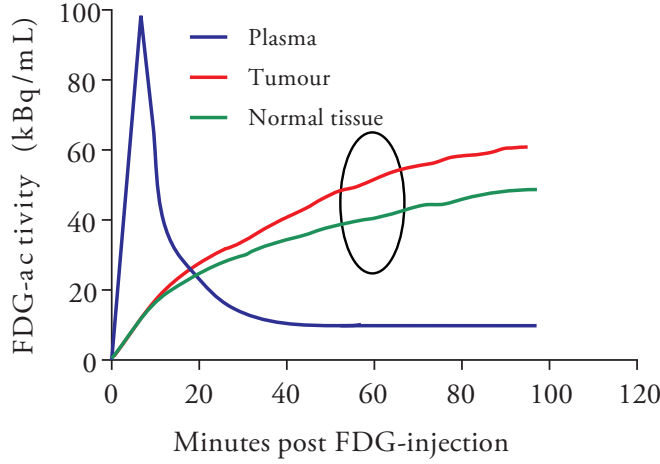


Fig 9

The relative difference in FDG accumulation between tumour cells and normal cells will be revealed on PET imaging.

FDG uptake and metabolism is depicted in figure 10 where the rate constants, K_1^* - K_3^* , are used for determining the influx constant, K_i , when calculating the metabolic rate of glucose (MR_{glu}), $K_i = K_1^*K_3^*/K_2^* + K_3^*$. The dephosphorylation of FDG-6-phosphate, K_4^* , is not part of the MR_{glu} formula since it is assumed to be negligible at the time of measurement [80]. The primary route of FDG excretion is renal.

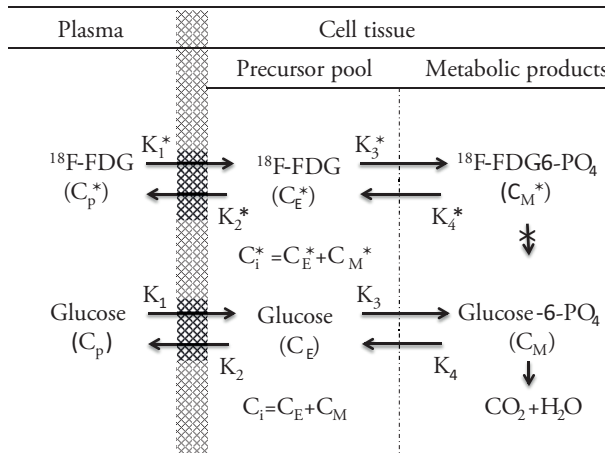


Fig 10

The three compartment model for measurement of MR_{glu} as developed by Phelps et al [81]. C_i^*

represents total ^{18}F concentration in tissue. C_E^* is the ^{18}F -FDG and C_M^* is the ^{18}F -FDG-6- PO_4 concentration in tissue. C_p^* is the plasma concentration of ^{18}F -FDG. Representation without asterix is related to glucose. (With permission from Jonathan Siikanen).

PET development

The first images using annihilation radiation following positron emission were produced in the early 50's, initially attempting to detect brain tumours. The application involved a simple probe and two opposed coincidence detectors. It was not until the middle of the 1970s more powerful cyclotrons, producing isotopes including ^{11}C , ^{13}N , ^{15}O and ^{18}F became accessible to a wider population. F-FDG was first synthesized in 1978. A simultaneous technical development to more sensitive and sophisticated detection devices eventually resulted in high resolution images obtained from multiple small detectors placed in a circle around the positron-emitting subject [82]. The resolution of modern PET cameras in clinical use is approximately 5mm. PET does not have a spatial resolution comparable with CT or MRI. To obtain anatomic correlation and attenuation correction, CT scanners (and recently also MRI scanners) are integrated with modern PET cameras. These dual modality systems can automatically fuse metabolic and anatomic or structural images, see figure 6. This is noteworthy since studies published ten years ago or more usually refer to PET as single PET studies but nowadays, as in this thesis, PET means PET-CT. PET-CT has proven to be more accurate than CT or PET alone not only in staging procedures [83] but also for determining a benign versus malignant character of a lesion [84].

The scanning procedure

PET protocols used in head and neck cancer patients are similar between institutions. PET examinations are performed after a four to six hours fasting period. Fasting is important since FDG competes with endogenous glucose for uptake in the cells and increased serum levels of glucose can decrease FDG uptake in tumour cells [85]. Furthermore, meal associated insulin secretion causes a diffuse muscular FDG uptake, disturbing the image quality [86]. The blood glucose is then measured and should be $<10\text{mmol/L}$. If the blood glucose is higher, the patient is rescheduled. After an intravenous injection of FDG, in a dose of 4MBq/kg body weight to maximum 400MBq , the patient rests for the one-hour uptake period. During the scanning procedure images are acquired for two minutes per bed position. When PET is used for staging it can be combined with a contrast enhanced CT. For follow-up studies low-dose CT scans (50mAs) can be used for attenuation correction and anatomic localization.

The investigated scanned area typically extends from the vertex to mid-thigh. Additional use of intravenous contrast allows full diagnostic CT capability and improves diagnostic performance in the head and neck region, especially with regards to cystic and/or necrotic lymph metastases, which is not an uncommon finding in OPC [87].

Assessment of PET scans

Most publications regarding PET in HNSCC have been dealing with response to treatment assessment. Traditionally, tumour response is measured by tumour shrinkage, in the 1980s according to the World Health Organization response evaluation criteria and from 2000 according to Response Evaluation Criteria in Solid Tumours (RECIST) [88, 89]. Tumour shrinkage occurs later than the metabolic response especially in bulky tumours and shrinkage will occur in spite of minor clones of resistant tumour cells which make evaluation of the metabolic response valuable in these scenarios. In the light of the contemporary status of PET technique in 1999, the European Organization for Research and Treatment (EORTC) PET study group published a position paper with recommendations on the measurement of FDG uptake for tumour response monitoring [80]. In that time integrated PET and CT scanners were not introduced. In 2009, Wahl et al summarized the present status based on the EORTC paper, recent studies and an update on RECIST and they introduced PET Response Criteria in Solid Tumours (PERCIST) [90]. PERCIST is intended to be used in clinical trials and in structured quantitative reporting of PET results but it is not widely used.

The outcome of PET assessment depends on several technical, physical and biological factors. Even though many of the factors have a relatively small effect, the accumulation of small errors can lead to considerable differences in outcome. Boellard has listed the most common factors influencing PET assessment and they include camera related factors as relative calibration and incorrect synchronization of clocks between camera and dose calibrator. Residual FDG activity in syringe, incorrect time interval for decay correction, scan acquisition, image reconstruction parameters and the determination of region interest (ROI) are other technical issues. Biologic factors relate to the blood glucose level, the accumulation phase, the presence of inflammation, patient comfort, motion and breathing [91].

Quantitative assessment

For quantitative analysis of FDG uptake, a ROI encompassing the tumour is defined manually or by software solutions. The amount of radioactivity within the ROI is measured. Calculation of MR_{glu} is a kinetic modelling and the most accurate approach to measure metabolism. Calculation of MR_{glu} , either with non-linear regression [81] or Patlak analysis [92] is based on measurements of the rate of glucose uptake over

time and requires repeated, rapid measurements of radioactivity under dynamic scanning. MR_{glu} is expressed in $\mu\text{mol}/\text{min}/100\text{g}$ tissue. With single scans, MR_{glu} can be evaluated with a modified auto radiographic method.

$$MR_{glu} = \frac{C_{gl} \cdot C_i(T)}{LC \cdot \int_0^T C_p(t)dt}$$

The formula is based on a 3-compartment model where the lump constant (LC) is set to 1 and represents the difference in transport and phosphorylation between blood glucose and FDG. C_{gl} is the blood glucose value, C_i is activity in tissue, T is the time point post injection and $C_p(t)$ is the plasma FDG concentration as a function over time [93].

Measuring MR_{glu} is gold standard in calculating tumour metabolism and important in trials including metabolic studies and as reference when new, simpler quantification methods of measurements are introduced [91]. Due to the necessity of frequent blood sampling and demanding calculations MR_{glu} is not in routine clinical use.

Semiquantitative assessment

Standardized uptake value (SUV) is called a semiquantitative measurement of activity in a region at a fixed time point. SUV relates tissue activity to injected activity and the body mass (or area) of the patient. SUV is dimensionless.

$$SUV = \frac{\text{mean regional activity (Bq / mL)}}{\text{injected activity (Bq) / body weight (g)}}$$

This is the most widespread way of calculating FDG uptake in PET [90]. In the SUV formula the level of blood glucose is not taken into account, which would stabilize the SUV. Another factor influencing the outcome of SUV is the plasma activity of FDG that is assumed to be consistent [94].

Different types of SUV methods are used, the most common are:

- SUVmax, the highest single pixel/voxel value and the most frequently used parameter
- SUVmean, the mean SUV value of a number of voxels in a volume of interest.

- SUV_{peak}, the average SUV within a small, fixed-sized ROI, centred on a high uptake part of the tumour

What type of SUV method to be selected depends on a fundamental biologic question – is the metabolically most active portion of the tumour more important or is the total tumour volume? Or are they equally important? Vanderhoek et al have analysed tumour response with different types of SUV methods. SUV_{max}, mean, peak and total were studied. On average, a 20% variation of individual tumour response was noted (ranging up to 90%). More than 80% of the tumours ended up in different categories of response when different SUV methods were used [95]. Cheebsumon et al have also compared SUV with different types of kinetic analysis and conclude that SUV may provide different response values compared with MR_{glu} [96]. With the PERCIST criteria it is still hard to compare different studies using SUV as outcome because of the different parameters and the different formulas used for calculation.

In a clinical setting, SUV usually do not add any extra information to a visual evaluation and cannot replace, but might assist, the nuclear physician in the interpretation of PET images [97, 98].

Other parameters based on SUV are metabolic tumour volume (MTV) and total lesion glycolysis (TLG), also called SUV_{total}. Both of them are candidates to be prognostic biomarkers of therapeutic response [99, 100]. Different methods with various thresholds can be used to determine MTV and no absolute standard is agreed upon. MTV largely corresponds to the gross tumour volume (GTV) and has a higher prognostic value than SUV_{max} on pretreatment scans [101]. TLG integrates both metabolic and anatomic data and is calculated for the total tumour burden in the patient according to the formula SUV_{mean} x MTV.

Qualitative assessment

In qualitative interpretation of FDG uptake the distribution and intensity of the uptake in suspected tumour foci are compared with the uptake in normal structures such as adjacent tissue, brain, blood pool and liver. It takes clinical experience, knowledge of normal distribution and artefacts as well as awareness of expected disease pattern for a solid qualitative interpretation. Qualitative assessment usually ends up in three different categories: positive/indicative for tumour, negative/not indicative for tumour or equivocal. There are few data on reproducibility of qualitative assessment. A Likert scale is proposed in order to sharpen qualitative assessments and PET reports. A 5-point Likert scale, the Deauville criteria, is validated for lymphoma studies and the concordance between readers is good [102]. Recently introduced for head and neck cancer is a similar 5-point scale, the Hopkins criteria that also shows substantial inter-reader reliability [103].

Pitfalls in the interpretation of PET images

While interpreting PET images, knowledge of normal FDG distribution and common causes for false positive and negative findings is crucial. In 25% of whole body PET examinations benign, reactive and/or physiological uptake is observed and more than half of these lesions might mimic malignant structures [84].

Physiological low to moderate, symmetrical FDG uptake is often found in the Waldeyer's ring due to accumulation in lymphocytes and macrophages. The uptake is sometimes asymmetrical which makes the interpretation challenging and additional clinical evaluation might be necessary [104].

Low to high symmetrical, diffuse, uptake in the parotid and submandibular glands is often encountered and increased in cases of viral infections, tuberculosis, sialadenitis and so forth. Focal salivary gland uptake is more likely to be suggestive of tumours, benign or malignant. Asymmetrical, sublingual FDG uptake caused by tongue movements sometimes mimics oral cavity malignancy [105].

The muscles of the head and neck frequently show physiological uptake. It is usually possible to follow a linear uptake from origin to insertion on fused images. Talking, chewing and eating after the FDG injection must be avoided in order to decrease muscular uptake [106].

Brown adipose tissue has high metabolism and is often encountered in the lower neck and upper mediastinum, paravertebrally and perirenally. Sympathetic stimulation increases metabolic activity in brown adipocytes leading to increased FDG uptake. Brown adipose tissue is more frequently seen in children than in adults, more so in females than in males and it occurs more often in patients with low body mass index. Brown adipose tissue activity disturbs PET image interpretation and can be reduced by a low dose of beta blockers [86].

Granulomatous diseases, infections and inflammation may show increased FDG uptake, mainly caused by activated macrophages. Clinical history can often point out the cause of abnormal FDG uptake but in oncologic imaging the coexistence of neoplasia and focal inflammation is not uncommon. RT induced inflammation in terms of mucositis, reactive lymph nodes, soft tissue necrosis and osteo- or chondroradionecrosis are confounders for false positive posttreatment PET scans. These issues are less pronounced 8-12 weeks after treatment and treatment evaluation is therefore often scheduled within that time frame. Inflammatory oedema, granulation tissue and scarring cause increased FDG uptake four to six weeks after surgery. Later on, after removal of a muscle or a gland, its contralateral counterpart may show increased FDG uptake. The same happens as a result of cranial nerve palsy – the contralateral innervated muscles show an increased FDG uptake [105].

In a retrospective review of 2594 patients, incidental increased FDG uptake in the thyroid demonstrated a prevalence of 4% and was categorized as either diffuse or focal. Homogenous, diffuse uptake most likely represented a normal variant or was

explained by thyroiditis. However, focal thyroid uptake had a high risk, 64%, of harbouring malignancy [107].

False negative PET scans might be caused by several factors. Small tumours, approximately less than five mm, may not be reliably detected due to a phenomenon called the partial volume effect. It refers to two different camera related problems that cause the activity of a small source to be underestimated - the limited spatial resolution and the image sampling technique. The extent of the problem depends largely on the resolution of the PET camera [108].

The type of tumour is also an issue. As examples, adenoid cystic carcinomas, well-differentiated sarcomas, extranodal marginal zone lymphomas as well as any type of necrotic tumour may not be FDG avid.

If the malignant lesion is situated in the vicinity of an area with high FDG accumulation like close to the urinary bladder, the brain or the tonsils the lesions might be overlooked or not visible [105].

PET in HNSCC

PET in the work-up

PET is not commonly part of a routine diagnostic work-up for HNSCC. However, a correct TNM classification is crucial before planning any oncologic treatment and PET-CT is the most accurate imaging modality for tumour staging compared with PET or CT alone [83]. In a meta-analysis by Kyzas et al pretreatment lymph node staging capability was evaluated and showed a sensitivity of 79% and a specificity of 86% in patients with different types of HNSCC. In the clinical N0 neck PET is only able to identify 50% of occult node metastases [109]. A prospective study by Nair et al, where whole body PET was performed after regular work-up but before treatment start, demonstrated no significant change in T but in N classification. In total, 17% of the patients changed TNM classification and in 16% it resulted in an altered treatment [110]. The results are in line with results from Connell who showed that 34% of the patients changed TNM classification after the PET scan, which had a direct clinical impact in almost half of them [111]. The above results indicate that PET might take a more prominent part in the work-up in the future.

PET plays an important role in the search for primary tumours in CUP. However, there is still an argument what is the preferred order to use conventional imaging, endoscopy with biopsies and PET. In a Canadian analysis it was demonstrated that PET before panendoscopy is cost-effective in N1-N2 tumours [112]. Recent studies and meta-analysis have presented that PET has a detection rate of 28 to 44% after conventional work-up, with panendoscopy and routine imaging, was considered negative or inconclusive [113-115]. Canadian guidelines from 2012, recommend PET before treatment start in advanced stage (III and IV) tumours, other tumours

with an increased risk of distant metastasis (*i.e.*, nasopharyngeal cancer) and in the diagnosis of CUP [116].

PET in the planning of radiotherapy

Radiation therapy is routinely planned based on pretreatment CT images. Low soft tissue resolution and dental artefacts can especially make the primary tumour delineation difficult. Delineation studies incorporating functional imaging of the primary site have been performed and PET was shown to be more accurate in defining GTV than CT or MRI alone. However, all modalities failed to detect superficial tumour extension and none allowed perfect three-dimensional estimation of the tumour volume compared with pathological specimen [117]. Thiagarajan et al have emphasized the importance of a thorough physical examination to reveal the true superficial extent of the primary tumour. In a study using CT, MRI, PET and combinations of them in order to delineate GTV, a lack of concordance between the imaging modalities was demonstrated. The authors suggest that a combination of them, and not to forget, physical examination, is beneficial for an accurate RT treatment planning [118]. The fact that different imaging modalities complement each other is also pointed out by Perez et al, drawing attention to novel MRI technique like diffusion-weighted MRI and dynamic contrast enhanced MRI [119].

The International Atomic Energy Agency reported on PET in head and neck cancer radiation planning in 2008 and stated that there was no data to prove a superior outcome as a result of PET in the planning procedure but they could nevertheless not support the idea of a prospective randomized trial between RT planning +/- PET due to the ethical challenge of not using PET as part of the RT planning [120].

PET for prognosis and prediction

Only two prospective studies have evaluated the prognostic and predictive value of PET by calculating MR_{glu} for primary site and lymph nodes. PET before treatment start was of limited prognostic value but PET performed early in the therapy, after a median dose of 24 Gy, was predictive of OS. When 16 $\mu\text{mol}/\text{min}/100\text{g}$ tissue was used as a cutoff value to separate patients in a high and a low MR_{glu} group, the 5-year OS was 35% and 72% respectively [121, 122].

Much more, but also, contradictory data have been published on semiquantitative measures. $SUV_{max} < 8$ at the primary site before treatment is favourable for OS according to Suzuki et al, finding no similar association of nodal SUV and OS [123]. Joo et al have also demonstrated favourable OS with a SUV_{max} cutoff value of 8.5 at the primary site and 3.5 at the nodal site [124]. Other studies, on the other hand, have not been able to demonstrate any relationship between SUV_{max} at the primary site and outcome but have shown that MTV for primary and total tumour lesions can prognosticate DFS and OS [125-127]. In patients with oral cavity cancer and metastatic nasopharyngeal cancer MTV, but not SUV, independently predicts OS [99, 128].

To briefly summarize the literature it is, not surprisingly, an ominous sign to have persistent tumour metabolism post RT. OS and DSS are generally significantly worse if a metabolic response is not achieved. The conclusions are more or less the same, at least if the restaging scan is performed six weeks posttreatment or later [129-133]. However, comparison between studies might be difficult since different time frames (two weeks to six months), ways of assessment (visual inspection and various SUV measurements) and SUV cutoff values have been used.

PET evaluation of treatment and PET directed treatment policies

There are currently no guidelines to adjust treatment regimens according to the level of tumour metabolism prior to therapy. To date there are not any established protocols using PET as evaluation of (C)RT response under ongoing therapy for head and neck cancer. If we knew the optimal time to schedule a PET evaluation under ongoing RT and how to interpret the results (is a flare or a quick metabolic decrease the optimal response?) we would be able to give non-responders an early surgical option and avoid futile radiation. So far, few trials are published with that question at issue [134].

On the other hand, several PET directed policies are in use regarding management of the neck after (C)RT. PET is now an established method for evaluation of neck node response and to lesser extent, primary site response to therapy. Many institutions use PET to decide if a posttreatment ND is recommended. PET demonstrates significantly higher negative and positive predictive values than CT or physical examination [135-138]. The NPV for PET in this setting is usually satisfying but the PPV is more often lower but still superior to other imaging modalities. Studies regarding PET accuracy for treatment response evaluation of neck nodes are summarized in table 1. Only studies using a combined PET-CT for the response assessment and presenting at least predictive values are shown.

Table 1

Studies evaluating neck node (C)RT response with PET-CT. The scanning time posttreatment is median value if not a time frame is given.

Study	Weeks posttreatment	Sens %	Spec %	PPV %	NPV %	Accuracy %
2006 Chen et al [139] n=30	7	100	70	36	100	74
2007 Connell et al [111] n=30	12	-	-	50	100	-
2007 Kim et al [140] n=97	4	100	99	83	100	99
2007 Nayak et al [141] n=43	8-22	88	91	70	97	91
2008 Ong et al [98] n=65	12	71	89	38	97	88
2009 Cho et al [142] n=48	>8	81.8	97.3	90	95	-
2009 Gourin et al [143] n=32	8-11	40	91	67	77	-
2009 Malone et al [144] n=21	6-8	75	94	75	94	95
2009 Moeller et al [145] n=98	8	75	76	27	96	-
2009 Rabalais et al [146] n=52	12	100	88	40	100	88
2010 Gupta et al [147] n=57	9	63	98	83	94	93
2011 Porceddu et al [137] n=112	12	-	-	78	98	-
2012 Prestwich et al n=41	17	100	92	63	100	-
2014 Keski-Säntti et al [148] n=54	13	75	100	100	93	94
2014 Pellini et al [149] n=36	12	44	95	89	64	70
2015 Schouten et al [150] n=58	13	100	84	25	100	-

PET in the follow-up situation

There is currently no acceptance for the use of surveillance PET in patients treated for HNSCC. One might postulate that early detected, even asymptomatic recurrences, have better chances of successful salvage treatment and PET might be an option for

early detection. Several retrospective studies have implied the value of PET in the follow-up. PET at three to six and at 12 months posttherapy far exceeds the ability of a physical examination for detecting recurrences with high sensitivity, specificity and predictive values [151]. Most asymptomatic recurrences are diagnosed within the first year and almost all within two years and approximately 50% of them are distant metastasis [152, 153]. Krabbe et al and Abgral et al also confirm excellent results in prospective studies regarding the ability of PET in this setting where a significant difference in diagnostic properties between PET and physical examination is demonstrated [154, 155]. Despite earlier detection of recurrences, so far no one has presented any data on the benefits of surveillance PET in terms of increased LRC or OS. Nevertheless, Kostakoglu et al concludes that there is enough data to recommend a PET scan two times a year during the first two years after completed treatment [156].

PET in the work-up of recurrences

If a locoregional recurrence is confirmed and salvage treatment is an option, it is obviously very important to establish the extent of the disease. Extensive surgery, involving the primary site, is of no benefit for the patient if distant metastases are present. The incidence of distant metastases in a population with locoregional recurrences is around 20%, with a majority of pulmonary lesions [157, 158]. Gourin et al have published an incidence of 23% of distant metastases when a locoregional recurrence is suspected and PET predicted distant malignancy with a PPV of 60% and a NPV of 95% [157]. In comparison with CT, even with the addition of skeletal scintigraphy, PET is a more sensitive, specific and accurate method for detecting distant metastasis [159, 160]. The NPV for PET is higher, 95-99%, than the PPV, 50-70%, because of the high rate of inflammatory pulmonary lesions [157-159]. PET is thus important before major salvage surgery to exclude distant metastases.

Radiotracers for potential use in head and neck cancer

¹⁸F-fluorothymidine, FLT, is a tracer for monitoring cell proliferation. It is a pyrimidine analogue, taken up by actively dividing cells and not by inflammatory cells possibly adjacent to the tumour. Unfortunately, germinal centres in reactive lymph nodes take up FLT giving it a low PPV. It has nevertheless a potential to be used for treatment monitoring but is not yet in routine clinical use [161].

A few tracers have been investigated as PET imaging agents focusing on hypoxia. ¹⁸F-fluoroazomycin arabinoside, FAZA, ¹⁸F –fluoroerythronitroimidazole, FETNIM and N4-methylthiosemicarbazone, Cu-ATSM have all been tried with the purpose of localizing hypoxic areas suitable for dose escalation in RT planning [162]. ¹⁸F-fluoromisonidazole, FMISO is the most studied tracer but is not yet in routine clinical use [37].

Non-invasive imaging of apoptosis would allow early monitoring of response to therapy. Fluoro-pentyl-methyl-malonic acid, ^{18}F -ML-10, is an apoptosis specific PET tracer recently tried on humans [163].

THE CLINICAL PROBLEM

HNSCC is often diagnosed with patients in their 60's and trending to an earlier age reflecting the increased proportion of patients with HPV-positive tumours often diagnosed in their 50's. The treatment is inevitably accompanied by long-term side effects that affect quality of life. The morbidity depends largely on the extent of the surgery and/or the extent and dose of cytotoxic therapy; the more interventions, the more morbidity.

Radically intended (C)RT is efficient and yields a high rate of complete remission. Long-term side effects, especially in combination with ND, can therefore be a burden for a prolonged survivorship.

As part of the treatment protocol and gold standard in Lund, RT response at the primary site has been thoroughly assessed under anaesthesia with an endoscopic examination including biopsies, six weeks after the RT was completed. It was noted that residual tumours were very uncommon and probably also would have been detected at a physical examination. Accordingly, a procedure that is futile, not without risk for the patient and also costly should be questioned.

Regarding the neck, a planned ND for N2-3 after (C)RT has been part of the standard protocol at most institutions for many years. Challenging this regimen has been the modest rate of residual tumours in a node-positive neck after treatment in combination with the perioperative risk, associated costs and most of all, the morbidity after ND. It has therefore been more common to evaluate neck node response to RT and hereby select patients who could potentially benefit from the surgery. How and when this neck evaluation should be performed and scheduled in order to achieve the most accurate outcome have been debated. Another issue has been the long-term effect of the omitted ND. Is the clinical outcome adversely affected or can the neck be safely observed without surgery if the patient is in remission?

PET is to date the most accurate way of evaluating tumour response to RT. There are several methods to analyze and report PET results, quantitatively and qualitatively. Visual inspection, a qualitative method, is the preferred method and sufficient in clinical routine. However, a certain amount of PET scans judged as equivocal pose a clinical problem. Is an equivocal PET scan after treatment most likely representing a complete response or not? There is no consensus on how to report PET scans following visual inspection. In order to facilitate the comparison of PET results over time and between institutions the evaluation of qualitative PET assessments would benefit from a common reporting system.

OBJECTIVES

The general aim of the thesis was to explore if PET could be used for RT response evaluation and adequately determine the need for further therapeutic interventions in patients with HNSCC treated with curative intent.

The overall clinical goal with these studies was to reduce the treatment related morbidity by avoiding unnecessary ND without risking an increase in failures.

The study specific objectives were:

- I. To evaluate if an early PET scan, six weeks after RT, is able to adequately select patients in whom a ND can be safely omitted.
- II. To assess the accuracy of PET in evaluating primary site response after RT.
- III. To establish, with a long-term analysis, if PET is an appropriate way to spare ND after organ preservation therapy and if PET-negative nodes can be safely observed without compromising isolated nodal control or OS.
- IV. To examine if a 5-point Likert scale can sharpen the evaluation of therapy response in PET scans and also to study the performance of three different methods of PET evaluation and their relation to outcome.

MATERIALS AND METHODS

The thesis is based on two different study populations, one Swedish (paper I, II and IV) with 106 patients included, and one Australian (paper III) with 121 patients enrolled.

Patients

All patients diagnosed with head and neck cancer in the Southern Swedish Health Care Region, with a catchment area of approximately 1.8 million people, are routinely referred to the Department of Otorhinolaryngology Head and Neck Surgery, Skane University Hospital in Lund. Diagnosis and stage is confirmed at the weekly multidisciplinary team (MDT) conference where also a decision is made regarding the most suitable treatment for each patient. A similar procedure with a weekly MDT conference is carried out at the corresponding department at Princess Alexandra hospital in Brisbane, from where the Australian study population is recruited.

The Swedish patients were consecutively offered inclusion from August 2009 until the study was closed in July 2012. The Australian patients were included between January 2005 and April 2009 and the long-term follow-up was performed from 2013 to 2014.

Patients with SCC of epi/oro/hypopharynx or larynx (and in Australia also CUP) suitable for organ preservation therapy with curative intent were screened for inclusion. All patients required biopsy-proven (both primary and node) cervical node-metastatic SCC. Exclusion criteria were distant metastases at presentation or PET-negative nodes at the baseline PET. Ultimately, for study I, III and IV, 105 Swedish and 112 Australian patients were eligible for analysis since a complete response at the primary site was required. In paper II, patients with no hypermetabolism at the primary site before treatment were excluded and 82 patients were eligible for analysis.

Ethical aspects

The Nuremberg code is the fundamental guideline for legislation related to ethics in human research in both Sweden and Australia. The original studies were approved by

regional (in Sweden) or institutional (in Australia) ethics boards. The participants, in both countries, have had oral and written information about the studies and given their informed consent.

Methods

An overview of the studies is shown in figure 11.

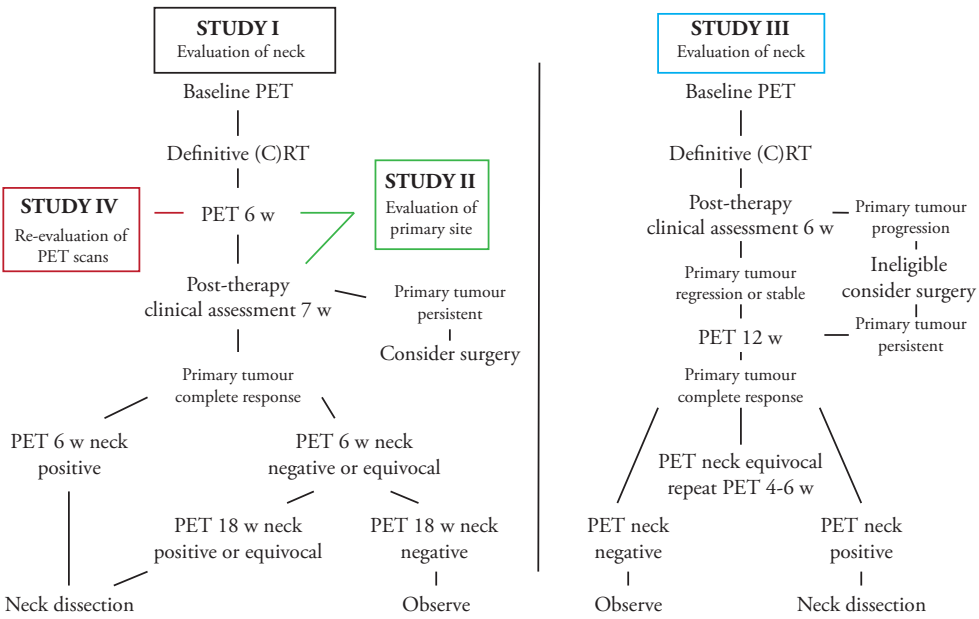


Fig 11
Overview of the studies presented in paper I-IV.

Work-up

All patients had a physical examination, biopsy and cytology acquired from the primary tumour and neck nodes respectively. A pathologist confirmed a HNSCC diagnosis. Imaging with CT of the neck and chest was part of the work-up. In Australia, MRI was performed at the discretion of the treating physician.

HPV or p16 status was also included in all Swedish patients and p16 status in Australian patients with OPC. HPV was determined either by PCR followed by Luminex-based genotyping [164, 165] or by single-tube multiplex PCR [166]. P16 was analyzed by IHC and p16 positivity was defined as strong and diffuse nuclear and cytoplasmic staining in $\geq 70\%$ of tumour cells that has the best concordance with the presence of HPV [23]. Before treatment began a thorough assessment of tumour

resectability at the primary site was performed, usually under anaesthesia. Neck node resectability was determined from the CT scans. As mentioned, all patients were discussed at the weekly MDT conference. If the patient was eligible for inclusion and willing to participate, a PET scan was scheduled less than three weeks before treatment start in Australia. In Sweden all patients had a PET scan as part of the RT planning procedure and could thereafter decide whether to participate in the study.

PET imaging

PET images were acquired for two minutes per bed position, from vertex to mid-thigh, on integrated PET-CT systems (Philips Gemini TF in Sweden and Philips Gemini GXL in Australia) operating in 3D mode. Low-dose CT was performed for attenuation correction and lesion localization.

PET interpretation

Nuclear physicians assessed the images by visual inspection as part of the clinical routine in papers I-III. In the Swedish studies adjacent tissue was used as reference and in the Australian study liver activity was taken into account as well.

In paper II, the original PET reports from the six weeks posttreatment PET, were categorized into positive, negative or equivocal at the primary tumour site.

In paper IV the Swedish PET scans were re-evaluated regarding the neck. The original PET reports at six weeks posttreatment, were categorized visually as in paper II, but with regards to the neck nodes. SUVmax was automatically calculated from a ROI defined by the software of the PET camera. Two experienced PET interpreters re-assessed the PET scans using a 5-point Likert scale, the Deauville criteria, designed to describe FDG uptake pattern in relation to mediastinum and liver, see figure 12. The Deauville criteria score 1 is defined as “no FDG uptake” and was not applicable in the present material. If there was a discrepancy between the readers a consensus was reached.

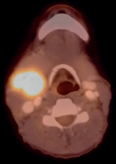


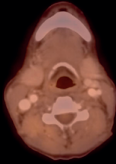
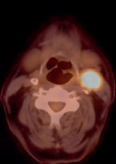


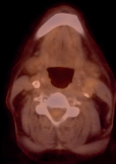
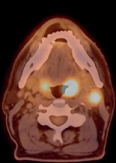


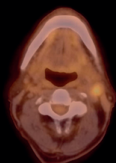



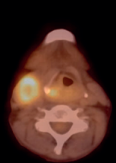
Baseline		6 weeks after radiotherapy		
Fusion PET/CT	¹⁸ F-FDG-PET	¹⁸ F-FDG-PET	Fusion PET/CT	Deauville score
				2
				3
				4
				5

Fig 12
 PET images and corresponding Deauville criteria. Score 1 was not used and is not depicted in the figure. Score 2 – likely complete response, score 3 – likely postradiation inflammation, score 4 – likely persistent tumour, score 5 – persistent tumour.

Therapy and follow-up

Radiotherapy

RT was delivered five days a week. In Sweden, RT was administered with IMRT, with conventional fractionation 2 Gy/day, to an absorbed dose of 68 Gy to known disease and 54.4 Gy, prophylactic dose, to elective neck levels; in Australia, with 3-dimensional conformal RT and two different protocols were used at the discretion of the radiotherapist. The patients received either 2 Gy/fraction to a dose of 70 Gy or a

concomitant boost schedule to 66 Gy with 2 Gy every morning over five weeks and an afternoon boost of 1.6 Gy. Elective sites were treated to 50 Gy in 2 Gy/day over five weeks.

Systemic therapy

Systemic therapy was given according to local guidelines. In Sweden, six of 106, 5.7%, patients with advanced, high-risk tumours received concurrent chemotherapy with cisplatin. Two patients were scheduled for induction cisplatin and 5-fluorouracil (PF). In Australia, 102/112, 91% of the study population received chemotherapy, most of them with cisplatin (n=86) but in cases of contraindications to cisplatin, cetuximab (n=10) or carboplatin/PF (n=6) was used and patients with a low volume disease, T0-2, N1 did not always receive systemic therapy.

Primary site response evaluation

In papers I and II, the primary site response evaluation included a PET scan six weeks posttherapy (further discussed below). Two weeks afterwards an experienced head and neck surgeon assessed the patient according to routines. The assessment comprised a physical examination, most often endoscopic under anaesthesia, with or without biopsies. The PET result was known to the surgeon and was used to direct the biopsies when indicated. The pathologist reported the biopsies as remaining tumour, benign epithelia or dysplasia.

Neck dissections

A ND was performed if the first posttreatment PET scan was considered positive or if a second posttreatment PET scan was considered positive or equivocal. The extent of the ND was at the discretion of the head and neck surgeon.

Follow-up

Clinical follow-up was done according to local guidelines in Sweden and Australia. PET imaging was as per protocol above. Additional imaging, cytology or biopsies was performed if clinical suspicion of recurrence was raised.

Statistics

Definitions of endpoints

A residual tumour in the neck was characterized as persistent tumour according to the pathology report after a ND scheduled as a result of any of the PET scans in the study protocols.

Tumours in the neck diagnosed later than any of the PET scans in the study protocols were categorized as recurrences.

Complete response to RT was defined as no residual tumour in the neck according to PET after completed RT.

Regional control was defined as no tumour involving the neck after completed therapy (RT +/- ND) until last date of follow-up.

A residual tumour at the primary site was characterized as persistent tumour according to the pathology report on biopsies taken at the primary site evaluation scheduled in the study protocol. Tumours at the primary site diagnosed later than that were categorized as local recurrences.

The time from diagnosis (papers I and IV) or the time from completion of therapy (paper III) to last date of follow-up or recurrence was chosen for Kaplan-Meier estimates.

A true positive PET scan was confirmed by a pathology report showing residual tumour or by the clinical follow-up.

A true negative PET scan was defined as no signs of tumour in the neck within 12 months after the PET scan in paper I and no signs of tumour in the neck during the entire follow-up time in papers III and IV.

In paper II, a true negative PET scan was confirmed with what we considered gold standard, physical examination with or without biopsy.

Statistical methods

To assess the usefulness of our diagnostic tool, PET, the following statistical definitions and methods were chosen:

Sensitivity: The true positive rate describes how likely a PET is to detect the presence of a tumour in someone who has a tumour.

Specificity: The true negative rate describes how likely a PET is to detect the absence of a tumour in someone who does not have a tumour.

Predictive values calculate a tests' probability to diagnose or out rule a condition and depends on the prevalence of the condition in question.

The PPV: describes the probability that positive PET scans are true positive (*i.e.*, caused by viable tumour cells). The PPV is bound to be low with a low prevalence of viable tumour cells in a population.

The NPV: describes the probability that negative PET scans are true negative.

Accuracy describes how well a binary classification test correctly identifies or excludes a condition *i.e.*, the proportion of true test results in a population.

A p-value of <0.05 was considered significant. 95% confidence intervals (CI) were used.

Survival analysis data was calculated using the Kaplan-Meier method. Log-rank test was used for comparison between groups.

In paper IV, receiver operating characteristic (ROC) curve analysis was performed for the Likert scale and SUVmax and the ROC data used to determine cutoff values. Differences between groups were evaluated by Fisher's exact test or chi-square test for categorical variables and Mann-Whitney U-test for continuous variables.

RESULTS

Paper I

The aim of paper I was to evaluate if an early PET scan, six weeks after RT, was able to adequately select patients in whom a ND can be safely omitted. Since previous studies had indicated a higher accuracy in later scheduled PET scans we were concerned about missing any residual tumour and chose to perform an additional PET scan 18 weeks after RT. Endpoints were OS and isolated neck recurrences. Patient demographics are depicted in table 2.

Table 2

Patient (n=106) and tumour (n=108) characteristics.

Patient characteristics, no. of patients=106	Frequency
Age	
Median (range)	61 (34–89)
Sex	
Female	28 (26%)
Male	78 (74%)
Primary site (no. of tumours=108)	
Tonsil	72 (67%)
Tongue base	18 (17%)
Oropharynx (other than above)	6 (5%)
Supraglottis	7 (7%)
Hypopharynx	5 (4%)
HPV or p16[†] positivity (no. of tumours=108)	
HPV-positive	43 (40%)
p16-positive	36 (33%)
HPV or p16-negative	26 (24%)
Unknown	3 (3%)
Differentiation (no. of tumours=108)	
Well differentiated	6 (6%)
Moderately differentiated	28 (26%)
Poorly differentiated	63 (58%)
Not specified	11 (10%)
Smoking status	
Current smoker or stopped smoking <6 months	32 (30%)
Ex-smoker, stopped smoking >6 months	43 (41%)
Never smoked	31 (29%)
Treatment	
Radiotherapy alone	98 (92%)
Concurrent cisplatin	6 (6%)
Induction PF [‡]	2 (2%)

*HPV = human papillomavirus; [†]p16 = p16INKA; [‡]PF = cisplatin and 5-fluorouracil.

Of 106 included patients, all but one was considered in complete remission regarding the primary site and thus 105 patients were eligible for analysis. The restaging PET scan, PET6w, was performed on average 44 days posttherapy (with 90% of the patients within the range of 37-52 days). Based on the PET6w results 17 patients underwent ND whereof one bilaterally. Ten of 18 neck specimens harboured remaining tumour cells.

With a median follow-up time of 25 months (range 9-49 months) and presented in paper I, PET6w was false negative in six cases, three of these were detected at PET18w and the additional three were diagnosed during the following 12 months.

In detecting residual neck tumour, performing PET six weeks posttherapy showed a sensitivity, specificity, PPV and NPV of 62.5% (CI 35.9-83.7%), 92% (CI 84.7-96.3%), 56% (CI 31.3-77.6%) and 94% (CI 86.9-97.5%) respectively.

The 2-year OS rate was 86.3% and LRC was 85.4%.

Looking specifically at the OPC patients, with HPV/p16 positive (n=75) and negative (n=16) tumours the PPV was 41.7% (CI 16.5-71.4%) and 100% (CI 39.6-100%) respectively and the NPV was 94.1% (CI 84.9-98.1%) and 92.9% (CI 64.2-99.6%) respectively.

In total, four isolated neck recurrences occurred. The four patients underwent ND. At the time of analysis, two of them were classified as alive, no evidence of disease (ANED) and two patients who had had surgery with positive margins were classified as alive with disease (AWD).

There was a significant difference in the 2-year OS between patients with HPV/p16 positive, 95.3%, and negative, 58.7%, tumours ($p<0.00001$).

After PET6w or PET18w, 12 patients had residual tumour in the neck according to the pathology report of the ND specimen. Six of them are ANED and six are dead of disease (DOD).

The three PET scans included in the protocol added valuable information regarding staging and synchronous tumours. Following baseline PET, one patient was re-classified to a more advanced T classification and 14 patients to a more advanced N classification. Seven of the patients changed tumour stage from 3 to 4a. One patient was diagnosed with a pulmonary metastasis not noticed in the work-up. The PET examinations revealed six synchronous tumours, four malignant (colon=2; lung=1; hypopharynx=1) and two benign (adrenal adenoma=1; prolactinoma=1) tumours. Another four suspicious lesions could be discarded after additional examinations.

Second analysis

The following results are from a second analysis that was performed with a median follow-up of 42 months (range 17-66 months).

The 3.5-year OS rate was 83.7%. For patients with HPV/p16 positive and negative tumours the OS was 94.7% and 52.3%, respectively ($p < 0.00001$), see figure 13.

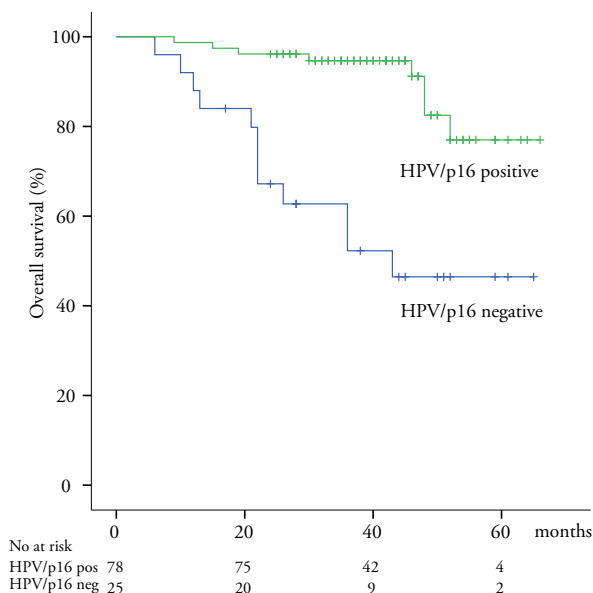


Fig 13

3.5-year OS in patients with HPV/p16-positive tumours, 94.7% and HPV/p16-negative tumours 52.3% ($p < 0.00001$).

There was no significant difference ($=0.075$) in LRC between patients with HPV/p16 positive, 80.9%, and negative tumours, 66.9% but in DFS, 75.4% and 47.3%, respectively ($p = 0.003$).

In total, 28 patients suffered from recurrences during the follow-up period, see table 3 for first failure sites according to HPV/p16 status.

Table 3

Failures during the follow-up period according to HPV/p16 status.

First failure site	All patients n=105, (%)	HPV/p16 pos n=78, (%)	HPV/p16 neg n=25, (%)
T	9 (8.6)	6 (7.7)	3 (12.0)
N	5 (4.8)	3 (3.8)	2 (8.0)
M	7 (6.7)	3 (3.8)	4 (16.0)
TN	5 (4.8)	4 (5.1)	1 (4.0)
NM	2 (1.9)	1 (1.2)	1 (4.0)
Total	28 (26.8)	17 (21.8)	11 (44)

50% of the failures involved the primary tumour site. Five isolated neck recurrences were diagnosed, three of them were HPV/p16 positive and two negative. The two patients with positive margins mentioned in the primary analysis had additional (C)RT and are in complete remission. A fifth patient, with a very late contralateral recurrence more than four years after completion of therapy, also had a ND and is ANED.

For recurrences according to initial N classification see table 4.

Table 4

Failures during the follow-up period according to initial N classification.

First failure site	Total n=105, (%)	N1 n=14, (%)	N2a n=18, (%)	N2b n=58, (%)	N2c n=13, (%)	N3 n=2, (%)
T	9 (8.6)	1 (7.1)	2 (11.1)	4 (6.9)	2 (15.4)	-
N	5 (4.8)	-	-	5 (8.6)	-	-
M	7 (6.7)	-	-	3 (5.2)	4 (30.7)	-
TN	5 (4.8)	1 (7.1)	-	4 (6.9)	-	-
NM	2 (1.9)	-	-	1 (1.7)	1 (7.7)	-
Total	28 (26.8)	2 (14.2)	2 (11.1)	17 (29.3)	7 (53.8)	-

The survival rate for patients with recurrences is generally regarded as poor. In this study cohort the 1-year survival rate after a locoregional recurrence for patients with HPV/p16 positive tumours is 76.6% compared to patients with HPV/p16 negative tumours, 23.9% ($p=0.0003$).

Paper II

In paper II, the objective was to assess the accuracy of PET in evaluating primary site response after RT by comparing the PET result with the current gold standard that was physical examination, often endoscopy under general anaesthesia, with or without biopsies.

Of the 106 patients, 82 patients were eligible for this analysis. At the baseline PET, there was no visible hypermetabolism at the primary site in 24 patients whereof 21 had been subjected to tonsillectomy in the work-up and three patients had microscopic tongue base tumours. One patient had two simultaneous primary tumours, one tonsillar and one hypopharyngeal cancer.

Evaluation of the primary tumour site was performed with knowledge of the PET result by the head and neck surgeon, on average seven days after the PET scan. The vast majority of the patients were examined under general anaesthesia with biopsies taken, see table 5.

Table 5

Clinical evaluation of the primary site.

n=82	Biopsy	No biopsy
Endoscopy during anaesthesia	65	12
Clinical outpatient assessment	2	3

For PET results in comparison with the pathology report, see table 6.

Table 6

PET results in comparison with the pathology report.

PET PAD/px	No visual hypermetabolism	Remaining hypermetabolism	Equivocal	Total
Negative	49	3	11	63
Dysplasia	3	0	0	3
Positive	0	1	0	1
No biopsy	12	0	3	15
Total	64	4	14	82

Only one patient turned out to have a residual tumour at the primary site after RT. The tumour was clearly hypermetabolic at the PET scan. Residual tumour was also suspected at a physical examination and an endoscopy with biopsy confirmed the

status. Salvage surgery was performed but the patient died of the disease from metastasis soon afterwards.

PET demonstrated a sensitivity of 100% (CI 5.4%-100%), specificity 78% (CI 65.2-86.9%), PPV 6% (0.3-33.9%), NPV 100% (90.9-100%) and an accuracy of 78% in detecting residual disease.

During the follow-up period (median 42 months) 14 recurrences involving the primary site were diagnosed. They occurred at a median time of 12 months after the therapy evaluation (3-31 months). All of them had a negative PET scan, normal clinical status during endoscopy and benign biopsies.

Paper III

The objectives of paper III were to establish if PET is an appropriate way to spare ND after organ preservation therapy and if PET-negative nodes can be safely observed without compromising isolated nodal control or OS.

The median follow-up time in this long-term analysis was 62 months (range 23-104 months, interquartile range 54-67 months) and 112 patients were included. They had all been restaged with PET 12 weeks after the completion of the chemotherapy.

All patients also had a CT scan 12 weeks after the treatment but the metabolic response determined the management of the neck. There were no neck node involved failures in any patients with an incomplete response on CT and a complete metabolic response on PET.

Nine patients had an incomplete metabolic response according to PET and eight of them underwent ND. One of the patients had developed pulmonary metastases and was considered inappropriate for further surgical treatment. Six out of the eight ND specimens were reported with residual tumour cells.

Of the 103 observed patients, two patients soon suffered from composite nodal failures (one locoregional and one regional/distant recurrence). After 27 months, one patient was diagnosed with an isolated nodal failure.

The sensitivity, specificity, PPV and NPV values for PET 12 weeks posttherapy in detecting residual tumours were 70% (CI, 35.4-91.9%), 98% (CI 92.4-99.7%), 77.8% (CI 40.2-96.1%), 97.1% (CI 91.1-99.2%).

In OPC patients with p16 positive (n=59) and negative (n=18) tumours the PPV was 66.7% (CI 12.5-98.2%) and 75% (CI 21.9-98.7%) respectively and the NPV was 96.4% (CI 86.6-99.4%) and 92.9 (CI 64.2-99.6%).

The 5-year OS rate in the study population was 69%.

The most common failure site was distant metastasis and 80.8% of the recurrences occurred during the first two years after treatment. For first failure sites, see table 7.

Table 7

Failures during the follow-up period according to p16 status.

First failure site	All patients n=112, (%)	p16 pos n=59, (%)	p16 neg n=18, (%)	p16 unknown n=11, (%)
T	2 (1.8)	1 (1.7)	-	1 (9.1)
N	3 (2.7)	1 (1.7)	2 (11.1)	-
M	12 (10.7)	6 (10.2)	-	6 (54.5)
TN	1 (0.9)	-	1 (5.6)	-
TM	2 (1.8)	-	-	2 (18.2)
NM	1 (0.9)	1 (1.7)	-	-
Total	21 (18.8)	9 (15.3)	3 (16.7)	9 (81.8)

For recurrences in the whole cohort according to initial N classification see table 8.

Table 8

Failures during the follow-up period according to initial N classification.

First failure site	Total n=112, (%)	N1 n=14, (%)	N2 (NPC) n=9, (%)	N2a n=11, (%)	N2b n=43, (%)	N2c n=21, (%)	N3 n=14, (%)	
T	2 (1.8)	-	-	-	-	2 (9.5)	-	
N	3 (2.7)	1 (7.1)	-	-	-	1 (4.8)	1 (7.1)	
M	12 (10.7)	-	1 (11.1)	-	5 (11.6)	1 (4.8)	5 (35.7)	
TN	1 (0.9)	1 (7.1)	-	-	-	-	-	
TM	2 (1.8)	-	-	-	1 (2.3)	-	1 (7.1)	
NM	1 (0.9)	-	-	-	-	-	1 (7.1)	
Total	21 (18.8)	2 (14.2)	1 (11.1)	-	6 (13.9)	4 (19.1)	8 (57.0)	

Paper IV

In the last paper, the purpose was to examine if a 5-point Likert scale can sharpen the evaluation of therapy response in PET scans and also to study the performance of three different methods of PET evaluation and their relation to therapy outcome. The assessment methods used were visual inspection, a Likert scale according to the Deauville criteria and SUVmax.

As previously described, the 105 patients with complete primary site response in this study population had a PET scan six weeks after treatment. The PET scans were assessed as part of the clinical routine with visual evaluation and for the purpose of this analysis categorized as responders (n=75), non-responders (n=11) or equivocal (n=19).

Regarding the 5-point scale according to the Deauville criteria, 104 patients were eligible since adequate scanning including the mediastinal blood pool was missing in one patient. No patient fell into category one. The 5-point scale was dichotomized and patients in category two and three were defined as responders and patients in category four and five as non-responders.

A ROC analysis was performed and the ROC data was used to determine cutoff values for SUVmax. Patients with SUVmax values ≤ 2 were defined as responders and patients with values > 2 as non-responders.

All methods significantly correlated to metabolic response and neck node remission ($p < 0.0005$).

The positive and negative predictive values for predicting nodal control after RT were 68.7% (CI 41.5-87.9%) and 86.4% (CI 77.0-92.5%) for the dichotomized 5-point scale and the accuracy was 83.6%. Corresponding figures for SUVmax was 37.3% (CI 24.5-51.9) and 92.6% (CI 81.2-97.6) giving an accuracy of 65.7%.

A significant difference in regional control was shown for the different categories of visual inspection ($p < 0.0005$), for the dichotomized 5-point scale ($p < 0.0005$) and for SUVmax ≤ 2 compared with > 2 ($p = 0.0005$), see figure 14. There were no similar findings for OS.

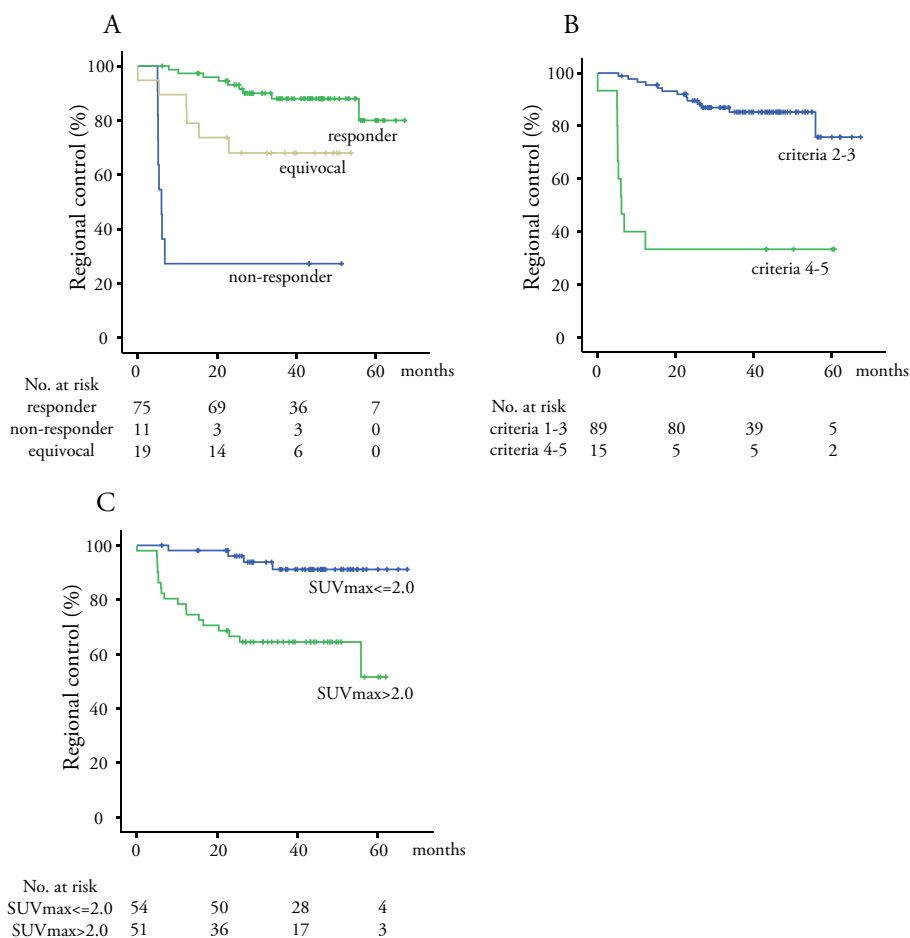


Fig 14

Regional control in relation to visual inspection (A), the Likert scale (B) and SUVmax (C).

Visual inspection assessed 19 PET scans as equivocal regarding the neck nodes. In six of these patients residual tumours were found following ND or a neck node involved failure developed during the follow-up period. Regional control was maintained in the remaining 13 patients.

When the Deauville criteria was applied to scans judged as equivocal 15/19, 79% of the patients were correctly classified into groups of responders i.e., patients with score 2 to 3, and non-responders i.e., patients with score 4 to 5 but no significance was reached ($p=0.07$).

Among the six patients where regional remission failed, three patients were scored 4 to 5 and three patients were scored 3. The latter were two patients with tonsillar tumours where locoregional recurrences were diagnosed nine and 19 months after therapy respectively. The third patient had a supraglottic tumour, with a neck recurrence, 12 months after therapy, successfully salvaged by surgery.

Complete response was noted in 13 patients whereof 12 were scored 2 to 3 according to the 5-point scale. The last patient scored 5 and had a SUVmax of 7.1 but no remaining tumour cells were found in the neck node specimen.

SUVmax was not able to adequately categorize PET scans assessed as equivocal into responders and non-responders ($p=0.28$).

According to the ROC analysis of PET scans judged as equivocal the 5-point Likert scale was superior to SUVmax in correctly identifying the level of metabolism that correlated to regional tumour control, with an AUC of 0.82 (CI 0.65-0.99) compared to 0.67 (CI 0.41-0.93).

DISCUSSION

Head and neck cancer is a heterogeneous group of tumours. The increasing knowledge about HPV and other prognostic and predictive markers has yet to prove that treatment and follow-up can be individualized. The present work has focused on PET in different aspects of treatment evaluation of HNSCC.

Long-term side effects of HNSCC treatment adversely affect patients' quality of life. There is a need to reduce therapy intensity without compromising LRC and survival.

Before the initiation of these studies, there was an ongoing debate concerning routine ND following organ preservation therapy. The debate is, to a certain extent, still ongoing. A ND was traditionally part of the protocol. Persistent tumour cells in the neck after (C)RT are usually reported in no more than 30% of the surgical specimen [167-170] thus challenging the justification for systematic ND. Consequently, it is important to adequately select patients benefitting from ND.

Summarizing papers I and III, a PET based protocol for management of the neck after (C)RT is an excellent way of sparing ND without a decrease in regional control. That accounts for patients with both HPV/p16 positive and negative tumours. In study I and study III, five and one isolated nodal recurrences respectively, occurred in the two cohorts when systemic surgery was omitted. With the addition of composite regional recurrences the failure rate remains similar or less compared with previous reports presenting a neck failure rate of 6-12% despite systemic posttherapy ND [143, 167, 171]. Even in patients with isolated neck failures one can be optimistic since five out of the six patients are ANED after salvage surgery +/- additional therapy with a follow-up time of 5.2-23.2 months. Agrawal et al, have reported a 5-year OS of only 12% and a median survival of 17.8 months among patients with regional failures after radical therapy *i.e.*, surgery alone or in combination with RT)[172].

Neither is OS negatively affected by the omission of ND in cases with complete metabolic response after therapy. The 5-year OS rate in the Australian material is 69% and the 3.5 year OS rate in the Swedish material is 83.7%.

The timing of treatment evaluation has also been a matter of debate. With the results from paper I at hand we believe that accuracy would have been better if the PET evaluation was scheduled later than six weeks post RT, although we hypothesized that a PET evaluation at that time would be sufficient to select for ND. A PET scan scheduled 12 weeks after therapy obtains higher predictive values and ND can be

performed after that without decreased LRC or increased surgical complications [173]. In a retrospective review of 247 patients a similar accuracy was found for first posttreatment PET scans performed more than seven weeks after therapy but a significantly lower accuracy for earlier PET scans ($p < 0.05$) [174].

There is a noteworthy difference in the frequency of chemotherapy between the Swedish and Australian study population. Nine percent of the Swedish patients received CRT and 92% of the Australians received CRT although the patient demographics were similar. Additionally, there was a difference in patterns of failure, with primary site failures more frequent in the Swedish cohort and distant failures as the most frequent type of recurrence in the Australian cohort. The difference is shown in the 2-year LRC rate, 85.4 % and 93%, but the 2-year OS rate was very alike between the cohorts, 86.3 and 88%, for the Swedish and Australian patients respectively.

The number of patients is limited but the addition of chemotherapy does not seem to prevent distant metastases or increase survival but may reduce the risk for locoregional recurrence. This is in concordance with a meta-analysis performed by Pignon et al where the use of concomitant chemotherapy was beneficial for LRC but not that obvious when it came to distant control [45].

Papers I and III were based on prospective studies. It would have strengthened the conclusions but required larger study populations if a randomized interventional PET study with two different treatment arms had been performed; systemic posttherapy ND and PET determined management of the neck. In our studies the populations are too small to draw conclusions about the possible benefit of routine ND in subgroups of patients *e.g.*, patients with high N classification or HPV/p16 negative tumours.

Our main concern, maintaining LRC and OS, is achieved with a PET-guided management of the neck. An intriguing question is if there could be other advantages of systematic ND like prevention of distant metastases? Ranck et al, have retrospectively studied 287 patients where 74 had a posttherapy ND and 213 patients were observed. The management of the neck was determined by response according to CT. Patients with N2b-N3 disease with a posttherapy ND demonstrated a significant advantage in local control, distant failure free survival and OS. This could not be shown for patients with lower N classifications. The decrease in non-regional failures is interesting and the authors speculate about the possibilities of a restored immune function or a prevention of reseeding after clearance of involved dysfunctional lymph nodes [175]. The endpoints for our studies have been isolated nodal control and it might be questioned in the light of the findings of Ranck et al [175]. Further prospective studies are needed to address this issue properly.

Our results, where ND can be safely omitted in patients with complete metabolic response are in line with previous retrospective reports on the outcome of observation versus ND after organ preservation therapy. In a large study by Thariat et al with 880 patients included, the outcome between patients who underwent ND or not after

therapy was assessed. Among the 377 patients who had achieved complete response to (C)RT as assessed by physical examination and/or CT, neck failure rates were similar to ours, 7 to 8%, regardless of posttreatment ND. When the neck node response was equivocal (n=232), 20% of the patients who underwent ND and 32% of those who did not experienced a neck failure [176]. The results support a policy where ND should not be carried out routinely after (C)RT when a complete response is achieved.

Returning to the discussion about N2-3 tumours, several studies describe the neck failure rate in the observed neck as very low even without the use of PET for response assessment [177, 178]. Soltys et al have shown that 4% of patients with N2-3 tumours with a complete response after therapy might have benefitted from a ND, but only 56 patients were studied [179]. When a PET-directed management of solely N3 tumours is performed the failure site is mainly distant [180]. The authors conclude that focus should shift from routine ND to adjusted systemic therapy in this subgroup of patients.

One of our intentions by trying to avoid unnecessary ND is the potential reduction of treatment related morbidity. In retrospect, it would have been an advantage if quality of life studies had been included during the follow-up period. However, based on the existing literature, we can assume that the patients that were spared a ND suffer from less morbidity [181-183].

When PET is scheduled as early as six weeks after treatment it is also suitable to assess primary tumour response. In paper II, 82 patients were evaluated with PET and physical examination, in most cases endoscopy under anaesthesia with biopsies. Bearing in mind that no imaging modality is sensitive enough to detect very small or especially submucosal tumour spread [117] PET demonstrated a high NPV and a very low PPV. The results reflect that excellent primary site remission was obtained; only one patient presented a residual tumour. Due to that circumstance it is hard to actually draw any conclusions regarding the ability of PET in this study. On the other hand, previous works have also reported high NPV but also better PPV when PET was used for primary site assessment four weeks posttherapy [140].

The residual primary tumour rate in paper II was calculated to 1% as assessed at six to seven weeks posttreatment. This might be an exceptionally low figure explained by the substantial number of patients with HPV/p16 positive tumours. In the Australian study population the residual primary tumour rate was 3% but less favourable results with rates >10% have also been reported [140, 144].

However, it is apparent that routine endoscopy with biopsies is superfluous if the frequency of residual primary site tumour is low. A thorough physical examination at the outpatient clinic, preferably in combination with PET, should be a sufficient treatment evaluation. Endoscopy with biopsies will be performed if the examination is suspicious of residual tumour.

Even if a complete response at the primary site is obtained according to the evaluation six weeks posttherapy it is still a common site for failures, some of them after a short period of time. This fact emphasizes the importance of thorough follow-up especially during the first and second year after treatment. One can also argue for a later scheduled primary site evaluation with regards to false positive PET findings and dysplasia if biopsies are performed before acute RT effects like mucositis have subsided.

As is the case with unnecessary NDs, unnecessary procedures with anaesthesia and potential complications should be avoided for the benefit of the patient and also for the health care system [184].

Despite a widespread use of PET in head and neck cancer patients, there is no consensus on how to assess report or use cutoff values in the evaluation of treatment. Quantitative (not in routine clinical practice), different types of semiquantitative assessments and qualitative evaluation are all used alone or in combinations.

All PET evaluations in the thesis have been performed by visual inspection using adjacent tissue activity (and in Australia also liver activity) as reference since SUV is not proven to ameliorate diagnostic accuracy [97, 98].

Equivocal results, no matter what kind of investigation that has been performed, are always unsatisfactory. Apart from uncertainty and worry, it can cause repeated or additional procedures. The number of equivocal results differs. In papers I and III it was 18% and 10% respectively. The different frequencies can depend on the timing of the PET scan where posttherapy inflammatory changes are more likely to confound the result if the scan is performed early after therapy. The main reason for conducting the study presented in paper IV was to determine if the number of PET scans reported as equivocal regarding the neck nodes could be reduced by referring them to a group of responders or non-responders. A similar study on the primary site would be interesting since we experienced an equal amount of equivocal PET results in paper II.

A 5-point Likert scale according to the Deauville criteria used in the treatment monitoring of lymphoma patients was used as well as SUVmax. The 5-point scale improved the reports and categorized 15/19, 79%, of the equivocal PET scans correctly. SUVmax was less reliable in that respect. However, the sample size was small and none of the methods reached significance. One patient was falsely classified as a non-responder and three were false negative although recurrences occurred more than nine months after the PET scan was performed.

There is still no imaging modality in clinical use or other ways of evaluating HNSCC treatment that are sensitive enough to detect sporadic tumour cells or small tumour clusters. The limit or resolution for detecting cancer cells with modern PET cameras is 0.4-1.0 cm, corresponding to around 0.1-1g or 10^8 - 10^9 tumour cells. It is estimated that as many as 10^7 tumour cells can be present after RT but still not be detected on a

PET scan. However, a negative PET scan posttherapy corresponds to good prognosis even if it is not necessary a total absence of tumour cells [90].

According to the results in paper IV, the three different methods of PET scan evaluation, visual inspection, the 5-point Likert scale and SUVmax were able to categorize responders and non-responders related to metabolic response and regional control. In this setting, the 5-point scale was superior to SUVmax in categorizing PET scans judged as equivocal into responders and non-responders. However, repeated delayed PET scans with SUV calculations might also be able to differ between inflammation and increased metabolism caused by cancer and reduce the number of equivocal and false positive scans [185]. Even so, there is to date no consistent way of performing semiquantitative analysis and calculating SUV and cutoff values vary between studies.

We believe that qualitative interpretation, visual inspection “enhanced” by the use of a 5-point Likert scale, is the most solid way of evaluating PET scans. A Likert scale, either according to the Deauville or the Hopkins criteria [103], gives distinct reports, easily interpreted by the clinician, and is also the tool needed for a common way of reporting PET results, facilitating communication and comparison between institutions.

FUTURE PERSPECTIVES AND FINAL CONCLUSIONS

So far, PET is proven to be the most accurate imaging modality of the evaluation of neck node response to organ preservation therapy. Even though qualitative assessment with visual inspection and preferably with a Likert scale is satisfactory, the measurement of tumour metabolism could yet be refined. Other internal reference tissues might be explored such as cerebellum. SUV can be measured with multiple methods and new methods can be expected to be introduced. We will probably also see novel molecular tracers used for PET imaging.

One of the most important current issues is to agree upon a standardization of PET assessment and reporting in order to facilitate larger multicenter studies and/or compare results from different trials.

The role of PET as part of follow-up is yet to be established. So far, PET seems to be a promising method to detect subclinical recurrences although the timing and frequency of the PET scans has yet to be determined as well as the cost-benefit of such a protocol. Will we be able to improve the success rate of salvage procedures with a potentially earlier detection of recurrences? We would like to address this issue in a prospective study.

There are also other imaging techniques challenging PET or complementing it. MR-PET, functional MR imaging like dynamic contrast-enhanced MR and diffusion-weighted MR are examples of coming, promising, techniques.

Planned ND after (C)RT can, for now, be considered obsolete. However, the understanding of patterns of failure in patients with positive neck nodes is still limited and with future increasing knowledge of biomarkers, it is hard to rule out if high-risk subgroups of patients onwards would benefit from a planned ND after (C)RT.

A lot of work has been performed on predictive markers for radiosensitivity and it is still ongoing. We are aiming to analyze the diagnostic biopsies and the neck specimen from the Swedish study population for the presence of alpha B-Crystallin, Survivin, CD 133, CD 44.

Hopefully, the future carries increased knowledge about the biologic differences in head and neck cancer tumours and their hosts, the patients. Molecular profiling and

targeted agents as well as improvement in treatment response assessment will pave the way to greater tailoring of therapy.

Conclusions based on this thesis:

- PET-guided management of the neck following organ preservation therapy is an appropriate way to spare neck dissections in patients with node-positive head and neck squamous cell carcinoma regardless of primary site, nodal-classification or HPV/p16-status.
- PET-negative neck nodes after (C)RT can be observed with acceptable nodal control and overall survival
- The PET evaluation of treatment response should be scheduled later than six weeks after therapy to optimize accuracy.
- Planned endoscopy with biopsies for evaluation of primary site response to radiotherapy is superfluous. A thorough physical examination, preferably supported by a PET scan, is sufficient.
- Qualitative interpretation with visual inspection is a satisfactory way to assess tumour metabolism in evaluation of response after RT.
- The use of a Likert scale in the interpretation of PET scans is a promising tool to refer PET scans, visually assessed as equivocal, to categories of responders or non-responders.

ACKNOWLEDGEMENTS

This work has been integrated in my clinical work and everyday life for several years. It would never have been completed if I had not received a tremendous support in all areas. I wish to express my sincere gratitude to my family, my friends and colleagues and to all the patients who participated in the studies and made the work possible. However, some of you have been particularly involved and I especially want to thank:

Eva Brun. You can infect anyone with your enthusiasm, your energy and your never ending positive view of difficult projects. You are so generous with your vast experience and your time. And Camp Vikhög – splendid! We have shared many fun moments and many cups of tea while tapping on the computer in your sofa and I am happy to call you my friend. You should be careful who you choose as a supervisor – I could never have found a better one!

Peter Wahlberg, my role model at work – tremendously skilled and knowledgeable. You are my always so supportive co-supervisor and the man who introduced me to Eva and also, with an endless patience, tries to teach me surgery as well as science. It is a privilege. Oh, oobe doo, I wanna be like yoo-hoo-hoo...

Elisabeth Kjellén and Per Nilsson, my bonus supervisors. And what a bonus! You have tried to teach me about science, radiotherapy and statistics. You are most proficient and clear sighted and I am truly honoured that you wanted to participate at Camp Vikhög with Eva, Peter and me. You have really made an effort to get me through this work. Thank you.

Sandro Porceddu (co-supervisor), and Benjamin Chua. I thank you for welcoming me to Princess Alexandra Hospital in Brisbane and letting me work with you. It was a great opportunity for me and you generously shared your knowledge and helped me through paper III. I hope to see you soon again!

Lars Ekblad, for taking on the role as co-supervisor and for doing a great work as head of the lab-group. The road of science is winding and I fell off the lab path rather early along the way but I hope to work with you more closely in the future!

Johan Wennerberg, emeritus head of the lab-group, for revealing excel spread sheet secrets and always being prepared to answer my various questions. You, and the rest of the **lab-group**, have also contributed, with valuable input and discussions, to this thesis.

Lennart Greiff, the man, the myth, the concept. The most efficient man in Götaland and as such, also a great surgeon, researcher, friend and the best boss you can wish for. What would the head and neck-team do without you?

Anna Hafström and Per Fremlin, for being another very supportive couple, at the department of ORL-HNS and privately. Anna you are such a wonderful doctor and a good friend, skillful, funny and dedicated. And Per, you have turned out to be a grammar-dictator and hyphenophobic but also a man with unexpected knowledge – teaching me about the monetary value of a human body! Thanks you so much for linguistic advice and all the funny remarks about my shortcomings!

Anders Sandell and Jonathan Siikanen, who have been my life line to PET knowledge and really have tried to make me understand at least the basics of PET. I am very grateful for being given the opportunity of repeated PET lessons in your office, Anders!

Ulrika Bitzén, for sharing a nuclear physicians view of PET and for a fruitful cooperation so far. I do hope it will continue!

Marie Gisselsson-Solén and Johan Nilsson, my former roommates, and **all my colleagues** at the department of ORL-HNS with whom I can share failure and success, discuss problems and points of light. You actually make Monday mornings something I can look forward to!

Helena Marell Hesla, Anders Cervin and other “Brisbanian” friends who were constantly encouraging when I tried to gain momentum with this thesis during my year in Australia. But you also gilded our time there with a lot of enjoyable social happenings.

Mariann and Lennart Petersson for at even intervals, when it has just been too busy, taking care of our everyday life. You are always positive and it is a delight to have such parents-in-law!

Team Karlsson! My parents Iréne and Eije, my brother David and my sister-in-law Mariette. I can’t express how much you mean to me. You are always there when I need you, these last years as well as ever before. You have always believed in me. It is such a comfort to have you and it is always good fun when we get together!

Figge, Gustav and Ingrid. Now I get sentimental and I run out of words. You are undoubtedly the three best, most treasured and loved parts of my life. You make the life worth living. I love you.

REFERENCES

1. Mehanna H, West CM, Nutting C, Paleri V: Head and neck cancer--Part 2: Treatment and prognostic factors. *BMJ* 2010, 341:c4690.
2. Tiwana MS, Wu J, Hay J, Wong F, Cheung W, Olson RA: 25 year survival outcomes for squamous cell carcinomas of the head and neck: population-based outcomes from a Canadian province. *Oral Oncol* 2014, 50(7):651-656.
3. Pulte D, Brenner H: Changes in survival in head and neck cancers in the late 20th and early 21st century: a period analysis. *The oncologist* 2010, 15(9):994-1001.
4. Torre LA, Bray F, Siegel RL, Ferlay J, Lortet-Tieulent J, Jemal A: Global cancer statistics, 2012. *CA Cancer J Clin* 2015.
5. Hammarstedt L, Lindquist D, Dahlstrand H, Romanitan M, Dahlgren LO, Joneberg J, Creson N, Lindholm J, Ye W, Dalianis T *et al*: Human papillomavirus as a risk factor for the increase in incidence of tonsillar cancer. *Int J Cancer* 2006, 119(11):2620-2623.
6. Rietbergen MM, Leemans CR, Bloemena E, Heideman DA, Braakhuis BJ, Hesselink AT, Witte BI, Baatenburg de Jong RJ, Meijer CJ, Snijders PJ *et al*: Increasing prevalence rates of HPV attributable oropharyngeal squamous cell carcinomas in the Netherlands as assessed by a validated test algorithm. *Int J Cancer* 2013, 132(7):1565-1571.
7. Marklund L, Hammarstedt L: Impact of HPV in Oropharyngeal Cancer. *J Oncol* 2011, 2011:509036.
8. Blot WJ, McLaughlin JK, Winn DM, Austin DF, Greenberg RS, Preston-Martin S, Bernstein L, Schoenberg JB, Stemhagen A, Fraumeni JF, Jr.: Smoking and drinking in relation to oral and pharyngeal cancer. *Cancer Res* 1988, 48(11):3282-3287.
9. Rosenquist K, Wennerberg J, Schildt EB, Bladstrom A, Goran Hansson B, Andersson G: Oral status, oral infections and some lifestyle factors as risk factors for oral and oropharyngeal squamous cell carcinoma. A population-based case-control study in southern Sweden. *Acta Otolaryngol* 2005, 125(12):1327-1336.
10. Conway DI, Brenner DR, McMahon AD, Macpherson LM, Agudo A, Ahrens W, Bosetti C, Brenner H, Castellsague X, Chen C *et al*: Estimating and explaining the effect of education and income on head and neck cancer risk: INHANCE consortium pooled analysis of 31 case-control studies from 27 countries. *Int J Cancer* 2015, 136(5):1125-1139.
11. Negri E, Boffetta P, Berthiller J, Castellsague X, Curado MP, Dal Maso L, Daudt AW, Fabianova E, Fernandez L, Wunsch-Filho V *et al*: Family history of cancer: pooled

- analysis in the International Head and Neck Cancer Epidemiology Consortium. *Int J Cancer* 2009, 124(2):394-401.
12. Lacko M, Braakhuis BJ, Sturgis EM, Boedeker CC, Suarez C, Rinaldo A, Ferlito A, Takes RP: Genetic susceptibility to head and neck squamous cell carcinoma. *Int J Radiat Oncol Biol Phys* 2014, 89(1):38-48.
 13. Gillison ML, Shah KV: Human papillomavirus-associated head and neck squamous cell carcinoma: mounting evidence for an etiologic role for human papillomavirus in a subset of head and neck cancers. *Curr Opin Oncol* 2001, 13(3):183-188.
 14. zur Hausen H: Papillomaviruses causing cancer: evasion from host-cell control in early events in carcinogenesis. *J Natl Cancer Inst* 2000, 92(9):690-698.
 15. Rautava J, Syrjanen S: Biology of human papillomavirus infections in head and neck carcinogenesis. *Head Neck Pathol* 2012, 6 Suppl 1:S3-15.
 16. D'Souza G, Kreimer AR, Viscidi R, Pawlita M, Fakhry C, Koch WM, Westra WH, Gillison ML: Case-control study of human papillomavirus and oropharyngeal cancer. *N Engl J Med* 2007, 356(19):1944-1956.
 17. Mehanna H, Paleri V, West CM, Nutting C: Head and neck cancer--Part 1: Epidemiology, presentation, and prevention. *BMJ* 2010, 341:c4684.
 18. Oguejiofor KK, Hall JS, Mani N, Douglas C, Slevin NJ, Homer J, Hall G, West CM: The Prognostic Significance of the Biomarker p16 in Oropharyngeal Squamous Cell Carcinoma. *Clin Oncol (R Coll Radiol)* 2013.
 19. Fakhry C, Westra WH, Li S, Cmelak A, Ridge JA, Pinto H, Forastiere A, Gillison ML: Improved survival of patients with human papillomavirus-positive head and neck squamous cell carcinoma in a prospective clinical trial. *J Natl Cancer Inst* 2008, 100(4):261-269.
 20. Mirghani H, Amen F, Moreau F, Guigay J, Ferchiou M, Melkane AE, Hartl DM, Lacau St Guily J: Human papilloma virus testing in oropharyngeal squamous cell carcinoma: What the clinician should know. *Oral Oncol* 2013.
 21. Allen CT, Lewis JS, Jr., El-Mofty SK, Haughey BH, Nussenbaum B: Human papillomavirus and oropharynx cancer: biology, detection and clinical implications. *Laryngoscope* 2010, 120(9):1756-1772.
 22. Doxtader EE, Katzenstein AL: The relationship between p16 expression and high-risk human papillomavirus infection in squamous cell carcinomas from sites other than uterine cervix: a study of 137 cases. *Hum Pathol* 2012, 43(3):327-332.
 23. Gronhoj Larsen C, Gyldenlove M, Jensen DH, Therkildsen MH, Kiss K, Norrild B, Konge L, von Buchwald C: Correlation between human papillomavirus and p16 overexpression in oropharyngeal tumours: a systematic review. *Br J Cancer* 2014.
 24. Anneroth G, Batsakis J, Luna M: Review of the literature and a recommended system of malignancy grading in oral squamous cell carcinomas. *Scand J Dent Res* 1987, 95(3):229-249.

25. Paleri V, Wight RG, Silver CE, Haigentz M, Jr., Takes RP, Bradley PJ, Rinaldo A, Sanabria A, Bien S, Ferlito A: Comorbidity in head and neck cancer: a critical appraisal and recommendations for practice. *Oral Oncol* 2010, 46(10):712-719.
26. Wang JR, Habbous S, Espin-Garcia O, Chen D, Huang SH, Simpson C, Xu W, Liu F, Brown DH, Gilbert RW *et al*: Comorbidity and performance status as independent prognostic factors in head and neck squamous cell carcinoma patients. *Head Neck* 2014.
27. Boje CR, Dalton SO, Primdahl H, Kristensen CA, Andersen E, Johansen J, Andersen LJ, Overgaard J: Evaluation of comorbidity in 9388 head and neck cancer patients: a national cohort study from the DAHANCA database. *Radiother Oncol* 2014, 110(1):91-97.
28. Dayyani F, Etzel CJ, Liu M, Ho CH, Lippman SM, Tsao AS: Meta-analysis of the impact of human papillomavirus (HPV) on cancer risk and overall survival in head and neck squamous cell carcinomas (HNSCC). *Head Neck Oncol* 2010, 2:15.
29. Ang KK, Harris J, Wheeler R, Weber R, Rosenthal DI, Nguyen-Tan PF, Westra WH, Chung CH, Jordan RC, Lu C *et al*: Human papillomavirus and survival of patients with oropharyngeal cancer. *N Engl J Med* 2010, 363(1):24-35.
30. Bose P, Brockton NT, Dort JC: Head and neck cancer: from anatomy to biology. *Int J Cancer* 2013, 133(9):2013-2023.
31. Lin A, Hahn SM: Hypoxia imaging markers and applications for radiation treatment planning. *Semin Nucl Med* 2012, 42(5):343-352.
32. Robertson G, Greenlaw N, Steering Group Committee for the Scottish Audit of H, Neck C, Bray CA, Morrison DS: Explaining the effects of socio-economic deprivation on survival in a national prospective cohort study of 1909 patients with head and neck cancers. *Cancer Epidemiol* 2010, 34(6):682-688.
33. Mellin Dahlstrand H, Lindquist D, Bjornestal L, Ohlsson A, Dalianis T, Munck-Wikland E, Elmberger G: P16(INK4a) correlates to human papillomavirus presence, response to radiotherapy and clinical outcome in tonsillar carcinoma. *Anticancer Res* 2005, 25(6C):4375-4383.
34. Lassen P, Eriksen JG, Hamilton-Dutoit S, Tramm T, Alsner J, Overgaard J: Effect of HPV-associated p16INK4A expression on response to radiotherapy and survival in squamous cell carcinoma of the head and neck. *J Clin Oncol* 2009, 27(12):1992-1998.
35. Bol V, Gregoire V: Biological basis for increased sensitivity to radiation therapy in HPV-positive head and neck cancers. *Biomed Res Int* 2014, 2014:696028.
36. Pang E, Delic NC, Hong A, Zhang M, Rose BR, Lyons JG: Radiosensitization of oropharyngeal squamous cell carcinoma cells by human papillomavirus 16 oncoprotein E6 *I. *Int J Radiat Oncol Biol Phys* 2011, 79(3):860-865.
37. Hendrickson K, Phillips M, Smith W, Peterson L, Krohn K, Rajendran J: Hypoxia imaging with [F-18] FMISO-PET in head and neck cancer: potential for guiding intensity modulated radiation therapy in overcoming hypoxia-induced treatment resistance. *Radiother Oncol* 2011, 101(3):369-375.

38. Janssen HL, Haustermans KM, Balm AJ, Begg AC: Hypoxia in head and neck cancer: how much, how important? *Head Neck* 2005, 27(7):622-638.
39. Shah JP: Surgical approaches to the oral cavity primary and neck. *Int J Radiat Oncol Biol Phys* 2007, 69(2 Suppl):S15-18.
40. Weinstein GS, O'Malley BW, Jr., Magnuson JS, Carroll WR, Olsen KD, Daio L, Moore EJ, Holsinger FC: Transoral robotic surgery: a multicenter study to assess feasibility, safety, and surgical margins. *Laryngoscope* 2012, 122(8):1701-1707.
41. Sansoni ER, Gross ND: The role of transoral robotic surgery in the management of oropharyngeal squamous cell carcinoma: a current review. *Curr Oncol Rep* 2015, 17(3):432.
42. Byers RM: Modified neck dissection. A study of 967 cases from 1970 to 1980. *American journal of surgery* 1985, 150(4):414-421.
43. Basic Clinical Radiobiology, Fourth edition edn: CRC Press, Taylor&Francis Group, LLC; 2009.
44. Hong TS, Ritter MA, Tome WA, Harari PM: Intensity-modulated radiation therapy: emerging cancer treatment technology. *Br J Cancer* 2005, 92(10):1819-1824.
45. Pignon JP, le Maitre A, Maillard E, Bourhis J: Meta-analysis of chemotherapy in head and neck cancer (MACH-NC): an update on 93 randomised trials and 17,346 patients. *Radiother Oncol* 2009, 92(1):4-14.
46. Peters LJ, O'Sullivan B, Giralt J, Fitzgerald TJ, Trotti A, Bernier J, Bourhis J, Yuen K, Fisher R, Rischin D: Critical impact of radiotherapy protocol compliance and quality in the treatment of advanced head and neck cancer: results from TROG 02.02. *J Clin Oncol* 2010, 28(18):2996-3001.
47. Cooper JS, Fu K, Marks J, Silverman S: Late effects of radiation therapy in the head and neck region. *Int J Radiat Oncol Biol Phys* 1995, 31(5):1141-1164.
48. Kaye SB: New antimetabolites in cancer chemotherapy and their clinical impact. *Br J Cancer* 1998, 78 Suppl 3:1-7.
49. Bonner JA, Harari PM, Giralt J, Cohen RB, Jones CU, Sur RK, Raben D, Baselga J, Spencer SA, Zhu J *et al*: Radiotherapy plus cetuximab for locoregionally advanced head and neck cancer: 5-year survival data from a phase 3 randomised trial, and relation between cetuximab-induced rash and survival. *Lancet Oncol* 2010, 11(1):21-28.
50. Wilson GD, Bentzen SM, Harari PM: Biologic basis for combining drugs with radiation. *Seminars in radiation oncology* 2006, 16(1):2-9.
51. Peron J, Polivka V, Chabaud S, Poupert M, Ceruse P, Ramade A, Girodet D, Zrounba P, Fayette J: An effective and well-tolerated strategy in recurrent and/or metastatic head and neck cancer: successive lines of active chemotherapeutic agents. *BMC Cancer* 2014, 14:504.
52. O'Neill CB, Baxi SS, Atoria CL, O'Neill JP, Henman MC, Sherman EJ, Lee NY, Pfister DG, Elkin EB: Treatment-related toxicities in older adults with head and neck cancer: A population-based analysis. *Cancer* 2015.

53. Adelstein DJ, Lavertu P, Saxton JP, Secic M, Wood BG, Wanamaker JR, Eliachar I, Strome M, Larto MA: Mature results of a phase III randomized trial comparing concurrent chemoradiotherapy with radiation therapy alone in patients with stage III and IV squamous cell carcinoma of the head and neck. *Cancer* 2000, 88(4):876-883.
54. Machtay M, Moughan J, Trotti A, Garden AS, Weber RS, Cooper JS, Forastiere A, Ang KK: Factors associated with severe late toxicity after concurrent chemoradiation for locally advanced head and neck cancer: an RTOG analysis. *J Clin Oncol* 2008, 26(21):3582-3589.
55. Ye AY, Hay JH, Laskin JJ, Wu JS, Ho CC: Toxicity and outcomes in combined modality treatment of head and neck squamous cell carcinoma: cisplatin versus cetuximab. *J Cancer Res Ther* 2013, 9(4):607-612.
56. Manikantan K, Khode S, Dwivedi RC, Palav R, Nutting CM, Rhys-Evans P, Harrington KJ, Kazi R: Making sense of post-treatment surveillance in head and neck cancer: when and what of follow-up. *Cancer Treat Rev* 2009, 35(8):744-753.
57. Pagh A, Vedtofte T, Lynggaard CD, Rubek N, Lonka M, Johansen J, Andersen E, Kristensen CA, von Buchwald C, Andersen M *et al*: The value of routine follow-up after treatment for head and neck cancer. A National Survey from DAHANCA. *Acta Oncol* 2013, 52(2):277-284.
58. Nichols AC, Kneuert PJ, Deschler DG, Lin DT, Emerick KS, Clark JR, Busse PW, Rocco JW: Surgical salvage of the oropharynx after failure of organ-sparing therapy. *Head Neck* 2011, 33(4):516-524.
59. Guo T, Qualliotine JR, Ha PK, Califano JA, Kim Y, Saunders JR, Blanco RG, D'Souza G, Zhang Z, Chung CH *et al*: Surgical salvage improves overall survival for patients with HPV-positive and HPV-negative recurrent locoregional and distant metastatic oropharyngeal cancer. *Cancer* 2015.
60. Strojan P, Corry J, Eisbruch A, Vermorken JB, Mendenhall WM, Lee AW, Haigentz M, Jr., Beitler JJ, de Bree R, Takes RP *et al*: Recurrent and second primary squamous cell carcinoma of the head and neck: when and how to reirradiate. *Head Neck* 2015, 37(1):134-150.
61. Kasperts N, Slotman B, Leemans CR, Langendijk JA: A review on re-irradiation for recurrent and second primary head and neck cancer. *Oral Oncol* 2005, 41(3):225-243.
62. Wang Y, Ow TJ, Myers JN: Pathways for cervical metastasis in malignant neoplasms of the head and neck region. *Clin Anat* 2012, 25(1):54-71.
63. Jaber JJ, Murrill L, Clark JI, Johnson JT, Feustel PJ, Mehta V: Robust Differences in p16-Dependent Oropharyngeal Squamous Cell Carcinoma Distant Metastasis: Implications for Targeted Therapy. *Otolaryngol Head Neck Surg* 2015.
64. Ferlito A, Johnson JT, Rinaldo A, Pratt LW, Fagan JJ, Weir N, Suarez C, Folz BJ, Bien S, Towpik E *et al*: European surgeons were the first to perform neck dissection. *Laryngoscope* 2007, 117(5):797-802.

65. Robbins KT, Shaha AR, Medina JE, Califano JA, Wolf GT, Ferlito A, Som PM, Day TA: Consensus statement on the classification and terminology of neck dissection. *Arch Otolaryngol Head Neck Surg* 2008, 134(5):536-538.
66. Ferlito A, Robbins KT, Shah JP, Medina JE, Silver CE, Al-Tamimi S, Fagan JJ, Paleri V, Takes RP, Bradford CR *et al*: Proposal for a rational classification of neck dissections. *Head Neck* 2011, 33(3):445-450.
67. Crile G: III. On the Technique of Operations upon the Head and Neck. *Annals of surgery* 1906, 44(6):842-850.
68. Bocca E, Pignataro O, Oldini C, Cappa C: Functional neck dissection: an evaluation and review of 843 cases. *Laryngoscope* 1984, 94(7):942-945.
69. Medina JE, Byers RM: Supraomohyoid neck dissection: rationale, indications, and surgical technique. *Head Neck* 1989, 11(2):111-122.
70. Goldstein DP, Ringash J, Bissada E, Jaquet Y, Irish J, Chepeha D, Davis AM: Evaluation of shoulder disability questionnaires used for the assessment of shoulder disability after neck dissection for head and neck cancer. *Head Neck* 2013.
71. Short SO, Kaplan JN, Laramore GE, Cummings CW: Shoulder pain and function after neck dissection with or without preservation of the spinal accessory nerve. *American journal of surgery* 1984, 148(4):478-482.
72. Sobol S, Jensen C, Sawyer W, 2nd, Costiloe P, Thong N: Objective comparison of physical dysfunction after neck dissection. *American journal of surgery* 1985, 150(4):503-509.
73. Lango MN, Egleston B, Ende K, Feigenberg S, D'Ambrosio DJ, Cohen RB, Ahmad S, Nicolaou N, Ridge JA: Impact of neck dissection on long-term feeding tube dependence in patients with head and neck cancer treated with primary radiation or chemoradiation. *Head Neck* 2010, 32(3):341-347.
74. Donatelli-Lassig AA, Duffy SA, Fowler KE, Ronis DL, Chepeha DB, Terrell JE: The effect of neck dissection on quality of life after chemoradiation. *Otolaryngol Head Neck Surg* 2008, 139(4):511-518.
75. Eickmeyer SM, Walczak CK, Myers KB, Lindstrom DR, Layde P, Campbell BH: Quality of life, shoulder range of motion, and spinal accessory nerve status in 5-year survivors of head and neck cancer. *PM & R: the journal of injury, function, and rehabilitation* 2014, 6(12):1073-1080.
76. Macheda ML, Rogers S, Best JD: Molecular and cellular regulation of glucose transporter (GLUT) proteins in cancer. *J Cell Physiol* 2005, 202(3):654-662.
77. Warburg O: On the origin of cancer cells. *Science* 1956, 123(3191):309-314.
78. Ngo DC, Ververis K, Tortorella SM, Karagiannis TC: Introduction to the molecular basis of cancer metabolism and the Warburg effect. *Molecular biology reports* 2015, 42(4):819-823.
79. Alberts B JA, Lewis J, Raff M, Roberts K, Walter P: Molecular biology of the cell, 6th edn: Taylor & Francis Group; 2014.

80. Young H, Baum R, Cremerius U, Herholz K, Hoekstra O, Lammertsma AA, Pruim J, Price P: Measurement of clinical and subclinical tumour response using [18F]-fluorodeoxyglucose and positron emission tomography: review and 1999 EORTC recommendations. European Organization for Research and Treatment of Cancer (EORTC) PET Study Group. *Eur J Cancer* 1999, 35(13):1773-1782.
81. Phelps ME, Huang SC, Hoffman EJ, Selin C, Sokoloff L, Kuhl DE: Tomographic measurement of local cerebral glucose metabolic rate in humans with (F-18)2-fluoro-2-deoxy-D-glucose: validation of method. *Ann Neurol* 1979, 6(5):371-388.
82. Brownell: A history of positron imaging. *Presentation prepared in celebration of the 50th year of services by the author to the Massachusetts General Hospital on October 15th, 1999* 1999.
83. Antoch G, Saoudi N, Kuehl H, Dahmen G, Mueller SP, Beyer T, Bockisch A, Debatin JF, Freudenberg LS: Accuracy of whole-body dual-modality fluorine-18-2-fluoro-2-deoxy-D-glucose positron emission tomography and computed tomography (FDG-PET/CT) for tumor staging in solid tumors: comparison with CT and PET. *J Clin Oncol* 2004, 22(21):4357-4368.
84. Metser U, Miller E, Lerman H, Even-Sapir E: Benign nonphysiologic lesions with increased 18F-FDG uptake on PET/CT: characterization and incidence. *AJR Am J Roentgenol* 2007, 189(5):1203-1210.
85. Lindholm P, Minn H, Leskinen-Kallio S, Bergman J, Ruotsalainen U, Joensuu H: Influence of the blood glucose concentration on FDG uptake in cancer--a PET study. *J Nucl Med* 1993, 34(1):1-6.
86. Cohade C: Altered biodistribution on FDG-PET with emphasis on brown fat and insulin effect. *Semin Nucl Med* 2010, 40(4):283-293.
87. Haerle SK, Strobel K, Ahmad N, Soltermann A, Schmid DT, Stoeckli SJ: Contrast-enhanced (1)(8)F-FDG-PET/CT for the assessment of necrotic lymph node metastases. *Head Neck* 2011, 33(3):324-329.
88. WHO: WHO handbook for reporting results of cancer treatment. Geneva (Switzerland): World Health Organization Offset Publication No. 48; 1979.; 1979.
89. Therasse P, Arbuck SG, Eisenhauer EA, Wanders J, Kaplan RS, Rubinstein L, Verweij J, Van Glabbeke M, van Oosterom AT, Christian MC *et al*: New guidelines to evaluate the response to treatment in solid tumors. European Organization for Research and Treatment of Cancer, National Cancer Institute of the United States, National Cancer Institute of Canada. *J Natl Cancer Inst* 2000, 92(3):205-216.
90. Wahl RL, Jacene H, Kasamon Y, Lodge MA: From RECIST to PERCIST: Evolving Considerations for PET response criteria in solid tumors. *J Nucl Med* 2009, 50 Suppl 1:122S-150S.
91. Boellaard R: Standards for PET image acquisition and quantitative data analysis. *J Nucl Med* 2009, 50 Suppl 1:11S-20S.

92. Patlak CS, Blasberg RG, Fenstermacher JD: Graphical evaluation of blood-to-brain transfer constants from multiple-time uptake data. *J Cereb Blood Flow Metab* 1983, 3(1):1-7.
93. Rhodes CG, Wise RJ, Gibbs JM, Frackowiak RS, Hatazawa J, Palmer AJ, Thomas DG, Jones T: In vivo disturbance of the oxidative metabolism of glucose in human cerebral gliomas. *Ann Neurol* 1983, 14(6):614-626.
94. Laffon E, Marthan R: The total amount of uptake may affect the input function: a theoretic approach about 18F-FDG PET imaging. *Nucl Med Biol* 2015.
95. Vanderhoek M, Perlman SB, Jeraj R: Impact of different standardized uptake value measures on PET-based quantification of treatment response. *J Nucl Med* 2013, 54(8):1188-1194.
96. Cheebsumon P, Velasquez LM, Hoekstra CJ, Hayes W, Kloet RW, Hoetjes NJ, Smit EF, Hoekstra OS, Lammertsma AA, Boellaard R: Measuring response to therapy using FDG PET: semi-quantitative and full kinetic analysis. *Eur J Nucl Med Mol Imaging* 2011, 38(5):832-842.
97. Fakhry N, Lussato D, Jacob T, Giorgi R, Giovanni A, Zanaret M: Comparison between PET and PET/CT in recurrent head and neck cancer and clinical implications. *Eur Arch Otorhinolaryngol* 2007, 264(5):531-538.
98. Ong SC, Schoder H, Lee NY, Patel SG, Carlson D, Fury M, Pfister DG, Shah JP, Larson SM, Kraus DH: Clinical utility of 18F-FDG PET/CT in assessing the neck after concurrent chemoradiotherapy for Locoregional advanced head and neck cancer. *J Nucl Med* 2008, 49(4):532-540.
99. Chan SC, Hsu CL, Yen TC, Ng SH, Liao CT, Wang HM: The role of 18F-FDG PET/CT metabolic tumour volume in predicting survival in patients with metastatic nasopharyngeal carcinoma. *Oral Oncol* 2013, 49(1):71-78.
100. Roh JL, Kim JS, Kang BC, Cho KJ, Lee SW, Kim SB, Choi SH, Nam SY, Kim SY: Clinical significance of pretreatment metabolic tumor volume and total lesion glycolysis in hypopharyngeal squamous cell carcinomas. *J Surg Oncol* 2014, 110(7):869-875.
101. Abgral R, Keromnes N, Robin P, Le Roux PY, Bourhis D, Palard X, Rousset J, Valette G, Marianowski R, Salaun PY: Prognostic value of volumetric parameters measured by F-FDG PET/CT in patients with head and neck squamous cell carcinoma. *Eur J Nucl Med Mol Imaging* 2013.
102. Barrington SF, Qian W, Somer EJ, Franceschetto A, Bagni B, Brun E, Almquist H, Loft A, Hojgaard L, Federico M *et al*: Concordance between four European centres of PET reporting criteria designed for use in multicentre trials in Hodgkin lymphoma. *Eur J Nucl Med Mol Imaging* 2010, 37(10):1824-1833.
103. Marcus C, Ciarallo A, Tahari AK, Mena E, Koch W, Wahl RL, Kiess AP, Kang H, Subramaniam RM: Head and Neck PET/CT: Therapy Response Interpretation Criteria (Hopkins Criteria)-Interreader Reliability, Accuracy, and Survival Outcomes. *J Nucl Med* 2014.

104. Nakamoto Y, Tatsumi M, Hammoud D, Cohade C, Osman MM, Wahl RL: Normal FDG distribution patterns in the head and neck: PET/CT evaluation. *Radiology* 2005, 234(3):879-885.
105. Purohit BS, Ailianou A, Dulguerov N, Becker CD, Ratib O, Becker M: FDG-PET/CT pitfalls in oncological head and neck imaging. *Insights Imaging* 2014.
106. Blodgett TM, Fukui MB, Snyderman CH, Branstetter BfT, McCook BM, Townsend DW, Meltzer CC: Combined PET-CT in the head and neck: part 1. Physiologic, altered physiologic, and artifactual FDG uptake. *Radiographics* 2005, 25(4):897-912.
107. Chen W, Parsons M, Torigian DA, Zhuang H, Alavi A: Evaluation of thyroid FDG uptake incidentally identified on FDG-PET/CT imaging. *Nucl Med Commun* 2009, 30(3):240-244.
108. Soret M, Bacharach SL, Buvat I: Partial-volume effect in PET tumor imaging. *J Nucl Med* 2007, 48(6):932-945.
109. Kyzas PA, Evangelou E, Denaxa-Kyza D, Ioannidis JP: 18F-fluorodeoxyglucose positron emission tomography to evaluate cervical node metastases in patients with head and neck squamous cell carcinoma: a meta-analysis. *J Natl Cancer Inst* 2008, 100(10):712-720.
110. Nair S, Mohan S, Nilakantan A, Gupta A, Malik A, Gupta A: Impact of (18)f-fluorodeoxyglucose positron emission tomography/computed tomography scan on initial evaluation of head and neck squamous cell carcinoma: our experience at a tertiary care center in India. *World journal of nuclear medicine* 2015, 14(1):19-24.
111. Connell CA, Corry J, Milner AD, Hogg A, Hicks RJ, Rischin D, Peters LJ: Clinical impact of, and prognostic stratification by, F-18 FDG PET/CT in head and neck mucosal squamous cell carcinoma. *Head Neck* 2007, 29(11):986-995.
112. Smith KA, Dort JC, Hall SF, Rudmik L: Cost-effectiveness of Positron Emission Tomography-Computed Tomography in the Evaluation of Cancer Unknown Primary of the Head and Neck. *Head Neck* 2014.
113. Al-Ibraheem A, Buck A, Krause BJ, Scheidhauer K, Schwaiger M: Clinical Applications of FDG PET and PET/CT in Head and Neck Cancer. *J Oncol* 2009, 2009:208725.
114. Waltonen JD, Ozer E, Hall NC, Schuller DE, Agrawal A: Metastatic carcinoma of the neck of unknown primary origin: evolution and efficacy of the modern workup. *Arch Otolaryngol Head Neck Surg* 2009, 135(10):1024-1029.
115. Wang G, Wu Y, Zhang W, Li J, Wu P, Xie C: Clinical value of whole-body F-18 fluorodeoxyglucose positron emission tomography/computed tomography in patients with carcinoma of unknown primary. *J Med Imaging Radiat Oncol* 2013, 57(1):65-71.
116. Yoo J, Henderson S, Walker-Dilks C: Evidence-based guideline recommendations on the use of positron emission tomography imaging in head and neck cancer. *Clin Oncol (R Coll Radiol)* 2013, 25(4):e33-66.
117. Daisne JF, Duprez T, Weynand B, Lonneux M, Hamoir M, Reyckler H, Gregoire V: Tumor volume in pharyngolaryngeal squamous cell carcinoma: comparison at CT, MR

- imaging, and FDG PET and validation with surgical specimen. *Radiology* 2004, 233(1):93-100.
118. Thiagarajan A, Caria N, Schoder H, Iyer NG, Wolden S, Wong RJ, Sherman E, Fury MG, Lee N: Target volume delineation in oropharyngeal cancer: impact of PET, MRI, and physical examination. *Int J Radiat Oncol Biol Phys* 2012, 83(1):220-227.
 119. Perez CA, Bradley J, Chao CK, Grigsby PW, Mutic S, Malyapa R: Functional imaging in treatment planning in radiation therapy: a review. *Rays* 2002, 27(3):157-173.
 120. MacManus M, Nestle U, Rosenzweig KE, Carrio I, Messa C, Belohlavek O, Danna M, Inoue T, Deniaud-Alexandre E, Schipani S *et al*: Use of PET and PET/CT for radiation therapy planning: IAEA expert report 2006-2007. *Radiother Oncol* 2009, 91(1):85-94.
 121. Brun E, Kjellen E, Tennvall J, Ohlsson T, Sandell A, Perfekt R, Wennerberg J, Strand SE: FDG PET studies during treatment: prediction of therapy outcome in head and neck squamous cell carcinoma. *Head Neck* 2002, 24(2):127-135.
 122. Brun E, Ohlsson T, Erlandsson K, Kjellen E, Sandell A, Tennvall J, Wennerberg J, Strand SE: Early prediction of treatment outcome in head and neck cancer with 2-18FDG PET. *Acta Oncol* 1997, 36(7):741-747.
 123. Suzuki H, Kato K, Fujimoto Y, Itoh Y, Hiramatsu M, Naganawa S, Hasegawa Y, Nakashima T: Prognostic value of F-fluorodeoxyglucose uptake before treatment for pharyngeal cancer. *Ann Nucl Med* 2014.
 124. Joo YH, Yoo Ie R, Cho KJ, Park JO, Nam IC, Kim CS, Kim MS: Prognostic value of preoperative 18F-FDG PET/CT for primary head and neck squamous cell carcinoma. *Eur Arch Otorhinolaryngol* 2014, 271(6):1685-1691.
 125. Kikuchi M, Koyasu S, Shinohara S, Usami Y, Imai Y, Hino M, Itoh K, Tona R, Kanazawa Y, Kishimoto I *et al*: Prognostic value of pretreatment F-FDG PET/CT volume-based parameters in patients with oropharyngeal squamous cell carcinoma with known p16 and p53 status. *Head Neck* 2014.
 126. Alluri KC, Tahari AK, Wahl RL, Koch W, Chung CH, Subramaniam RM: Prognostic value of FDG PET metabolic tumor volume in human papillomavirus-positive stage III and IV oropharyngeal squamous cell carcinoma. *AJR Am J Roentgenol* 2014, 203(4):897-903.
 127. Koyasu S, Nakamoto Y, Kikuchi M, Suzuki K, Hayashida K, Itoh K, Togashi K: Prognostic value of pretreatment 18F-FDG PET/CT parameters including visual evaluation in patients with head and neck squamous cell carcinoma. *AJR Am J Roentgenol* 2014, 202(4):851-858.
 128. Ryu IS, Kim JS, Roh JL, Cho KJ, Choi SH, Nam SY, Kim SY: Prognostic significance of preoperative metabolic tumour volume and total lesion glycolysis measured by (18)F-FDG PET/CT in squamous cell carcinoma of the oral cavity. *Eur J Nucl Med Mol Imaging* 2014, 41(3):452-461.
 129. Murphy JD, La TH, Chu K, Quon A, Fischbein NJ, Maxim PG, Graves EE, Loo BW, Jr., Le QT: Postradiation metabolic tumor volume predicts outcome in head-and-neck cancer. *Int J Radiat Oncol Biol Phys* 2011, 80(2):514-521.

130. Vainshtein JM, Spector ME, Stenmark MH, Bradford CR, Wolf GT, Worden FP, Chepeha DB, McHugh JB, Carey T, Wong KK *et al*: Reliability of post-chemoradiotherapy F-18-FDG PET/CT for prediction of locoregional failure in human papillomavirus-associated oropharyngeal cancer. *Oral Oncol* 2014, 50(3):234-239.
131. Enomoto K, Inohara H, Higuchi I, Hamada K, Tomiyama Y, Kubo T, Hatazawa J: Prognostic Value of FDG-PET in patients with oropharyngeal carcinoma treated with concurrent chemoradiotherapy. *Mol Imaging Biol* 2008, 10(4):224-229.
132. Castaldi P, Rufini V, Bussu F, Micciche F, Dinapoli N, Autorino R, Lago M, De Corso E, Almadori G, Galli J *et al*: Can "early" and "late" 18F-FDG PET-CT be used as prognostic factors for the clinical outcome of patients with locally advanced head and neck cancer treated with radio-chemotherapy? *Radiother Oncol* 2012, 103(1):63-68.
133. Kunkel M, Forster GJ, Reichert TE, Kutzner J, Benz P, Bartenstein P, Wagner W: Radiation response non-invasively imaged by [18F]FDG-PET predicts local tumor control and survival in advanced oral squamous cell carcinoma. *Oral Oncol* 2003, 39(2):170-177.
134. Subesinghe M, Scarsbrook AF, Sourbron S, Wilson DJ, McDermott G, Speight R, Roberts N, Carey B, Forrester R, Gopal SV *et al*: Alterations in anatomic and functional imaging parameters with repeated FDG PET-CT and MRI during radiotherapy for head and neck cancer: a pilot study. *BMC Cancer* 2015, 15(1):137.
135. Martin RC, Fulham M, Shannon KF, Hughes C, Gao K, Milross C, Tin MM, Jackson M, Clifford A, Boyer MJ *et al*: Accuracy of positron emission tomography in the evaluation of patients treated with chemoradiotherapy for mucosal head and neck cancer. *Head Neck* 2009, 31(2):244-250.
136. Ware RE, Matthews JP, Hicks RJ, Porceddu S, Hogg A, Rischin D, Corry J, Peters LJ: Usefulness of fluorine-18 fluorodeoxyglucose positron emission tomography in patients with a residual structural abnormality after definitive treatment for squamous cell carcinoma of the head and neck. *Head Neck* 2004, 26(12):1008-1017.
137. Porceddu SV, Pryor DI, Burmeister E, Burmeister BH, Poulsen MG, Foote MC, Panizza B, Coman S, McFarlane D, Coman W: Results of a prospective study of positron emission tomography-directed management of residual nodal abnormalities in node-positive head and neck cancer after definitive radiotherapy with or without systemic therapy. *Head Neck* 2011.
138. Passero VA, Branstetter BF, Shuai Y, Heron DE, Gibson MK, Lai SY, Kim SW, Grandis JR, Ferris RL, Johnson JT *et al*: Response assessment by combined PET-CT scan versus CT scan alone using RECIST in patients with locally advanced head and neck cancer treated with chemoradiotherapy. *Ann Oncol* 2010, 21(11):2278-2283.
139. Chen AY, Vilaseca I, Hudgins PA, Schuster D, Halkar R: PET-CT vs contrast-enhanced CT: what is the role for each after chemoradiation for advanced oropharyngeal cancer? *Head Neck* 2006, 28(6):487-495.
140. Kim SY, Lee SW, Nam SY, Im KC, Kim JS, Oh SJ, Ahn SD, Shin SS, Choi EK, Kim JH: The Feasibility of 18F-FDG PET scans 1 month after completing radiotherapy of squamous cell carcinoma of the head and neck. *J Nucl Med* 2007, 48(3):373-378.

141. Nayak JV, Walvekar RR, Andrade RS, Daamen N, Lai SY, Argiris A, Smith RP, Heron DE, Ferris RL, Johnson JT *et al*: Deferring planned neck dissection following chemoradiation for stage IV head and neck cancer: the utility of PET-CT. *Laryngoscope* 2007, 117(12):2129-2134.
142. Cho AH, Shah S, Ampil F, Bhartur S, Nathan CO: N2 disease in patients with head and neck squamous cell cancer treated with chemoradiotherapy: is there a role for posttreatment neck dissection? *Arch Otolaryngol Head Neck Surg* 2009, 135(11):1112-1118.
143. Gourin CG, Boyce BJ, Williams HT, Herdman AV, Bilodeau PA, Coleman TA: Revisiting the role of positron-emission tomography/computed tomography in determining the need for planned neck dissection following chemoradiation for advanced head and neck cancer. *Laryngoscope* 2009, 119(11):2150-2155.
144. Malone JP, Gerber MA, Vasireddy S, Hughes LF, Rao K, Shevlin B, Kuhn M, Collette D, Tennenhouse J, Robbins KT: Early prediction of response to chemoradiotherapy for head and neck cancer: reliability of restaging with combined positron emission tomography and computed tomography. *Arch Otolaryngol Head Neck Surg* 2009, 135(11):1119-1125.
145. Moeller BJ, Rana V, Cannon BA, Williams MD, Sturgis EM, Ginsberg LE, Macapinlac HA, Lee JJ, Ang KK, Chao KS *et al*: Prospective risk-adjusted [18F]Fluorodeoxyglucose positron emission tomography and computed tomography assessment of radiation response in head and neck cancer. *J Clin Oncol* 2009, 27(15):2509-2515.
146. Rabalais AG, Walvekar R, Nuss D, McWhorter A, Wood C, Fields R, Mercante DE, Pou AM: Positron emission tomography-computed tomography surveillance for the node-positive neck after chemoradiotherapy. *Laryngoscope* 2009, 119(6):1120-1124.
147. Gupta T, Jain S, Agarwal JP, Rangarajan V, Purandare N, Ghosh-Laskar S, Dinshaw KA: Diagnostic performance of response assessment FDG-PET/CT in patients with head and neck squamous cell carcinoma treated with high-precision definitive (chemo)radiation. *Radiother Oncol* 2010, 97(2):194-199.
148. Keski-Santti H, Mustonen T, Schildt J, Saarilahti K, Makitie AA: FDG-PET/CT in the Assessment of Treatment Response after Oncologic Treatment of Head and Neck Squamous Cell Carcinoma. *Clin Med Insights Ear Nose Throat* 2014, 7:25-29.
149. Pellini R, Manciocco V, Turri-Zanoni M, Vidiri A, Sanguineti G, Marucci L, Sciuto R, Covello R, Sperduti I, Kayal R *et al*: Planned neck dissection after chemoradiotherapy in advanced oropharyngeal squamous cell cancer: The role of US, MRI and FDG-PET/TC scans to assess residual neck disease. *J Craniomaxillofac Surg* 2014.
150. Schouten CS, de Graaf P, Alberts FM, Hoekstra OS, Comans EF, Bloemena E, Witte BI, Sanchez E, Leemans CR, Castelijns JA *et al*: Response evaluation after chemoradiotherapy for advanced nodal disease in head and neck cancer using diffusion-weighted MRI and 18F-FDG-PET-CT. *Oral Oncol* 2015.
151. Kim JW, Roh JL, Kim JS, Lee JH, Cho KJ, Choi SH, Nam SY, Kim SY: F-FDG PET/CT surveillance at 3-6 and 12 months for detection of recurrence and second

- primary cancer in patients with head and neck squamous cell carcinoma. *Br J Cancer* 2013.
152. Dunsy KA, Wehrmann DJ, Osman MM, Thornberry BM, Varvares MA: PET-CT and the detection of the asymptomatic recurrence or second primary lesions in the treated head and neck cancer patient. *Laryngoscope* 2013.
 153. Beswick DM, Gooding WE, Johnson JT, Branstetter BFt: Temporal patterns of head and neck squamous cell carcinoma recurrence with positron-emission tomography/computed tomography monitoring. *Laryngoscope* 2012, 122(7):1512-1517.
 154. Krabbe CA, Pruijm J, Dijkstra PU, Balink H, van der Laan BF, de Visscher JG, Roodenburg JL: 18F-FDG PET as a routine posttreatment surveillance tool in oral and oropharyngeal squamous cell carcinoma: a prospective study. *J Nucl Med* 2009, 50(12):1940-1947.
 155. Abgral R, Querellou S, Potard G, Le Roux PY, Le Duc-Pennec A, Marianovski R, Pradier O, Bizais Y, Kraeber-Bodere F, Salaun PY: Does 18F-FDG PET/CT improve the detection of posttreatment recurrence of head and neck squamous cell carcinoma in patients negative for disease on clinical follow-up? *J Nucl Med* 2009, 50(1):24-29.
 156. Kostakoglu L, Fardanesh R, Posner M, Som P, Rao S, Park E, Doucette J, Stein EG, Gupta V, Misiukiewicz K *et al*: Early detection of recurrent disease by FDG-PET/CT leads to management changes in patients with squamous cell cancer of the head and neck. *The oncologist* 2013, 18(10):1108-1117.
 157. Gourin CG, Watts T, Williams HT, Patel VS, Bilodeau PA, Coleman TA: Identification of distant metastases with PET-CT in patients with suspected recurrent head and neck cancer. *Laryngoscope* 2009, 119(4):703-706.
 158. Yi JS, Kim JS, Lee JH, Choi SH, Nam SY, Kim SY, Roh JL: 18F-FDG PET/CT for detecting distant metastases in patients with recurrent head and neck squamous cell carcinoma. *J Surg Oncol* 2012, 106(6):708-712.
 159. Chua ML, Ong SC, Wee JT, Ng DC, Gao F, Tan TW, Fong KW, Chua ET, Khoo JB, Low JS: Comparison of 4 modalities for distant metastasis staging in endemic nasopharyngeal carcinoma. *Head Neck* 2009, 31(3):346-354.
 160. Gao G, Gong B, Shen W: Meta-analysis of the additional value of integrated FDG PET-CT for tumor distant metastasis staging: Comparison with FDG PET alone and CT alone. *Surg Oncol* 2013.
 161. Rasey JS, Grierson JR, Wiens LW, Kolb PD, Schwartz JL: Validation of FLT uptake as a measure of thymidine kinase-1 activity in A549 carcinoma cells. *J Nucl Med* 2002, 43(9):1210-1217.
 162. Bhatnagar P, Subesinghe M, Patel C, Prestwich R, Scarsbrook AF: Functional imaging for radiation treatment planning, response assessment, and adaptive therapy in head and neck cancer. *Radiographics* 2013, 33(7):1909-1929.
 163. Hoglund J, Shirvan A, Antoni G, Gustavsson SA, Langstrom B, Ringheim A, Sorensen J, Ben-Ami M, Ziv I: 18F-ML-10, a PET tracer for apoptosis: first human study. *J Nucl Med* 2011, 52(5):720-725.

164. Soderlund-Strand A, Carlson J, Dillner J: Modified general primer PCR system for sensitive detection of multiple types of oncogenic human papillomavirus. *J Clin Microbiol* 2009, 47(3):541-546.
165. Schmitt M, Bravo IG, Snijders PJ, Gissmann L, Pawlita M, Waterboer T: Bead-based multiplex genotyping of human papillomaviruses. *J Clin Microbiol* 2006, 44(2):504-512.
166. Dictor M, Warenholt J: Single-tube multiplex PCR using type-specific E6/E7 primers and capillary electrophoresis genotypes 21 human papillomaviruses in neoplasia. *Infect Agent Cancer* 2011, 6(1):1.
167. Ahlberg A, Lagerlund M, Lewin F, Friesland S, Lundgren J: Clinical outcome following radiotherapy and planned neck dissection in N+ head and neck cancer patients. *Acta Otolaryngol* 2008, 128(12):1354-1360.
168. Dautremont JF, Brake MK, Thompson G, Trites J, Hart RD, Taylor SM: Planned neck dissection following radiation treatment for head and neck malignancy. *Int J Otolaryngol* 2012, 2012:954203.
169. Sandhu A, Rao N, Giri S, He F, Karakla D, Wadsworth T, McGaughey D, Silverberg M: Role and extent of neck dissection for persistent nodal disease following chemoradiotherapy for locally advanced head and neck cancer: how much is enough? *Acta Oncol* 2008, 47(5):948-953.
170. Sewall GK, Palazzi-Churas KL, Richards GM, Hartig GK, Harari PM: Planned postradiotherapy neck dissection: Rationale and clinical outcomes. *Laryngoscope* 2007, 117(1):121-128.
171. Johansen LV, Grau C, Overgaard J: Squamous cell carcinoma of the oropharynx--an analysis of treatment results in 289 consecutive patients. *Acta Oncol* 2000, 39(8):985-994.
172. Agrawal A, Hammond TH, Young GS, Avon AL, Ozer E, Schuller DE: Factors affecting long-term survival in patients with recurrent head and neck cancer may help define the role of post-treatment surveillance. *Laryngoscope* 2009, 119(11):2135-2140.
173. Goguen LA, Chapuy CI, Li Y, Zhao SD, Annino DJ: Neck dissection after chemoradiotherapy: timing and complications. *Arch Otolaryngol Head Neck Surg* 2010, 136(11):1071-1077.
174. Leung AS, Rath TJ, Hughes MA, Kim S, Branstetter BF: Optimal timing of first post-treatment FDG-PET/CT in head and neck squamous cell carcinoma. *Head Neck* 2015.
175. Ranck MC, Abundo R, Jefferson G, Kolokythas A, Wenig BL, Weichselbaum RR, Spiotto MT: Effect of postradiotherapy neck dissection on nonregional disease sites. *JAMA Otolaryngol Head Neck Surg* 2014, 140(1):12-21.
176. Thariat J, Ang KK, Allen PK, Ahamad A, Williams MD, Myers JN, El-Naggar AK, Ginsberg LE, Rosenthal DI, Glisson BS *et al*: Prediction of neck dissection requirement after definitive radiotherapy for head-and-neck squamous cell carcinoma. *Int J Radiat Oncol Biol Phys* 2012, 82(3):e367-374.

177. Corry J, Peters L, Fisher R, Macann A, Jackson M, McClure B, Rischin D: N2-N3 neck nodal control without planned neck dissection for clinical/radiologic complete responders-results of Trans Tasman Radiation Oncology Group Study 98.02. *Head Neck* 2008, 30(6):737-742.
178. Karakaya E, Yetmen O, Oksuz DC, Dyker KE, Coyle C, Sen M, Prestwich RJ: Outcomes following chemoradiotherapy for N3 head and neck squamous cell carcinoma without a planned neck dissection. *Oral Oncol* 2013, 49(1):55-59.
179. Soltys SG, Choi CY, Fee WE, Pinto HA, Le QT: A planned neck dissection is not necessary in all patients with N2-3 head-and-neck cancer after sequential chemoradiotherapy. *Int J Radiat Oncol Biol Phys* 2012, 83(3):994-999.
180. Adams G, Porceddu SV, Pryor DI, Panizza B, Foote M, Rowan A, Burmeister B: Outcomes after primary chemoradiotherapy for N3 (> 6cm) head and neck squamous cell carcinoma following an FDG-PET guided neck management policy: Does size still matter? *Head Neck* 2013.
181. Shah S, Har-El G, Rosenfeld RM: Short-term and long-term quality of life after neck dissection. *Head Neck* 2001, 23(11):954-961.
182. Kuntz AL, Weymuller EA, Jr.: Impact of neck dissection on quality of life. *Laryngoscope* 1999, 109(8):1334-1338.
183. Terrell JE, Ronis DL, Fowler KE, Bradford CR, Chepeha DB, Prince ME, Teknos TN, Wolf GT, Duffy SA: Clinical predictors of quality of life in patients with head and neck cancer. *Arch Otolaryngol Head Neck Surg* 2004, 130(4):401-408.
184. Pryor DI, Porceddu SV, Scuffham PA, Whitty JA, Thomas PA, Burmeister BH: Economic analysis of FDG-PET-guided management of the neck after primary chemoradiotherapy for node-positive head and neck squamous cell carcinoma. *Head Neck* 2012.
185. Anderson CM, Chang T, Graham MM, Marquardt MD, Button A, Smith BJ, Menda Y, Sun W, Pagedar NA, Buatti JM: Change of Maximum Standardized Uptake Value Slope in Dynamic Triphasic [(18)F]-Fluorodeoxyglucose Positron Emission Tomography/Computed Tomography Distinguishes Malignancy From Postradiation Inflammation in Head-and-Neck Squamous Cell Carcinoma: A Prospective Trial. *Int J Radiat Oncol Biol Phys* 2015, 91(3):472-479.

A prospective study of positron emission tomography for evaluation of neck node response 6 weeks after radiotherapy in patients with head and neck squamous cell carcinoma

Johanna Sjövall, MD,^{1*} Peter Wahlberg, MD, PhD,¹ Helen Almquist, MD, PhD,² Elisabeth Kjellén, MD, PhD,³ Eva Brun, MD, PhD³

¹Department of ORL–Head and Neck Surgery, Clinical Sciences, Skane University Hospital, Lund University, Sweden, ²Department of Clinical Physiology and Nuclear Medicine, Skane University Hospital, Lund University, Sweden, ³Department of Oncology, Clinical Sciences, Skane University Hospital, Lund University, Sweden.

Accepted 23 February 2015

Published online 00 Month 2015 in Wiley Online Library (wileyonlinelibrary.com). DOI 10.1002/hed.24021

ABSTRACT: *Background.* The purpose of this study was to evaluate if a positron emission tomography (PET) scan, 6 weeks after radiotherapy (RT), adequately selects patients in whom a neck node dissection can be omitted. Primary endpoints were isolated neck recurrences and overall survival (OS).

Methods. One hundred five patients, mainly with oropharyngeal human papillomavirus (HPV)-positive tumors, with a positive PET scan before treatment, were evaluated regarding the neck response 6 weeks post-RT. The PET results determined the management of the neck: observation versus neck dissection.

Results. Median follow-up was 25 months. Positive predictive value (PPV) and negative predictive value (NPV) were 56% and 94%, respectively. Four isolated neck recurrences occurred. The 2-year OS rate was 86.3%.

Conclusion. PET scans performed 6 weeks after RT have a high NPV and can obviate neck dissections but the PPV is insufficient. A later scheduled scan is recommended. © 2015 Wiley Periodicals © 2015 Wiley Periodicals, Inc. *Head Neck* 00: 000–000, 2015

KEY WORDS: head and neck, squamous cell carcinoma, positron emission tomography, radiotherapy, neck dissection

INTRODUCTION

In locally advanced, neck node-positive head and neck squamous cell carcinoma, the need for planned neck dissection after curatively intended radiotherapy (RT) is questioned.¹ It has been demonstrated that only 20% to 40% of the neck specimens contain residual tumor cells^{2–4} after radical RT. With the addition of a neck node dissection, enhanced morbidity in the neck and shoulder region, with soft tissue fibrosis and impaired function, as well as pain, can be expected.⁵ Consequently, an increasing number of studies advocate imaging methods for assessment of the neck node response after RT in order to select patients in whom a neck dissection is indicated.^{6–11}

Anatomic and functional imaging with 18-fluorodeoxyglucose (FDG)-positron emission tomography (PET)-CT, performed 12 weeks postchemoradiotherapy, has been proven to be superior to contrast-enhanced CT alone in evaluating the presence of viable tumor in the neck.^{12–15}

The optimal timing of a post-RT PET scan is, however, still not clear.¹⁶ A few previous studies^{17–22} have focused

on early assessment (<8 weeks after therapy) of treatment response. These studies, comprising a limited number of patients, are mainly based on patients treated with chemoradiation. We aimed for an early evaluation in a cohort with head and neck squamous cell carcinoma, human papillomavirus (HPV)/P16 positive and negative tumors, predominantly treated with RT, because it would allow for timely salvage surgery if warranted. An early assessment would also be favorable for performing adjuvant neck dissection without unnecessary delay and before the onset of RT-induced fibrosis, which was a concern of ours.

The purpose of this study was to evaluate if a PET scan, 6 weeks post-RT, is able to adequately select patients in whom a neck node dissection could be safely omitted. The primary endpoints were isolated neck recurrences and overall survival (OS).

PATIENTS AND METHODS

This prospective study was performed as an observational, registry, single institution study at a tertiary referral center, at Skane University Hospital in Lund, Sweden, with a catchment area of 1.8 million people. The study protocol was approved by the regional ethics committee and enrolled patients signed informed consent forms.

Patient eligibility

All patients were reviewed by the head and neck multidisciplinary team, and their disease was staged according

*Corresponding author: J. Sjövall, Department of ORL–Head and Neck Surgery, Clinical Sciences, Skane University Hospital, Lund University, 22185 Lund, Sweden. E-mail: johanna.sjovall@med.lu.se

Contract grant sponsor: This study was supported by grants from the Swedish Foundation Acta Oto-Laryngologica, and governmental funding of clinical research within Lund University Hospital and the Region of Scania R&D.

TABLE 1. Patient (*n* = 106) and tumor (*n* = 108) characteristics.

Patient characteristics, no. of patients = 106	No. (%)
Age	
Median (range)	61 (34–89)
Sex	
Female	28 (26)
Male	78 (74)
Primary site (no. of tumors = 108)	
Tonsil	72 (67)
Tongue base	18 (17)
Oropharynx (other than above)	6 (5)
Supraglottis	7 (7)
Hypopharynx	5 (4)
HPV or P16 positivity (no. of tumors = 108)	
HPV-positive	43 (40)
P16-positive	36 (33)
HPV or P16-negative	26 (24)
Unknown	3 (3)
Differentiation (no. of tumors = 108)	
Well differentiated	6 (6)
Moderately differentiated	28 (26)
Poorly differentiated	63 (58)
Not specified	11 (10)
Smoking status	
Current smoker or stopped smoking <6 mo	32 (30)
Ex-smoker, stopped smoking >6 mo	43 (41)
Never smoked	31 (29)
Treatment	
RT alone	98 (92)
Concurrent cisplatin	6 (6)
Induction PF	2 (2)

Abbreviations: HPV, human papillomavirus; P16, P16INKA; RT, radiotherapy; PF, cisplatin and 5-fluorouracil.

The majority of patients had P16-positive, oropharyngeal cancer (OPC), T2N2. Synchronous head and neck primary tumors were found in 2 patients.

to the International Union Against Cancer TNM classification, seventh edition. A CT scan of the head/neck and thorax was part of the diagnostic workup in all patients. Patients with no previous neck node surgery, locally advanced, neck node-positive, biopsy-proven squamous cell carcinoma of oropharynx, hypopharynx, or larynx intended for curative organ preservation therapy were invited to participate. Patients were eligible only if hypermetabolism was present in the neck node metastases and no distant metastases were found at baseline PET (PET1). Inclusion was accomplished between September 2009 and July 2012.

Patient characteristics

During the inclusion period, 132 patients were screened for enrolment in the study. Because of severe comorbidity, 2 patients were not considered suitable for inclusion, another 6 patients declined participation, 9 patients were never addressed, and 4 never performed a baseline PET. At PET1, 4 patients had PET-negative neck metastases and 1 patient had a pulmonary metastasis and they were consequently not included, leaving 106 patients eligible for the study. Patients not included in the study were treated according to local guidelines with radical RT followed by neck dissection. Patient demographics, tumor characteristics, and TNM classification are summarized in

Tables 1 and 2. The median age was 61 years; 26% were women. The majority of patients had HPV-associated (HPV or P16-positive), oropharyngeal cancer (OPC), stage 4. Synchronous head and neck primary tumors were found in 2 patients; in 1 patient, a tonsillar cancer and a hypopharyngeal cancer, and in the other patient, bilateral tonsillar cancer.

Human papillomavirus/P16INKA analysis

HPV status was determined either by polymerase chain reaction (PCR) followed by Luminex-based genotyping^{23,24} or by single-tube multiplex PCR²⁵; alternatively, P16INKA (P16) was determined by immunohistochemical staining. P16INKA positivity was defined as strong and diffuse nuclear and cytoplasmic staining in $\geq 70\%$ of the tumor cells. E6H4 antibody from the CINtec P16 histology kit (Ventana Medical Systems, Tucson, AZ) was used for immunohistochemistry analysis. In 3 cases, the biopsy material was insufficient for P16 or PCR analysis. Among the oropharyngeal tumors, 80% were HPV or P16-positive and among the 12 supraglottic or hypopharyngeal tumors, 2 were P16-positive and 1 was HPV-positive.

Positron emission tomography imaging

All patients were imaged with an integrated PET-CT system (Philips Gemini TF; Philips Medical Systems, Cleveland, OH) providing a 3D display. In accordance with our standard clinical PET protocol, the patients were injected intravenously with 4 MBq/kg body weight of FDG to a maximum dose of 400 MBq after a 4-hour fasting period. Images were acquired after the 1-hour uptake period, during which the patients rested. PET images had an acquisition time of 2 minutes per bed position. At baseline, the dose planning CT was acquired together with the PET scan. For follow-up studies, low-dose CT scans (50 mAs) were used. The CT data were used for attenuation correction and anatomic localization. The PET1 scan was acquired from the skull base to the upper thighs. The subsequent PET scans were acquired from the skull base to the upper abdomen.

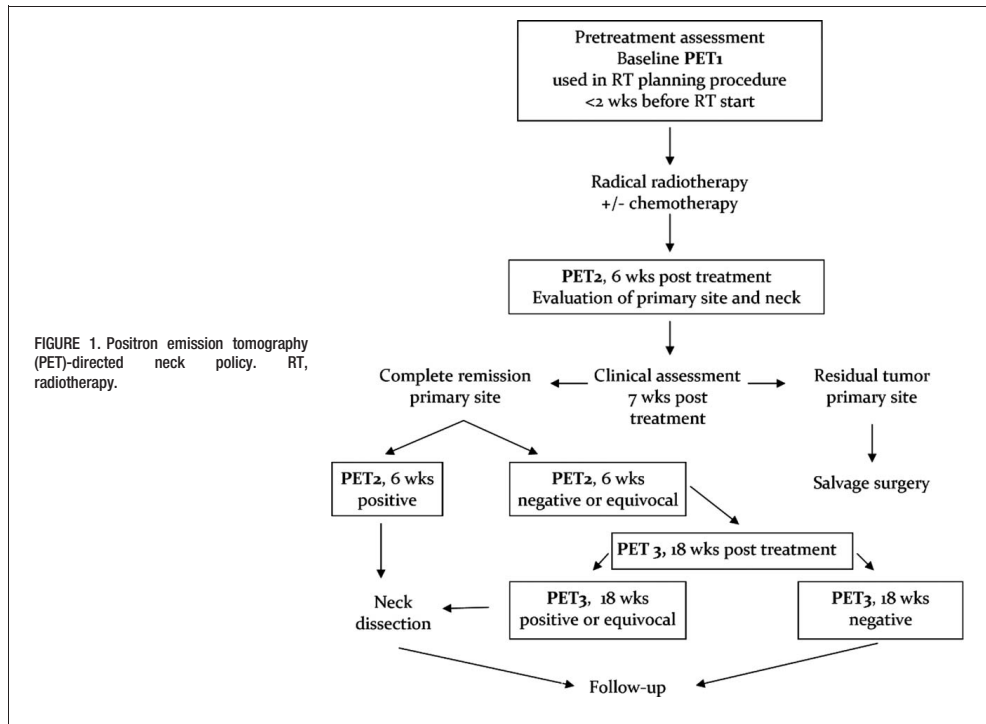
Image interpretation

All PET scans were interpreted by nuclear medicine physicians as part of the clinical routine. A visual evaluation was done of the relative differences in FDG uptake. When a clearly hypermetabolic focus, with an anatomic

TABLE 2. Tumor, node, metastasis classification after positron emission tomography scan 1.

T classification	No. by N classification					Total
	N1	N2a	N2b	N2c	N3	
T1	1	5	13	0	0	19 (+1T)
T2	8	10	31	5	1	55 (+1T)
T3	3	2	11	2	1	19
T4	2	1	4	6	0	13
Total	14	18	59	13	2	T = 108/ N = 106

No. of T classifications = 108; no. of N classifications = 106.



correlation to a suspected lymph node, could be established, the FDG uptake was considered pathological. A visible but not clearly hypermetabolic FDG uptake compared to adjacent tissue was judged as equivocal metabolism.

Radiotherapy and systemic treatment

Baseline PET-CT scans served as dose planning studies in the RT planning procedure and ultimately confirmed known sites of disease. All patients were treated with intensity-modulated radiation therapy with a simultaneous boost technique. All macroscopic disease was treated to an absorbed dose of 68 Gy, 2 Gy per fraction, 5 fractions per week. Elective nodes received 54 Gy, 1.67 Gy per fraction. When a tonsillectomy was performed, it was regarded as a biopsy and the tonsillar fossa was treated to 68 Gy.

According to our guidelines, systemic treatment was not given routinely but was considered for patients with a heavy tumor burden. Only 8 of the included patients received chemotherapy. In 2 patients, 2 cycles of neoadjuvant chemotherapy with cisplatin 100 mg/m² and 5-fluorouracil 100 mg/m² (chemotherapy) was given on days 1 to 5, every 3 weeks, and in 6 patients, concurrent chemoradiotherapy with weekly cisplatin, at a total dose of 50 mg/week, was given.

Response assessment of primary site

Clinical controls and side effect monitoring were performed weekly during the treatment at the Department of Oncology and also at a post-RT visit 4 weeks after completed therapy. Tumor response was assessed 6 to 7 weeks posttreatment by PET scan and clinically by a head and neck surgeon. The response grade was ultimately evaluated by the multidisciplinary team. If residual tumor was found at the primary site, the patient was excluded from the protocol and evaluated for salvage surgery.

Positron emission tomography-directed neck policy

For the PET-directed neck policy, see Figure 1. All patients were scheduled for a baseline PET scan, PET1, which also served as the dose planning study, <2 weeks before RT start. Neck response was assessed by PET scan 6 weeks post-RT (PET2). If PET2 was considered negative or equivocal, the patient was rescheduled for one additional PET scan 18 weeks post-RT (PET3). If PET2 was considered positive or if PET3 was considered positive or equivocal, a neck dissection was performed. The extent of the neck dissection was at the discretion of the head and neck surgeon. The PET2 and PET3 results were reviewed by the head and neck multidisciplinary team and an ultimate decision was taken to recommend surgery.

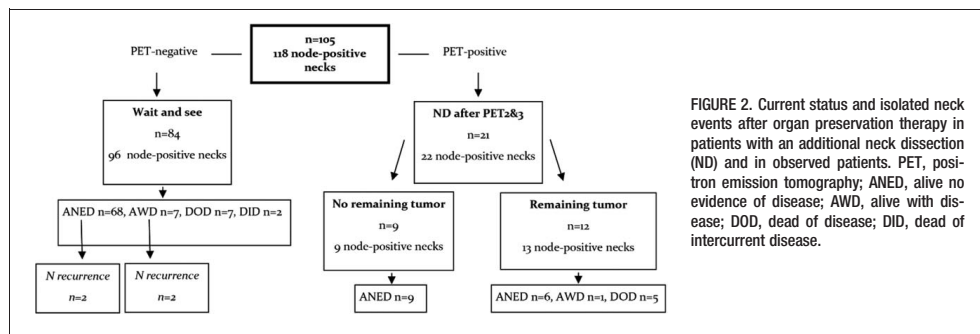


FIGURE 2. Current status and isolated neck events after organ preservation therapy in patients with an additional neck dissection (ND) and in observed patients. PET, positron emission tomography; ANED, alive no evidence of disease; AWD, alive with disease; DOD, dead of disease; DID, dead of intercurrent disease.

or not. Neither imaging studies nor fine-needle biopsies were performed routinely in equivocal cases.

Follow-up

After a neck dissection or a negative PET3 scan, patients were scheduled for clinical follow-ups, according to routine, every 3 months during the first 2 years, every 4 months in year 3, and every 6 months during the last 2 years of follow-up. The clinical examinations were performed by a head and neck surgeon and/or a head and neck oncologist at a joint outpatient clinic. Imaging and additional biopsies were provided if there was any clinical suspicion of recurrence.

Outcome analysis and statistical considerations

One patient did not achieve a primary site complete response and was excluded from the study, leaving 105 patients eligible for analysis.

The sensitivity, specificity, positive predictive value (PPV), negative predictive value (NPV), and accuracy regarding PET in relation to neck node disease were calculated for the 118 node-positive neck sides. If a neck recurrence, either isolated or composite, occurred <12 months after a negative PET3 scan, the PET scan was considered a false-negative result.

Using IBM SPSS Statistics 20 (SPSS, Chicago, IL), OS, locoregional control, and disease-free survival (DFS) were estimated by means of the Kaplan–Meier method and log-rank test was used for comparison between groups. A *p* value of <.05 was considered significant. The time from diagnosis to death, or the date of last follow-up, was used for calculations.

RESULTS

Median follow-up from diagnosis was 25 months (range, 9–49 months). The median time from completion of RT to PET2 was 43 days; 90% of the patients had the second PET scan between 37 and 52 days posttherapy.

Upstaging by positron emission tomography

Following the PET1 scan, 14 patients were reclassified to a more advanced N classification and 1 patient to a more advanced T classification. In addition, a lung metastasis was diagnosed in 1 patient who was subsequently excluded from

the study. Seven of these patients went from clinical tumor stage 3 to stage 4a. The PET examinations also revealed 6 synchronous tumors not found in the diagnostic workup, consisting of 4 malignant (colon = 2; lung = 1; and hypopharynx = 1), and 2 benign (adrenal adenoma = 1; and prolactinoma = 1) tumors. Another 4 suspicious malignant findings (colon = 1; lung = 1; and thyroid = 2) on the PET scan could be discarded after additional examinations.

Neck dissections

Based on the PET2 results, 17 patients underwent neck dissection, one of whom bilaterally, which adds up to 18 hemineck dissections. Remaining tumor cells, as assessed by the pathologist, were found in 10 of these 18 specimens. Another 4 patients were selected for neck dissection after PET3, and 3 of these specimens contained remaining tumor. The pathology report, as well as clinical follow-up, were considered the golden standards for determining persisting tumor, and were compared to the PET results. During the follow-up period, after PET3, 4 isolated neck recurrences occurred at 4, 7, 15, and 19 months, respectively, after PET3. These 4 patients underwent neck dissection and the first 2 patients are considered disease-free, whereas the 2 patients with late failures are alive with disease (see Figure 2).

Positron emission tomography outcome, all patients (n = 105)

Calculations for PET2, 6 weeks after treatment completion, resulted in a sensitivity of 62.5% (confidence interval [CI] = 35.9% to 83.7%), specificity 92% (CI = 84.7% to 96.3%), PPV 56% (CI = 31.3% to 77.6%), NPV 94% (CI = 86.9% to 97.5%), and accuracy 88%. In total, 6 false-negative cases occurred within 12 months after a negative PET2; 3 cases with remaining tumor in the neck specimen after PET3 and 3 neck recurrences, 2 isolated, and 1 composite.

Positron emission tomography outcome in patients with oropharyngeal cancer, human papillomavirus/P16 positive and negative

Calculations for PET 2, 6 weeks after treatment completion in HPV/P16-positive patients (n = 75) resulted in

TABLE 3. Patterns of failure during the follow-up period.

Site	No. of failures = 23	%
T	8	7.6
N	4	3.8
M	6	5.7
T + N	3	2.9
N + M	2	1.9

Abbreviations: T, primary tumor site; N, neck node metastasis; M, distant metastasis. Percentages are in relation to the patients with complete remission at the primary site after radiotherapy (no. of patients = 105).

a sensitivity of 55.6% (CI = 22.6% to 84.7%), specificity 90.1% (CI = 80.2% to 95.6%), PPV 41.7% (CI = 16.5% to 71.4%), NPV 94.1% (CI = 84.9% to 98.1%), and accuracy 86.2%.

Corresponding figures for patients who were HPV/P16-negative ($n = 16$) were: sensitivity 80% (CI = 29.9% to 98.9%), specificity 100% (CI = 71.7% to 100%), PPV 100% (CI = 39.6% to 100%), NPV 92.9% (CI = 64.2% to 99.6%), and accuracy 94.4%.

In total, 23 patients suffered from recurrences. Isolated primary tumor relapse ($n = 8$) and isolated distant metastasis ($n = 6$) were the most common presentations. First failure sites are presented in Table 3.

Patient outcome

In Kaplan-Meier estimates of the whole cohort ($n = 105$), patients with HPV/P16-positive tumors demonstrated a significant survival benefit compared with patients with HPV/P16-negative tumors, $p < .00001$. The OS is shown in Figure 3. The 2-year OS rate was 86.3%.

OS, locoregional control, and DFS in the OPC group stratified for HPV/P16-status ($n = 91$) is demonstrated in Figure 4A–4C. The 2-year OS for patients who were HPV/P16-positive was 95.3% and for the patients who were HPV/P16-negative it was 58.7%, $p < .00001$. Locoregional control for patients with OPC who were HPV/P16-positive and negative, respectively, was 91.1% and 78.6%, $p = .23$ at 2 years of follow-up and DFS was correspondingly 95.3% and 58.7%, $p = .01$.

As a consequence of the PET studies, 80 of 105 patients (76%) could be spared a neck dissection and 12 patients (11%) were correctly scheduled for surgery. Nine patients (9%) underwent unnecessary neck dissection. Four patients (4%), in whom a neck dissection was omitted, had an isolated neck failure during the follow-up.

DISCUSSION

In this prospective study, we were able to correctly treat the neck node metastases in 87% of our patients, which corroborates previous results advocating PET as a tool for selecting patients who will benefit from a neck dissection post-RT. Two previous prospective studies on locally advanced head and neck cancer have compared FDG-PET to CT and simultaneously investigated the role of PET for evaluation of neck node response after organ preservation therapy. Moeller et al²⁶ conclude that PET might be of additional value to CT in a subgroup of patients with high-risk tumors. Porceddu et al,¹⁵ on the other hand, have found a significant advantage for PET in

all patients, with the PET performed 12 weeks postradiochemotherapy treatment.

Retrospective studies and meta-analyses have also added to the growing body of knowledge indicating that PET is superior to other imaging modalities in the evaluation of remaining neck node disease after organ preservation therapy.¹⁶ The issue of timing has, however, remained uncertain.

The current study was designed to evaluate the safety of an early posttherapy PET scan, 6 weeks post-RT, to decide if a neck node dissection could be omitted in patients who were diagnosed as HPV/P16-positive and negative. By choosing this relatively short interval between RT completion and the evaluating PET scan, we enabled a simultaneous evaluation of both the primary site and the neck.²⁷ Our treatment policy with mainly single modality RT followed by neck dissection is based on previously published results.²⁸ Because the study was designed to deescalate the treatment intensity avoiding futile neck dissections, an early scheduled PET scan was considered important. Salvage surgery because of residual tumor at the primary site or neck dissections, if decided appropriate, could then be carried out approximately 8 weeks post-RT. That is well before late radiation sequelae occur, which would potentially complicate and compromise a surgical procedure if a later timing were allowed. Concerns were raised about microscopic residual disease not detectable as early as 6 weeks after therapy and another PET scan, PET3, was scheduled 18 weeks posttherapy to confirm remission or offer surgery if needed.

In the present study, a PET scan 6 weeks after completed RT achieved an NPV of 94%, which is comparable to other studies in which the PET scan was scheduled between 8 and 12 weeks posttherapy.^{3,10,26} Two of the previous studies with an early follow-up PET, evaluating the primary site and the neck nodes 4 to 6 weeks after RT, have also shown excellent results, with an NPV of 98.8% and 93.1%, respectively.^{18,19} However, several authors argue that an assessment should be scheduled later than 8 weeks post-RT and studies have shown even less false-negative results but especially less false-positive results and, therefore, a better NPV, PPV, and accuracy when PET scans are performed later.^{13,20,21,29–31} Furthermore, Goguen et al³² have recently published results indicating that neck dissections can be performed 12 weeks postchemoradiotherapy without affecting survival

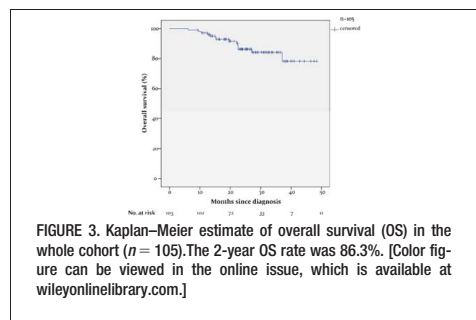
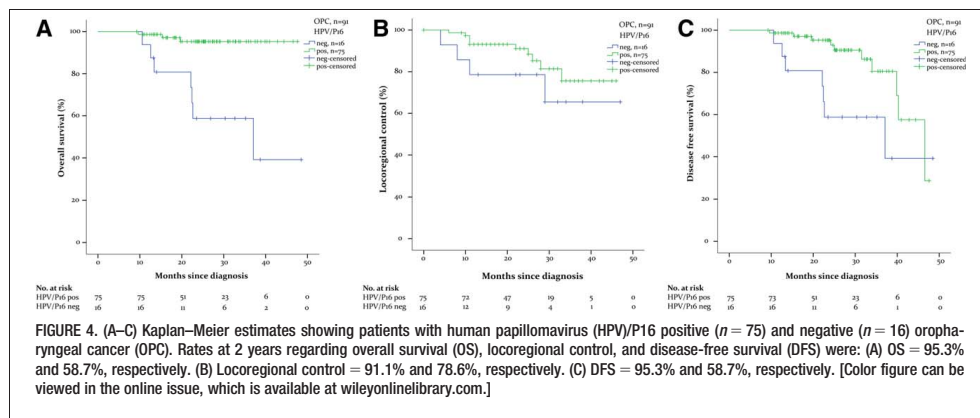


FIGURE 3. Kaplan-Meier estimate of overall survival (OS) in the whole cohort ($n = 105$). The 2-year OS rate was 86.3%. [Color figure can be viewed in the online issue, which is available at wileyonlinelibrary.com.]



variables or surgical complications. As mentioned above, the value of PET has been discussed in light of high-risk versus low-risk tumors. An early PET in our group of HPV/P16-negative oropharyngeal tumors showed excellent predictive values and the NPV for the early PET in patients with HPV/P16-positive tumors is high but the PPV was disappointing.

In the western world an increase in HPV-related oropharyngeal tumors is seen, outnumbering the ones caused by tobacco and alcohol³³ but the prevalence of HPV-positive OPC varies between regions and figures from 20–90% have been reported.³⁴ In this study, the vast majority of patients (89%) had oropharyngeal tumors and 80% of these were HPV or P16-positive, which favorably affects the response to RT, as well as OS and progression-free survival.³⁵ Even though a small proportion of patients had HPV/P16-negative tumors, the difference, compared to the positive ones, in OS and locoregional control was, as expected, significant.

We had 17 locoregional failures (13.3%) during the follow-up period with a median of 25 months. Three of these patients, never smokers, were HPV/P16-positive and relapses occurred more than 18 months after completion of treatment. This is consistent with the literature reporting fewer, later, and more distant failures in general for patients with HPV.³⁶ A recent retrospective study demonstrates excellent locoregional control in HPV/P16-positive OPC, with only T4, N3, and smoking history as negative prognostic factors for locoregional failure.³⁷ However, it is too early to support a regimen where posttherapy evaluation is omitted in nonsmokers with small HPV-positive oropharyngeal tumors.

The rate of 4 isolated neck failures and 5 composite neck failures that occurred in our study population is comparable to regional failure rates in settings where both RT and neck dissection were performed.¹ In a retrospective study concerning treatment results after single modality treatment with RT in patients with oropharyngeal tumors, 7.2% suffered from isolated neck failures during the follow-up period compared to 3.8% in our study population.³⁸ Another retrospective study by Garden

et al,³⁹ in which 67% of 401 patients with HPV-positive OPC were treated with chemoradiation and 20% had undergone neck dissection, the 2-year actuarial neck recurrence rate was 7%. Our neck failure rate is thus modest, even though more than 90% of the patients received RT alone and the proportion of performed neck dissections is similar.

In this study, the median follow-up was 25 months, and fewer than 10% of the patients were followed for <1 year. According to Beswick et al,⁴⁰ most failures, 95%, occur within the first 2 years after treatment and 79% occur during the first year. With a longer follow-up period, we would certainly have encountered a few more recurrences, especially considering the high number of HPV/P16-positive tumors; however, it is unlikely that our statistics and conclusions would have changed dramatically.

Only patients with PET-positive neck nodes before treatment were enrolled in the present study. It was a potential limitation because it seems to be more common with cystic neck metastasis in patients with HPV/P16-positive OPC,⁴¹ but only 4 patients were ineligible because of absence of neck node hypermetabolism on the baseline PET scan. Nevertheless, our results apply exclusively to patients with initially PET-positive neck node metastases.

Furthermore, the PET scans were interpreted by different nuclear medicine physicians as part of the clinical routine and there is a potential interobserver variability, which was not taken into account.

Last, our study population was mixed and dominated by oropharyngeal tumors, the majority were HPV/P16-positive. Only 12 patients had other primary tumor locations; hypopharyngeal and supraglottic tumors. We believe that this mix does not affect the ability to report the accuracy of the PET results because an intraindividual comparison of the neck node metabolism before and after treatment was made in the same manner in all patients.

CONCLUSION

We conclude that PET evaluation of neck node response to RT can obviate the need for neck dissections

in many cases. Neck dissections in patients planned for organ preservation therapy should be performed in non-responders and considered a salvage procedure regardless of initial primary site and N classification or HPV/P16 status. The timing, with a PET scan performed 6 weeks after RT, shows a high NPV but a low PPV. Thus, a later scheduled PET evaluation is recommended.

Acknowledgments

The authors thank Malin Heide von Knorring for valuable support, and all contributing oncologists and surgeons.

REFERENCES

- Ferlito A, Corry J, Silver CE, Shaha AR, Thomas Robbins K, Rinaldo A. Planned neck dissection for patients with complete response to chemoradiotherapy: a concept approaching obsolescence. *Head Neck* 2010; 32:253–261.
- Ahlberg A, Lagerlund M, Lewin F, Friesland S, Lundgren J. Clinical outcome following radiotherapy and planned neck dissection in N+ head and neck cancer patients. *Acta Otolaryngol* 2008;128:1354–1360.
- Brkovich VS, Miller FR, Karnad AB, Hussey DH, McGuff HS, Otto RA. The role of positron emission tomography scans in the management of the N-positive neck in head and neck squamous cell carcinoma after chemoradiotherapy. *Laryngoscope* 2006;116:855–858.
- Boyd TS, Harari PM, Tannehill SP, et al. Planned postradiotherapy neck dissection in patients with advanced head and neck cancer. *Head Neck* 1998;20:132–137.
- Bradley PJ, Ferlito A, Silver CE, et al. Neck treatment and shoulder morbidity: still a challenge. *Head Neck* 2011;33:1060–1067.
- Goguen LA, Posner MR, Tishler RB, et al. Examining the need for neck dissection in the era of chemoradiation therapy for advanced head and neck cancer. *Arch Otolaryngol Head Neck Surg* 2006;132:526–531.
- Yao M, Smith RB, Graham MM, et al. The role of FDG PET in management of neck metastasis from head-and-neck cancer after definitive radiation treatment. *Int J Radiat Oncol Biol Phys* 2005;63:991–999.
- Liauw SL, Mancuso AA, Amdur RJ, et al. Postradiotherapy neck dissection for lymph node-positive head and neck cancer: the use of computed tomography to manage the neck. *J Clin Oncol* 2006;24:1421–1427.
- Corry J, Peters L, Fisher R, et al. N2-N3 neck nodal control without planned neck dissection for clinical/radiologic complete responders—results of Trans Tasman Radiation Oncology Group Study 98.02. *Head Neck* 2008;30:737–742.
- Ong SC, Schöder H, Lee NY, et al. Clinical utility of 18F-FDG PET/CT in assessing the neck after concurrent chemoradiotherapy for locoregional advanced head and neck cancer. *J Nucl Med* 2008;49:532–540.
- Hermann RM, Christiansen H, Rödel RM. Lymph node positive head and neck carcinoma after curative radiochemotherapy: a long lasting debate on elective post-therapeutic neck dissections comes to a conclusion. *Cancer Radiother* 2013;17:323–331.
- Martin RC, Fulham M, Shannon KF, et al. Accuracy of positron emission tomography in the evaluation of patients treated with chemoradiotherapy for mucosal head and neck cancer. *Head Neck* 2009;31:244–250.
- Porceddu SV, Pryor DI, Burmeister E, et al. Results of a prospective study of positron emission tomography-directed management of residual nodal abnormalities in node-positive head and neck cancer after definitive radiotherapy with or without systemic therapy. *Head Neck* 2011;33:1675–1682.
- Ware RE, Matthews JP, Hicks RJ, et al. Usefulness of fluorine-18 fluorodeoxyglucose positron emission tomography in patients with a residual structural abnormality after definitive treatment for squamous cell carcinoma of the head and neck. *Head Neck* 2004;26:1008–1017.
- Passero VA, Branstetter BF, Shuai Y, et al. Response assessment by combined PET-CT scan versus CT scan alone using RECIST in patients with locally advanced head and neck cancer treated with chemoradiotherapy. *Ann Oncol* 2010;21:2278–2283.
- Isles MG, McConkey C, Mehanna HM. A systematic review and meta-analysis of the role of positron emission tomography in the follow up of head and neck squamous cell carcinoma following radiotherapy or chemoradiotherapy. *Clin Otolaryngol* 2008;33:210–222.
- Nam SY, Lee SW, Im KC, et al. Early evaluation of the response to radiotherapy of patients with squamous cell carcinoma of the head and neck using 18FDG-PET. *Oral Oncol* 2005;41:390–395.
- Kim SY, Lee SW, Nam SY, et al. The feasibility of 18F-FDG PET scans 1 month after completing radiotherapy of squamous cell carcinoma of the head and neck. *J Nucl Med* 2007;48:373–378.
- Goerres GW, Schmid DT, Bandhauer F, et al. Positron emission tomography in the early follow-up of advanced head and neck cancer. *Arch Otolaryngol Head Neck Surg* 2004;130:105–109.
- Greven KM, Williams DW III, McGuirt WF Sr, et al. Serial positron emission tomography scans following radiation therapy of patients with head and neck cancer. *Head Neck* 2001;23:942–946.
- Andrade RS, Heron DE, Degimenci B, et al. Posttreatment assessment of response using FDG-PET/CT for patients treated with definitive radiation therapy for head and neck cancers. *Int J Radiat Oncol Biol Phys* 2006;65:1315–1322.
- Malone JP, Gerber MA, Vasireddy S, et al. Early prediction of response to chemoradiotherapy for head and neck cancer: reliability of restaging with combined positron emission tomography and computed tomography. *Arch Otolaryngol Head Neck Surg* 2009;135:1119–1125.
- Söderlund-Strand A, Carlsson J, Dillner J. Modified general primer PCR system for sensitive detection of multiple types of oncogenic human papillomavirus. *J Clin Microbiol* 2009;47:541–546.
- Schmitt M, Bravo IG, Snijders LJ, Gissmann L, Pawlita M, Waterboer T. Bead-based multiplex genotyping of human papillomaviruses. *J Clin Microbiol* 2006;44:504–512.
- Dictor M, Warenholt J. Single-tube multiplex PCR using type-specific E6/E7 primers and capillary electrophoresis genotypes 21 human papillomaviruses in neoplasia. *Infect Agent Cancer* 2011;6:1.
- Moeller BJ, Rana V, Cannon BA, et al. Prospective risk-adapted [18F]fluorodeoxyglucose positron emission tomography and computed tomography assessment of radiation response in head and neck cancer. *J Clin Oncol* 2009;27:2509–2515.
- Sjövall J, Brun E, Almqvist H, Kjellén E, Wahlberg P. Radiotherapy response in head and neck cancer – evaluation of the primary tumour site. *Acta Otolaryngol* 2014;134:646–651.
- Zackrisson B, Nilsson P, Kjellen E, et al. Two-year results from a Swedish study on conventional versus accelerated radiotherapy in head and neck squamous cell carcinoma—the ARTSCAN study. *Radiother Oncol* 2011;100:41–48.
- Chen AY, Vilaseca I, Hudgins PA, Schuster D, Halkar R. PET-CT vs contrast-enhanced CT: what is the role for each after chemoradiation for advanced oropharyngeal cancer? *Head Neck* 2006;28:487–495.
- Gupta T, Master Z, Kannan S, et al. Diagnostic performance of post-treatment FDG PET or FDG PET/CT imaging in head and neck cancer: a systematic review and meta-analysis. *Eur J Nucl Med Mol Imaging* 2011; 38:2083–2095.
- Gupta T, Jain S, Agarwal JP, et al. Diagnostic performance of response assessment FDG-PET/CT in patients with head and neck squamous cell carcinoma treated with high-precision definitive (chemo)radiation. *Radiother Oncol* 2010;97:194–199.
- Goguen LA, Chapuy CI, Li Y, Zhao SD, Annino DJ. Neck dissection after chemoradiotherapy: timing and complications. *Arch Otolaryngol Head Neck Surg* 2010;136:1071–1077.
- Marklund L, Hammarstedt L. Impact of HPV in oropharyngeal cancer. *J Oncol* 2011;2011:509036.
- Rietbergen MM, Leemans CJ, Bloemena E, et al. Increasing prevalence rates of HPV attributable oropharyngeal squamous cell carcinomas in the Netherlands as assessed by a validated test algorithm. *Int J Cancer* 2013; 132:1565–1571.
- Ang KK, Harris J, Wheeler R, et al. Human papillomavirus and survival of patients with oropharyngeal cancer. *N Engl J Med* 2010;363:24–35.
- Huang SH, Perez-Ordóñez B, Weinreb I, et al. Natural course of distant metastases following radiotherapy or chemoradiotherapy in HPV-related oropharyngeal cancer. *Oral Oncol* 2013;49:79–85.
- Vainshtein JM, Spector ME, McHugh JB, et al. Refining risk stratification for locoregional failure after chemoradiotherapy in human papillomavirus-associated oropharyngeal cancer. *Oral Oncol* 2014;50:513–519.
- Johansen LV, Grau C, Overgaard J. Squamous cell carcinoma of the oropharynx—an analysis of treatment results in 289 consecutive patients. *Acta Oncol* 2000;39:985–994.
- Garden AS, Gunn GB, Hessel A, et al. Management of the lymph node-positive neck in the patient with human papillomavirus-associated oropharyngeal cancer. *Cancer* 2014;120:3082–3088.
- Beswick DM, Gooding WE, Johnson JT, Branstetter BF IV. Temporal patterns of head and neck squamous cell carcinoma recurrence with positron-emission tomography/computed tomography monitoring. *Laryngoscope* 2012;122:1512–1517.
- Goldenberg D, Begum S, Westra WH, et al. Cystic lymph node metastasis in patients with head and neck cancer: an HPV-associated phenomenon. *Head Neck* 2008;30:898–903.

Paper II

ORIGINAL ARTICLE

Radiotherapy response in head and neck cancer – evaluation of the primary tumour site

JOHANNA SJÖVALL¹, EVA BRUN², HELEN ALMQUIST³, ELISABETH KJELLÉN² & PETER WAHLBERG¹

¹Department of ORL-Head and Neck Surgery, Clinical Sciences, ²Department of Oncology, Clinical Sciences and

³Department of Clinical Physiology and Nuclear Medicine, Skane University Hospital, Lund University, Sweden

Abstract

Conclusion: PET-CT scans seem to be sufficient to rule out residual tumour at the primary site. Patients with positive or equivocal PET findings should be scheduled for endoscopy with biopsy or a second PET-CT scan. **Objectives:** Assessment of remission at the primary site, in patients treated with organ preservation therapy with curative intent, is important to identify residual tumours requiring treatment with salvage surgery. The aim of this study was to evaluate the diagnostic accuracy of fluorodeoxyglucose positron emission tomography (FDG-PET) after radiotherapy with or without chemotherapy in assessing primary site response in patients with head and neck cancer. **Methods:** A total of 82 patients, with a positive baseline PET-CT scan before start of treatment, were evaluated with a PET-CT scan 6–7 weeks post-radiotherapy and with a clinical examination/endoscopy with or without biopsy 1–2 weeks later. The majority of patients had p16-positive oropharyngeal tumours. **Results:** Post-treatment, 77% of the patients had no visible hypermetabolism. If equivocal PET scans are regarded as positive, the sensitivity, specificity, negative (NPV) and positive predictive value (PPV) and accuracy were 100%, 78%, 100%, 6% and 78%, respectively. Eight patients suffered from relapses involving the primary site during the 9-month follow-up.

Keywords: Squamous cell carcinoma, positron emission tomography, endoscopy, treatment outcome

Introduction

A prerequisite for successful curative treatment of locally advanced head and neck squamous cell carcinoma (HNSCC) is complete remission following primary treatment. Remission rates after radiotherapy with or without chemotherapy are high; figures from 80% to 90% of complete responders are common [1–3]. Evaluation of therapy response is scheduled within 2 months of completed therapy in order to identify residual tumours requiring salvage therapy, still with curative intent.

Methods for treatment evaluation vary between institutions but usually comprise imaging and a clinical examination, sometimes under anaesthesia, sometimes with biopsies of the primary site. Anatomical and functional imaging with 18-fluorodeoxyglucose

(FDG)-positron emission tomography-computed tomography (PET-CT) has been proved to be superior to CT alone in evaluating remaining viable tumour in the neck [2,4].

Compared with clinical examination of the primary site, an endoscopic evaluation under anaesthesia with biopsies enables a thorough examination; however, the procedure is not without risk.

The majority of patients with pharyngeal tumours present with locoregional advanced disease, stage III–IV [5]. Post-treatment PET-CT for response assessment of the neck will simultaneously give information on metabolic response at the primary site. If this metabolic study can supply equally robust information on remission grade regarding the primary site as well as the neck nodes, the assessment of the therapy response will be facilitated.

Correspondence: Johanna Sjövall, MD, Department of ORL-Head and Neck Surgery, Clinical Sciences, Skane University Hospital, Lund University, 22185 Lund, Sweden. Tel: +46 46 17 10 00. Fax: +46 46 17 17 58. E-mail: johanna.sjovall@med.lu.se

(Received 21 December 2013; accepted 7 February 2014)

ISSN 0001-6489 print/ISSN 1651-2251 online © 2014 Informa Healthcare
DOI: 10.3109/00016489.2014.895038

We performed a prospective study aiming to assess primary site and neck node response with a PET-CT in patients with locoregional advanced HNSCC. The presented material is part of a larger study and in this article we report on the diagnostic accuracy of FDG-PET-CT in evaluating primary site response after radical radiotherapy with or without chemotherapy.

Material and methods

This prospective study was performed as a single institutional study at the tertiary referral Skane University Hospital, Lund, Sweden. The study protocol was approved by the regional ethics committee.

Patient and tumour characteristics

All patients were reviewed by the head and neck multidisciplinary team and disease was staged according to the International Union Against Cancer (UICC) tumour-node-metastasis (TNM) classification, 7th edition. Inclusion criteria were: (1) biopsy-proved, locally advanced squamous cell carcinoma of oropharynx, hypopharynx and larynx; (2) no distant metastasis; and (3) treatment with curative intent. All patients who met all inclusion criteria were invited to participate and they were enrolled consecutively. Those who were included signed informed consent. Inclusion was accomplished between 2009 and 2012. All patients underwent a baseline PET-CT before starting radiotherapy. For eligibility for analysis, this pretreatment scan had to show a hypermetabolic tumour. Altogether 111 patients were considered for enrolment in the study; however, 4 patients never underwent the baseline PET-CT. Another 24 patients were excluded from the analysis because of lack of visible hypermetabolism on the baseline PET-CT. This group consisted of 21 patients who had been subject to tonsillectomy in the diagnostic work-up and 3 patients with microscopic tumours on the base of the tongue. One further patient was excluded after baseline PET-CT because of a pulmonary metastasis.

Among the 82 included patients, 1 had 2 simultaneous primary tumours: 1 hypopharyngeal and 1 tonsillar cancer. The patients' median age was 62 years (range 34–89 years); 24% were women. The majority of primary sites, 71 cases, involved oropharynx. Among the oropharyngeal tumours 36 patients were HPV-positive, 18 were p16-positive, 14 were HPV- or p16-negative and 3 were unknown. Seventeen patients had undergone tonsillectomy in the diagnostic work-up, still with increased focal metabolic activity visible on the PET-CT scan. These patients were included.

Patient and tumour characteristics are summarized in Table I.

Radiotherapy and systemic treatment

The baseline PET-CT scans were used in the radiotherapy planning procedure and ultimately confirmed known sites of disease. All patients were treated according to local guidelines with intensity-modulated radiation therapy (IMRT) and concomitant boost technique. All macroscopic disease with margin was treated with 68 Gy, 2 Gy per fraction, five fractions a week. Elective nodes received 54 Gy. Tonsillectomy was regarded as a biopsy and the tonsillar fossa was treated to full dose.

Table I. Characteristics of patients ($n = 82$) and tumours ($n = 83$).

Characteristic	Frequency
Age, years ($n = 82$)	
Median (range)	62 (34–89)
Sex ($n = 82$)	
Female	20 (24%)
Male	62 (76%)
Primary site ($n = 83$)	
Tonsil	50 (60%)
Tongue base	15 (18%)
Oropharynx (other than above sites)	6 (7%)
Supraglottis	7 (8%)
Hypopharynx	5 (6%)
HPV or p16 positivity ($n = 83$)	
HPV-positive	37 (45%)
p16-positive	20 (24%)
HPV- or p16-negative	23 (28%)
Unknown	3 (4%)
Smoking status ($n = 82$)	
Never smoked	26 (32%)
Ex-smoker (ceased >6 months)	31 (38%)
Current smoker (or ceased <6 months)	25 (30%)
T classification ($n = 83$)	
T1	5 (6%)
T2	47 (57%)
T3	18 (22%)
T4	13 (16%)
Treatment ($n = 82$)	
Radiotherapy alone	74 (90%)
Concurrent cisplatin	6 (7%)
Induction PF	2 (2%)

HPV, human papillomavirus; p16, p16INKA; PF, cisplatin and 5-fluorouracil.

Systemic treatment was not given routinely but when it was considered to be indicated, in locally advanced disease, it was given at the discretion of the treating physician. In two patients, neoadjuvant chemotherapy with cisplatin 100 mg/m² and 5-fluorouracil 100 mg/m² (PF chemotherapy) every 3 weeks, two cycles, was given and in six patients concurrent weekly cisplatin, at a total dose of 50 mg/week, was given during radiotherapy. These eight patients given systemic treatment did not differ significantly regarding primary site, HPV/p16 status or TNM classification compared to the patients treated with radiotherapy alone.

Human papillomavirus/P16INKA analysis

HPV status was determined either by polymerase chain reaction (PCR) followed by Luminex-based genotyping [6,7] or by single-tube multiplex PCR [8]; alternatively, p16INKA (p16) was determined by immunohistochemical staining. p16INKA positivity was defined as strong and diffuse nuclear and cytoplasmic staining in ≥70% of the tumour cells. E6H4™ antibody from the CINtec® p16 histology kit (Ventana Medical Systems Inc., Tucson, AZ, USA) was used for immunohistochemistry analysis. In three cases the biopsy material was insufficient for p16 or PCR analysis.

PET-CT imaging

All patients were imaged with an integrated PET-CT system (Philips Gemini TF; Philips Medical Systems, Cleveland, OH, USA) providing a three-dimensional display. In accordance with our standard clinical PET protocol, the patients were injected intravenously with 4 MBq/kg body weight of FDG to a maximum dose of 400 MBq after a 4 h fasting period. Images were acquired after the 1 h uptake period, during which the patients rested. PET images had an acquisition time of 2 min per bed position. At baseline a radiotherapy planning CT was acquired together with the PET scan. For follow-up studies, low-dose CT scans (50 mAs) were used. The CT data were used for attenuation correction and anatomic localization.

Image interpretation

All images were interpreted by visual inspection, which is the preferred method at our institution. This was done by nuclear medicine physicians as part of the clinical routine. FDG uptake above background was described. Their description of the primary site post-therapy was further categorized as

follows: remaining hypermetabolism, no visual hypermetabolism, or equivocal.

Primary site response

Primary site response was evaluated initially by PET-CT, 6–7 weeks post-radiotherapy. This was followed by evaluation by a head and neck surgeon in the multidisciplinary team, 1–2 weeks later. Thus, this examination was approximately 8 weeks post-radiotherapy, concurrent with the standard follow-up protocol. The latter examination was performed endoscopically under general anaesthesia with or without biopsy or by clinical examination with or without biopsy. The PET-CT result was known to the head and neck surgeon and used to target the biopsy.

Biopsies were analysed and reported by the pathologist as remaining viable cancer, benign epithelia or dysplasia.

Follow-up

All patients were followed for a minimum of 9 months after completion of therapy and were assessed every 3 months by clinical examination, according to our standard protocol. Imaging and additional biopsies were provided if there was any clinical suspicion of recurrence at the primary site.

Outcome analysis

The PET-CT results were compared with the results from the endoscopic or clinical examination including biopsy ($n = 68$ tumours). The sensitivity, specificity, negative predictive value (NPV), positive predictive value (PPV) and accuracy of the PET-CT assessment were calculated.

Results

Primary site response evaluation with PET-CT was performed on average 44 days post-therapy (range 28–87 days, with 90% of patients falling within the range of 37–52 days post-therapy). The post-therapy PET-CT scan showed no visual hypermetabolism in 64 patients (77%), remaining hypermetabolism in 4 patients (5%) and was equivocal in 15 patients (18%).

Evaluation of tumour response at the primary site was performed by the head and neck surgeon on average 7 days after the scan. Thus, 77 patients (78 tumours) were evaluated endoscopically, during anaesthesia whereof 65 patients (66 tumours) had a biopsy taken. Five patients underwent outpatient

Table II. PET results compared with pathology report for 82 patients and 83 tumours.

PET Biopsy	No visual hypermetabolism	Remaining hypermetabolism	Equivocal	Total
Negative	49	3	11 (+1)	63 (+1)
Dysplasia	3	0	0	3
Positive	0	1	0	1
No biopsy	12	0	3	15
Total	64	4	15	

clinical assessment whereof two patients had a biopsy taken.

The pathology reports for 68 biopsy sites (67 patients) revealed 64 diagnoses of benign epithelia, 3 of dysplasia and 1 of remaining viable cancer.

The sole patient with remaining viable cancer also clearly had hypermetabolism at the primary site on the post-therapy PET-CT images.

The PET results compared with the pathology report are described in Table II.

PET-CT statistics

If we refer equivocal PET findings to the group with remaining hypermetabolism the sensitivity is 100% and the specificity 78%. The NPV is 100% and the PPV is 6%. Accuracy is 78%.

Recurrences

During the follow-up period, eight patients suffered from recurrence at the primary site, five with local and three with composite failures (one locoregional, one local + distant and one locoregional + distant). All of them had been considered to be in complete remission when the treatment evaluation was performed. On that occasion, they had no remaining hypermetabolism on the PET scan, benign biopsies and a normal clinical status during endoscopy. The recurrences were confirmed by biopsy on average 165 (range 83–225) days after the PET-CT scan.

Discussion

This study demonstrates excellent primary site remission with only one residual tumour following, mainly, a single modality treatment with radiotherapy. The result might be explained by the high percentage (86%) of oropharyngeal tumours. A more favourable outcome is to be expected since the majority of these tumours were p16- or HPV-positive [9,10]. A similar

patient population from Australia, with 74% of oropharyngeal tumours, also showed a low proportion (3%) of residual tumours after chemoradiotherapy [2].

The timing of a post-radiotherapy PET-CT is often debated, and different protocols have been studied, especially regarding neck node response to treatment [11]. A PET-CT scan 12 weeks after treatment was shown to be reliable when neck node response was evaluated [2]. Radiotherapy must be allowed to have full effect before therapy evaluation; on the other hand, should a salvage treatment be necessary this should be performed without undue delay. Therefore, the optimal timing of PET-CT is difficult since fulfilment of both criteria is desirable. In the present study, PET-CT evaluation of the primary tumour site 6 weeks post-radiotherapy showed an NPV of 100%. This result is in line with findings by Kim et al. [12], whose study on 97 patients also showed a high NPV of 97.5% regarding PET-CT evaluation of the primary tumour site 1 month post-radiotherapy.

Because of the low prevalence of residual tumours the PPV is bound to be low. Inflammatory changes, such as oral ulcers within treated mucosa, can increase focal metabolism and can sometimes cause a high rate [13] of false-positive FDG uptake after treatment. Radiotherapy-induced mucositis and oedema can, in some cases, complicate the assessment of the primary site during endoscopy and likewise the histopathological assessment owing to inflammatory changes and dysplasia. In this group the pathology report identified three patients with dysplasia without any corresponding suspicious PET findings. They were subjected to frequent consecutive clinical examinations but none of them suffered any local recurrences during the subsequent follow-up period.

Even though a complete response after radiotherapy at the primary site is to be expected, the rate of local relapses remains far from negligible [1,14,15]. In our study population, eight patients (10%) developed a primary site relapse within 9 months of being judged to be in complete remission. The relapses occurred on average 165 days after response evaluation with PET-CT and these results were not considered false negative. Relapses illuminate the importance of thorough follow-up procedures at least during the first year post-radiotherapy. There are an increasing number of studies in favour of PET-CT as part of the surveillance schedule post-therapy, even though the timing of the PET-CT scans might be further debated [15,16].

In the present study, 78% of the primary tumours were visible at the baseline PET-CT. The remaining tumours were either surgically removed during the

diagnostic work-up, i.e. by tonsillectomy, or (in three patients with minimal tongue base tumours) were too small to be detected after diagnostic biopsy. A baseline PET-CT is a prerequisite for comparative studies, in the same way as the baseline clinical status is used for comparison with a post-therapy examination.

So how should we evaluate primary site response after completion of radiotherapy with or without chemotherapy? Minor tumours are elusive and a challenge to detect, regardless of imaging modality. Such small tumours, <5 mm or twice the resolution of the scanner used, may not be detectable by currently available PET scanners, which implies that a negative post-therapy PET scan can represent no remaining tumour cells or as many as 10^7 tumour cells left [17]. Compared with CT and magnetic resonance imaging (MRI), PET has equal sensitivity but better specificity for primary lesions post-treatment [18]. A negative PET-CT, even one performed as soon as 1 month after therapy, is shown to have a high NPV.

In our current protocol, endoscopic evaluation under anaesthesia is the gold standard. Mainly due to long distances in our catchment area, and/or co-morbidity, the procedure requires an average of 24 h (0.79 care days) at the hospital. Taking into account the disadvantages of the procedure, but the excellent remission rate, we have to consider the cost benefits of such a protocol. Since the endoscopic procedure usually is swift the contributions from the attending staff are comparatively large and so are the costs. The cost per admission for an endoscopy including biopsies is €1262 (August 2013 rates) excluding indirect expenditures, such as patients' lost earnings and productivity.

The cost-effectiveness of using PET-CT in selected patients for neck dissection post-radiotherapy instead of performing neck dissection according to the standard regimen has previously been confirmed [19,20]. The cost of a PET-(low-dose)CT scan in our practice is €1374 (August 2013 rate) but costs differ between institutions depending on patient throughput, type of scanner, consumables expenditure and the cost of labour.

The endoscopy cost per admission is therefore comparable to the cost of a PET-CT scan, and the advantages of a reliable, non-invasive method are obvious.

Since 18% of the patients in our study group showed remaining or equivocal metabolism, additional PET-CT scans or endoscopy would have followed the first scan if PET-CT was our sole method of assessment. However, we believe that a clinical examination and thorough patient history would reduce the number of endoscopies needed after an equivocal PET-CT scan.

Conclusion

This study shows that a negative PET-CT scan, in previously PET-positive tumours, approximately 6 weeks post-radiotherapy, is a reliable tool and should be sufficient to rule out residual tumour at the primary site. A protocol involving routine endoscopy with biopsy is therefore superfluous. Patients with positive or equivocal PET findings should be scheduled for endoscopy with biopsy or a second PET-CT scan depending on patient history and clinical examination.

Acknowledgments

This study was supported by grants from the Swedish Foundation Acta Oto-Laryngologica, governmental funding of clinical research within Lund University Hospital and the Region of Scania R&D.


Declaration of interest: The authors report no conflicts of interest. The authors alone are responsible for the content and writing of the paper.

References

- [1] Zackrisson B, Nilsson P, Kjellen E, Johansson KA, Modig H, Brun E, et al. Two-year results from a Swedish study on conventional versus accelerated radiotherapy in head and neck squamous cell carcinoma – the ARTSCAN study. *Radiother Oncol* 2011;100:41–8.
- [2] Porceddu SV, Pryor DJ, Burmeister E, Burmeister BH, Poulsen MG, Foote MC, et al. Results of a prospective study of positron emission tomography-directed management of residual nodal abnormalities in node-positive head and neck cancer after definitive radiotherapy with or without systemic therapy. *Head Neck* 2011;33:1675–82.
- [3] Brun E, Kjellen E, Tennvall J, Ohlsson T, Sandell A, Perfekt R, et al. FDG PET studies during treatment: prediction of therapy outcome in head and neck squamous cell carcinoma. *Head Neck* 2002;24:127–35.
- [4] Passero VA, Branstetter BF, Shuai Y, Heron DE, Gibson MK, Lai SY, et al. Response assessment by combined PET-CT scan versus CT scan alone using RECIST in patients with locally advanced head and neck cancer treated with chemoradiotherapy. *Ann Oncol* 2010;21:2278–83.
- [5] Dahlstrom KR, Calzada G, Hanby JD, Garden AS, Glisson BS, Li G, et al. An evolution in demographics, treatment, and outcomes of oropharyngeal cancer at a major cancer center: a staging system in need of repair. *Cancer* 2013;119:81–9.
- [6] Soderlund-Strand A, Carlson J, Dillner J. Modified general primer PCR system for sensitive detection of multiple types of oncogenic human papillomavirus. *J Clin Microbiol* 2009;47: 541–6.
- [7] Schmitt M, Bravo IG, Snijders PJ, Gissmann L, Pawlita M, Waterboer T. Bead-based multiplex genotyping of human papillomaviruses. *J Clin Microbiol* 2006;44:504–12.

- [8] Dictor M, Warenholt J. Single-tube multiplex PCR using type-specific E6/E7 primers and capillary electrophoresis genotypes 21 human papillomaviruses in neoplasia. *Infect Agent Cancer* 2011;6:1.
- [9] Fakhry C, Westra WH, Li S, Cmelak A, Ridge JA, Pinto H, et al. Improved survival of patients with human papillomavirus-positive head and neck squamous cell carcinoma in a prospective clinical trial. *J Natl Cancer Inst* 2008; 100:261–9.
- [10] Mellin Dahlstrand H, Lindquist D, Bjornestal L, Ohlsson A, Dalianis T, Munck-Wikland E, et al. P16(INK4a) correlates to human papillomavirus presence, response to radiotherapy and clinical outcome in tonsillar carcinoma. *Anticancer Res* 2005;25:4375–83.
- [11] Isles MG, McConkey C, Mehanna HM. A systematic review and meta-analysis of the role of positron emission tomography in the follow up of head and neck squamous cell carcinoma following radiotherapy or chemoradiotherapy. *Clin Otolaryngol* 2008;33:210–22.
- [12] Kim SY, Lee SW, Nam SY, Im KC, Kim JS, Oh SJ, et al. The feasibility of 18F-FDG PET scans 1 month after completing radiotherapy of squamous cell carcinoma of the head and neck. *J Nucl Med* 2007;48:373–8.
- [13] Mori M, Tsukuda M, Horiuchi C, Matsuda H, Taguchi T, Takahashi M, et al. Efficacy of fluoro-2-deoxy-D-glucose positron emission tomography to evaluate responses to concurrent chemoradiotherapy for head and neck squamous cell carcinoma. *Auris Nasus Larynx* 2011;38:724–9.
- [14] Jones AS, Husband D, Rowley H. Radical radiotherapy for squamous cell carcinoma of the larynx, oropharynx and hypopharynx: patterns of recurrence, treatment and survival. *Clin Otolaryngol Allied Sci* 1998;23:496–511.
- [15] Beswick DM, Gooding WE, Johnson JT, Branstetter BF 4th. Temporal patterns of head and neck squamous cell carcinoma recurrence with positron-emission tomography/computed tomography monitoring. *Laryngoscope* 2012; 122:1512–17.
- [16] Kim JW, Roh JL, Kim JS, Lee JH, Cho KJ, Choi SH, et al. F-FDG PET/CT surveillance at 3–6 and 12 months for detection of recurrence and second primary cancer in patients with head and neck squamous cell carcinoma. *Br J Cancer* 2013;109:2973–9.
- [17] Wahl RL, Jacene H, Kasamon Y, Lodge MA. From RECIST to PERCIST: evolving considerations for PET response criteria in solid tumors. *J Nucl Med* 2009;50:122S–50S.
- [18] Kitagawa Y, Nishizawa S, Sano K, Ogasawara T, Nakamura M, Sadato N, et al. Prospective comparison of 18F-FDG PET with conventional imaging modalities (MRI, CT, and 67Ga scintigraphy) in assessment of combined intraarterial chemotherapy and radiotherapy for head and neck carcinoma. *J Nucl Med* 2003;44:198–206.
- [19] Pryor DI, Porceddu SV, Scuffham PA, Whitty JA, Thomas PA, Burmeister BH. Economic analysis of FDG-PET-guided management of the neck after primary chemoradiotherapy for node-positive head and neck squamous cell carcinoma. *Head Neck* 2013;35:1287–94.
- [20] Sher DJ, Tishler RB, Annino D, Punglia RS. Cost-effectiveness of CT and PET-CT for determining the need for adjuvant neck dissection in locally advanced head and neck cancer. *Ann Oncol* 2010;21:1072–7.

Paper III



Long-term results of positron emission tomography-directed management of the neck in node-positive head and neck cancer after organ preservation therapy



Johanna Sjövall^a, Benjamin Chua^{b,c,*}, David Pryor^b, Elizabeth Burmeister^b, Matthew C. Foote^{b,d}, Benedict Panizza^{c,d}, Bryan H. Burmeister^{b,d}, Sandro V. Porceddu^{b,d}

^a Skane University Hospital, Department of ORL–Head and Neck Surgery, Clinical Sciences, Lund University, Sweden

^b Princess Alexandra Hospital, Radiation Oncology, Brisbane, Queensland, Australia

^c Princess Alexandra Hospital, Department of Otolaryngology, Brisbane, Queensland, Australia

^d University of Queensland, St. Lucia, Queensland, Australia

ARTICLE INFO

Article history:

Received 5 August 2014

Received in revised form 10 December 2014

Accepted 11 December 2014

Available online 29 December 2014

Keywords:

Head and neck
Squamous cell carcinoma
PET
Radiotherapy
Chemotherapy
Neck dissection

SUMMARY

Objectives: The current study presents the long-term results from a study designed to evaluate a restaging positron emission tomography (PET) directed policy whereby neck dissections were omitted in all node positive head and neck squamous cell carcinoma (N + HNSCC) patients with PET-negative lymph nodes after definitive radiotherapy (RT), with or without chemotherapy.

Methods: A post-therapy nodal response assessment with PET and computed tomography (CT) was performed in patients who achieved a complete response at the primary site after definitive radiotherapy. Patients with PET-negative lymph nodes were observed regardless of residual CT abnormalities.

Results: One hundred and twelve patients, the majority of whom (83 patients, 74%) had oropharyngeal primaries, were treated on protocol. Median follow-up was 62 months. Negative and positive predictive values for the restaging PET was 97.1% and 77.8% respectively, with only one patient who was PET-negative after treatment experiencing an isolated nodal relapse.

Conclusion: PET-guided management of the neck following organ preservation therapy effectively spares neck dissections in patients with N + HNSCC without compromising isolated nodal control or overall survival.

Crown Copyright © 2014 Published by Elsevier Ltd. All rights reserved.

Introduction

The standard of care for the non-surgical management of patients with node-positive mucosal head and neck squamous cell carcinoma (N + HNSCC) is radiotherapy (RT) with or without chemotherapy, and in many institutions this has traditionally been followed by a planned neck dissection of initially involved nodal regions. Improved imaging modalities are now available to evaluate the response of involved neck nodes and select patients who will potentially benefit from a neck dissection after completion of definitive radiotherapy [1]. In a number of retrospective studies, functional imaging with 18F-fluorodeoxyglucose positron

emission tomography (PET) has been shown to have a high negative predictive value (NPV) in nodal assessment after chemoradiotherapy [2–4].

We have previously reported results from a prospective study designed to evaluate a restaging PET policy where neck dissections were omitted in all N + HNSCC patients with PET-negative lymph nodes after definitive RT, with or without chemotherapy, regardless of the presence of residual lymph nodes on clinical examination and contrast-enhanced computed tomography (CT). With a median follow-up of 28 months from commencement of RT, the protocol appropriately spared neck dissections in patients who achieved a complete PET response at the primary and neck, despite residual structural imaging nodal abnormalities without compromising regional control [5].

The purpose of the present analysis is to present the long-term results of this approach and patterns of recurrences, failure free survival and overall survival.

* Corresponding author at: Department of Radiation Oncology, Princess Alexandra Hospital, Woolloongabba 4102, Queensland, Australia. Tel.: +61 7 3176 2111; fax: +61 7 3176 1970.

E-mail address: benjamin.chua@health.qld.gov.au (B. Chua).

Patients and methods

The study was approved by the institutional ethics board and written informed consent was obtained from all participants. A thorough description of patients and methods is previously described [5] and will be summarized in the following sections.

Patient eligibility and pathological evaluation

Patients were eligible for treatment on protocol if they had biopsy proven N + HNSCC with no evidence of distant metastasis, and after discussion at our multidisciplinary head and neck clinic were considered eligible for organ preservation therapy with definitive RT. For patients with oropharyngeal tumours and those with involved cervical nodes with unknown primary, biopsy p16 status was determined by immunohistochemical (IHC) staining and considered positive if strong and diffuse (nuclear and cytoplasmic) in $\geq 70\%$ of tumour cells.

Only patients who achieved a complete response at the primary site at 12 weeks post-RT were eligible for analysis; primary site response was based on clinical examination, CT and PET findings and a final determination of primary response made at the multidisciplinary team meeting.

Radiotherapy and systemic treatment

All patients were treated with definitive radiotherapy, either with concomitant boost RT or conventionally fractionated RT with or without systemic therapy. Elective sites were treated to a biologically equivalent dose of 50 Gy in 2 Gy fractions. Known sites of gross disease received either 2 Gy/fraction to a total of 70 Gy over 7 weeks or a concomitant boost schedule to a total of 66 Gy over 5 weeks using a morning dose of 2 Gy/day for 5 weeks and an afternoon boost dose of 1.6 Gy/day in weeks 4 and 5.

Selection of systemic therapy was at the discretion of the treating physician but was generally omitted for patients with low-volume disease (T0–2, N1). Concurrent systemic therapy consisted of either high-dose cisplatin (100 mg/m²) given in weeks 1, 4 and 7 or fractionated weekly cisplatin (40 mg/m²). Patients with contraindications to cisplatin received either carboplatin/5-fluorouracil in the final two weeks of radiotherapy, or cetuximab as a pre-radiotherapy loading dose then weekly during treatment.

Diagnostic CT imaging and definitions

A diagnostic contrast-enhanced CT of the head, neck and chest was performed as a baseline pre-therapy, and with the 12-week restaging PET. A residual nodal abnormality on structural imaging was defined as a node demonstrating necrosis, contrast enhancement or ≥ 10 mm in any dimension. Diagnostic CT scans were assessed by a radiologist associated with the multidisciplinary clinic.

PET imaging protocol and definitions

Preparation for imaging was in accordance with the guidelines of the Society of Nuclear Medicine and European association of Nuclear Medicine [6,7]. A Philips Gemini GXL PET/CT system was used and images acquired from skull vertex to mid-thigh, with a low-dose CT for attenuation correction and lesion localization (120 kVp; 30–50 mAs) also acquired.

Two qualified nuclear medicine physicians independently reviewed all the datasets on dedicated MedView display systems (MedImage, Ann Arbor, MI). The PET scans were assessed visually. FDG uptake was considered positive if it was focal, corresponded to

a structural abnormality and was of greater intensity than background liver activity. Where focal FDG avidity was below background liver activity, but of greater intensity than adjacent normal-tissue activity this was considered equivocal. No residual FDG avidity above background or diffuse uptake in the absence of a corresponding structural abnormality was considered negative. Standardized Uptake Value (SUV) were recorded for all PET imaging but not used in the assessment of treatment response algorithm.

PET-directed neck policy

The PET protocol (Fig. 1) consisted of a PET-CT scan performed within 3 weeks prior to commencing, and around 12 weeks post therapy. If the post-treatment PET was considered negative in the neck the patient remained on an observation policy regardless of an incomplete response on CT. If the post-treatment PET demonstrated equivocal nodal FDG avidity a repeat PET was performed 4–6 weeks later; if the repeat PET was equivocal or positive a neck dissection was performed. If the 12-week PET was positive a neck dissection was performed.

Follow-up

Following completion of treatment patients were assessed every 3 months for the first year, every 4 months for the next 2 years and every 6 months for another 2 years. Additional re-imaging was performed only if clinically indicated.

Analysis and statistical considerations

In order to analyze long-term results all patients' medical records were reviewed and, when needed, up-to-date information was obtained from treating physicians.

Isolated nodal failure was defined as nodal recurrence in the absence of any other type of failure, primary and/or distant. Composite nodal failure was defined as nodal failure that occurred in the presence of another failure site(s).

Survival analysis data was calculated using Kaplan–Meier methods using the time from the date of completion of RT until failure (defined below), death or the time of last follow-up. Nodal (isolated or composite) failure-free survival (FFS), locoregional (primary site and nodal) FFS, distant metastasis FFS and overall survival were calculated. Life tables were used to calculate actuarial five-year survival and confidence intervals for the proportion of patients surviving nodal-, locoregional- and distant-failure free. Median follow-up time was calculated using the reverse overall-survival Kaplan–Meier method.

Results

Patient and tumour characteristics

Between January 2005 and April 2009, 121 patients with node-positive HNSCC, suitable for organ preservation treatment, were treated according to the protocol. Four patients did not achieve a complete response at the primary site and five patients did not undergo the restaging PET. These patients were excluded; 112 patients were eligible for the primary analysis and all are also included in the present analysis. Patient demographics, tumour characteristics and TNM staging are summarized in Tables 1 and 2.

The median follow-up time for all eligible patients was 62 months (interquartile range (IQR) 54–67). At close-out date for analysis, 78 patients (70%) were alive with no evidence of

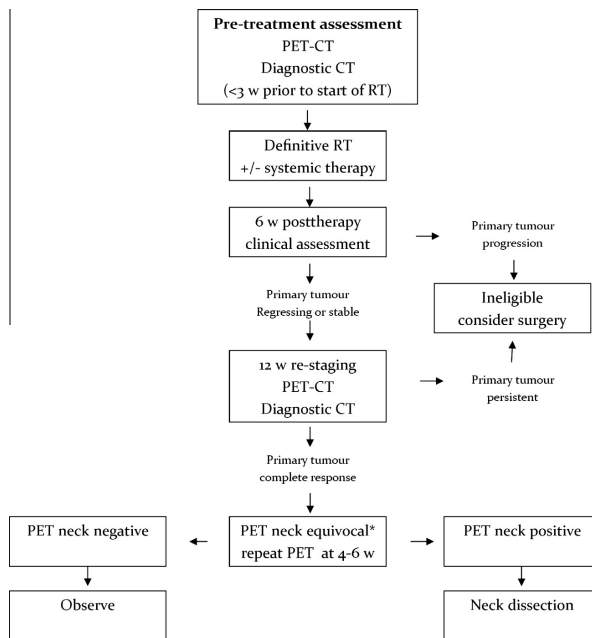


Fig. 1. PET-directed policy for managing the neck. Abbreviations: PET, positron emission tomography, CT, computerized tomography *A further equivocal PET on repeat scanning was treated as positive.

Table 1
Patient demographics and tumour characteristics (n = 112).

Variable	Frequency
Sex	
Female	21 (19%)
Male	91 (81%)
Primary site	
Oropharynx	83 (74%)
P16-positive	59
P16-negative	47
P16 unknown	7
Unknown primary	5
P16-negative	1
P16-unknown	4
Nasopharynx	10 (9%)
Larynx	7 (6%)
Hypopharynx	7 (6%)
Differentiation	
Well differentiated	2 (2%)
Moderately differentiated	46 (41%)
Poorly or undifferentiated	49 (44%)
Unknown	15 (13%)
Smoking status	
Current smoker	41 (37%)
Ex-smoker (ceased < 6 months)	42 (38%)
Never smoked	28 (25%)
Unknown	1 (1%)
Age	
Median (range), years	55 (25–88)
Follow-up time	
Median (IQR) ^a , months	62 (54–67)

^a IQR = Interquartile range.

disease, 20 (18%) had died from disease and 13 (12%) had died from unrelated causes.

Primary treatment received

107 patients (96%) received conventionally fractionated RT to a dose of 70 Gy, while 5 patients (4%) received concomitant boost RT to 66 Gy. A total of 102 patients (91%) received concurrent systemic therapy in the form of cisplatin (n = 86), cetuximab (n = 10) and carboplatin/5FU (n = 6).

PET outcome in patients with complete response on CT

At 12 weeks post therapy 62 patients (55%) showed a complete structural nodal response according to CT criteria. This group of

Table 2
TNM – classification of cohort according to American Joint Committee in Cancer Staging (AJCC), 6th edition.

T classification	No. of patients by N classification			Total
	N1	N2	N3	
T0	1	3	1	5
T1	2	12	1	15
T2	7	30	3	40
T3	2	29	1	32
T4	2	10	8	20
Total	14	84	14	112

patients also had a complete metabolic nodal response at the PET scan (one patient needed a repeat PET after the first was assessed as equivocal). Two composite nodal failures were observed as reported in the initial analysis, and one additional isolated nodal failure, 27 months after completion of therapy, occurred in this group. This patient was an ex-smoker with a p16 positive oropharyngeal primary tumour, T4N3, who failed in the lower neck, supraclavicular fossa and sternal notch 30 months after commencement of radiotherapy.

PET outcome in patients with partial response on CT

In the group with partial nodal response according to CT comprising 50 patients (45%), 41 patients (37%) had a complete metabolic response and were observed, and nine (8%) had persisting metabolic activity following post-treatment PET (their surgical outcomes are discussed subsequently). There were no nodal failures in the observed group. Two patients in the surgical group experienced isolated nodal failures, both of whom had undergone neck dissections as per protocol.

Surgery received

Of the nine patients who had persisting metabolic activity at post-treatment PET, eight of these were scheduled for neck dissection with the remaining patient developing pulmonary metastases at the restaging PET hence considered inappropriate for further locoregional therapy. The extent of the surgery was at the discretion of the head and neck surgeon and encompassed radical neck dissection (3 patients), modified level I–IV (2 patients), level II–IV (2 patients) and level II–V (one patient). No major surgical complications occurred. Viable tumour cells were reported in six out of the eight neck dissection specimens.

Due to one late isolated nodal failure the NPV and PPV for the restaging PET were slightly lower compared with the initial analysis, 97.1% (95% CI 91.1–99.2%) and 77.8% (95% CI 40.2–96.1%) respectively.

Outcome in relation to p16-status

Seventy-seven patients (69%) had tumour p16 status determined. In the p16-negative group comprising 18 patients, one composite (primary and nodal) failure occurred among the observed patients and two isolated nodal failures among the PET-positive patients who underwent planned neck dissections.

In the p16-positive group comprising 59 patients, one isolated nodal, one composite (nodal and distant) failure, and six distant failures occurred among the observed, PET negative patients.

NPV and PPV for p16-negative patients were 92.9% (95% CI 64.2–99.6%), 75% (95% CI 21.9–98.7%) and for p16-positive patients 96.4% (95% CI 86.6–99.4%), 66.7% (95% CI 12.5–98.2%) respectively.

Failure pattern by PET outcome

Among the 9 patients who were PET-positive after treatment, two failures, both isolated nodal failures, occurred following neck dissection.

In the PET negative group who were observed (103 patients), 19 failures were detected during the follow-up period, with distant metastasis (12 patients) being the most common type of relapse. First failure sites are presented in Fig. 2. No nodal failures, isolated or composite, occurred in PET-negative patients with residual structural abnormalities on CT.

Of a total of 21 failures, 10 (47.8% of failures) occurred within the first year, 7 (33%) during the second year and 4 (19%) in years

3–4 after treatment completion. No failures were detected beyond 4 years of follow-up.

For the entire cohort (112 patients), the 5-year nodal FFS was 94% (95% CI 88–97%), locoregional FFS 91% (95% CI 84–95%), distant metastasis FFS 83% (95% CI 75–89%) and overall survival 69% (95% CI 59–77%), see Figs. 3 and 4. The corresponding figures in the initial 2-year analysis were 98%, 93%, 87% and 88% respectively.

For the observed cohort (103 patients), the 5-year nodal FFS was 97% (95% CI 91–99%), locoregional FFS 94% (95% CI 86–97%), distant metastasis FFS 83% (95% CI 74–89%), and overall survival 72% (95% CI 61–80%).

Discussion

Modern radiotherapy in combination with systemic therapy, and the increasing incidence and improved outcomes of patients with HPV-associated oropharyngeal carcinoma [8] contribute to an improved rate of locoregional complete remission following definitive treatment of N + HNSCC [9].

A neck dissection performed after radiotherapy is associated with significant quality-of-life impacts due to impaired neck and shoulder function [10]. An appropriate evaluation of the neck node response after organ preservation therapy is therefore crucial in order to select patients who would potentially benefit from an additional neck dissection and conversely, allow patients to avoid surgery when it is likely to be of no value. Neck node abnormalities subside slowly after radiotherapy and conventional imaging with contrast-enhanced CT 12 weeks post radiotherapy has a low PPV for persistent disease [3].

In this study, qualitative analysis of FDG-PET was used as the primary determinant of treatment response, rather than a quantitative parameter such as maximum Standardized Uptake Value (SUVmax). Interpretation of post-treatment PET scans can be obscured by inflammation, making stratification of patients into responders and non-responders difficult if relying on quantitative parameters alone. Additionally, quantitative parameters derived from 18F-FDG PET such as SUVmax are poorly reproducible, even when scans are performed within a few days of each other [11]. At least one prospective study has demonstrated that SUVmax in isolation does not add significantly to CT in response assessment in head & neck cancer [12]. Recent studies of PET-based response assessment have utilized more sophisticated parameters such as metabolic tumour volume, which has been shown to be prognostic in the post-treatment setting [13], but these remain outside of routine clinical use and were not available at the time of development of our protocol.

The purpose of PET evaluation was to improve the accuracy of response assessment and identify patients with PET-negative residual CT nodal abnormalities who could be appropriately spared a neck dissection. The initial encouraging results from this study were published in 2011 [5]. In addition to benefits for individual patients, there are cost benefits for the health system from omitting a planned or CT-guided neck dissection in favour of a PET-guided strategy [14].

In the present analysis we clearly demonstrate that the PET-protocol continues to be tenable with long-term follow-up. After PET-guided management of the neck, over 90% of the study population, (102 patients), were adequately spared a neck dissection, with only one patient experiencing a relapse with isolated neck failure following complete response on PET. It is noteworthy that this patient had a complete response on restaging CT and would not therefore have been considered eligible for surgery using CT criteria either. Of the eight patients receiving surgery due to persistent PET avidity in the neck only two (2%) had no viable tumour on

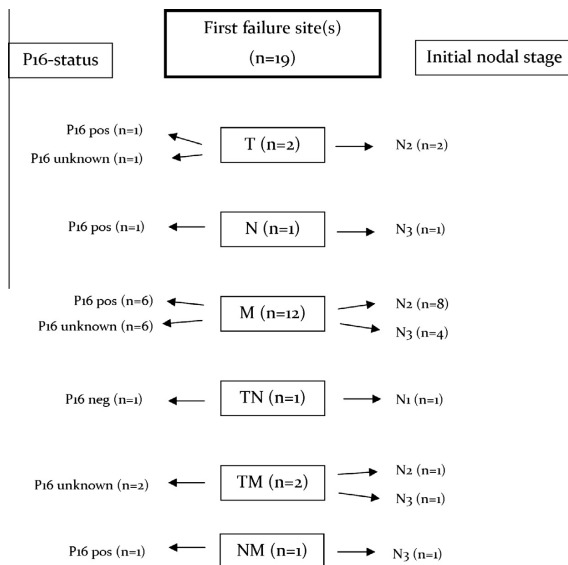


Fig. 2. First failure sites and corresponding p16-status and initial nodal stage in the observed group ($n = 103$).

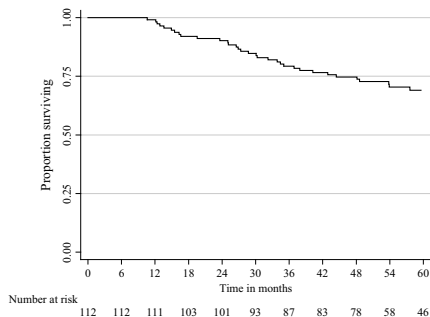


Fig. 3. Overall survival Kaplan–Meier curves for the entire cohort ($n = 112$).

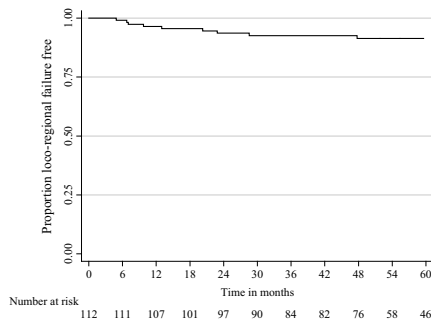


Fig. 4. Locoregional failure-free survival Kaplan–Meier curve for the entire cohort ($n = 112$).

their neck dissection specimens and the surgery may have been considered unnecessary in retrospect. This is consistent with a smaller study by Gupta et al. [15] which reported a high NPV for post-treatment PET in both the primary site and nodes.

Six additional failures, five distant and one composite (primary and distant) have occurred since the last analysis, all of them in patients with complete structural response on post-treatment CT. The most common failure site was distant metastasis which is in accordance with previous studies where excellent regional control is achieved but distant metastases remain an important determinant of long-term survival [16–18].

More than 50% of the study population had p16-positive oropharyngeal tumours. In assessing the proportion of human papillomavirus (HPV) mediated cancers, and the relevance of PET

response in this subset of patients, p16 oncoprotein immunohistochemistry was selected rather than HPV DNA testing. At the time of our study design, detection of p16 overexpression was considered equivalent, if not superior, to HPV DNA detection in prognostication of in oropharyngeal cancers [19]. More recent data suggests that the combination of p16 and HPV DNA detection may aid further in prognostication, particularly in non-oropharyngeal sites [20].

Huang et al. [21] have shown an equal incidence of distant metastasis but a longer disease free interval in patients with p16-positive compared with p16-negative tumours. As reported by Leon et al. [16], no failures in our study population are recorded more than four years post treatment but since our follow-up protocol does not include regular diagnostic imaging of the thorax

there might be an underestimation of distant failures. However, it is highly unlikely that it would affect our conclusions.

A recent retrospective analysis by Ranck et al. [22] suggested that a post-radiotherapy neck dissection might decrease the incidence of distant failure in patients presenting with advanced nodal disease even if a complete clinical remission is achieved, but further prospective studies are needed to confirm if a subgroup of patients actually benefit from planned neck dissections. Regarding regional control, even patients with extensive neck disease have a low rate of regional recurrence when treated with modern techniques [23,24].

The benefit of functional imaging with FDG-PET in evaluating neck node response has been questioned in patients with p16-positive tumours [12,25]. A high rate of complete pathological response in this group causes a lower PPV which to some extent is consistent with our findings. However, the PPV is still superior to CT [26] and more importantly, the NPV remains high which supports an observation policy regarding the neck in PET-negative patients [24].

The emerging role of primary surgery for N + HNSCC, particularly minimally-invasive trans-oral surgery for early stage oropharyngeal tumours, may diminish the role of post-treatment FDG-PET as a determinant of response. Given the high rates of negative margins [27] and locoregional control [28] reported in surgical series of select patients, it is unlikely that PET will have sufficient rates of detection of recurrent disease to justify its routine use in the post-operative setting.

By scheduling the restaging PET 12 weeks after radiotherapy, acute inflammatory changes were given time to subside and the number of equivocal and false positive PET scans in our study was low. No major surgical complications were recorded and we have no indications that an earlier evaluation would have improved our locoregional control. The timing is supported by findings reported by Goguen et al. [29] suggesting no difference in overall survival and surgical complications between patients undergoing neck dissection before compared to after 12 weeks post therapy.

Conclusion

Long-term follow-up of our prospective study confirms that PET-guided management of the neck, following organ preservation therapy, is an appropriate way to spare neck dissections in patients with N + HNSCC. PET-negative neck nodes, regardless of residual structural abnormalities on CT, can safely be observed without compromising isolated nodal control or overall survival. A planned neck dissection can now be considered obsolete.

Conflict of interest

None declared

Acknowledgments

The authors would like to acknowledge Josephine Logan for her diligent maintenance of the PET database over many years, to Dr. Scott Coman and Dr. Bill Coman for their support in enrolment of patients, and to Dr David McFarlane and the PET department at the Royal Brisbane and Women's Hospital for their support of this project.

References

- [1] Ferlito A, Corry J, Silver CE, Shaha AR, Thomas Robbins K, Rinaldo A. Planned neck dissection for patients with complete response to chemoradiotherapy: a concept approaching obsolescence. *Head Neck* 2010;32:253–61.
- [2] Yao M, Graham MM, Hoffman HT, Smith RB, Funk GF, Graham SM, et al. The role of post-radiation therapy FDG PET in prediction of necessity for post-radiation therapy neck dissection in locally advanced head-and-neck squamous cell carcinoma. *Int J Radiat Oncol Biol Phys* 2004;59:1001–10.
- [3] Ong SC, Schoder H, Lee NY, Patel SG, Carlson D, Fury M, et al. Clinical utility of 18F-FDG PET/CT in assessing the neck after concurrent chemoradiotherapy for Locoregional advanced head and neck cancer. *J Nucl Med* 2008;49:532–40.
- [4] Porceddu SV, Jarmolowski E, Hicks RJ, Ware R, Weih L, Rischin D, et al. Utility of positron emission tomography for the detection of disease in residual neck nodes after (chemo)radiotherapy in head and neck cancer. *Head Neck* 2005;27:175–81.
- [5] Porceddu SV, Pryor DI, Burmeister E, Burmeister BH, Poulsen MG, Foote MC, et al. Results of a prospective study of positron emission tomography-directed management of residual nodal abnormalities in node-positive head and neck cancer after definitive radiotherapy with or without systemic therapy. *Head Neck* 2011.
- [6] Delbeke D, Coleman RE, Guibertau MJ, Brown ML, Royal HD, Siegel BA, et al. Procedure guideline for tumor imaging with 18F-FDG PET/CT 1.0. *J Nucl Med* 2006;47:885–95.
- [7] Boellaard R, O'Doherty MJ, Weber WA, Mottaghy FM, Lonsdale MN, Stroobants SC, et al. FDG PET and PET/CT: EANM procedure guidelines for tumour PET imaging: version 1.0. *Eur J Nucl Med Mol Imag* 2010;37:181–200.
- [8] Mehanna H, Beech T, Nicholson T, El-Hariri I, McConkey C, Pateri V, et al. Prevalence of human papillomavirus in oropharyngeal and nonoropharyngeal head and neck cancer—systematic review and meta-analysis of trends by time and region. *Head Neck* 2013;35:747–55.
- [9] Benson E, Li R, Eisele D, Fakhry C. The clinical impact of HPV tumor status upon head and neck squamous cell carcinomas. *Oral Oncol* 2013.
- [10] Bradley PJ, Ferlito A, Silver CE, Takes RP, Woolgar JA, Stojan P, et al. Neck treatment and shoulder morbidity: still a challenge. *Head Neck* 2011;33:1060–7.
- [11] De Langen AJ, Vincent A, Velasquez LM, van Tinteren H, Boellaard R, Shankar LK, et al. Repeatability of 18F-FDG uptake measurements in tumors: a metaanalysis. *J Nucl Med* 2012;53:701–8.
- [12] Moeller BJ, Rana V, Cannon BA, Williams MD, Sturgis EM, Ginsberg LE, et al. Prospective risk-adjusted [18F] Fluorodeoxyglucose positron emission tomography and computed tomography assessment of radiation response in head and neck cancer. *J Clin Oncol* 2009;27:2509–15.
- [13] Murphy JD, La TH, Chu K, Quon A, Fischbein NJ, Maxim PG, et al. Postirradiation metabolic tumour volume predicts outcome in head-and-neck cancer. *Int J Radiation Oncology Biol Phys* 2011;80:514–21.
- [14] Pryor DI, Porceddu SV, Scuffham PA, Whitty JA, Thomas PA, Burmeister BH. Economic analysis of FDG-PET-guided management of the neck after primary chemoradiotherapy for node-positive head and neck squamous cell carcinoma. *Head Neck* 2012.
- [15] Gupta T, Jain S, Agarwal JP, Rangarajan V, Purandare N, Ghosh-Laskar S, et al. Diagnostic performance of response assessment FDG-PET/CT in patients with head and neck squamous cell carcinoma treated with high-precision definitive (chemo)radiation. *Radiother Oncol* 2010;97:194–9.
- [16] Leon X, Quer M, Orus C, del Prado Venegas M, Lopez M. Distant metastases in head and neck cancer patients who achieved loco-regional control. *Head Neck* 2000;22:680–6.
- [17] Vikram B, Strong EW, Shah JP, Spiro R. Failure at distant sites following multimodality treatment for advanced head and neck cancer. *Head Neck Surg* 1984;6:730–3.
- [18] Yao M, Nguyen T, Buatti JM, Dornfeld KJ, Tan H, Wacha J, et al. Changing failure patterns in oropharyngeal squamous cell carcinoma treated with intensity modulated radiotherapy and implications for future research. *Am J Clin Oncol* 2006;29:606–12.
- [19] Weinberger PM, Yu Z, Haffty BG, Kowalski D, Harigopal M, Brandsma J, et al. Molecular classification identifies a subset of human papillomavirus-associated oropharyngeal cancers with favorable prognosis. *J Clin Oncol* 2006;24:736–47.
- [20] Salazar CR, Anayannis N, Smith RV, Wang Y, Haigentz M, Garg M, et al. Combined P16 and human papillomavirus testing predicts head and neck cancer survival. *Int J Cancer* 2014;135:2404–12.
- [21] Huang SH, Perez-Ordóñez B, Weinreb I, Hope A, Massey C, Waldron JN, et al. Natural course of distant metastases following radiotherapy or chemoradiotherapy in HPV-related oropharyngeal cancer. *Oral Oncol* 2013;49:79–85.
- [22] Ranck MC, Abundo R, Jefferson G, Kolokythas A, Wenig BL, Weichselbaum RR, et al. Effect of postradiotherapy neck dissection on nonregional disease sites. *JAMA Otolaryngol Head Neck Surg* 2014;140:12–21.
- [23] Adams G, Porceddu SV, Pryor DI, Panizza B, Foote M, Rowan A, et al. Outcomes after primary chemoradiotherapy for N3 (> 6cm) head and neck squamous cell carcinoma following an FDG-PET guided neck management policy: Does size still matter? *Head Neck* 2013.
- [24] Goenka A, Morris LG, Rao SS, Wolden SL, Wong RJ, Kraus DH, et al. Long-term regional control in the observed neck following definitive chemoradiation for node-positive oropharyngeal squamous cell cancer. *Int J Cancer* 2013;133:1214–21.
- [25] Vainshtein JM, Spector ME, Stenmark MH, Bradford CR, Wolf GT, Worden FP, et al. Reliability of post-chemoradiotherapy F-18-FDG PET/CT for prediction of locoregional failure in human papillomavirus-associated oropharyngeal cancer. *Oral Oncol* 2014;50:234–9.

- [26] Chan JY, Sanguineti G, Richmon JD, Marur S, Gourin CG, Koch W, et al. Retrospective review of positron emission tomography with contrast-enhanced computed tomography in the posttreatment setting in human papillomavirus-associated oropharyngeal carcinoma. *Arch Otolaryngol Head Neck Surg* 2012;138:1040–6.
- [27] Weinstein GS, O'Malley Jr BW, Magnuson JS, Carroll WR, Olsen KD, Daio L, et al. Transoral robotic surgery: a multicenter study to assess feasibility, safety, and surgical margins. *Laryngoscope* 2012;122:1701–7.
- [28] Genden EM, Kotz T, Tong CC, Smith C, Sikora AG, Teng MS, et al. Transoral robotic resection and reconstruction for head and neck cancer. *Laryngoscope* 2011;121:1668–74.
- [29] Goguen LA, Chapuy CI, Li Y, Zhao SD, Annino DJ. Neck dissection after chemoradiotherapy: timing and complications. *Arch Otolaryngol Head Neck Surg* 2010;136:1071–7.

Paper IV