



# LUND UNIVERSITY

## Negative Pressure Wound Therapy - Effects on Sternotomy Wounds and the Intrathoracic Organs

Torbrand, Christian

2012

[Link to publication](#)

*Citation for published version (APA):*

Torbrand, C. (2012). *Negative Pressure Wound Therapy - Effects on Sternotomy Wounds and the Intrathoracic Organs*. [Doctoral Thesis (compilation), Ophthalmology, Lund]. Clinical Sciences, Lund University.

*Total number of authors:*

1

### General rights

Unless other specific re-use rights are stated the following general rights apply:

Copyright and moral rights for the publications made accessible in the public portal are retained by the authors and/or other copyright owners and it is a condition of accessing publications that users recognise and abide by the legal requirements associated with these rights.

- Users may download and print one copy of any publication from the public portal for the purpose of private study or research.
- You may not further distribute the material or use it for any profit-making activity or commercial gain
- You may freely distribute the URL identifying the publication in the public portal

Read more about Creative commons licenses: <https://creativecommons.org/licenses/>

### Take down policy

If you believe that this document breaches copyright please contact us providing details, and we will remove access to the work immediately and investigate your claim.

LUND UNIVERSITY

PO Box 117  
221 00 Lund  
+46 46-222 00 00

# Negative Pressure Wound Therapy

Effects on Sternotomy Wounds and the Intrathoracic Organs

Christian Torbrand  
M.D.



**LUND UNIVERSITY**  
Faculty of Medicine

Clinical Sciences, Lund  
Lund University  
Sweden  
2012



© Christian Torbrand

Lund University, Faculty of Medicine Doctoral Dissertation Series 2012:93

ISBN 978-91-87189-56-2

ISSN 1652-8220

Printed in Sweden by Media-Tryck, Lund 2012

*This thesis is dedicated to*  
*Císsi & Bönan*





# Contents

|  |    |
|--|----|
| Abstract   | i  |
| Summary in Swedish   | ii |
| List of Publications   | iv |
| Associated Publications  | v  |
| Abbreviations  | vi |
| 1. Introduction  | 1  |
| 1.1. Negative pressure wound therapy   | 1  |
| 1.2. Sternotomy wounds   | 2  |
| 1.3. Postoperative deep sternal wound infection  | 3  |
| 1.4. Treatment of DSWI using conventional techniques   | 7  |
| 1.5. Treatment of DSWI using NPWT  | 8  |
| 1.6. Clinical outcome of NPWT versus conventional treatment  | 11 |
| 1.7. Complications during NPWT of DSWI   | 11 |
| 1.8. Wound closure and healing   | 13 |
| 1.9. Effects of NPWT on sternotomy wounds and the intrathoracic organs                                     | 14 |
| 2. Aims  | 21 |
| 3. Materials and Methods   | 23 |
| 3.1. Animal preparation and surgical procedure   | 23 |
| 3.2. Pressure measurements in the thorax   | 23 |
| 3.3. Analysis of neurohormones and neuropeptides   | 24 |
| 3.4. Magnetic resonance imaging  | 28 |
| 3.5. Calculations and statistical analysis   | 30 |
| 4. Results and Discussion  | 31 |
| 4.1. Pressure transduction to the thoracic cavity during NPWT of a sternotomy wound                        | 31 |
| 4.2. Sympathetic and sensory nerve activation during NPWT of sternotomy wounds                             | 33 |
| 4.3. Changes in cardiac pumping efficiency and intrathoracic organ volume during NPWT of sternotomy wounds | 36 |
| 4.4. Wound contraction and macrodeformation during NPWT of sternotomy wounds                               | 40 |
| 5. Main Conclusions  | 43 |
| 6. Current and Future Research   | 45 |
| 7. Acknowledgements  | 47 |
| 8. References  | 51 |
| Papers I-IV  | 67 |



# Abstract

Negative pressure wound therapy (NPWT) has been widely adopted for the treatment of deep sternal wound infections due to its excellent clinical outcome. However, the mechanisms of action and effects on hemodynamics have not been thoroughly elucidated. The aims of the work presented in this thesis were, therefore, to examine the effects of NPWT on sternotomy wounds and on the intrathoracic organs. An uninfected porcine sternotomy wound model was used in all studies.

The studies showed that negative pressure is transmitted only to tissues that are in direct contact with the foam dressing and not to deeper parts of the wound or thoracic cavity.

As NPWT was applied, a transient increase was seen in the plasma levels of norepinephrine and epinephrine, followed by an increase in the adrenergic co-transmitter neuropeptide Y, which may reflect the effect of NPWT on the intrathoracic organs. Increased levels of the sensory nerve transmitter substance P may result from shearing forces arising from the mechanical effects of the negative pressure.

Magnetic resonance imaging showed that cardiac output increased while the cardiac pumping efficiency decreased following sternotomy, and then returned to pre-sternotomy values when the negative pressure resealed the thorax. NPWT contracts the wound and causes macrodeformation of the wound edge tissue. This may contribute to the clinical benefits of NPWT over open-chest treatment, including the stabilizing effect and reduced need for mechanical ventilation.

The results of the present work underline the importance of correct placement of the wound filler with regard to pressure transmission. The findings also reduce concerns that NPWT could impair cardiac output, and emphasize the beneficial effects of temporary closure provided by NPWT on restoring the intrathoracic anatomy.

# Summary in Swedish

*Populärvetenskaplig sammanfattning*

## *Bakgrund*

En till fem procent av de patienter som genomgår öppen hjärtkirurgi får en efterföljande infektion i operationssåret och bröstbenet. Infektionen kan leda till allvarliga komplikationer såsom blodförgiftning, organsvikt och i värsta fall till att patienten avlider. De traditionella metoder som används för att behandla den här typen av infektion har visat sig ha en hög dödlighet, i vissa studier upp till tjugofem procent. Undertrycksbehandling är en relativt ny behandlingsmetod som effektiviserar läkningsprocessen och minskar dödligheten drastiskt.

Innan undertrycksbehandlingen påbörjas måste patienten sövas och det infekterade såret öppnas. Infekterad och död vävnad samt ståltrådar och suturer tas bort. Såret fylls upp med ett sårfillnadsmaterial kallad skumsvamp som har en öppen struktur för att kunna fortplanta undertrycket. Såret täcks därefter med en självhäftande plast för att det ska bli lufttätt. En slang från skumsvampen kopplas till en vakuumpump och när denna sätts på bildas ett undertryck i såret som dras ihop och sårvätska sugs ut. Såret efter hjärtkirurgi är stort och komplicerat och det är viktigt att se till så att organen i bröstkorgen (t.ex. hjärtat) inte påverkas negativt av undertrycket.

## *Målsättning*

Målet med denna avhandling har varit att utforska effekterna av undertrycksbehandling på såret och organen i bröstkorgen. Samtliga studier är gjorda på nersövda grisar. Valet av försöksdjur har styrts av att anatomin på bröstkorgen hos grisar är mycket lik människans.

## *Resultat och diskussion*

Studie I visar att undertrycket bara når de delarna av såret som står i direkt kontakt med skumsvampen, d.v.s. sårkanterna och framsidan av hjärtat. Undertrycket når således inte djupare ner i bröstkorgen. Detta kan förklara fynden i studie III där vi visar att den sårvätska som finns i botten på bröstkorgen inte sugs upp av undertrycket. När patienterna rör sig mellan förbandsbytena är det dock troligt att vätskan så småningom förflyttas i riktning mot såröppningen så att den kan sugas upp. Det viktiga att ta med sig av studie I är att skumsvampen måste placeras i alla delar av såret där läkningseffekter önskas. Fynden i studie I talar också för att det bildas en tryckskillnad mellan den främre och den bakre delen av hjärtat. Detta leder till att hjärtat sugs upp mot det

uppsågade bröstbenet och det finns en risk för att hjärtat skadas när det stöter mot de vassa benkanterna. Just nu pågår intensiv forskning för att ta fram en platta som kan läggas som skydd över hjärtat.

Studie II visar att nivån av vissa stresshormoner ökar i blodet vid undertrycksbehandling av sår efter hjärtkirurgi. Orsaken till denna ökning är okänd men skulle kunna förklaras av förändringar av de anatomiska förhållandena i bröstkorgen då såret sluts av undertrycksbehandlingen. Studie II visar också att i samband med behandlingen ökar utsöndringen av hormoner som kan bidra till inflammation och smärta. Ökad utsöndring av dessa ämnen kan bero på att det uppstår dragkrafter mellan såret och skumsvampen när undertrycket kopplas på. Det är tyvärr vanligt att patienten har ont av behandlingen och undertrycksnivån får då minskas.

Tidigare studier har visat att undertrycksbehandling leder till en försämring av hjärtats pumpfunktion. Detta är något som har oroat läkarna eftersom många patienter som genomgår hjärtkirurgi redan har ett svagt hjärta. I studie III har vi med hjälp av MR-kamera (magnetresonans-kamera) mätt hjärtats pumpfunktion. Resultaten visar att den mängd blod som hjärtat pumpar varje minut ökar då bröstkorgen öppnas under en operation, för att sedan återgå mot det normala när bröstkorgen stängs av sugkrafterna i undertrycksbehandlingen. Studie III visar också att hjärtats och lungornas volymer ökar då bröstkorgen öppnas, för att återgå mot sina ursprungsvolymer när undertrycket kopplas på. Sammantaget så återskapar undertrycksbehandlingen bröstkorgens anatomi och hjärtfunktion och stabiliserar bröstkorgen. Detta gör att patienten inte behöver ligga i respirator utan kan röra sig fritt på avdelningen och därmed återhämta sig snabbare.

I studie IV visar vi, med hjälp av MR-kamera, hur undertrycksbehandlingen drar ihop såret i bröstkorgen. De dragkrafter som uppstår i sårkanterna tror vi leder till att vävnad nybildas och såret läker.

### *Konklusion*

Denna avhandling ger ökad kunskap om undertrycksbehandlingens effekter på såret och organen i bröstkorgen. Undertrycket drar ihop såret, vilket sannolikt stabiliserar bröstkorgen och stimulerar sårläkningen. Tyvärr så utsätts hjärtat för en sugkraft som kan vara skadlig och det pågår intensiv forskning för att skydda hjärtat vid undertrycksbehandling. Som tur är så påverkas inte hjärtats pumpfunktion i nämnvärd grad av behandlingen. Istället så återskapas de ursprungliga anatomiska och fysiologiska förhållandena. Vi hoppas att denna nyvunna kunskap kan komma patienterna till nytta i framtiden.

# List of Publications

This thesis is based on the following papers, which will be referred to by their Roman numerals in the text. The papers are appended at the end of the thesis.

- I. **Torbrand C**, Ingemansson R, Gustafsson L, Paulsson P, Malmsjö M  
Pressure transduction to the thoracic cavity during topical negative pressure therapy of a sternotomy wound  
*Int Wound J.* 2008 Oct;5(4):579-84
- II. **Torbrand C**, Wackenfors A, Lindstedt S, Ekman R, Ingemansson R, Malmsjö M  
Sympathetic and sensory nerve activation during negative pressure therapy of sternotomy wounds  
*Interact Cardiovasc Thorac Surg.* 2008 Dec;7(6):1067-70
- III. **Torbrand C**, Ugander M, Engblom H, Olivecrona GK, Gålne O, Arheden H, Ingemansson R, Malmsjö M  
Changes in cardiac pumping efficiency and intra-thoracic organ volume during negative pressure wound therapy of sternotomy wounds: assessment using magnetic resonance imaging  
*Int Wound J.* 2010 Aug;7(4):305-11
- IV. **Torbrand C**, Ugander M, Engblom H, Arheden H, Ingemansson R, Malmsjö M  
Wound contraction and macro-deformation during negative pressure therapy of sternotomy wounds  
*J Cardiothorac Surg.* 2010 Sep 30;5:75

# Associated Publications

- I. Anesäter E, Borgquist O, **Torbrand C**, Roupé KM, Ingemansson R, Lindstedt S, Malmjö M  
The use of a rigid disc to protect exposed structures in wounds treated with negative pressure wound therapy: effects on wound bed pressure and microvascular blood flow  
*Wound Repair Regen.* 2012 Jul-Aug; 20(4):611-6
- II. Anesäter E, Borgquist O, **Torbrand C**, Roupé KM, Ingemansson R, Lindstedt S, Malmjö M  
A rigid disc for protection of exposed blood vessels during negative pressure wound therapy  
*Surg Innov.* 2012 Apr 18
- III. Anesäter E, Roupé KM, Robertsson P, Borgquist O, **Torbrand C**, Ingemansson R, Lindstedt S, Malmjö M  
The influence on wound contraction and fluid evacuation of a rigid disc inserted to protect exposed organs during negative pressure wound therapy  
*Int Wound J.* 2011 Aug;8(4):393-9
- IV. Malmjö M, Petzina R, Ugander M, Engblom H, **Torbrand C**, Mokhtari A, Hetzer R, Arheden H, Ingemansson R  
Preventing heart injury during negative pressure wound therapy in cardiac surgery: assessment using real-time magnetic resonance imaging  
*J Thorac Cardiovasc Surg.* 2009 Sep;138(3):712-7



# Abbreviations

|      |  |
|------|--|
| CGRP | calcitonin gene-related peptide        |
| DSWI | deep sternal wound infection           |
| HPLC | high performance liquid chromatography |
| MR   | magnetic resonance                     |
| MRI  | magnetic resonance imaging             |
| NPWT | negative pressure wound therapy        |
| NPY  | neuropeptide Y                         |
| SEM  | standard error of the mean             |
| SP   | substance P                            |
| THV  | total heart volume                     |
| THVV | total heart volume variation           |
| VIP  | vasoactive intestinal peptide          |

# 1. Introduction

## 1.1. Negative pressure wound therapy

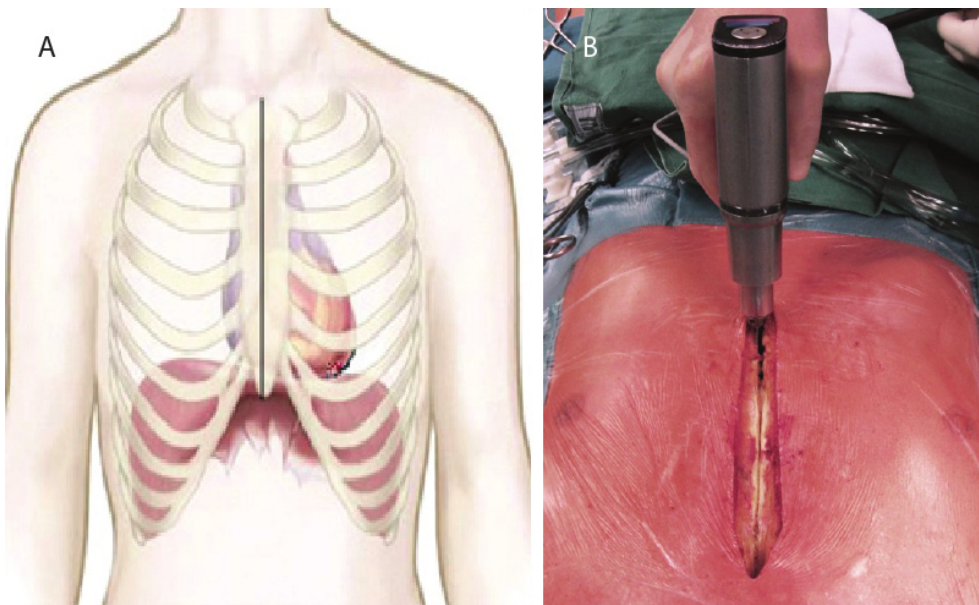
Vacuum therapy was introduced by Bier in 1908, and has now been in use by clinicians for the treatment of open wounds for over a century.<sup>1</sup> Fleischmann and colleagues<sup>2</sup> described more contemporary use of vacuum suction to promote healing in 1993 following the successful use of this technique in 15 patients with open fractures. Four years later, Morykwas and Argenta were the first to try to explain the observed clinical effects using a pig model.<sup>3</sup> Since then, thousands of research articles have been published on the subject.

Commonly used synonyms for negative pressure wound therapy (NPWT) are vacuum-assisted closure therapy, vacuum sealing therapy and topical negative pressure therapy. NPWT is being increasingly used to treat hard-to-heal wounds and is today used worldwide in almost every surgical discipline (trauma surgery,<sup>4</sup> orthopedic surgery,<sup>5</sup> general surgery,<sup>6</sup> vascular<sup>7</sup> and thoracic surgery,<sup>8</sup> plastic surgery,<sup>9</sup> pediatric surgery,<sup>10</sup> urology,<sup>11</sup> and gynecology<sup>12</sup>). Examples of wounds that can be treated with NPWT are traumatic orthopedic<sup>5</sup> and soft tissue wounds<sup>13</sup>, skin grafts,<sup>9</sup> flaps,<sup>14</sup> decubitus ulcers,<sup>15</sup> venous leg ulcers,<sup>16</sup> vascular surgery wounds,<sup>7</sup> diabetic foot ulcers,<sup>17</sup> burns,<sup>18</sup> wound dehiscence following abdominal<sup>19</sup> and thoracic surgery,<sup>8</sup> and surgical infections.<sup>20</sup>

Before negative pressure is applied the wound is filled with a porous material – most commonly, gauze or polyurethane foam.<sup>21</sup> Hermetic sealing of the wound with an adhesive drape prevents entry of air from the environment. Drainage tubes are used to connect the wound to a vacuum source. Suction is applied by the vacuum pump and subatmospheric pressure is propagated through the wound filler to the wound bed, leading to the removal of exudate. Vacuum pumps have been designed to make the treatment as safe as possible, including alarms for leakage (to ensure the wound does not dry out if it is not properly sealed) and occlusion (to ensure that the negative pressure environment is not compromised). The fluid collection canister is visually inspected to monitor drainage and to detect bleeding.

## 1.2. Sternotomy wounds

The most commonly used incision in cardiac surgery is the midline sternotomy,<sup>22</sup> providing access for most operations involving the heart and the great vessels. The surgical technique was first described by Dr. H Milton in “The Lancet” in 1897,<sup>23</sup> and has been the standard approach for open-heart surgery since 1957.<sup>24, 25</sup> An incision extending from the midpoint between the angle of Louis and the sternal notch to below the xiphoid process is made in the skin with a scalpel (Figure 1). This is followed by a diathermy incision through the subcutaneous tissue down to the sternum, which is divided using a standard pneumatic sternal saw (Figure 1). The pericardium is opened anteriorly to expose the heart.<sup>22, 26</sup> The most common procedure in heart surgery is coronary artery bypass grafting, followed by valve repair and replacement surgery.<sup>22</sup> The standard procedure for closing the sternal incision is to use wire sutures to secure the sternum.<sup>22, 27</sup> In general, two wire sutures are placed around the manubrium and four are placed around the edges of the body of the sternum. The wound is then fully closed by sutures in the pre-sternal fascia and in the skin.



**Figure 1.**<sup>28</sup> The incision made for a median sternotomy (A). Median sternotomy being performed with a sternum saw (B).

### 1.3. Postoperative deep sternal wound infection

Postoperative deep sternal wound infection (DSWI) or mediastinitis, postcardiotomy heart failure and stroke are regarded as the three most serious complications after open-heart surgery.<sup>29</sup> Although the incidence of postoperative DSWI is relatively low, between 1 and 5 percent in recent reports,<sup>30-34</sup> its associated early mortality rate varies from 8 to 25 percent.<sup>32, 34</sup> Furthermore, postoperative DSWI is associated with high morbidity,<sup>35, 36</sup> decreased long-term survival,<sup>8, 37</sup> prolonged length of hospital stay<sup>37</sup> and increased cost of care.<sup>38</sup>

#### 1.3.1. Pathogenesis

The organisms most commonly isolated in infected sternotomy wounds after cardiac surgery are gram-positive bacteria, especially *Staphylococcus epidermidis* and *Staphylococcus aureus*.<sup>39-41</sup> Both belong to the normal flora of the skin and the patient's skin is the major source of endogenous contamination of the surgical wound.<sup>42</sup> However, antibiotic-resistant organisms, such as methicillin-resistant *Staphylococcus aureus*, reflecting hospital flora, are becoming more common.<sup>40, 41</sup> Gram-negative organisms and fungal infections are infrequently incriminated in DSWI.<sup>43, 44</sup>

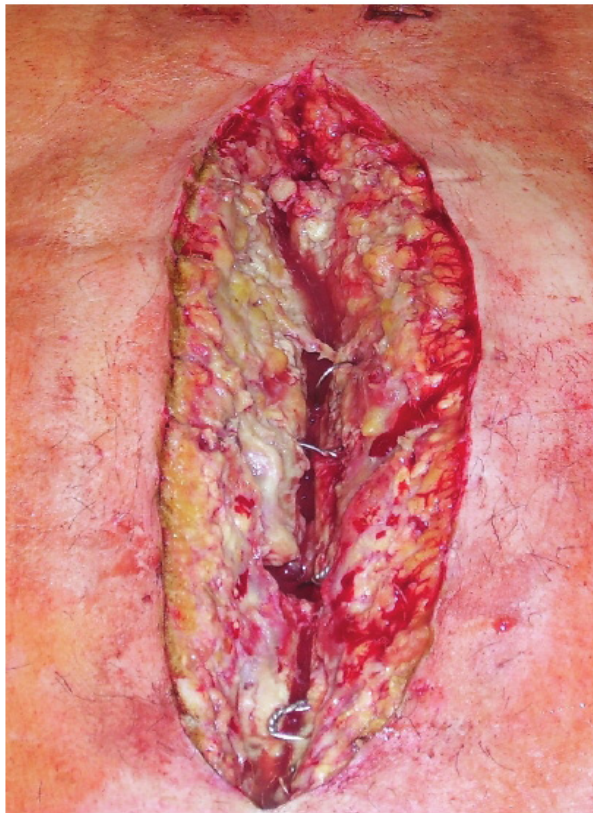
It has been proposed that median sternotomy wound infection starts like osteomyelitis in other bones, with a localized area of sternal osteomyelitis without any external signs.<sup>45, 46</sup> Sternal separation is seen in a few days. Others believe that the key event in the development of postoperative DSWI is sternal instability, followed by seepage of bacteria from the surface of the skin into deeper layers.<sup>47</sup> Another suggestion for the pathogenesis of DSWI is insufficient mediastinal drainage, leading to a large retrosternal collection of wound fluid acting as a culture medium for bacterial growth.<sup>48</sup>

#### 1.3.2. Diagnosis

According to the guidelines of the Centers for Disease Control and Prevention<sup>49</sup> the diagnosis of mediastinitis requires at least one of the following:

1. an organism isolated from culture of mediastinal tissue or fluid obtained during surgery or needle aspiration,
2. evidence of mediastinitis seen during surgery or by histopathological examination, or
3. one of the following: fever ( $>38^{\circ}\text{C}$ ), chest pain, or sternal instability AND any of the following: a) purulent drainage from mediastinal area, b) an organism isolated from blood culture or culture of drainage fluid from the mediastinal area, or c) mediastinal widening on X-ray examination.

The typical signs and symptoms of acute infection are not always present in mediastinitis and fever and leukocytosis may be the only clinical features encountered in a small percentage of patients.<sup>46</sup> Wound discharge is the most common clinical presentation (Figure 2).<sup>50-52</sup> Mediastinitis should always be suspected in patients with unexplained slow postoperative recovery. Bimanual alternating chest compression, to reveal sternal instability, sternal movements or sternal clicks, is the most important and useful diagnostic maneuver.<sup>53</sup> Laboratory investigations can be helpful in confirming the clinical suspicion of mediastinitis, but there is no single test that can definitely exclude a sternal infection.<sup>46</sup> Blood cultures should be performed in patients with a temperature above 38°C after the first 48 hours following operation.<sup>48</sup> Chest X-rays are rarely helpful in the early diagnosis of mediastinitis.<sup>54</sup> Chest computed tomography scanning with mediastinal aspiration may provide valuable information both for diagnostic purposes<sup>55</sup> and for planning future management.<sup>56</sup> However, it can sometimes be difficult to differentiate postoperative tissue changes from early inflammatory tissue.<sup>53</sup> A multidisciplinary approach is thus recommended in the diagnosis of mediastinitis.



**Figure 2.**<sup>28</sup> Poststernotomy mediastinitis with sternal dehiscence, devitalized soft tissue and wound secretion.

### 1.3.3. Prevention

Prevention of infection begins prior to surgery with the identification of patient-related risk factors. Obese patients should be asked to reduce their weight prior to surgery if possible, and efforts should be made to optimize lung function. Preoperative recommendations include hair removal and bathing with chlorhexidine to disinfect the patient's skin immediately before surgery.<sup>57</sup> All the members of the surgical team must adhere strictly to hygienic standards. Prophylaxis using intravenous  $\beta$ -lactam antibiotics (cephalosporins or in Sweden most commonly isoxazolyl-penicillins) during surgery and for up to 48 hours postoperatively, is routinely practiced.<sup>58, 59</sup> Operative recommendations include appropriate aseptic surgical technique including gentle tissue handling, avoidance of ischemia and necrosis, hemostasis, adequate removal of devitalized tissue, elimination of any dead space, judicious use of diathermy and bone wax, appropriate use of drains and suture materials and correct postoperative management of the incision.<sup>60-62</sup>

### 1.3.4. Risk factors

Many risk factors have been identified as being predictive of sternal wound infection following heart surgery, and are divided into preoperative, operative and postoperative as follows.

#### *Preoperative*

- Obesity<sup>57, 63-69</sup>
- Diabetes mellitus<sup>34, 68-71</sup>
- Chronic obstructive pulmonary disease<sup>64, 69, 72, 73</sup>
- Male gender<sup>64, 70</sup>
- Smoking<sup>31, 63, 68, 74</sup>
- Impaired left ventricular ejection fraction <40%<sup>31, 32, 36</sup>
- Renal failure<sup>75-77</sup>
- Cardiac resuscitation (external massage)<sup>36, 78</sup>
- Immunosuppression<sup>79</sup>

### *Operative*

- Inadequate sterility<sup>57</sup>
- Paramedian sternotomy<sup>56</sup>
- Prolonged operative time<sup>36, 67</sup>
- Use of bilateral internal mammary artery grafts<sup>32, 34, 64, 70-72</sup>
- Increasing number of grafts<sup>32</sup>
- Reoperation, e.g. for bleeding<sup>32</sup>
- Re-do surgery<sup>36</sup>
- Transfusion<sup>34, 67, 80</sup>
- Use of diathermy and bone wax<sup>60, 62</sup>
- Incorrect technique for sternal closure<sup>81-83</sup>
- Emergency surgery<sup>84</sup>

### *Postoperative*

- Prolonged mechanical ventilation<sup>31, 73</sup>
- Reoperation, e.g. for bleeding<sup>32</sup>
- Re-do surgery<sup>36</sup>
- Transfusion<sup>34, 67, 80</sup>
- Cardiac resuscitation (external massage)<sup>36, 78</sup>
- Prolonged stay in the intensive care unit<sup>63</sup>

Combinations of risk factors have an additive effect, e.g. bilateral internal mammary artery grafting in a patient suffering from diabetes increases the risk of postoperative DSWI five times.<sup>48, 70</sup> Therefore, identification of high-risk patients is an important first step in preventing this feared complication.

#### 1.3.5. Classification

Sternal wound infections can be superficial, confined to the subcutaneous tissue, or deep; the latter being defined as wound infections associated with sternal osteomyelitis with or without infected retrosternal space.<sup>48</sup> Postoperative DSWI can be classified according to several different systems, e.g. those of Schulman<sup>85</sup> and Jones.<sup>86</sup> The most commonly used system in the literature published in English is that of El Oakley and Wright (Table 1).<sup>48</sup> According to this system, postoperative DSWI is classified into five different subtypes based on the time of first presentation, the presence or absence of risk factors, and whether previous therapeutic attempts have failed.<sup>48</sup> Morbidity and mortality rates increase from type I to type V.

**Table 1.** Classification of deep sternal wound infections in patients undergoing cardiopulmonary bypass grafting according to El Oakley and Wright.

| Class     | Description   |
|-----------|---|
| Type I    | DSWI presenting within two weeks of operation in the absence of risk factors    |
| Type II   | DSWI presenting two to six weeks after operation in the absence of risk factors |
| Type IIIA | DSWI type I in the presence of one or more risk factors                         |
| Type IIIB | DSWI type II in the presence of one or more risk factors                        |
| Type IVA  | DSWI type I, II, or III after one failed therapeutic attempt                    |
| Type IVB  | DSWI type I, II, or III after more than one failed therapeutic attempt          |
| Type V    | DSWI presenting for the first time more than six weeks after operation          |

#### 1.4. Treatment of DSWI using conventional techniques

Early diagnosis and initiation of systemic administration of broad-spectrum antibiotics is essential in the treatment of DSWI. When DSWI is diagnosed, the antibiotic therapy usually involves administration of Vancocin (vancomycin) and Tienam (imipenem/cilastatin) intravenously, which is continued until the results of the tissue cultures become available.<sup>42</sup> Thereafter, the antibiotic therapy is adjusted according to bacterial sensitivity and strain.<sup>42</sup> Prolonged antibiotic therapy alone for the treatment of DSWI is associated with high rates of mortality and morbidity and is nowadays unjustified in the clinic.<sup>48</sup> The same applies to wound incision and drainage alone.<sup>87</sup>

Conventional treatment usually involves surgical revision with open dressings or closed irrigation, or reconstruction with vascularized soft tissue flaps such as omentum or pectoral muscle. These wound healing techniques may be used as a single-line therapy or in combination with other procedures. Previously, DSWI was often treated using a technique called open dressings or wound packing.<sup>8, 88</sup> When signs of DSWI were encountered the management strategy included complete re-opening of the sternal incision and extensive debridement with removal of necrotic tissues, the wound was packed with moist saline-soaked gauze and the chest was left open for one or several days.<sup>8</sup> Dressings were changed several times daily in combination with surgical revision. When the wound was considered clean and there was a bed of fresh granulation tissue, the sternum was closed. This kind of open-chest treatment is associated with thoracic instability and requires prolonged mechanical ventilation and immobilization,<sup>42</sup> leading in turn to high mortality and long hospital stays.<sup>78, 89</sup>



Shumacker and Mendelbaum were the first to describe the closed irrigation technique in 1963.<sup>90</sup> This involved re-opening of the sternum, wound debridement, primary sternal closure, and closed mediastinal catheter irrigation using antibiotics or 0.5% iodine. Closed-chest irrigation systems have the advantage of a stable sternum, but show a high degree of recurrent infection,<sup>91</sup> and unacceptably high rates of failure<sup>92-94</sup> and mortality.<sup>46</sup> A commonly accepted treatment for DSWI is primary, or delayed, wound closure with vascularized soft tissue flaps. In 1976 Lee et al.<sup>95</sup> described a method in which an omentum flap is mobilized and passed through a hole in the peritoneum to the mediastinum (omentopexy or omentoplasty). Jurkiewicz introduced the use of pectoralis muscle flaps in 1980 for closure of mediastinal defects.<sup>96</sup> Others advocate the technique employing the reversed rectus abdominis muscle flap.<sup>97</sup>

There is still little consensus regarding optimal surgical management, and a general lack of a standard treatment protocol.<sup>98</sup> Reconstruction with soft tissue flaps has led to a decrease in the mortality rate in DSWI after cardiac surgery.<sup>86, 99</sup> However, flap-related complications include pain, hernias, ileus, necrosis of the flaps and an unstable thoracic cage.<sup>99-101</sup> Major plastic surgery procedures also entail additional surgical trauma to already weak cardiac patients. In some cases osteitis leads to sternal defects and bone resection procedures are indicated. Sometimes, complete sternectomy is unavoidable with subsequent instability of the thoracic cage. Reconstruction of the thorax can be performed using various kinds of bone plates to stabilize the sternum, allowing a higher quality of life.<sup>102-104</sup>

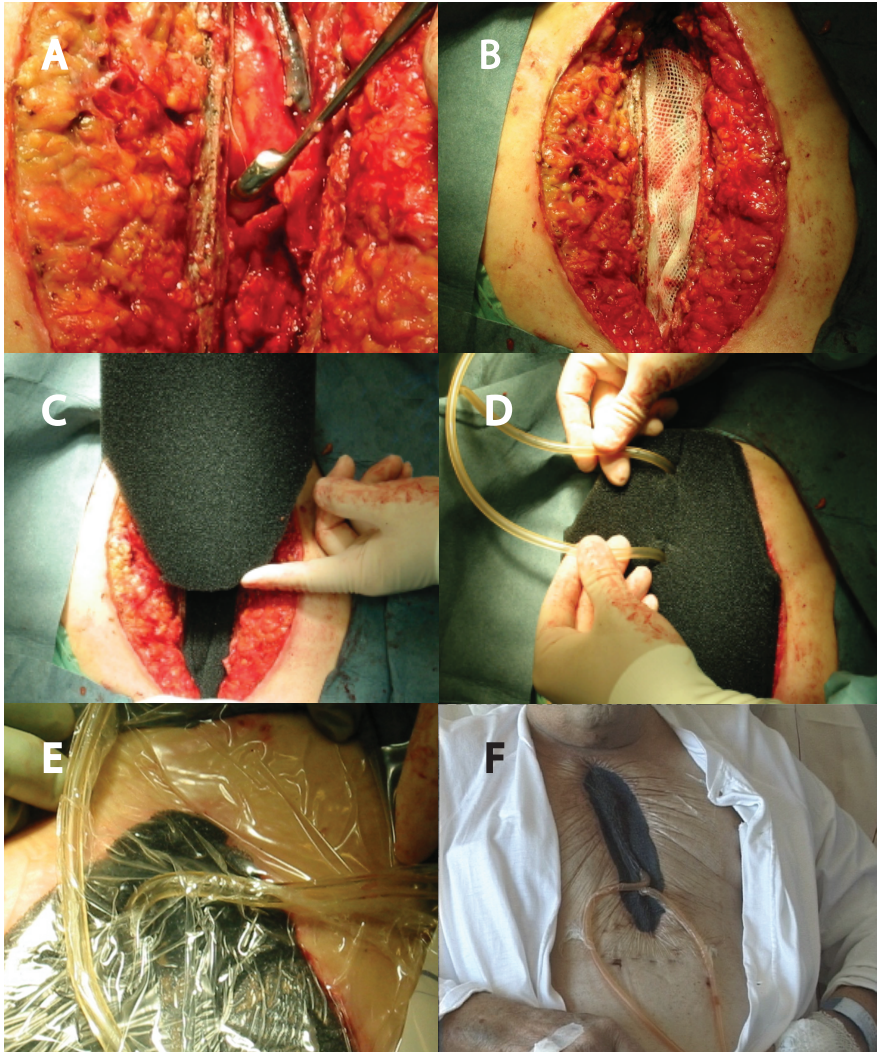
Conventional treatment has disadvantages such as destabilization of the thoracic cage, prolonged immobilization, and substantial surgical trauma, which may be deleterious in a compromised patient.<sup>78, 97, 99, 100</sup> Therefore, less invasive alternatives are needed to effectively control infection and preserve the sternum.

## 1.5. Treatment of DSWI using NPWT

In 1999, Obdeijn and colleagues<sup>105</sup> first described how three patients who had developed DSWI after cardiac surgery were successfully treated using NPWT. Four years later, Gustafsson and colleagues<sup>106</sup> described how the technique was used in 40 consecutive patients with DSWI after cardiac surgery. As a result of the excellent clinical outcome, NPWT became the method of choice for the treatment of DSWI.<sup>42, 107, 108</sup>

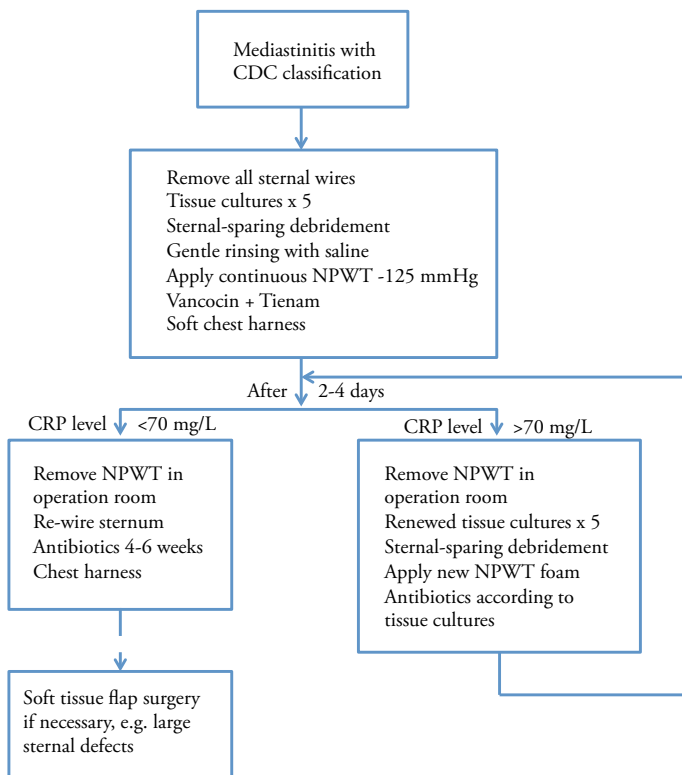
According to Gustafsson et al.,<sup>106</sup> NPWT can be started when clean surgical wound conditions have been created by surgical debridement and all necrotic tissue and infected metal implants (e.g. sternal wires) have been removed. The most commonly used wound filler in DSWI is open-pore polyurethane foam. Three or four layers of paraffin gauze are placed over the free wall of the right ventricle before the first layer of polyurethane foam is positioned between the sternal edges to protect the anterior

portion of the heart and bypass grafts. The second layer of foam is placed subcutaneously, covering the wound completely. Hermetic sealing of the wound with an adhesive drape prevents the entry of air from the environment. Drainage tubes connect the wound to a vacuum source designed for this purpose. The vacuum source is usually set to deliver a continuous negative pressure of -125 mmHg (or -75 mmHg if the patient experiences pain) (Figure 3).



**Figure 3.** Photographs showing the procedure for NPWT in the treatment of DSWI. The wound is opened and debrided (A). Three or four layers of paraffin gauze are placed over the anterior portion of the heart (B). The wound is filled with two layers of foam to allow pressure to be transmitted to the wound (C). Drainage tubes connect the wound to a vacuum pump (D). The wound is then sealed with an adhesive drape (E). The negative pressure is applied (F).

The wound dressing should be changed every two to four days, combined with sampling for bacterial cultures and, if necessary, debridement of the wound.<sup>106</sup> The frequency of dressing changes is dictated by the C-reactive protein levels and dressings are changed under aseptic conditions under general anesthesia.<sup>109</sup> The wound environment is normally clear, i.e., there is a decline in inflammation parameters (leukocytes and C-reactive protein) and negative bacteriological cultures after two to four dressing changes. The wound is considered to be free of infection when the C-reactive protein level is in the range of 30 to 70 mg/L without confounding factors such as the presence of tissue injury or infection elsewhere.<sup>109</sup> In such cases cultures should be taken from the sternum before closure. Furthermore, visual inspection should demonstrate a well-vascularized wound bed covered with granulation tissue. The wound can then be closed and the sternum re-wired. Sjögren and colleagues<sup>42</sup> at the Department of Cardiothoracic Surgery, Lund University, Sweden, have developed a protocol for the treatment of DSWI after cardiac surgery (Figure 4). Successful delayed primary closure, including sternal re-wiring, was possible without the use of vascularized tissue flaps in all patients with DSWI who were treated with NPWT according to this protocol.<sup>42</sup>



**Figure 4.** The Lund University clinical protocol for NPWT of mediastinitis. CDC, the Centers for Disease Control and Prevention.

## 1.6. Clinical outcome of NPWT versus conventional treatment

Previous studies have found that DSWI is an independent factor having a negative influence on long-term survival after coronary artery bypass graft surgery.<sup>32, 36, 110</sup> The reason for this negative prognostic effect is not fully understood, but a serious systemic infection with septic episodes may cause irreversible damage to vulnerable organs such as the heart, kidneys, and bypass grafts.

NPWT has shown promising results on both short- and long-term survival compared with conventional techniques. Two independent studies, one a retrospective study by Sjögren et al.<sup>8</sup> on 101 patients with DSWI, and the other a retrospective study by Deniz et al.<sup>111</sup> on 90 patients with DSWI, have shown significantly lower 90-day mortality and treatment failure in patients with DSWI who were treated with NPWT, compared with conventional methods of treatment. The cause of all deaths was multiorgan failure resulting from severe sepsis. Both studies also showed increased overall survival in the NPWT group. A retrospective study by De Feo et al.<sup>112</sup> on 157 patients supports the finding of reduced mortality following NPWT compared to conventional treatment, and also showed lower reinfection rates using NPWT. In contrast, no difference in long-term survival was seen between patients treated with NPWT and closed drainage with irrigation in a recent retrospective study by Risnes and colleagues<sup>113</sup> on 130 patients. They also reported failure of sternal wound healing and reinfection to be more common in the closed drainage group. A meta-analysis by Damiani et al.<sup>114</sup> of 321 patients showed no significant differences in mortality between NPWT and conventional therapy. Another retrospective study by Sjögren and colleagues<sup>115</sup> showed that DSWI patients treated with NPWT may have similar long-term survival to patients without DSWI after coronary artery bypass grafting.

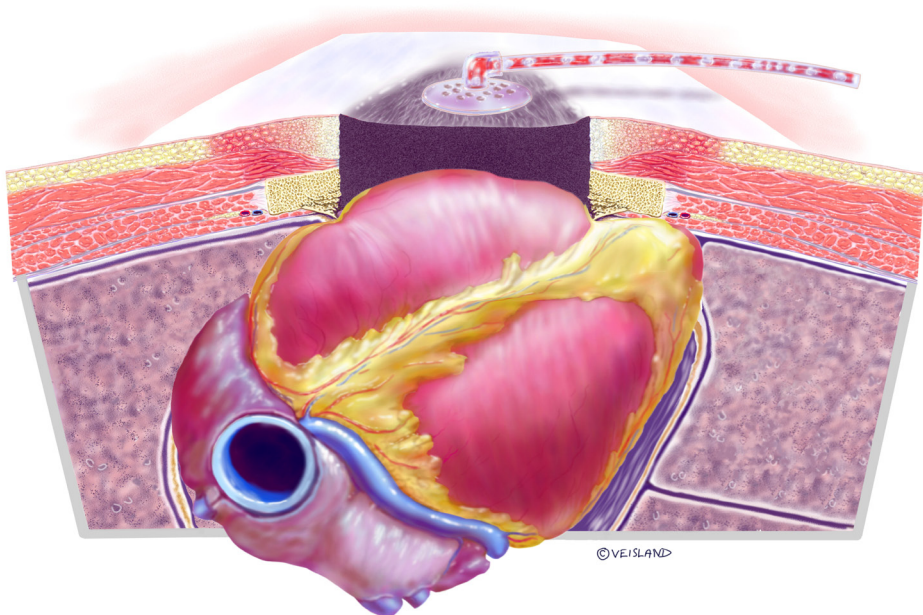
Conflicting results have also been published regarding the length of hospital stay and length of treatment. Doss et al.<sup>37</sup> described a retrospective study demonstrating a shorter length of stay and treatment after NPWT compared with conventional wound management. These results were supported by a retrospective study by Simek et al.,<sup>116</sup> the meta-analysis by Damiani et al.,<sup>114</sup> and the retrospective study by De Feo et al.<sup>112</sup> However, no significant differences were seen in length of hospital stay or treatment duration between NPWT and conventional treatment in the two studies conducted by Sjögren et al.<sup>8</sup> and Deniz et al.<sup>111</sup> mentioned above.

## 1.7. Complications during NPWT of DSWI

The most devastating complication associated with NPWT in patients treated for DSWI after cardiac surgery is heart rupture and bypass graft rupture resulting in death. This occurs in 4 to 7 percent of all cases treated with NPWT for DSWI.<sup>117-127</sup> In 2009, our

group identified the cause of heart rupture through an advanced series of experiments using magnetic resonance imaging (MRI) on pigs undergoing heart surgery.<sup>128</sup> When NPWT was applied the heart was displaced towards the thoracic wall and, in some cases, the right ventricle bulged into the space between the sternal edges, causing the sharp edges of the sternum to protrude into the anterior surface of the heart (Figure 5).<sup>128</sup>

The surgical technique used to minimize the risk of right ventricle rupture has been described by Gustafsson et al.<sup>106</sup> and is explained above. Three or four layers of paraffin gauze are placed over the anterior portion of the heart to reduce adherence between the sternum and the right ventricle. This also protects exposed parts of the right ventricle from the sternal edges. According to our previous study, four layers of paraffin gauze did not prevent the deformation of the heart upon application of NPWT.<sup>128</sup> However, when a perforated rigid plastic disc was placed between the anterior surface of the heart and the thoracic wall, the heart was clearly separated from the sharp sternal edges. Furthermore, the shape of the heart was not affected by NPWT. The development and use of a protective device in NPWT is now the subject of research by our group, as described in the "Current and Future Research" section at the end of this thesis.



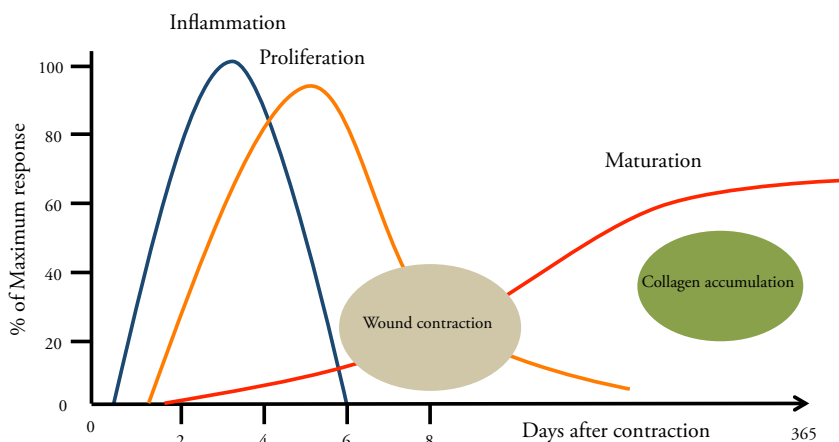
**Figure 5.** A schematic illustration of a cross section of a sternotomy wound showing how the heart is affected when NPWT is applied. The heart is sucked up and damaged by the sternum bone edges.



## 1.8. Wound closure and healing

Wound closure can be divided into three categories: primary, secondary, and tertiary. *Primary closure* involves the closure of a wound within hours of its creation. *Secondary closure* refers to the strategy of allowing wounds to heal on their own without surgical closure. *Tertiary wound closure*, also known as delayed primary closure, involves initial debridement of the wound for an extended period followed by formal closure by suturing or another mechanism.<sup>129</sup>

Wound healing is a complex and dynamic process and can also be divided into three phases (Figure 6).<sup>130</sup> The *inflammatory phase* occurs immediately after the injury and lasts approximately 6 days.<sup>131</sup> After initial wounding, platelets aggregate at the injury site to form a fibrin clot to stop active bleeding.<sup>132</sup> Once hemostasis has been achieved, the blood vessels dilate and become more permeable, which leads to an increase in exudate and allows the migration of inflammatory cells involved in phagocytosis of bacteria and debris.<sup>130</sup> The *proliferative phase* is the anabolic phase of wound healing; it follows the inflammatory phase and can last up to 4 weeks.<sup>131</sup> This phase is characterized by angiogenesis, collagen deposition, granulation tissue formation, re-epithelialization, and wound contraction.<sup>132</sup> Angiogenesis is the formation of new vasculature by vascular endothelial cells.<sup>133</sup> In fibroplasia and granulation tissue formation, fibroblasts excrete collagen and fibronectin to form a new, provisional extracellular matrix.<sup>132</sup> Re-epithelialization of the epidermis, in which epithelial cells proliferate, occurs simultaneously, resulting in a thin epithelial cell layer, which bridges the wound.<sup>134</sup> *Maturation* is the final phase and occurs once the wound has closed and can last for years.<sup>131</sup> This phase involves the remodeling of collagen, which is realigned along tension lines, and cells that are no longer needed are removed by apoptosis.<sup>132</sup>



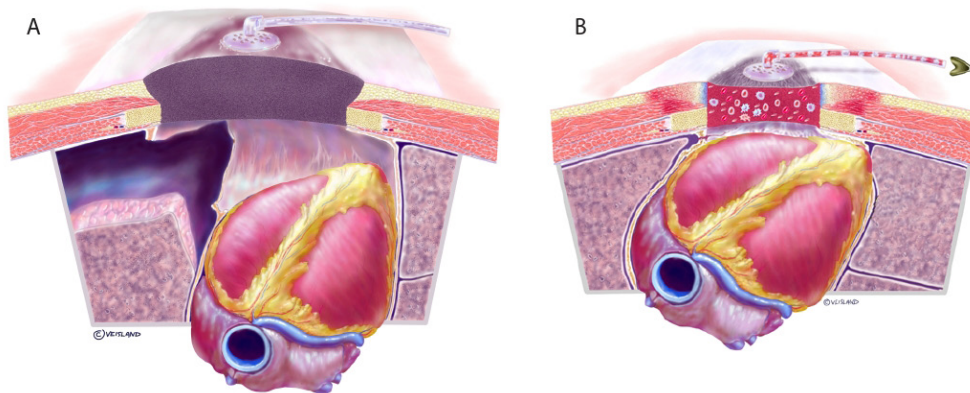
**Figure 6.** Line chart showing the various stages of wound healing.

## 1.9. Effects of NPWT on sternotomy wounds and the intrathoracic organs

The treatment of DSWI with NPWT provides a number of desirable clinical attributes:<sup>135</sup> (Figure 7)

- closure of the wound preventing external infection,
- removal of exudate and aiding the inflow of systemic antibiotics,
- maintenance of sternal stability removing the need for mechanical ventilation, and
- improvement of wound healing of the soft tissue components.

A detailed description of the effects of NPWT on sternotomy wounds and the intrathoracic organs is given below.



**Figure 7.** Illustration of a cross section of the thoracic cavity with an open sternotomy wound before negative pressure is applied (A). Illustration showing some of the effects of the negative pressure (B). Fluid and debris are drained from the wound. NPWT affects local blood flow, reduces wound edge edema, and stimulates angiogenesis and granulation tissue formation (not shown). The foam is inhabited by granulocytes, which may promote bacterial clearance, although this is currently being debated. The sternal wound is stabilized and ventilation is facilitated (not shown). The effect of NPWT on hemodynamics is a matter of controversy (not shown).

### 1.9.1. Sternal wound stabilization

The use of NPWT in the treatment of DSWI after cardiac surgery provides a stable sternum and restoration of the thoracic cage. This reduces the need for mechanical ventilation and enables earlier mobilization compared to conventional open-chest care.<sup>136</sup> NPWT also acts as a bridging therapy for reconstructive surgery, and thus provides adequate temporary stabilization of the thorax, which enhances lung function.<sup>137</sup>

Several technical aspects must be considered before applying a high negative pressure to an open sternotomy wound. One important issue is the way in which the foam interacts with the underlying vital structures such as the heart, lungs and bypass grafts. It has been suggested that a less negative pressure (e.g., -75 mmHg) might lead to insufficient sternal stability with an increased risk of organ damage.<sup>135</sup> In contrast, the application of too great a negative pressure to the mediastinum has been suggested to increase the risk of right ventricular rupture.<sup>121</sup> It has been shown that low negative pressures (-50 to -100 mmHg) stabilize the sternum just as efficiently as high negative pressures (-150 to -200 mmHg).<sup>138</sup> A negative pressure of -125 mmHg is commonly used in clinical practice today and is theoretically a safe choice.<sup>106, 139</sup> Some patients experience pain at this level in which case it can be reduced.<sup>140</sup> The maximum positive or negative pressure that can be induced in the thorax by, for example, breathing or coughing, is approximately  $\pm 75$  mmHg.<sup>135</sup> It is thus likely that -75 mmHg is the negative pressure threshold value that provides sternal wound stability.

### 1.9.2. Hemodynamic effects

Two separate studies in pigs have shown reduced cardiac pumping during NPWT. Using a sonometric technique, Conquest and colleagues<sup>141</sup> showed that negative pressures of 50 and 125 mmHg immediately decreased the left ventricular volume, stroke volume, cardiac output, and systolic blood pressure. Application of a rectus muscle flap to the sternal wound before NPWT significantly reduced the negative hemodynamic effects. Using MRI, our group recently showed that NPWT resulted in an immediate decrease in cardiac output.<sup>142</sup> Interestingly, the effects were smaller (approximately a 10 percent decrease in cardiac output) than reported in the previous study using sonometry, where a decrease of approximately 30 percent was observed.

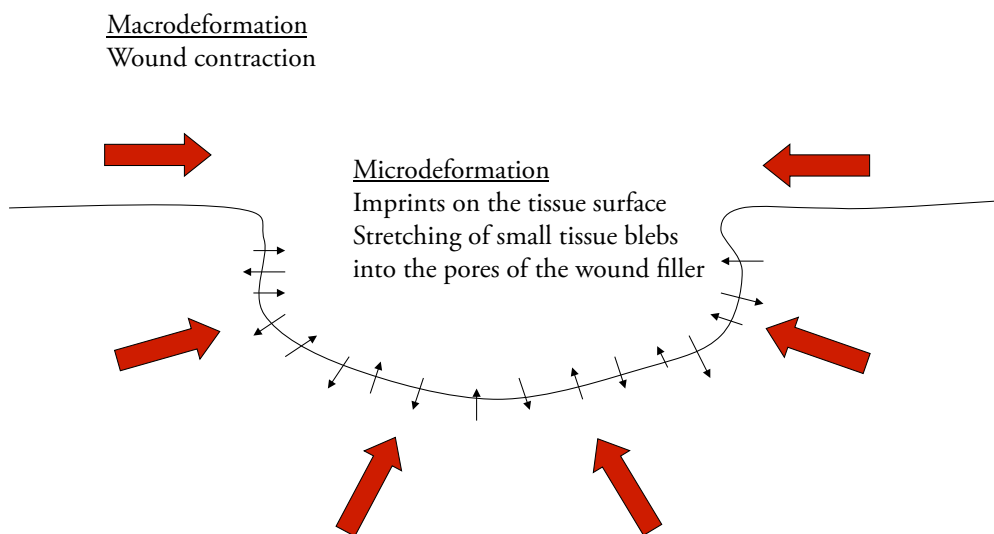
Studies reporting a reduction in cardiac output have caused major concern among cardiac surgeons, especially because many patients with DSWI after cardiac surgery already have reduced cardiac function. Careful monitoring of the hemodynamic function in patients undergoing sternal NPWT has been suggested, especially when cardiac function is reduced.<sup>141</sup> However, the effect of NPWT on cardiac output has hitherto only been studied in sternotomized pigs, and no comparison has yet been made with pigs with an intact chest, i.e., non-sternotomized pigs. In Study III presented in this thesis, the effects of NPWT on the cardiac pumping efficiency and the volumes of the intrathoracic organs were investigated and a comparison made between non-sternotomized and sternotomized pigs upon the application of different negative pressures. The effects of NPWT of sternotomy wounds on stress hormones known to affect the heart,<sup>143, 144</sup> have also been investigated (Study II).



### 1.9.3. Mechanical effects on the wound edges

NPWT pulls the wound edges together, creating shearing forces in the tissue and at the wound–foam interface. This macrodeformation is believed to be one of the fundamental mechanisms by which NPWT results in wound healing.<sup>145</sup> It has also been found in experimental wound models that the wound tissue and the wound filler material interact on a microscopic level (microdeformation) (Figure 8).<sup>146</sup> The wound bed is drawn into the pores of the foam or in between the threads of the gauze. This mechanical stress affects the cytoskeleton of the cells and promotes the expression of growth factors, which in turn stimulate granulation tissue formation and angiogenesis.<sup>147-149</sup>

Several *in vitro* studies have been conducted that demonstrate the role of mechanical tension and shear on the ability of cells to develop and maintain a synthetic phenotype that enables the formation of extracellular matrix and fibrous structural constituents.<sup>150-153</sup> In a computerized model of vacuum-induced wound deformation, most elements were stretched 5 to 20 percent by NPWT, which is similar to *in vitro* strain levels shown to promote cellular proliferation.<sup>146</sup> Study IV was performed to examine the effects of NPWT on wound contraction and macrodeformation in sternotomy wounds.



**Figure 8.**<sup>154</sup> Schematic illustration explaining the deformation of the wound edge tissue during NPWT. Macrodeformation is the effect on the bulk tissue and is dependent on the compliance of the periwound tissues, while microdeformation implies the suction of small tissue blebs or “tissue mushrooms” into the pores of the foam dressing.

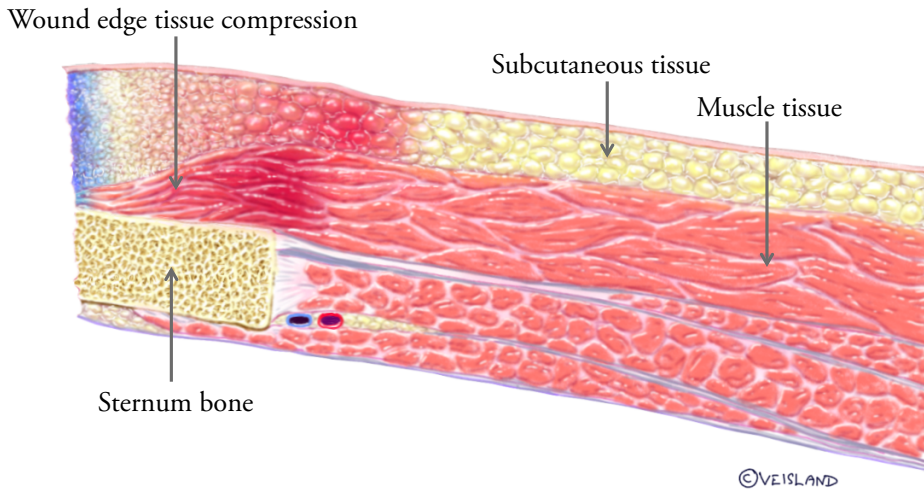
#### 1.9.4. Formation of granulation tissue

Granulation tissue is the well-vascularized fibrous connective tissue that replaces a fibrin clot in healing wounds.<sup>21</sup> It provides a nutrient-rich matrix that allows epidermal cells to migrate over the bed of the wound. The positive effects of NPWT on granulation tissue formation compared to conventional moist gauze therapy were first reported by Morykwas et al.<sup>3</sup> using a porcine back model, and their findings were later confirmed in humans.<sup>15, 155, 156</sup> It is now clear that granulation tissue forms faster as a result of NPWT than with conventional forms of treatment.<sup>157, 158</sup> It is a common belief that the introduction of the wound filler leads to the release of various chemotactic factors. In response, neutrophils and macrophages migrate to the wound area.<sup>159</sup> The cells in the wound bed are transformed into fibroblasts, and a surrounding collagen matrix is formed.

#### 1.9.5. Effect on blood flow in the wound edges

When coronary artery bypass grafting is performed, unilateral or bilateral harvesting of the internal mammary arteries is common practice. DSWI after cardiac surgery is more frequent when bilateral harvesting has been performed, especially in obese patients and those with diabetes.<sup>71, 160, 161</sup> One explanation of the higher risk of infection in these patients could be that the soft tissue is poorly perfused postoperatively. Interest has therefore been directed towards the effect of NPWT on peristernal microvascular blood flow. Most studies on the affects of NPWT on blood flow in the wound edge have been conducted in porcine wound models.<sup>162-165</sup> NPWT has been shown to stimulate the blood flow in the peristernal thoracic wall after internal mammary artery harvesting.<sup>163</sup> Microvascular blood flow has been shown to increase approximately two centimeters into the wound edge, while in the most superficial layers of the wound wall, the microvascular blood flow was reduced (Figure 9).<sup>162, 164, 165</sup> These effects have been observed in both sternal and peripheral wounds.<sup>164, 165</sup>

The combination of increased blood flow in the peristernal soft tissue and decreased blood flow in the superficial tissue is believed to be advantageous in the wound healing process.<sup>21</sup> Increased blood flow may lead to improved oxygen and nutrient supply to the tissue, as well as improved penetration of antibiotics and removal of waste products. The mechanism underlying the increased blood perfusion in the peristernal soft tissue is not known. It has been speculated that the negative pressure causes a pulling force in the tissue that opens up capillaries and vascular beds, thereby increasing blood flow.<sup>21</sup> The mechanism underlying the reduction of blood flow in the superficial tissue has been identified. NPWT exerts compressive forces on the tissue.<sup>166, 167</sup> NPWT may also be beneficial during surgical procedures as it has been shown to tamponade superficial bleeding.<sup>168</sup> When tissue perfusion is reduced, angiogenic factors are released which stimulate the formation of new blood vessels.<sup>169</sup> This promotes granulation tissue formation and, ultimately, wound healing.



**Figure 9.** Detailed illustration of a cross section of the sternal wall showing the immediate effects of the application of NPWT (to the left in the image). Note how the pressure against the wound edge compresses the tissue, probably resulting in edema removal. Local blood flow is reduced in the immediate proximity of the foam (blue), whereas blood flow is increased 1 to 2 cm from the wound edge (dark red).

#### 1.9.6. Bacterial clearance

There is a common misconception that NPWT controls or reduces the bacterial burden in the wound. In an initial study on pig wounds inoculated with human *Staphylococcus aureus* and *Staphylococcus epidermidis* a reduction in bacterial counts during the course of NPWT was reported.<sup>3</sup> However, no clinical studies since then have been able to confirm the early *in vivo* findings of Morykwas et al.,<sup>156, 170, 171</sup> and some have even reported an increase in bacterial numbers during NPWT.<sup>145, 171, 172</sup> NPWT has been shown to cause a shift in the bacterial species towards biofilm-producing organisms such as *S. aureus* and *S. epidermidis*.<sup>156, 170, 171</sup> It has been hypothesized that occlusion and negative pressure create relative hypoxia, thus promoting anaerobes resulting in a shift in microorganism populations.<sup>170</sup> The current recommendation is that NPWT should not be used in isolation to control wound infections ([www.npwtexperts.com](http://www.npwtexperts.com)). An advantage of NPWT is, however, that it is a closed system that isolates the wound and prevents contamination from the surroundings.<sup>109</sup>

### 1.9.7. Edema

After wounding, an inflammatory reaction causes tissue edema, which in turn increases the interstitial pressure and reduces blood flow.<sup>21</sup> As a result, nutrition and oxygenation of the wound edge are compromised, which decreases the resistance to secondary infections and delays healing. Thus, to ensure proper healing it is important to reduce tissue edema. NPWT causes compression of the tissue closest to the surface of the wound, which is believed to reduce interstitial edema.<sup>166</sup> However, no detailed studies have been carried out to investigate this possible effect of NPWT. Nonetheless, this is clearly seen in the everyday clinical environment.

### 1.9.8. Wound drainage

Surgeons have used negative pressure suction to drain surgical wounds for many years. This is also the basis of NPWT, but in a more controlled manner. It is believed that active suction removes inhibitory components (e.g., proteolytic enzymes and metalloproteinases), which have been observed at high levels in chronic wounds and are known to degrade the extracellular matrix and delay wound healing.<sup>173, 174</sup> It has also been suggested that the removal of proinflammatory cytokines, which may have immunosuppressive effects on wounds, has a positive effect.<sup>175, 176</sup> NPWT probably improves the wound environment, but no quantitative studies have yet been performed to evaluate this hypothesis. The drainage of wound fluid from the deeper parts of the thoracic cavity has been suggested as one of the positive factors promoting healing of sternotomy wounds using NPWT.<sup>135</sup> Study I was designed to investigate the extent to which negative pressure is transduced to the anterior portions of the heart and to deeper parts of the thoracic cavity. In Study III the volume of the wound fluid before and after NPWT was measured using MRI.



## 2. Aims

The general aim of the work presented in this thesis was to investigate the effects of NPWT on sternotomy wounds and the intrathoracic organs.

The specific aims were:

- I. to investigate the extent to which negative pressure is transduced to the sternotomy wound, heart and deeper regions of the thoracic cavity during NPWT,
- II. to investigate whether the plasma levels of certain neurohormones and neuropeptides are affected by the application of NPWT to sternotomy wounds,
- III. to study the effects of NPWT on the cardiac pumping efficiency and the volumes of the intrathoracic organs using MRI, and
- IV. to investigate the effects of NPWT on sternotomy wound contraction and wound edge tissue deformation using MRI.



# 3. Materials and Methods

## 3.1. Animal preparation and surgical procedure

The studies were approved by the Ethics Committee for Animal Research, Lund University, Sweden.

An uninfected porcine sternotomy wound model was used in the experiments. In total, 31 pigs were used in these studies. The animals were under full anesthesia during the entire duration of the experiments. Detailed descriptions of the anesthesia can be found in the respective papers.

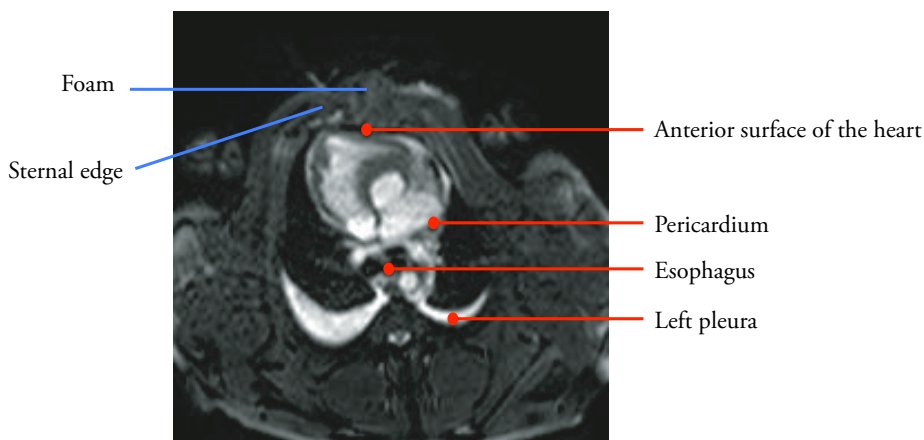
When treating DSWI the sternotomy is re-opened and NPWT is applied between the edges of the sternum and the soft tissue, in which case the wound filler will be in direct contact with the heart. The heart was covered with four layers of paraffin gauze dressing. A polyurethane foam dressing was placed between the sternal edges and two non-collapsible drainage tubes were inserted into the foam. A second layer of foam was placed over the first layer and secured to the surrounding skin with sutures. The open wound was then sealed with a transparent adhesive drape. The drainage tubes were connected to a vacuum source, which could be set to deliver a freely adjustable continuous pressure.

## 3.2. Pressure measurements in the thorax

Study I was performed to investigate the extent to which negative pressure is transduced to the heart and deeper regions of the thoracic cavity during NPWT. Seven pigs were sternotomized. Pressure measurements in the thorax were made as follows. Three saline-filled pressure catheters were inserted through the sternotomy wound; one was placed in the left pleura, the second in the pericardium (under the heart) and the tip of the third on the surface of the heart (under the foam). A fourth pressure transduction catheter was inserted through the mouth into the esophagus so that the tip was positioned level with the heart. The pressure catheters were connected to a calibrated custom-built pressure gauge (Figure 10). The wound was then prepared for NPWT. The vacuum



source was set to deliver negative pressures between -50 and -200 mmHg. The pressure in the thorax was recorded on the anterior surface of the heart (under the foam), in the pericardium (under the heart), in the left pleura, and in the esophagus.



**Figure 10.** Magnetic resonance (MR) image showing a cross section of the thoracic cavity of a pig with an open sternotomy. Pressure transduction catheters were placed on the anterior surface of the heart (under the foam), in the pericardium (under the heart), in the esophagus, and in the left pleura.

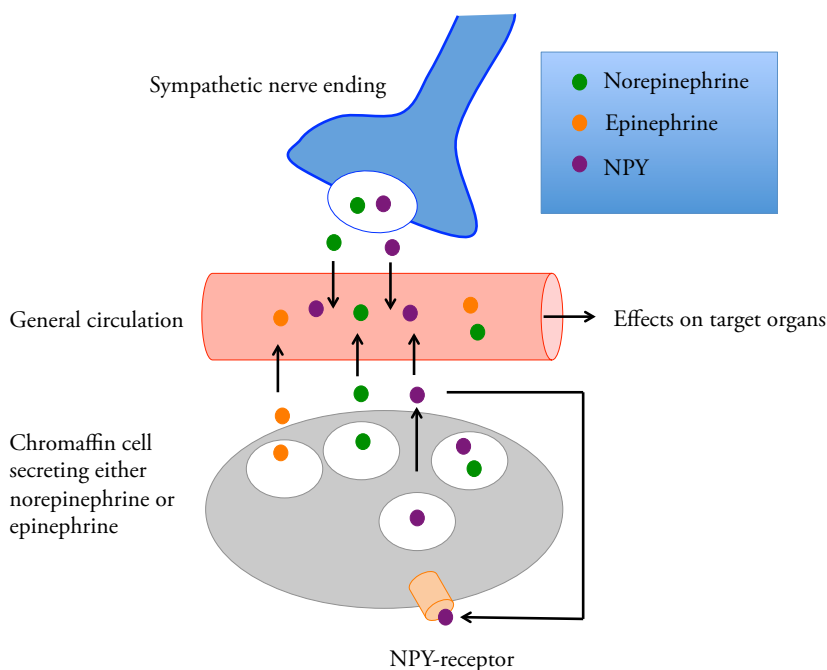
### 3.3. Analysis of neurohormones and neuropeptides

Study II was performed to investigate whether the plasma levels of norepinephrine and epinephrine (also called noradrenaline and adrenaline, respectively), neuropeptide Y (NPY), substance P (SP), vasoactive intestinal peptide (VIP) and calcitonin gene-related peptide (CGRP) are affected by NPWT in sternotomy wounds.

Norepinephrine and epinephrine are neurotransmitters and hormones produced mainly by the chromaffin cells of the adrenal medulla and the postganglionic fibers of the sympathetic nervous system.<sup>177</sup> NPY is co-localized with norepinephrine in sympathetic nerve terminals and is released when the rate of nerve firing is high.<sup>143</sup> NPY is also released from chromaffin cells in the adrenal medulla.<sup>178</sup> NPY enhances the effects of norepinephrine and accounts for the long-term effects of sympathetic nerve transmission (Figure 11).<sup>143</sup> Sympathetic nerve activation triggers the fight-or-flight response in stressful times and emergency situations.<sup>177</sup> As a result, blood sugar levels rise, blood vessels constrict and the heart beats faster (together raising the blood pressure), and blood is temporarily diverted from nonessential organs to the brain, heart and skeletal muscles. At the same time, preganglionic sympathetic nerve endings that weave through the adrenal medulla trigger the release of catecholamines, which reinforce and prolong the fight-or-flight response.<sup>177</sup>

VIP is a co-transmitter in the parasympathetic nervous system.<sup>179</sup> It is involved in the autonomic regulation of the cardiovascular system, where it exerts positive inotropic and chronotropic effects, and causes coronary vasodilatation.<sup>179</sup> SP and CGRP are released from primary afferent neurons upon the stimulation of pain, and act in the periphery to stimulate vasodilatation and promote inflammation.<sup>180-183</sup> This mechanism, known as “neurogenic inflammation”, amplifies and sustains an inflammatory reaction.<sup>183</sup>

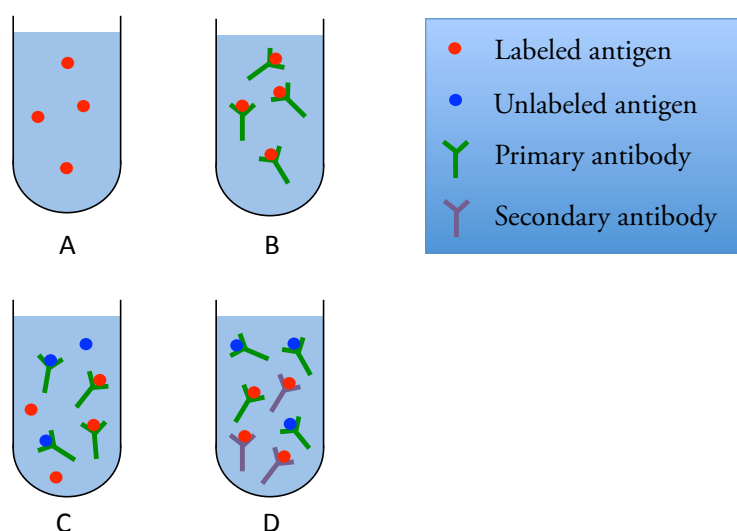
For the experiments of Study III, twelve pigs were sternotomized: six were treated with NPWT, while the other six were not (referred to as sham-treated). Blood samples were collected from a central venous catheter before (0 minutes) and 5, 20, 60, and 180 minutes after NPWT was started, in both the NPWT and the sham-treated pigs. Blood samples were not taken until one hour after the sternotomy to minimize the effects of the surgical procedure on the results.



**Figure 11.** Schematic drawing representing the involvement of NPY originating from the sympathetic nervous system and the adrenal gland during stress. NPY is co-released with norepinephrine from nerve endings. Furthermore, NPY is also secreted from chromaffin cells in the adrenal medulla and stimulates catecholamine release by an autocrine/paracrine mechanism.<sup>178</sup> Therefore, NPY acts as an important modulator of the sympathetic function by sustaining the catecholamine plasmatic levels and potentiating their effects during stressful situations.

### 3.3.1. Radioimmunoassay

NPY, SP, VIP and CGRP were analyzed at The Neurochemistry Laboratory, Institute of Neuroscience and Physiology, The Sahlgrenska Academy at the University of Gothenburg, Mölndal, Sweden using radioimmunoassay, as described previously.<sup>184-187</sup> Radioimmunoassay is a very sensitive method for the measurement of the *in vitro* concentration of an antigen (for example, hormone levels in the blood) by use of antibodies (Figure 12). A known amount of an antigen is radioactively labeled with a gamma-emitting isotope of iodine attached to tyrosine. The radiolabeled antigen is then mixed with a known quantity of antibody for that antigen and the two will bind to one another. A sample of serum from a patient containing an unknown amount of the same antigen is added to the mixture. This initiates a competitive reaction for antibody binding sites between the unlabeled antigen from the serum sample and the radiolabeled antigen from the preparation. Thus, as the concentration of unlabeled antigen increases, more of it will bind to the antibody, displacing the labeled variant. The bound antigens are then separated from the unbound ones using a secondary antibody that recognizes the primary antibody. The radioactivity of the free antigen remaining in the supernatant is measured using a gamma counter. Using known standards, a binding curve can then be generated which allows the amount of antigen in the patient's serum to be analyzed.

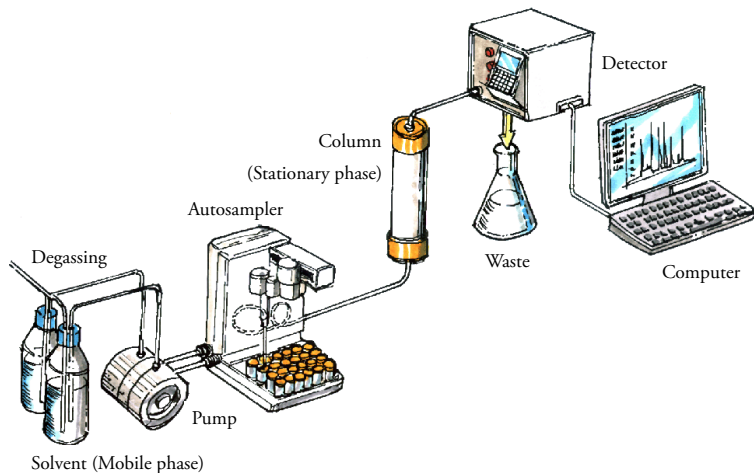


**Figure 12.** A schematic illustration of a radioimmunoassay. A known concentration of a radioactively labeled antigen is added to a buffer (A). A known amount of antibody (primary antibody) for that antigen is then added to the tubes (B). Increasing amounts of unlabeled antigen are added, resulting in competition between the labeled and unlabeled antigen for the limited number of binding sites on the antibody (C). The antibody-bound labeled antigen can then be separated from the free labeled antigen using a secondary antibody (D).

### 3.3.2. High-performance liquid chromatography

Norepinephrine and epinephrine were analyzed at *Labmedicin Skåne* in Malmö, Sweden using a high-performance liquid chromatography with fluorescence detection, as described previously.<sup>180, 181</sup> Chromatography is a technique used to separate a mixture into its individual components. High Performance Liquid Chromatography (HPLC) is a form of column chromatography in which a sample mixture or analyte in a solvent (known as the mobile phase) is pumped through a column packed with solid particles (known as the stationary phase) at high pressure (Figure 13). The sample is carried by a carrier gas stream of helium or nitrogen. HPLC has the ability to separate, and identify compounds that are present in any sample that can be dissolved in a liquid at trace concentrations as low as parts per trillion.

HPLC is used in a variety of industrial and scientific applications, such as pharmaceutical, environmental, forensics, and chemicals. Sample retention time will vary depending on the interaction between the stationary phase, the molecules being analyzed, and the solvent, or solvents used. As the sample passes through the column it interacts with the two phases at different rates, primarily due to the different polarities of the analytes. Analytes that interact least with the stationary phase or most with the mobile phase will exit the column faster. After separation the catecholamines were converted into the corresponding fluorescent compounds and the plasma levels determined using a fluorescence detector.



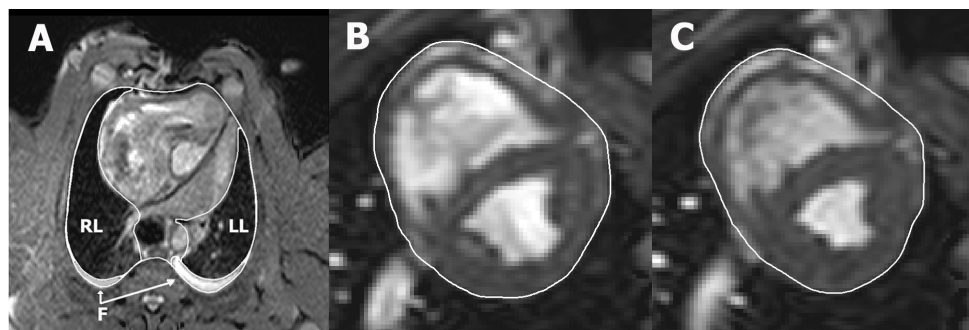
**Figure 13.** An illustration of the setup used for HPLC. The solvent, which is referred to as the mobile phase, is held in a minimum of two reservoirs. Each reservoir holds up to 1000 cc of solvent and is usually fitted with a gas diffuser through which helium can be bubbled. The injector, or autosampler, introduces the solvent into a phase stream that carries the sample into the high-pressure (up to 400 bar) column, which contains packing material, referred to as the stationary phase, used to effect separation. A detector is used to visualize the separated compounds as they elute from the high-pressure column. The information from the detector is presented as a chromatogram on a computer. The mobile phase exits the detector and is either voided or collected.

### 3.4. Magnetic resonance imaging

Studies III and IV were performed to investigate the effect of NPWT on intrathoracic organ volume and wound contraction using MRI. Six pigs underwent sternotomy and NPWT, while six control pigs were not sternotomized. Studies III and IV were performed simultaneously, using the same negative pressures, setup and MRI scanner. Both the sternotomized and non-sternotomized pigs were used in Study IV, while only the sternotomized pigs were used in Study III. MRI was first performed at baseline (0 mmHg). A negative pressure was then applied and MRI was performed when the target pressure had been reached. This procedure was repeated for each negative pressure (-75, -125, and -175 mmHg). The topography of the porcine thorax was visualized with the help of MRI in the transverse and sagittal planes, covering the entire thoracic cavity. The heart was imaged in the short-axis, and two-, three- and four-chamber long-axis planes. For detailed descriptions of the MRI settings, see Papers III and IV. The images in Study III and IV were evaluated using the freeware Segment 1.699 (<http://segment.heiberg.se>).<sup>188</sup>

#### 3.4.1. Analysis of intrathoracic organ volume

Intrathoracic volume measurements were made from the transverse images using simultaneous viewing of sagittal images and image plane intersections for orientation (Study III). The right lung, left lung, intrathoracic wound fluid and total thoracic areas were manually delineated by defining dedicated regions of interest in all transverse images (Figure 14).



**Figure 14.** Illustration of manual delineation of organ volumes. Image (A) shows how the intrathoracic structures were outlined in a transverse MR image through the thorax of a pig with an open sternotomy wound. The right lung (RL), left lung (LL) and intrathoracic fluid (F) were delineated in each image throughout the entire thorax, allowing the volume of each structure to be quantified. Images (B) and (C) show short-axis MR images of the same animal's heart in end diastole and end systole, respectively. The pericardial border of the heart was manually delineated in all short-axis slices covering the entire volume within the pericardium. The total heart volume was then quantified in end diastole and end systole, as well as the variation in total heart volume throughout the cardiac cycle.

### 3.4.2. Total heart volume variation and cardiac output

In order to quantify the cardiac pumping efficiency, the total heart volume variation (THVV) throughout the cardiac cycle was measured (Study III). THVV has been shown to be around 8 percent in human subjects and the major contribution to the change in volume is found in the region around the AV plane with a left-sided predominance.<sup>189</sup> A large change in total volume could result in energy loss through displacement of surrounding tissues, or induce a pendular motion of cardiac tissue and blood.<sup>190-193</sup> Thus, an increase in THVV leads to a decrease in cardiac pumping efficiency.<sup>189</sup>

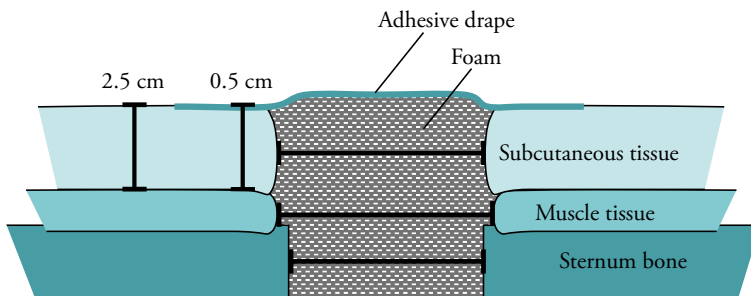
The total heart volume (THV) was measured by manually delineating the pericardial border of the heart in short-axis images (Figure 14) in both end diastole and end systole, as described previously.<sup>189</sup> Long-axis images and image plane intersections were viewed simultaneously for orientation. THVV, expressed in percent, was calculated according to the following formula:

$$\text{THVV (\%)} = [(\text{THV in end diastole} - \text{THV in end systole}) / \text{THV in end diastole}] \times 100.$$

Cardiac output data from two previously published studies (NPWT treated pigs<sup>142</sup> and control pigs<sup>194</sup>) were analyzed. Cardiac output was measured using phase contrast velocity encoded MRI flow quantification in the ascending aorta.<sup>142</sup>

### 3.4.3. Wound contraction

Measurements of wound contraction and soft tissue macrodeformation were performed using the same transverse images acquired at the cardiac midventricular level before (0 mmHg) and after the application of -75, -125 and -175 mmHg (Study IV). The distances between the two wound edges of subcutaneous tissue, muscle tissue and sternum bone were measured (lateral wound width). The anterior-posterior thickness of the soft tissue, including the subcutaneous and muscle tissue, was measured at distances of 0.5 cm and 2.5 cm from the wound edge (Figure 15).



**Figure 15.** Schematic illustration showing a transverse section through a sternotomy wound and the location of the wound dimension measurements.

### 3.5. Calculations and statistical analysis

Statistical analysis was performed using the Kruskal-Wallis test with Dunn's post-test for multiple comparisons (Studies I and III) or Student's t-test, unpaired (Study II) and paired (Study IV). Significance was defined as  $p < 0.05$ . The results are presented as mean values  $\pm$  standard error of the mean (SEM).

Different statistical methods were used in the various studies presented in this thesis. In two of the studies (II and IV) a parametric test was used for the comparison of two groups (Student's t-test) while in the other two (I and III) a non-parametric test was used for multiple observations (Kruskal-Wallis). It can be argued that all biological material is normally distributed, and that a parametric test is more suitable. However, it may be more correct that, in a study based on a small number of observations, use a nonparametric test. Furthermore, it can always be discussed whether correction for multiple comparisons shall be used. If one chooses to correct for multiple analyses, the correction could decrease the statistical power substantially. Furthermore, mean values and the SEM were used to describe the data in all studies. Strictly speaking, these measures should only be used to describe normally distributed data. It is however common in scientific literature that SEM is used to describe non-normally distributed material.<sup>195, 196</sup> Preferably, however, SD should be used instead of SEM to describe the variability in the outcome measurements within each group. For non-normally distributed data, the range or an appropriate choice of percentiles should be used as measures of the variability instead of SEM and SD.

The following precautions were taken to eliminate systemic errors. In Study I the order in which the experiments were performed with the respirator turned on and off were varied in a randomized manner. In the MRI studies (III and IV) the sequence of application of the three different negative pressures was varied using a 3 by 3 Latin square design. When analyzing the MR images, the images were coded and analyzed randomized and blinded.

## 4. Results and Discussion

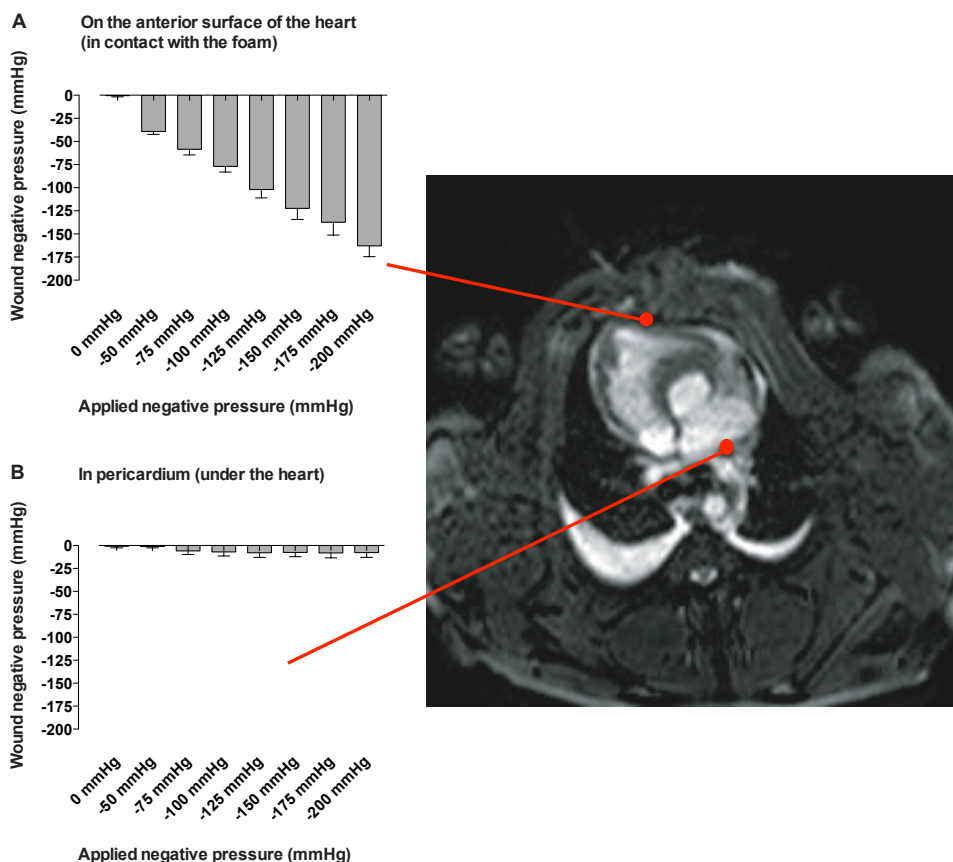
### 4.1. Pressure transduction to the thoracic cavity during NPWT of a sternotomy wound

The suction force created by NPWT is known to have local wound healing effects such as drainage of excessive fluid and debris,<sup>186, 187</sup> stimulation of angiogenesis,<sup>157, 197</sup> and granulation tissue formation,<sup>3</sup> but little is known about its effects on the intrathoracic organs. The present study was designed to investigate the extent to which negative pressure is transduced to the anterior portions of the heart and to deeper regions of the thoracic cavity (behind the heart, in the left pleura, and in the esophagus). A porcine sternotomy wound model was used and pressures between -50 and -200 mmHg were applied.

#### 4.1.1. Pressure transduction to the anterior portion of the heart and thoracic cavity

The pressure on the anterior surface of the heart changed linearly with the negative pressure applied (Figure 16). This shows that the subatmospheric pressure during NPWT is effectively propagated to the anterior portion of the heart. There was no significant change in pressure due to NPWT deeper in the thoracic cavity, in the pericardium (under the heart), in the left pleura or in the esophagus (Figure 16). Previous studies in pigs have shown that NPWT stimulates blood flow to the wound edge that is exposed to the negative pressure, while tissue further from the vacuum source remains unaffected.<sup>164, 165</sup> This is in accordance with the current findings that the pressure only affects the tissue in direct contact with the wound filler and is not transduced to deeper structures. As noticed empirically in the clinical setting of wounds other than sternotomy wounds, if fluid is to be drained from a deep wound pocket, the entire pocket must be in contact with the filler. For this reason, the wound filler must be carefully positioned so as to cover all areas of the wound. In sternotomy wounds, however, the patient moves around, and the fluid may therefore come into contact with the wound filler and be drained by NPWT.





**Figure 16.** Pressures measured using pressure transduction catheters over the anterior surface of the heart (A), where there is direct contact between the NPWT foam, and in the pericardium under the heart, where there is no direct contact between the foam and the tissue (B). The results are presented as mean values  $\pm$  SEM from seven experiments. Note how the pressure on the surface of the heart in contact with the foam changes linearly with the applied negative pressure, while the pressure lower down in the thoracic cavity was not affected.

#### 4.1.2. Effects of the pressure gradient between the anterior and posterior parts of the heart

The results of Study I show that the anterior part of the heart is subjected to negative pressure, but not the posterior part. The pressure difference between the anterior and posterior part of the heart may explain the finding that, upon the delivery of negative pressure, the anterior part of the right ventricle is drawn up towards the anterior thoracic wall.<sup>128</sup> The pressure causes the right ventricle to bulge into the space between the sternal edges, which deforms the anterior portion of the heart and may expose

the right ventricular free wall to the sharp edges of the sternal bone. This provides a plausible explanation of heart rupture, which is an uncommon but feared complication of NPWT in DSWI after cardiac surgery.<sup>117, 120, 121, 123, 125, 127</sup> Recent research has been focused on preventing such complications by inserting a rigid disc between the heart and the sternum.<sup>128, 198</sup>

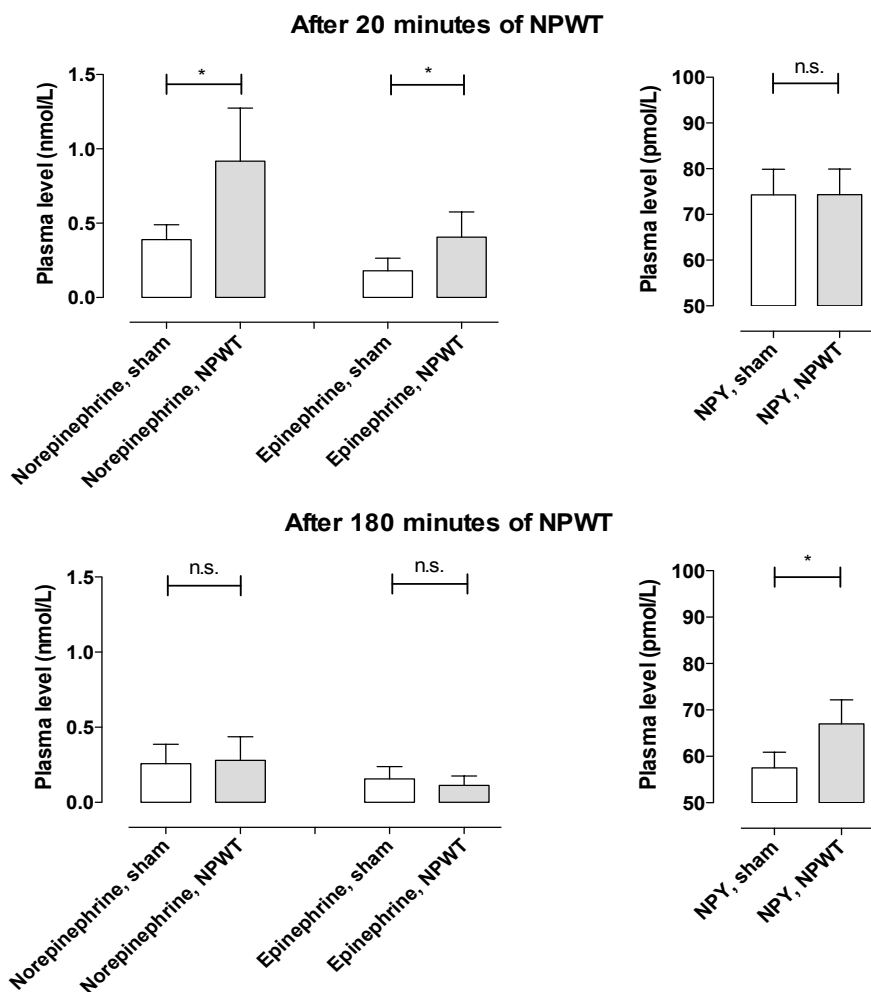
## 4.2. Sympathetic and sensory nerve activation during NPWT of sternotomy wounds

The aim of Study II was to investigate whether NPWT causes a change in the plasma levels of certain neurohormones and neuropeptides known to affect the heart<sup>143, 144</sup> and known to be released in response to painful stimulation.<sup>140, 199</sup> The plasma levels of norepinephrine, epinephrine, NPY, SP, VIP, and CGRP were measured before (0 minutes) and after 5, 20, 60, and 180 minutes in NPWT and sham-treated pigs.

### 4.2.1. Plasma levels of catecholamines and NPY

The levels of norepinephrine and epinephrine were found to be higher in NPWT treated than in sham-treated pigs after 20 min of negative pressure therapy at -125 mmHg (Figure 17). These are sympathetic nervous system transmitters and hormones known to trigger the fight-or-flight response, constricting blood vessels and increasing heart rate (causing an increase in blood pressure).<sup>177</sup> It has been shown that NPWT alters the intrathoracic anatomy as the thoracic cage is closed and the heart and lungs are drawn up towards to the sternotomy wound opening.<sup>128</sup> The catecholamine elevation was transient, and the levels of norepinephrine and epinephrine were similar to baseline values after 60 and 180 min, respectively. The reason why the elevation of norepinephrine and epinephrine levels is transient may be acclimatization of the body to the effects of NPWT with time.

NPY is a co-transmitter of sympathetic nerves and is released at high rates of nerve firing.<sup>143</sup> In the present study, the plasma levels of NPY were similar after 20 minutes of NPWT in both groups, but were significantly elevated after 180 minutes in the NPWT group (Figure 17), probably as a late effect of the initially increased norepinephrine and epinephrine levels in this group. This is in accordance with the general belief that NPY is responsible for the long-term effects of sympathetic nerve activity.<sup>143</sup> A steady decline in NPY levels was seen in the sham-treated pigs. NPY levels are presumably high during surgery as a result of the trauma, and when surgery is completed, the NPY levels decrease.



**Figure 17.** The plasma levels of norepinephrine, epinephrine, and NPY in pigs subjected to negative pressure wound therapy at -125 mmHg (NPWT) and sham-treated pigs (Sham). The results are presented as mean values  $\pm$  SEM from six experiments. Statistical analysis was performed using Student's t-test. Significance was defined as  $p < 0.05$  (\*). Note how the levels of norepinephrine and epinephrine are increased after 20 minutes of NPWT and then decline. NPY, on the other hand, shows the same levels in the NPWT and sham-treated pigs after 20 minutes, but after 180 minutes of NPWT NPY is slightly elevated.

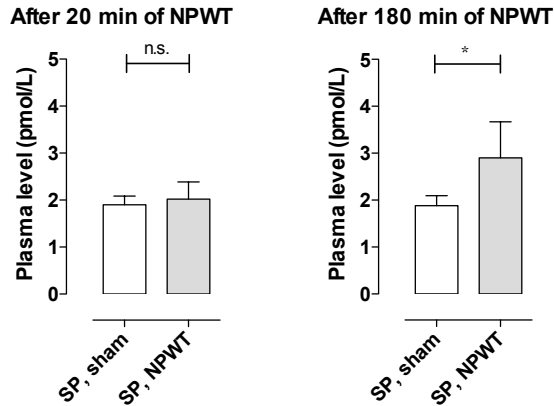
#### 4.2.2. Mechanisms underlying the increased plasma levels of catecholamines and NPY

Initial increases in the plasma levels of norepinephrine and epinephrine were seen in the present study, followed by elevated levels of NPY. These increases may reflect increased sympathetic nerve activity.<sup>200, 201</sup> The reason for the increase in catecholamines and NPY cannot be deduced from the studies presented in this thesis or from the literature. It has been shown that NPWT alters the intrathoracic anatomy as the thoracic cage is closed, and that the heart and lungs are drawn up towards to the sternotomy wound opening.<sup>128</sup> This mechanical alteration of the intrathoracic organs is most probably responsible for the increase in catecholamines and NPY during NPWT.

It has also been shown in a study by Petzina et al.,<sup>142</sup> using the same sternotomized pigs as in Study III, that when NPWT is applied there is a trend towards an increase in heart rate and a significant decrease in stroke volume, resulting in a decrease in cardiac output. The increase in heart rate is consistent with the current findings of increase in catecholamines and NPY when NPWT is applied. In Study III it was found that cardiac output is increased after sternotomy and it is therefore suggested that the decrease in stroke volume may be due to restoration of the intrathoracic anatomical conditions by NPWT, thereby relieving the mechanical deformation of the heart caused by sternotomy. One limitation of this study is, however, that the hormone levels were not measured before sternotomy. Such measurements may have clarified the effect of sternotomy, which was found to increase cardiac output (Study III), and sternotomy closure by NPWT, which was found to normalize cardiac output (Study III), and the change in levels of catecholamines and NPY found in Study II.

#### 4.2.3. Plasma levels of SP, VIP and CGRP

SP is released from primary afferent sensory nerves upon stimulation.<sup>183</sup> After 180 minutes of NPWT the plasma levels of SP were significantly increased (Figure 18). This may be due to sensory nerve stimulation by the negative pressure on the wound edge. It is well known that NPWT causes mechanical deformation of the tissue at the wound edge and shearing forces at the foam–wound interface.<sup>202</sup> This is presumably the reason why some patients experience pain during NPWT. No such difference was observed for CGRP or VIP.



**Figure 18.** The plasma levels of SP in pigs treated with negative pressure wound therapy at -125 mmHg (NPWT) and sham-treated pigs (Sham). The results are presented as mean values  $\pm$  SEM from six experiments. Statistical analysis was performed using Student's t-test. Significance was defined as  $p < 0.05$  (\*). Note how SP increases after 180 minutes of NPWT treatment.

#### 4.3. Changes in cardiac pumping efficiency and intrathoracic organ volume during NPWT of sternotomy wounds

It has been reported that NPWT causes a decrease in cardiac output.<sup>141, 142</sup> This is an important finding because many patients undergoing cardiac surgery suffer from heart failure. However, the effect of NPWT on cardiac output has hitherto only been studied in sternotomized pigs and no comparison has been made with non-sternotomized pigs (intact chest). Study III was performed to investigate the effects of NPWT on the volume of the intrathoracic organs and heart function, using MRI. A porcine sternotomy wound model was used and the results compared with those from non-sternotomized pigs. The vacuum source was set to deliver a continuous negative pressure of -75, -125 or -175 mmHg.

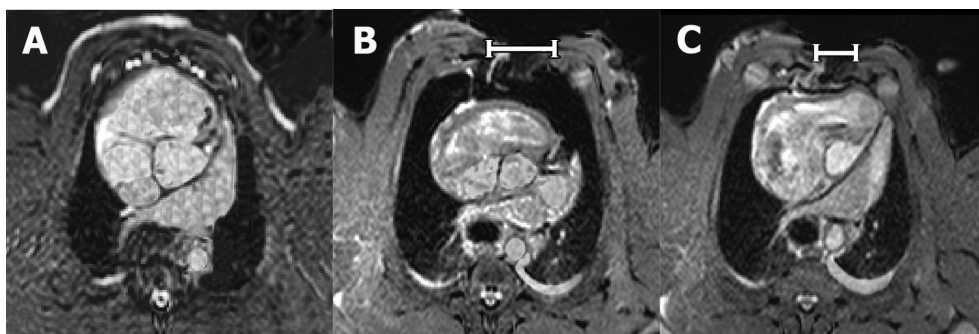
##### 4.3.1. Intrathoracic organ volume

As could be expected, the volume of the thoracic cavity and the intrathoracic organs was greater in the sternotomized pigs than in the non-sternotomized pigs. The lung volume showed a tendency to be larger in the sternotomized pigs, although these results did not reach statistical significance ( $p = 0.152$  for the right lung and  $p = 0.281$  for the left lung). This could be the result of changes in the quantity of blood that collects in

these organs due to the change in the pressure conditions. Another explanation of the tendency towards increased lung volume may be that sternotomy results in increased end expiratory volumes of air in the lungs.

Upon the application of NPWT, the volume of the thoracic cavity and intrathoracic organs was reduced. NPWT contracts the wound and draws the two sternal edges together, thereby decreasing the circumference of the thorax (Figure 19). Previous studies have reported similar findings regarding soft tissue wound contraction and macrodeformation upon NPWT.<sup>202</sup> The lung volume appeared to decrease when NPWT was applied ( $p=0.085$  for the right lung and  $p=0.052$  for the left lung, compared with 0 mmHg). During NPWT, air is evacuated from the thorax, decreasing the total intrathoracic volume. NPWT thus largely restores the macroscopic anatomical conditions in the thorax, which may explain the clinical benefits of NPWT over open-chest care, including the stabilizing effects and the reduced need for mechanical ventilation.<sup>136, 137</sup>

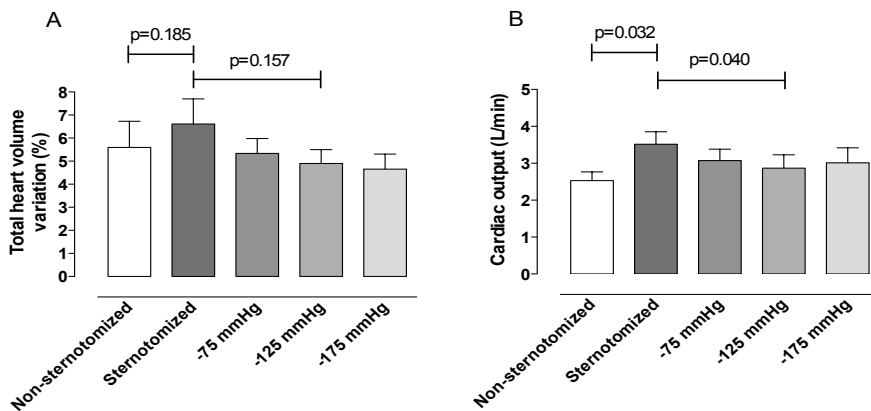
The volume of the intrathoracic organs decreased upon the application of NPWT, but did not return to pre-sternotomy levels. This may be explained by the fact that the NPWT foam separates the sternal edges, resulting in a larger thoracic cavity during NPWT than before sternotomy. Also, open-heart surgery may have resulted in interstitial edema, causing the organs to be slightly enlarged.



**Figure 19.** Representative transverse MR images at the level of the aortic root. The images were obtained from a non-sternotomized pig (A) and a sternotomized pig before (0 mmHg) (B) and after the application of -125 mmHg (C). Note the differences in the size, shape and position of the intrathoracic organs induced by sternotomy and NPWT. In particular, note how NPWT draws the two sternal edges closer to each other (white bars), thereby decreasing the circumference of the thorax, making it similar to that of the non-sternotomized pig.

#### 4.3.2. Effects on central hemodynamics

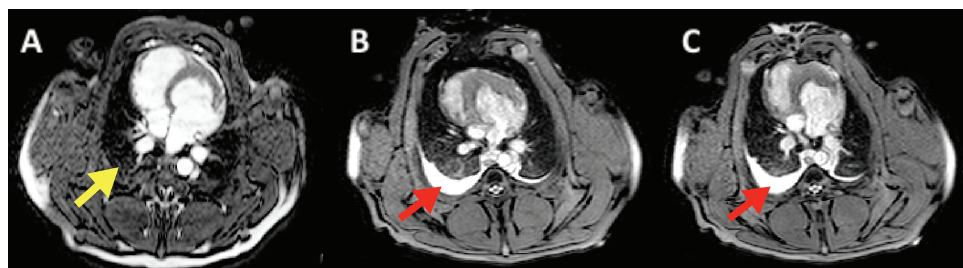The variation in total heart volume, which is inversely related to cardiac pumping efficiency,<sup>189</sup> showed a tendency towards being increased after sternotomy ( $p=0.185$ ) (Figure 20). Upon the application of NPWT, the THVV trended to decrease to values similar to those in the non-sternotomized pigs ( $p=0.157$  when comparing 0 mmHg with -125 mmHg) (Figure 20). A retrospective analysis of two previous studies suggests similar changes in cardiac output.<sup>142, 194</sup> Cardiac output was significantly higher after sternotomy and then returned to pre-sternotomy levels during NPWT. These findings are in accordance with previous reports where cardiac output has been shown to increase upon sternotomy.<sup>203</sup> It is speculated here that the opening of the thorax and pericardium may mechanically impede cardiac pumping, and that the resulting increase in cardiac output represents overcompensation for this effect, but the exact mechanism is unclear. Other reports show a decrease in cardiac output when the sternotomy wound is resealed during NPWT.<sup>133, 134</sup> Many surgeons have been concerned over the finding that cardiac output decreases during NPWT, and invasive monitoring of hemodynamics has been suggested. However, the results of the present study are reassuring as they indicate that cardiac pumping efficiency nearly returns to pre-sternotomy levels during NPWT.



**Figure 20.** The total heart volume variation (A) and the cardiac output (B) in non-sternotomized pigs ( $n=6$ ) and sternotomized pigs ( $n=6$ ) before and after the application of NPWT at -75, -125 and -175 mmHg. The results are presented as mean values  $\pm$  SEM. Statistical analysis was performed using Kruskal-Wallis test with Dunn's post-test for multiple comparisons. Significance was defined as  $p<0.05$ . Note that after sternotomy, the cardiac pumping efficiency appears to decrease (i.e. an increase in total heart volume variation), and cardiac output increases, but that these return to baseline levels upon the application of NPWT.

#### 4.3.3. Wound fluid removal

Following sternotomy, wound fluid accumulates in the bottom of the thoracic cavity, in the right and left pleura. The application of negative pressure did not decrease the amount of free fluid at the bottom of the thoracic cavity (Figure 21). In Study I it was found that the negative pressure was not transduced to the bottom of the thoracic cavity, which may explain why the wound fluid was not evacuated. However, in the clinical situation the patient is mobilized. The wound fluid may then move around in the thoracic cavity and come into contact with the foam and negative pressure and thus be withdrawn. However, drainage of the wound fluid from the thoracic cavity may not be crucial in resolving DSWI. We believe that one of the most important issues in DSWI is the infection in the sternum. The results from Study I underline the importance of the NPWT wound filler being in direct contact with the sternal bone edge to resolve the bone infection in DSWI. We have previously shown that NPWT affects the fluid in the sternum.<sup>204</sup> Presumably, fluid is drawn from the surrounding tissue towards the sternum and into the vacuum source. This “endogenous drainage” may be one possible mechanism by which osteitis is resolved by NPWT in DSWI after cardiac surgery.



**Figure 21.** Transverse MR images at the cardiac midventricular level showing the lack of fluid (yellow arrow) in a non-sternotomized pig (A) and the wound fluid (red arrows) in the deeper parts of the thoracic cavity in a sternotomized pig before (0 mmHg) (B) and after the application of -125 mmHg (C). It can be seen that wound fluid is accumulated in the right and left pleura as a result of surgery, and that NPWT does not result in the evacuation of fluid from the bottom of the thoracic cavity.

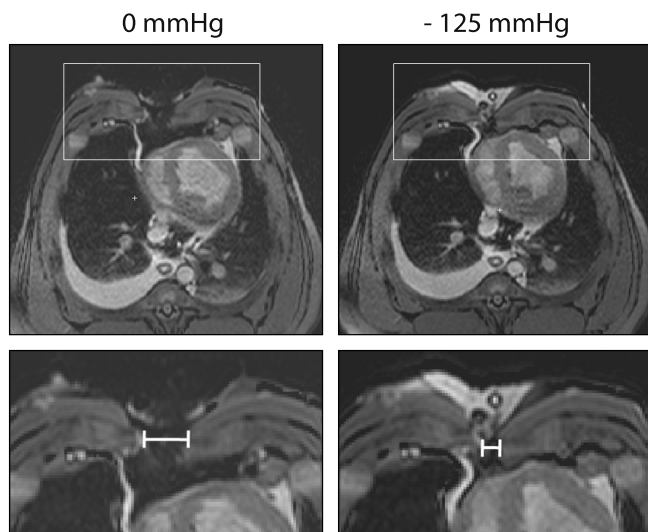


#### 4.4. Wound contraction and macrodeformation during NPWT of sternotomy wounds

It is believed that one of the major driving forces promoting healing during NPWT is the drawing together of the wound edges.<sup>146</sup> The present study was performed to investigate in detail the effects of NPWT at different negative pressures (0, -75, -125 and -175 mmHg) on wound contraction and wound edge tissue deformation in a porcine sternotomy wound model, using MRI. The effects were measured in subcutaneous tissue, muscle and the sternum.

##### 4.4.1. Temporary closure of the thorax by NPWT

The thorax contains vital structures such as the heart and lungs, and the establishment of a stable thorax is thus important during the treatment of sternotomy wounds. The present study shows that NPWT contracts the wound and draws the two sternal edges together, thereby resealing the thoracic cavity and restoring the macroscopic anatomical conditions in the thorax (Figure 22). This may explain the clinical benefits of NPWT over open-chest care, including the reduced need for mechanical ventilation.<sup>136, 137</sup> This is in concordance with one of our previous studies, showing that the sternum is stabilized and can withstand external forces during NPWT.<sup>138</sup> Stabilization of the sternum enables early mobilization, which is crucial for the clinical outcome.<sup>106, 139</sup>



**Figure 22.** Transverse MR images at the cardiac midventricular level showing wound contraction upon the application of NPWT. The lower panels show enlargements of the insets in the upper panels, illustrating the width of the wound, showing how the negative pressure pulls the sternotomy wound edges closer together.

#### 4.4.2. Macrodeformation of the wound edges by NPWT

The negative pressure draws the subcutaneous tissue wound edges together to a greater extent than the wound edges of the sternum, suggesting macrodeformation of the wound edge tissue. This presumably creates shearing forces in the tissue and at the wound–foam interface. This is believed to be one of the fundamental mechanisms by which NPWT results in wound healing.<sup>146</sup> Contraction of the wound and macrodeformation of the wound edge tissue upon NPWT causes mechanical stress in the tissue. Mechanical stress is known to promote the expression of growth factors (e.g., vascular endothelial growth factor and fibroblast growth factor-2) and to stimulate granulation tissue formation and angiogenesis.<sup>147-149</sup>

#### 4.4.3. Different levels of negative pressure

The greatest decrease in lateral wound width in the different tissues was seen when switching from 0 mmHg to -75 mmHg; the level of negative pressure did not play a significant role in the degree of wound contraction. Similar findings have also been reported in a study by Isago et al.,<sup>205</sup> carried out in peripheral rat wounds using polyurethane foam, where negative pressures of -50, -75 and -125 mmHg caused similar reductions in wound area. Furthermore, in a pig sternotomy wound model,<sup>138</sup> the wound contraction upon the application of NPWT was found to be similar in wounds treated with low (-50 to -100 mmHg) and high (-150 to -200 mmHg) negative pressures. Thus, both low and high levels of negative pressure will induce macro-mechanical deformation during NPWT.



## 5. Main Conclusions

### *Pressure transduction to the sternotomy wound and the thoracic cavity*

The way in which the negative pressure is distributed over the sternotomy wound and deeper parts of the thoracic cavity during NPWT is currently the subject of debate. In Study I it was shown that the pressure is only transmitted to the superficial wound and the anterior portion of the heart, and does not reach the deeper parts of the thoracic cavity. Negative pressure can therefore only be anticipated to be effective in superficial parts of the wound, e.g. the sternotomy wound edges and the anterior surface of the heart, which are in direct contact with the foam, and not in the lower regions of the thoracic cavity. The pressure difference between the anterior and posterior parts of the heart during NPWT causes the right ventricle to be drawn up towards the sternum where it might be exposed to the sharp edges of the sternal bone, which in turn may result in injury to the heart.

### *Effects on neurohormones and neuropeptides*

Study II was performed to determine the effects of NPWT of sternotomy wounds on neurohormones and neuropeptides. The results showed elevated plasma levels of norepinephrine and epinephrine upon NPWT application, followed by an increase in NPY. These increases in catecholamines and NPY may reflect increased sympathetic nerve activity. The mechanism behind the increase in sympathetic nerve activity cannot be deduced from this study. However, the increase in stress hormones probably reflects the changes in the intrathoracic anatomical conditions when the wound is closed by NPWT. The increase in catecholamine levels is only transient, suggesting that the body acclimatizes to negative pressure therapy. The results also show increased SP levels during NPWT, which may reflect increased sensory nerve activation. This may be a result of the mechanical deformation of the wound edge tissue and shearing forces at the foam–wound interface during NPWT.

### *Effects on central hemodynamics and intrathoracic organ volumes*

Reduced cardiac output has been described during NPWT in cardiac surgery and the effects of NPWT on the intrathoracic organs are currently the subject of debate. In Study III it was demonstrated that NPWT closes and largely restores the thoracic cavity. This may contribute to the clinical benefits of NPWT over open-chest care, including the stabilizing effects and the reduced need for mechanical ventilation.

NPWT does not result in the evacuation of wound fluid from the bottom of the wound, presumably because the negative pressure is not transmitted to the deeper parts of the thoracic cavity. However, in the clinical situation the patient is mobilized. The wound fluid may then move around in the thoracic cavity and come into contact with the foam and negative pressure and thus be withdrawn. The negative pressure is transmitted to the sternal bone edge via the foam, which may be crucial in resolving the bone infection in DSWI.

The variation in total heart volume, which is inversely related to heart pumping efficiency, appeared to increase after sternotomy. Upon the application of NPWT, the variation in total heart volume decreased to values similar to those in non-sternotomized pigs. Many surgeons have been concerned about previous findings that cardiac output decreases during NPWT, and invasive monitoring of hemodynamics has been proposed. However, the results of the present study are reassuring, indicating that cardiac pumping efficiency returns to pre-sternotomy levels during NPWT.

#### *Effects on wound contraction and macrodeformation*

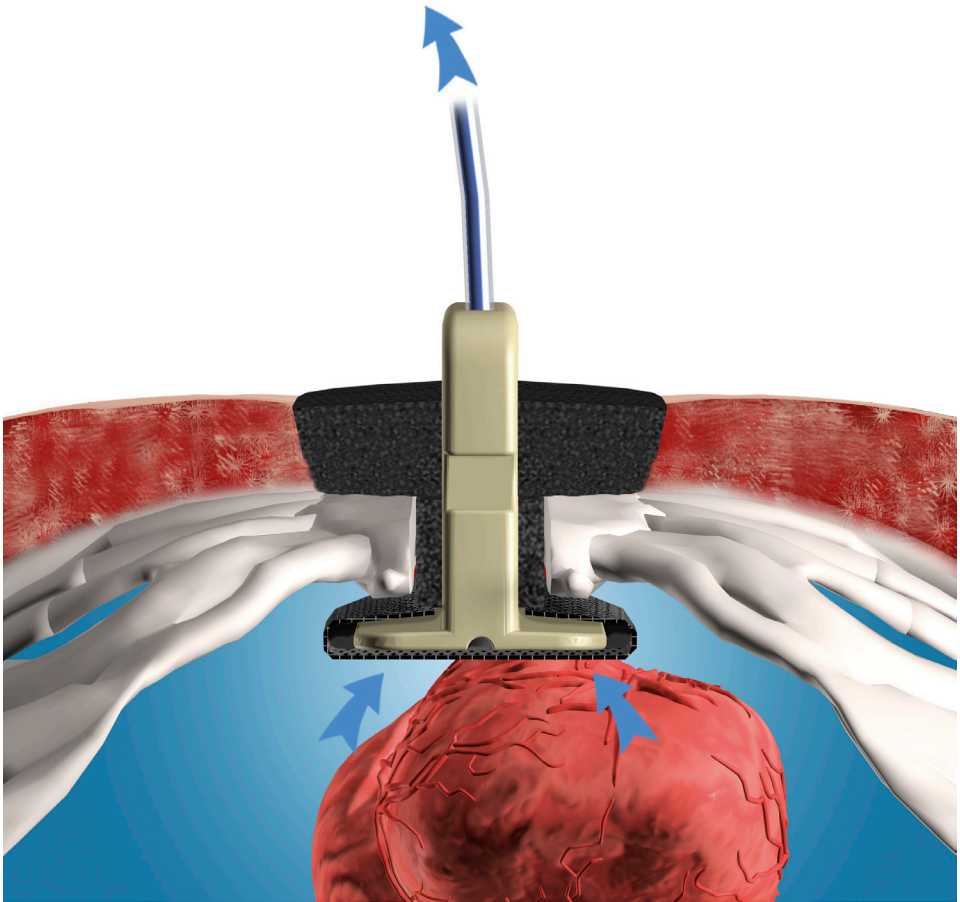
Study IV demonstrated that NPWT contracts the wound and draws the two sternal edges together, thereby resealing the thoracic cavity and restoring the macroscopic anatomical conditions in the thorax. As NPWT contracts the sternotomy wound it causes macrodeformation of the wound edge tissue. This mechanical stress in the tissue and at the wound–foam interface creates shearing forces that are known to promote granulation tissue formation and facilitate healing.

## 6. Current and Future Research

Negative pressure wound therapy has been widely adopted as a result of favorable clinical experience and excellent healing effects. However, a number of reports show that serious complications can result from the use of NPWT for the treatment of DSWI, of which heart rupture leading to death is the most devastating. The international scientific community has thus recognized the importance of protecting the heart and other exposed organs.<sup>42, 106, 117-127, 206, 207</sup>

Research carried out by our group has shown that damage to the heart and lungs during NPWT can be prevented by inserting a rigid device (HeartShield®) between the sternal edges and the heart (Figure 23).<sup>128, 198, 208</sup> Seven patients have been treated successfully so far, and the results show less damage to the heart, lungs and cardiovascular structures during NPWT.<sup>128, 198, 208</sup> The results also show improved healing of the DSWI in the patients treated with the device, as demonstrated by the more rapid decrease in C-reactive protein and leukocyte levels,<sup>209</sup> and faster recovery.<sup>210</sup> This is probably the result of the more efficacious drainage from the sternotomy wound in the presence of the device.<sup>211</sup>

We aim to contribute to the future development of NPWT to make it as safe and efficacious for the patient. We believe it is important that the knowledge gained from the research on NPWT in sternotomy wounds be adapted to other wounds with underlying vital organs, such as abdominal wounds or wounds in which blood vessels are exposed.



**Figure 23.** Cross section of the thoracic cavity with an open sternotomy wound with NPWT using HeartShield®. The rigid barrier device protects the heart from damage. Arrows indicate the evacuation of fluid from the wound cavity by the negative pressure.

## 7. Acknowledgements

I wish to express my sincere appreciation to all those who, in one way or another, have contributed to this thesis, especially the following people:

*Professor Malin Malmström*, my supervisor and dear friend. I admire your working capacity and your incredible ability to get things done, while at the same time enjoying your work. I am grateful for your generosity and for always making me feel welcome to your home and your family. You are a real source of inspiration and I want to thank you for your enthusiasm, encouragement and scientific guidance.

I would also like to express my gratitude to my co-supervisor, *Dr. Martin Ugander*, who has always had time for me, regardless of where he was in the world. Our chats over Skype have been truly valuable. Thanks for your friendly advice, constructive criticism and for your expertise in clinical physiology, statistics and MRI. You have shown me that nothing is impossible in the world of science.

Thank you also to my other co-supervisor, *Associate Professor Richard Ingemansson*, for performing the surgical procedures, sharing his cardiothoracic knowledge and expertise, as well as providing the clinical perspective throughout my research.

My co-authors *Dr. Lotta Gustafsson*, *Dr. Per Paulsson*, *Dr. Angelica Wackenfors*, *Associate Professor Sandra Lindstedt-Ingemansson*, *Professor Rolf Ekman*, *Dr. Henrik Engblom*, *Dr. Göran Olivecrona*, *Dr. Olof Gålne*, and *Professor Håkan Arheden*, who have all contributed to this thesis.

*Dr. Ola Borgquist*, for being a good friend and valuable research colleague. Your bizarre sense of humor and sharp comments are always appreciated. I also love your baking and your wonderful family.

*Dr. Erik Anesäter*, also a friend and research colleague. Thanks for the amusing times in the *in vivo* lab and for sharing your knowledge about how to buy expensive watches on eBay without getting scammed.

*Associate Professor Jonas Björk*, at the Department of Medical Statistics and Epidemiology at R&D Centre Skåne (*FoU-centrum Skåne*) for his contribution to the statistical analysis.

*Helen Sheppard*, Word for Word in Lund, for her linguistic advice.

*Professor Per-Anders Abrahamsson*, Head of the Department of Urology at Skåne University Hospital, for his encouragement and understanding of the importance of research.



*Dr. Annika Malmquist*, Head of the Department of Surgery and Urology at Ystad Hospital, for her kind support and for giving me leave of absence from the clinic.

*Dr. Britten Klöfver-Ståhl*, my mentor since childhood. Thanks for letting me come with you to the operating room as a teenager, and later teaching me how to perform surgery. You are a true inspiration and have played an important part in my choice of profession.

*Dr. Thomas Jiborn*, my supervisor in urology and *Dr. Ulrika Olsson Rosén*, my supervisor in surgery, for their professional guidance in the clinical work and for sharing their experience and knowledge with me.

Colleagues at the Urology Department in Malmö and Surgical Department in Ystad for their friendship, for creating a positive working environment and for making work rewarding.

My family and relatives for their support, love and patience, especially:

My grandfather *Gunnar*, for being the best grandpa. You are showing all of us how to age with dignity. My parents *Erik* and *Gunilla*, for being excellent parents and for always believing in me. My sister *Ulrika*, for being such a cool sister, chasing crooks in Sweden, Kosovo and Afghanistan.

All my friends for their encouragement and for giving me other dimensions in life. A special thanks to:

*Bengt*, for always encouraging and helping me to achieve my goals and dreams. *Olof*, for being a great friend, providing endless support in good times and bad. *Martin* for being a loyal friend, always agreeing to my crazy escapades, and for keeping me up to date about the academic world. *Jenny*, for being full of energy, always putting a smile on my face. *Markus*, for being the coolest “wigga” in Eksjö. Keep it real! *Josef* and *Henke*, for being the best “wingmen” ever. *Saeed*, for never tiring of discussing work-related matters. *Annie* and *Katrin*, for being “better halves” of Olof and Martin. Thanks to my friends from back home *Fredrik*, *Jocke*, *Johan* and *Josef*, for all the crazy times and adventures we had together.

My fiancée’s parents *Lotta* and *Ingemar*, for being supportive, helping us to handle daily life, and for making me realize that there are other things in life than research and work.

Finally, my wonderful fiancée *Cissi* for her unconditional love, endless support, for proof-reading my manuscripts, for all the joy she gives me and for giving me the greatest gift a man could wish for. My life wouldn’t be the same without you.

### *Financial support*

The research presented in this thesis was supported by grants from:

the Anders Otto Swärd Foundation/Ulrika Eklund Foundation, the Anna Lisa and Sven Eric Lundgren's Foundation for Medical Research, the Åke Wiberg Foundation, the Magnus Bergvall Foundation, the Swedish Medical Association, the Royal Physiographic Society in Lund, the Swedish Medical Research Council, the Crafoord Foundation, the Swedish Heart-Lung Foundation, the Swedish Government Grant for Clinical Research, the Swedish Hypertension Society, Lund University Faculty of Medicine, Lund University Hospital Research Grants, the Jeansson Foundation, the Swedish Heart-Lung Foundation, Anna and Edwin Berger's Foundation, the Märta Lundqvist Foundation, and the Lars Hierta Memorial Foundation.



## 8. References

1. Meyer W, Schmieden V, Bier AKG. *Bier's hyperemic treatment in surgery*. Philadelphia and London,: W. B. Saunders company; 1908.
2. Fleischmann W, Strecker W, Bombelli M, Kinzl L. [vacuum sealing as treatment of soft tissue damage in open fractures]. *Unfallchirurg*. 1993;96:488-492
3. Morykwas MJ, Argenta LC, Shelton-Brown EI, McGuirt W. Vacuum-assisted closure: A new method for wound control and treatment: Animal studies and basic foundation. *Ann Plast Surg*. 1997;38:553-562
4. Kaplan M, Daly D, Stemkowski S. Early intervention of negative pressure wound therapy using vacuum-assisted closure in trauma patients: Impact on hospital length of stay and cost. *Adv Skin Wound Care*. 2009;22:128-132
5. Bollero D, Carnino R, Risso D, Gangemi EN, Stella M. Acute complex traumas of the lower limbs: A modern reconstructive approach with negative pressure therapy. *Wound Repair Regen*. 2007;15:589-594
6. Baharestani MM, Gabriel A. Use of negative pressure wound therapy in the management of infected abdominal wounds containing mesh: An analysis of outcomes. *Int Wound J*. 2011;8:118-125
7. Ross RE, Aflaki P, Gendics C, Lantis Ii JC. Complex lower extremity wounds treated with skin grafts and NPWT: A retrospective review. *J Wound Care*. 2011;20:490, 492-495
8. Sjogren J, Gustafsson R, Nilsson J, Malmsjo M, Ingemansson R. Clinical outcome after poststernotomy mediastinitis: Vacuum-assisted closure versus conventional treatment. *Ann Thorac Surg*. 2005;79:2049-2055
9. Scherer LA, Shiver S, Chang M, Meredith JW, Owings JT. The vacuum assisted closure device: A method of securing skin grafts and improving graft survival. *Arch Surg*. 2002;137:930-933; Discussion 933-934
10. Gutierrez IM, Gollin G. Negative pressure wound therapy for children with an open abdomen. *Langenbecks Arch Surg*. 2012
11. Czymek R, Schmidt A, Eckmann C, Bouchard R, Wulff B, Laubert T, Limmer S, Bruch HP, Kujath P. Fournier's gangrene: Vacuum-assisted closure versus conventional dressings. *Am J Surg*. 2009;197:168-176
12. Altman AD, Nelson G, Nation J, Chu P, Ghatage P. Vacuum assisted wound closures in gynaecologic surgery. *J Obstet Gynaecol Can*. 2011;33:1031-1037

13. Stannard JP, Robinson JT, Anderson ER, McGwin G, Jr., Volgas DA, Alonso JE. Negative pressure wound therapy to treat hematomas and surgical incisions following high-energy trauma. *J Trauma*. 2006;60:1301-1306
14. Eisenhardt SU, Schmidt Y, Thiele JR, Iblher N, Penna V, Torio-Padron N, Stark GB, Bannasch H. Negative pressure wound therapy reduces the ischaemia/reperfusion-associated inflammatory response in free muscle flaps. *J Plast Reconstr Aesthet Surg*. 2012;65:640-649
15. Joseph E, Hamori C, Bergman S, Roaf E, Swann N. A new prospective randomized trial of vacuum assisted closure versus standard therapy of chronic nonhealing wounds. *Wounds* 2000;12:60-67
16. Vuerstaek JD, Vainas T, Wuite J, Nelemans P, Neumann MH, Veraart JC. State-of-the-art treatment of chronic leg ulcers: A randomized controlled trial comparing vacuum-assisted closure (V.A.C.) with modern wound dressings. *J Vasc Surg*. 2006;44:1029-1037; discussion 1038
17. Armstrong DG, Lavery LA. Negative pressure wound therapy after partial diabetic foot amputation: A multicentre, randomised controlled trial. *Lancet*. 2005;366:1704-1710
18. Kamolz LP, Andel H, Haslik W, Winter W, Meissl G, Frey M. Use of subatmospheric pressure therapy to prevent burn wound progression in human: First experiences. *Burns*. 2004;30:253-258
19. Wild T, Stortecky S, Stremitzer S, Lechner P, Humpel G, Glaser K, Fortelny R, Karner J, Sautner T. [abdominal dressing -- a new standard in therapy of the open abdomen following secondary peritonitis?]. *Zentralbl Chir*. 2006;131 Suppl 1:S111-114
20. Ozturk E, Ozguc H, Yilmazlar T. The use of vacuum assisted closure therapy in the management of Fournier's gangrene. *Am J Surg*. 2009;197:660-665; discussion 665
21. Borgquist O, Ingemansson R, Malmsjo M. Individualizing the use of negative pressure wound therapy for optimal wound healing: A focused review of the literature. *Ostomy Wound Manage*. 2011;57:44-54
22. Chikwe J, Beddow E, Glenville B. *Cardiothoracic surgery*. Oxford ; New York: Oxford University Press; 2006.
23. Milton H. Mediastinal surgery. *Lancet*. 1897:872-875
24. Julian OC, Lopez-Belio M, Dye WS, Javid H, Grove WJ. The median sternal incision in intracardiac surgery with extracorporeal circulation; a general evaluation of its use in heart surgery. *Surgery*. 1957;42:753-761
25. Dalton ML, Connally SR, Sealy WC. Julian's reintroduction of Milton's operation. *Ann Thorac Surg*. 1992;53:532-533
26. Góngora E TS. *Myocardial revascularization with cardiopulmonary bypass*. McGraw-Hill Education; 2008.

27. Bek EL, Yun KL, Kochamba GS, Pfeffer TA. Effective median sternotomy closure in high-risk open heart patients. *Ann Thorac Surg.* 2010;89:1317-1318
28. Petzina R. Negative pressure wound therapy in cardiac surgery. *Faculty of Medicine, Lund University, Thesis, Doctoral Dissertation Series 2009:22.* 2009
29. Antunes PE, de Oliveira JF, Antunes MJ. Risk-prediction for postoperative major morbidity in coronary surgery. *Eur J Cardiothorac Surg.* 2009;35:760-766; discussion 766-767
30. Raudat CW, Pagel J, Woodhall D, Wojtanowski M, Van Bergen R. Early intervention and aggressive management of infected median sternotomy incision: A review of 2242 open-heart procedures. *Am Surg.* 1997;63:238-241; discussion 241-232
31. Ridderstolpe L, Gill H, Granfeldt H, Ahlfeldt H, Rutberg H. Superficial and deep sternal wound complications: Incidence, risk factors and mortality. *Eur J Cardiothorac Surg.* 2001;20:1168-1175
32. Lu JC, Grayson AD, Jha P, Srinivasan AK, Fabri BM. Risk factors for sternal wound infection and mid-term survival following coronary artery bypass surgery. *Eur J Cardiothorac Surg.* 2003;23:943-949
33. Stahle E, Tammelin A, Bergstrom R, Hambreus A, Nystrom SO, Hansson HE. Sternal wound complications--incidence, microbiology and risk factors. *Eur J Cardiothorac Surg.* 1997;11:1146-1153
34. Crabtree TD, Codd JE, Fraser VJ, Bailey MS, Olsen MA, Damiano RJ, Jr. Multivariate analysis of risk factors for deep and superficial sternal infection after coronary artery bypass grafting at a tertiary care medical center. *Semin Thorac Cardiovasc Surg.* 2004;16:53-61
35. Farinas MC, Gald Peralta F, Bernal JM, Rabasa JM, Revuelta JM, Gonzalez-Macias J. Suppurative mediastinitis after open-heart surgery: A case-control study covering a seven-year period in Santander, Spain. *Clin Infect Dis.* 1995;20:272-279
36. Milano CA, Kesler K, Archibald N, Sexton DJ, Jones RH. Mediastinitis after coronary artery bypass graft surgery. Risk factors and long-term survival. *Circulation.* 1995;92:2245-2251
37. Doss M, Martens S, Wood JP, Wolff JD, Baier C, Moritz A. Vacuum-assisted suction drainage versus conventional treatment in the management of poststernotomy osteomyelitis. *Eur J Cardiothorac Surg.* 2002;22:934-938
38. Mokhtari A, Sjogren J, Nilsson J, Gustafsson R, Malmso M, Ingemansson R. The cost of vacuum-assisted closure therapy in treatment of deep sternal wound infection. *Scand Cardiovasc J.* 2008;42:85-89
39. Ghotaslou R, Yagoubi AR, Khalili AA, Mahmodian R. Mediastinitis after cardiac surgery in Madani Heart Center, Tabriz, Iran. *Jpn J Infect Dis.* 2008;61:318-320

40. Gardlund B, Bitkover CY, Vaage J. Postoperative mediastinitis in cardiac surgery - microbiology and pathogenesis. *Eur J Cardiothorac Surg.* 2002;21:825-830
41. Tegnell A, Aren C, Ohman L. Coagulase-negative staphylococci and sternal infections after cardiac operation. *Ann Thorac Surg.* 2000;69:1104-1109
42. Sjogren J, Malmso M, Gustafsson R, Ingemansson R. Poststernotomy mediastinitis: A review of conventional surgical treatments, vacuum-assisted closure therapy and presentation of the Lund University Hospital mediastinitis algorithm. *Eur J Cardiothorac Surg.* 2006;30:898-905
43. Kohman LJ, Coleman MJ, Parker FB, Jr. Bacteremia and sternal infection after coronary artery bypass grafting. *Ann Thorac Surg.* 1990;49:454-457
44. Osada H, Nakajima H, Morishima M, Su T. Candidal mediastinitis successfully treated using vacuum-assisted closure following open-heart surgery. *Interact Cardiovasc Thorac Surg.* 2012;14:872-874
45. Culliford AT, Cunningham JN, Jr., Zeff RH, Isom OW, Teiko P, Spencer FC. Sternal and costochondral infections following open-heart surgery. A review of 2,594 cases. *J Thorac Cardiovasc Surg.* 1976;72:714-726
46. Grossi EA, Culliford AT, Krieger KH, Kloth D, Press R, Baumann FG, Spencer FC. A survey of 77 major infectious complications of median sternotomy: A review of 7,949 consecutive operative procedures. *Ann Thorac Surg.* 1985;40:214-223
47. Stoney WS, Alford WC, Jr., Burrus GR, Frist RA, Thomas CS, Jr. Median sternotomy dehiscence. *Ann Thorac Surg.* 1978;26:421-426
48. El Oakley RM, Wright JE. Postoperative mediastinitis: Classification and management. *Ann Thorac Surg.* 1996;61:1030-1036
49. Garner JS, Jarvis WR, Emori TG, Horan TC, Hughes JM. CDC definitions for nosocomial infections, 1988. *Am J Infect Control.* 1988;16:128-140
50. Bryant LR, Spencer FC, Trinkle JK. Treatment of median sternotomy infection by mediastinal irrigation with an antibiotic solution. *Ann Surg.* 1969;169:914-920
51. Engelman RM, Williams CD, Gouge TH, Chase RM, Jr., Falk EA, Boyd AD, Reed GE. Mediastinitis following open-heart surgery. Review of two years' experience. *Arch Surg.* 1973;107:772-778
52. Jimenez-Martinez M, Arguero-Sanchez R, Perez-Alvarez JJ, Mina-Castaneda P. Anterior mediastinitis as a complication of median sternotomy incisions: Diagnostic and surgical considerations. *Surgery.* 1970;67:929-934
53. Francel TJ, Kouchoukos NT. A rational approach to wound difficulties after sternotomy: The problem. *Ann Thorac Surg.* 2001;72:1411-1418
54. Yamaguchi H, Yamauchi H, Yamada T, Ariyoshi T, Aikawa H, Kato Y. Diagnostic validity of computed tomography for mediastinitis after cardiac surgery. *Ann Thorac Cardiovasc Surg.* 2001;7:94-98

55. Ochsner JL, Mills NL, Woolverton WC. Disruption and infection of the median sternotomy incision. *J Cardiovasc Surg (Torino)*. 1972;13:394-399
56. Shafir R, Weiss J, Herman O, Cohen N, Stern D, Igra Y. Faulty sternotomy and complications after median sternotomy. *J Thorac Cardiovasc Surg*. 1988;96:310-313
57. Ko W, Lazenby WD, Zelano JA, Isom OW, Krieger KH. Effects of shaving methods and intraoperative irrigation on suppurative mediastinitis after bypass operations. *Ann Thorac Surg*. 1992;53:301-305
58. Markewitz A, Schulte HD, Scheld HH. Current practice of peri- and postoperative antibiotic therapy in cardiac surgery in Germany. Working group on cardiothoracic surgical intensive care medicine of the German society for thoracic and cardiovascular surgery. *Thorac Cardiovasc Surg*. 1999;47:405-410
59. Parry GW, Holden SR, Shabbo FP. Antibiotic prophylaxis for cardiac surgery: Current united kingdom practice. *Br Heart J*. 1993;70:585-586
60. Madden JE, Edlich RF, Custer JR, Panek PH, Thul J, Wangenstein OH. Studies in the management of the contaminated wound. Iv. Resistance to infection of surgical wounds made by knife, electrosurgery, and laser. *Am J Surg*. 1970;119:222-224
61. Mangram AJ, Horan TC, Pearson ML, Silver LC, Jarvis WR. Guideline for prevention of surgical site infection, 1999. Centers for disease control and prevention (CDC) hospital infection control practices advisory committee. *Am J Infect Control*. 1999;27:97-132; quiz 133-134; discussion 196
62. Nishida H, Grooters RK, Merkley DF, Thieman KC, Soltanzadeh H. Postoperative mediastinitis: A comparison of two electrocautery techniques on presternal soft tissues. *J Thorac Cardiovasc Surg*. 1990;99:969-976
63. Abboud CS, Wey SB, Baltar VT. Risk factors for mediastinitis after cardiac surgery. *Ann Thorac Surg*. 2004;77:676-683
64. Demmy TL, Park SB, Liebler GA, Burkholder JA, Maher TD, Benckart DH, Magovern GJ, Jr., Magovern GJ, Sr. Recent experience with major sternal wound complications. *Ann Thorac Surg*. 1990;49:458-462
65. Furnary AP, Gao G, Grunkemeier GL, Wu Y, Zerr KJ, Bookin SO, Floten HS, Starr A. Continuous insulin infusion reduces mortality in patients with diabetes undergoing coronary artery bypass grafting. *J Thorac Cardiovasc Surg*. 2003;125:1007-1021
66. Furnary AP, Zerr KJ, Grunkemeier GL, Starr A. Continuous intravenous insulin infusion reduces the incidence of deep sternal wound infection in diabetic patients after cardiac surgical procedures. *Ann Thorac Surg*. 1999;67:352-360; discussion 360-352
67. Loop FD, Lytle BW, Cosgrove DM, Mahfood S, McHenry MC, Goormastic M, Stewart RW, Golding LA, Taylor PC. J. Maxwell chamberlain memorial paper. Sternal wound complications after isolated coronary artery bypass grafting: Early and late mortality, morbidity, and cost of care. *Ann Thorac Surg*. 1990;49:179-186; discussion 186-177



68. Sa MP, Soares EF, Santos CA, Figueiredo OJ, Lima RO, Escobar RR, de Rueda FG, Lima Rde C. Risk factors for mediastinitis after coronary artery bypass grafting surgery. *Rev Bras Cir Cardiovasc.* 2011;26:27-35
69. Ariyaratnam P, Bland M, Loubani M. Risk factors and mortality associated with deep sternal wound infections following coronary bypass surgery with or without concomitant procedures in a UK population: A basis for a new risk model? *Interact Cardiovasc Thorac Surg.* 2010;11:543-546
70. Borger MA, Rao V, Weisel RD, Ivanov J, Cohen G, Scully HE, David TE. Deep sternal wound infection: Risk factors and outcomes. *Ann Thorac Surg.* 1998;65:1050-1056
71. Zacharias A, Habib RH. Factors predisposing to median sternotomy complications. Deep vs. superficial infection. *Chest.* 1996;110:1173-1178
72. Diez C, Koch D, Kuss O, Silber RE, Friedrich I, Boergermann J. Risk factors for mediastinitis after cardiac surgery - a retrospective analysis of 1700 patients. *J Cardiothorac Surg.* 2007;2:23
73. Newman LS, Szczukowski LC, Bain RP, Perlino CA. Suppurative mediastinitis after open heart surgery. A case control study of risk factors. *Chest.* 1988;94:546-553
74. Nagachinta T, Stephens M, Reitz B, Polk BF. Risk factors for surgical-wound infection following cardiac surgery. *J Infect Dis.* 1987;156:967-973
75. Liu JY, Birkmeyer NJ, Sanders JH, Morton JR, Henriques HF, Lahey SJ, Dow RW, Maloney C, DiScipio AW, Clough R, Leavitt BJ, O'Connor GT. Risks of morbidity and mortality in dialysis patients undergoing coronary artery bypass surgery. Northern New England Cardiovascular Disease Study Group. *Circulation.* 2000;102:2973-2977
76. Mangano CM, Diamondstone LS, Ramsay JG, Aggarwal A, Herskowitz A, Mangano DT. Renal dysfunction after myocardial revascularization: Risk factors, adverse outcomes, and hospital resource utilization. The multicenter study of perioperative ischemia research group. *Ann Intern Med.* 1998;128:194-203
77. Toumpoulis IK, Anagnostopoulos CE, Derosé JJ, Jr., Swistel DG. The impact of deep sternal wound infection on long-term survival after coronary artery bypass grafting. *Chest.* 2005;127:464-471
78. Sarr MG, Gott VL, Townsend TR. Mediastinal infection after cardiac surgery. *Ann Thorac Surg.* 1984;38:415-423
79. Zuckermann A, Barten MJ. Surgical wound complications after heart transplantation. *Transpl Int.* 2011;24:627-636
80. Ang LB, Veloria EN, Evanina EY, Smaldone A. Mediastinitis and blood transfusion in cardiac surgery: A systematic review. *Heart Lung.* 2012;41:255-263
81. Gottlieb LJ, Piolet RW, Karp RB, Krieger LM, Smith DJ, Jr., Deeb GM. Rigid internal fixation of the sternum in postoperative mediastinitis. *Arch Surg.* 1994;129:489-493

82. Miller MD, Johnson RG, Naifeh J. Repair of sternal dehiscence using a Harrington compression system. *Ann Thorac Surg.* 1988;45:684-685
83. Robicsek F, Daugherty HK, Cook JW. The prevention and treatment of sternum separation following open-heart surgery. *J Thorac Cardiovasc Surg.* 1977;73:267-268
84. Eagle KA, Guyton RA, Davidoff R, Edwards FH, Ewy GA, Gardner TJ, Hart JC, Herrmann HC, Hillis LD, Hutter AM, Jr., Lytle BW, Marlow RA, Nugent WC, Orszulak TA. Acc/aha 2004 guideline update for coronary artery bypass graft surgery: A report of the American College of Cardiology/American Heart Association Task Force on Practice Guidelines (committee to update the 1999 guidelines for coronary artery bypass graft surgery). *Circulation.* 2004;110:e340-437
85. Schulman NH, Subramanian V. Sternal wound reconstruction: 252 consecutive cases. The Lenox Hill experience. *Plast Reconstr Surg.* 2004;114:44-48
86. Jones G, Jurkiewicz MJ, Bostwick J, Wood R, Bried JT, Culbertson J, Howell R, Eaves F, Carlson G, Nahai F. Management of the infected median sternotomy wound with muscle flaps. The Emory 20-year experience. *Ann Surg.* 1997;225:766-776; discussion 776-768
87. Serry C, Bleck PC, Javid H, Hunter JA, Goldin MD, DeLaria GA, Najafi H. Sternal wound complications. Management and results. *J Thorac Cardiovasc Surg.* 1980;80:861-867
88. Vaska PL. Sternal wound infections. *AACN Clin Issues Crit Care Nurs.* 1993;4:475-483
89. Vos RJ, Yilmaz A, Sonker U, Kelder JC, Kloppenburg GT. Vacuum-assisted closure of post-sternotomy mediastinitis as compared to open packing. *Interact Cardiovasc Thorac Surg.* 2012;14:17-21
90. Shumacker HB, Jr., Mandelbaum I. Continuous antibiotic irrigation in the treatment of infection. *Arch Surg.* 1963;86:384-387
91. Nahai F, Rand RP, Hester TR, Bostwick J, 3rd, Jurkiewicz MJ. Primary treatment of the infected sternotomy wound with muscle flaps: A review of 211 consecutive cases. *Plast Reconstr Surg.* 1989;84:434-441
92. Cartier R, Diaz OS, Carrier M, Leclerc Y, Castonguay Y, Leung TK. Right ventricular rupture. A complication of postoperative mediastinitis. *J Thorac Cardiovasc Surg.* 1993;106:1036-1039
93. Catarino PA, Chamberlain MH, Wright NC, Black E, Campbell K, Robson D, Pillai RG. High-pressure suction drainage via a polyurethane foam in the management of poststernotomy mediastinitis. *Ann Thorac Surg.* 2000;70:1891-1895
94. Rand RP, Cochran RP, Aziz S, Hofer BO, Allen MD, Verrier ED, Kunzelman KS. Prospective trial of catheter irrigation and muscle flaps for sternal wound infection. *Ann Thorac Surg.* 1998;65:1046-1049

95. Lee AB, Jr., Schimert G, Shaktin S, Seigel JH. Total excision of the sternum and thoracic pedicle transposition of the greater omentum; useful strategies in managing severe mediastinal infection following open heart surgery. *Surgery*. 1976;80:433-436
96. Jurkiewicz MJ, Bostwick J, 3rd, Hester TR, Bishop JB, Craver J. Infected median sternotomy wound. Successful treatment by muscle flaps. *Ann Surg*. 1980;191:738-744
97. Shibata T, Hattori K, Hirai H, Fujii H, Aoyama T, Seuhiro S. Rectus abdominis myocutaneous flap after unsuccessful delayed sternal closure. *Ann Thorac Surg*. 2003;76:956-958
98. Juhl AA, Koudahl V, Damsgaard TE. Deep sternal wound infection after open heart surgery - reconstructive options. *Scand Cardiovasc J*. 2012;46:254-261
99. Milano CA, Georgiade G, Muhlbaier LH, Smith PK, Wolfe WG. Comparison of omental and pectoralis flaps for poststernotomy mediastinitis. *Ann Thorac Surg*. 1999;67:377-380; discussion 380-371
100. Ringelman PR, Vander Kolk CA, Cameron D, Baumgartner WA, Manson PN. Long-term results of flap reconstruction in median sternotomy wound infections. *Plast Reconstr Surg*. 1994;93:1208-1214; discussion 1215-1206
101. Yuen JC, Zhou AT, Serafin D, Georgiade GS. Long-term sequelae following median sternotomy wound infection and flap reconstruction. *Ann Plast Surg*. 1995;35:585-589
102. Astudillo R, Vaage J, Myhre U, Karevold A, Gardlund B. Fewer reoperations and shorter stay in the cardiac surgical ward when stabilising the sternum with the ley prosthesis in post-operative mediastinitis. *Eur J Cardiothorac Surg*. 2001;20:133-139
103. Chase CW, Franklin JD, Guest DP, Barker DE. Internal fixation of the sternum in median sternotomy dehiscence. *Plast Reconstr Surg*. 1999;103:1667-1673
104. Fawzy H, Osei-Tutu K, Errett L, Latter D, Bonneau D, Musgrave M, Mahoney J. Sternal plate fixation for sternal wound reconstruction: Initial experience (retrospective study). *J Cardiothorac Surg*. 2011;6:63
105. Obdeijn MC, de Lange MY, Lichtendahl DH, de Boer WJ. Vacuum-assisted closure in the treatment of poststernotomy mediastinitis. *Ann Thorac Surg*. 1999;68:2358-2360
106. Gustafsson RI, Sjogren J, Ingemansson R. Deep sternal wound infection: A sternal-sparing technique with vacuum-assisted closure therapy. *Ann Thorac Surg*. 2003;76:2048-2053; discussion 2053
107. Debreceni T, Szerafin T, Galajda Z, Miskolczi S, Peterffy A. [results of vacuum-assisted wound closure system in the treatment of sternotomy wound infections following cardiac surgery]. *Magy Seb*. 2008;61 Suppl:29-35
108. Fleck T, Fleck M. Negative pressure wound therapy for the treatment of sternal wound infections after cardiac surgery. *Int Wound J*. 2012

109. Gustafsson R, Johnsson P, Algotsson L, Blomquist S, Ingemansson R. Vacuum-assisted closure therapy guided by C-reactive protein level in patients with deep sternal wound infection. *J Thorac Cardiovasc Surg.* 2002;123:895-900
110. Braxton JH, Marrin CA, McGrath PD, Ross CS, Morton JR, Norotsky M, Charlesworth DC, Lahey SJ, Clough RA, O'Connor GT. Mediastinitis and long-term survival after coronary artery bypass graft surgery. *Ann Thorac Surg.* 2000;70:2004-2007
111. Deniz H, Gokaslan G, Arslanoglu Y, Ozcaliskan O, Guzel G, Yasim A, Ustunsoy H. Treatment outcomes of postoperative mediastinitis in cardiac surgery; negative pressure wound therapy versus conventional treatment. *J Cardiothorac Surg.* 2012;7:67
112. De Feo M, Della Corte A, Vicchio M, Pirozzi F, Nappi G, Cotrufo M. Is post-sternotomy mediastinitis still devastating after the advent of negative-pressure wound therapy? *Tex Heart Inst J.* 2011;38:375-380
113. Risnes I, Abdelnoor M, Veil T, Svennevig JL, Lundblad R, Rynning SE. Mediastinitis after coronary artery bypass grafting: The effect of vacuum-assisted closure versus traditional closed drainage on survival and reinfection rate. *Int Wound J.* 2012
114. Damiani G, Pinnarelli L, Sommella L, Tocco MP, Marvulli M, Magrini P, Ricciardi W. Vacuum-assisted closure therapy for patients with infected sternal wounds: A meta-analysis of current evidence. *J Plast Reconstr Aesthet Surg.* 2011;64:1119-1123
115. Sjogren J, Nilsson J, Gustafsson R, Malmsjo M, Ingemansson R. The impact of vacuum-assisted closure on long-term survival after post-sternotomy mediastinitis. *Ann Thorac Surg.* 2005;80:1270-1275
116. Simek M, Hajek R, Flugler I, Molitor M, Grulichova J, Langova K, Tobbia P, Nemec P, Zalesak B, Lonsky V. Superiority of topical negative pressure over closed irrigation therapy of deep sternal wound infection in cardiac surgery. *J Cardiovasc Surg (Torino).* 2012;53:113-120
117. Sartipy U, Lockowandt U, Gabel J, Jideus L, Dellgren G. Cardiac rupture during vacuum-assisted closure therapy. *Ann Thorac Surg.* 2006;82:1110-1111
118. Bapat V, El-Muttardi N, Young C, Venn G, Roxburgh J. Experience with vacuum-assisted closure of sternal wound infections following cardiac surgery and evaluation of chronic complications associated with its use. *J Card Surg.* 2008;23:227-233
119. Ennker IC, Malkoc A, Pietrowski D, Vogt PM, Ennker J, Albert A. The concept of negative pressure wound therapy (npwt) after poststernotomy mediastinitis--a single center experience with 54 patients. *J Cardiothorac Surg.* 2009;4:5
120. Khoynezhad A, Abbas G, Palazzo RS, Graver LM. Spontaneous right ventricular disruption following treatment of sternal infection. *J Card Surg.* 2004;19:74-78
121. Abu-Omar Y, Naik MJ, Catarino PA, Ratnatunga C. Right ventricular rupture during use of high-pressure suction drainage in the management of poststernotomy mediastinitis. *Ann Thorac Surg.* 2003;76:974; author reply 974-975

122. Yellin A, Refaely Y, Paley M, Simansky D. Major bleeding complicating deep sternal infection after cardiac surgery. *J Thorac Cardiovasc Surg.* 2003;125:554-558
123. Petzina R, Malmsjo M, Stamm C, Hetzer R. Major complications during negative pressure wound therapy in poststernotomy mediastinitis after cardiac surgery. *J Thorac Cardiovasc Surg.* 2010;140:1133-1136
124. Caianiello G, Petraio A, Ursomando F, Pepino P, Cotrufo M, De Feo M, Maiello C, De Santo LS. Aortic erosion during negative pressure therapy in a pediatric heart transplant recipient. *Ann Thorac Surg.* 2011;92:1879-1880
125. Sjogren J, Gustafsson R, Nilsson J, Lindstedt S, Nozohoor S, Ingemansson R. Negative-pressure wound therapy following cardiac surgery: Bleeding complications and 30-day mortality in 176 patients with deep sternal wound infection. *Interact Cardiovasc Thorac Surg.* 2011;12:117-120
126. Grauhan O, Navarsadyan A, Hussmann J, Hetzer R. Infectious erosion of aorta ascendens during vacuum-assisted therapy of mediastinitis. *Interact Cardiovasc Thorac Surg.* 2010;11:493-494
127. Carnero-Alcazar M, Silva Guisasola JA, Rodriguez Hernandez JE. Right ventricle bleeding secondary to vacuum assisted therapy? *Interact Cardiovasc Thorac Surg.* 2010;10:472
128. Malmsjo M, Petzina R, Ugander M, Engblom H, Torbrand C, Mokhtari A, Hetzer R, Arheden H, Ingemansson R. Preventing heart injury during negative pressure wound therapy in cardiac surgery: Assessment using real-time magnetic resonance imaging. *J Thorac Cardiovasc Surg.* 2009;138:712-717
129. Townsend Jr. C.M. RDB, B.M. Evers, K.L. Mattox *Sabiston textbook of surgery: The biological basis of modern surgical practice.* 2001.
130. Stadelmann WK, Digenis AG, Tobin GR. Physiology and healing dynamics of chronic cutaneous wounds. *Am J Surg.* 1998;176:26S-38S
131. Tanenbaum M. *Skin and tissue techniques.* 1995.
132. Midwood KS, Williams LV, Schwarzbauer JE. Tissue repair and the dynamics of the extracellular matrix. *Int J Biochem Cell Biol.* 2004;36:1031-1037
133. Chang HY, Sneddon JB, Alizadeh AA, Sood R, West RB, Montgomery K, Chi JT, van de Rijn M, Botstein D, Brown PO. Gene expression signature of fibroblast serum response predicts human cancer progression: Similarities between tumors and wounds. *PLoS Biol.* 2004;2:E7
134. Garg HG. Scarless wound healing. 2000
135. Malmsjo M, Ingemansson R, Sjogren J. Mechanisms governing the effects of vacuum-assisted closure in cardiac surgery. *Plast Reconstr Surg.* 2007;120:1266-1275
136. Ramnarine IR, McLean A, Pollock JC. Vacuum-assisted closure in the paediatric patient with post-cardiotomy mediastinitis. *Eur J Cardiothorac Surg.* 2002;22:1029-1031

137. Kutschka I, Frauendorfer P, Harringer W. [vacuum assisted closure therapy improves early postoperative lung function in patients with large sternal wounds]. *Zentralbl Chir.* 2004;129 Suppl 1:S33-34
138. Mokhtari A, Petzina R, Gustafsson L, Sjögren J, Malmjö M, Ingemansson R. Sternal stability at different negative pressures during vacuum-assisted closure therapy. *Ann Thorac Surg.* 2006;82:1063-1067
139. Hersh RE, Jack JM, Dahman MI, Morgan RF, Drake DB. The vacuum-assisted closure device as a bridge to sternal wound closure. *Ann Plast Surg.* 2001;46:250-254
140. Nease C. Using low pressure, negative pressure wound therapy for wound preparation and the management of split-thickness skin grafts in three patients with complex wounds. *Ostomy Wound Manage.* 2009;55:32-42
141. Conquest AM, Garofalo JH, Maziarz DM, Mendelson KG, Su Sun Y, Wooden WA, Meadows WM, Nifong W, Chitwood WR. Hemodynamic effects of the vacuum-assisted closure device on open mediastinal wounds. *J Surg Res.* 2003;115:209-213
142. Petzina R, Ugander M, Gustafsson L, Engblom H, Sjogren J, Hetzer R, Ingemansson R, Arheden H, Malmjö M. Hemodynamic effects of vacuum-assisted closure therapy in cardiac surgery: Assessment using magnetic resonance imaging. *J Thorac Cardiovasc Surg.* 2007;133:1154-1162
143. Lundberg JM, Franco-Cereceda A, Lacroix JS, Pernow J. Neuropeptide y and sympathetic neurotransmission. *Ann N Y Acad Sci.* 1990;611:166-174
144. Zouhal H, Jacob C, Delamarche P, Gratas-Delamarche A. Catecholamines and the effects of exercise, training and gender. *Sports Med.* 2008;38:401-423
145. Borgquist O, Ingemansson R, Malmjö M. Micro- and macromechanical effects on the wound bed by negative pressure wound therapy using gauze and foam *Ann Plast Surg.* 2010;64:789-793
146. Saxena V, Hwang CW, Huang S, Eichbaum Q, Ingber D, Orgill DP. Vacuum-assisted closure: Microdeformations of wounds and cell proliferation. *Plast Reconstr Surg.* 2004;114:1086-1096; discussion 1097-1088
147. Quinn TP, Schlueter M, Soifer SJ, Gutierrez JA. Cyclic mechanical stretch induces VEGF and FGF-2 expression in pulmonary vascular smooth muscle cells. *Am J Physiol Lung Cell Mol Physiol.* 2002;282:L897-903
148. Rivilis I, Milkiewicz M, Boyd P, Goldstein J, Brown MD, Egginton S, Hansen FM, Hudlicka O, Haas TL. Differential involvement of MMP-2 and VEGF during muscle stretch- versus shear stress-induced angiogenesis. *Am J Physiol Heart Circ Physiol.* 2002;283:H1430-1438
149. Urschel JD, Scott PG, Williams HT. The effect of mechanical stress on soft and hard tissue repair; a review. *Br J Plast Surg.* 1988;41:182-186
150. Chen CS, Mrksich M, Huang S, Whitesides GM, Ingber DE. Geometric control of cell life and death. *Science.* 1997;276:1425-1428

151. Huang S, Chen CS, Ingber DE. Control of cyclin d1, p27(kip1), and cell cycle progression in human capillary endothelial cells by cell shape and cytoskeletal tension. *Mol Biol Cell*. 1998;9:3179-3193
152. Huang S, Ingber DE. The structural and mechanical complexity of cell-growth control. *Nat Cell Biol*. 1999;1:E131-138
153. Ingber DE. Tensegrity: The architectural basis of cellular mechanotransduction. *Annu Rev Physiol*. 1997;59:575-599
154. Martin R. Smith & Nephew, Research and Development, Hull, UK, personal communication.
155. Genecov DG, Schneider AM, Morykwas MJ, Parker D, White WL, Argenta LC. A controlled subatmospheric pressure dressing increases the rate of skin graft donor site reepithelialization. *Ann Plast Surg*. 1998;40:219-225
156. Moues CM, Vos MC, van den Bemd GJ, Stijnen T, Hovius SE. Bacterial load in relation to vacuum-assisted closure wound therapy: A prospective randomized trial. *Wound Repair Regen*. 2004;12:11-17
157. Chen SZ, Li J, Li XY, Xu LS. Effects of vacuum-assisted closure on wound microcirculation: An experimental study. *Asian J Surg*. 2005;28:211-217
158. Fraccalvieri M. Negative pressure wound therapy using the gauze and the foam: Immunohistological and ultrasonography morphological analysis of the granulation tissue and the scar tissue. Preliminary report of a clinical study. *3rd Congress CO.R.T.E.* 2010;4-6 of March
159. Luttkhuizen DT, Harmsen MC, Van Luyn MJ. Cellular and molecular dynamics in the foreign body reaction. *Tissue Eng*. 2006;12:1955-1970
160. Gummert JF, Barten MJ, Hans C, Kluge M, Doll N, Walther T, Hentschel B, Schmitt DV, Mohr FW, Diegeler A. Mediastinitis and cardiac surgery--an updated risk factor analysis in 10,373 consecutive adult patients. *Thorac Cardiovasc Surg*. 2002;50:87-91
161. Miller Q, Bird E, Bird K, Meschter C, Moulton MJ. Effect of subatmospheric pressure on the acute healing wound. *Curr Surg*. 2004;61:205-208
162. Borgquist O, Ingemansson R, Malmso M. Wound edge microvascular blood flow during negative-pressure wound therapy: Examining the effects of pressures from -10 to -175 mmHg. *Plast Reconstr Surg*. 2010;125:502-509
163. Petzina R, Gustafsson L, Mokhtari A, Ingemansson R, Malmso M. Effect of vacuum-assisted closure on blood flow in the peristernal thoracic wall after internal mammary artery harvesting. *Eur J Cardiothorac Surg*. 2006;30:85-89
164. Wackenfors A, Gustafsson R, Sjogren J, Algotsson L, Ingemansson R, Malmso M. Blood flow responses in the peristernal thoracic wall during vacuum-assisted closure therapy. *Ann Thorac Surg*. 2005;79:1724-1730; discussion 1730-1721



165. Wackenfors A, Sjogren J, Gustafsson R, Algotsson L, Ingemansson R, Malmso M. Effects of vacuum-assisted closure therapy on inguinal wound edge microvascular blood flow. *Wound Repair Regen.* 2004;12:600-606
166. Kairinos N, Solomons M, Hudson DA. Negative-pressure wound therapy i: The paradox of negative-pressure wound therapy. *Plast Reconstr Surg.* 2009;123:589-598; discussion 599-600
167. Kairinos N, Solomons M, Hudson DA. The paradox of negative pressure wound therapy--in vitro studies. *J Plast Reconstr Aesthet Surg.* 2010;63:174-179
168. Sjogren J, Gustafsson R, Koul B, Ingemansson R. Selective mediastinal tamponade to control coagulopathic bleeding. *Ann Thorac Surg.* 2003;75:1311-1313
169. Hudlicka O, Brown M, Egginton S. Angiogenesis in skeletal and cardiac muscle. *Physiol Rev.* 1992;72:369-417
170. Chester DL, Waters R. Adverse alteration of wound flora with topical negative-pressure therapy: A case report. *Br J Plast Surg.* 2002;55:510-511
171. Khashram M, Huggan P, Ikram R, Chambers S, Roake JA, Lewis DR. Effect of TNP on the microbiology of venous leg ulcers: A pilot study. *J Wound Care.* 2009;18:164-167
172. Weed T, Ratliff C, Drake DB. Quantifying bacterial bioburden during negative pressure wound therapy: Does the wound vac enhance bacterial clearance? *Ann Plast Surg.* 2004;52:276-279; discussion 279-280
173. Armstrong DG, Jude EB. The role of matrix metalloproteinases in wound healing. *J Am Podiatr Med Assoc.* 2002;92:12-18
174. Yager DR, Nwomeh BC. The proteolytic environment of chronic wounds. *Wound Repair Regen.* 1999;7:433-441
175. Barbul A, Fishel RS, Shimazu S, Damewood RB, Wasserkrug HL, Efron G. Inhibition of host immunity by fluid and mononuclear cells from healing wounds. *Surgery.* 1984;96:315-320
176. Lazarou SA, Barbul A, Wasserkrug HL, Efron G. The wound is a possible source of posttraumatic immunosuppression. *Arch Surg.* 1989;124:1429-1431
177. Marieb EN. *Human anatomy & physiology.* Benjamin Cummings; 2001.
178. Silva AP, Cavadas C, Grouzmann E. Neuropeptide y and its receptors as potential therapeutic drug targets. *Clin Chim Acta.* 2002;326:3-25
179. Lucia P, Caiola S, Coppola A, Manetti LL, Maroccia E, Buongiorno AM, De Martinis C. Vasoactive intestinal peptide (VIP): A new neuroendocrine marker of clinical progression in chronic heart failure? *Clin Endocrinol (Oxf).* 2003;59:723-727
180. Brain SD, Williams TJ, Tippins JR, Morris HR, MacIntyre I. Calcitonin gene-related peptide is a potent vasodilator. *Nature.* 1985;313:54-56



181. De Felipe C, Herrero JF, O'Brien JA, Palmer JA, Doyle CA, Smith AJ, Laird JM, Belmonte C, Cervero F, Hunt SP. Altered nociception, analgesia and aggression in mice lacking the receptor for substance p. *Nature*. 1998;392:394-397
182. McCulloch J, Uddman R, Kingman TA, Edvinsson L. Calcitonin gene-related peptide: Functional role in cerebrovascular regulation. *Proc Natl Acad Sci U S A*. 1986;83:5731-5735
183. Wallengren J. Vasoactive peptides in the skin. *J Invest Dermatol Symp Proc*. 1997;2:49-55
184. Edvinsson L, Ekman R, Thulin T. Reduced levels of calcitonin gene-related peptide (CGRP) but not substance p during and after treatment of severe hypertension in man. *J Hum Hypertens*. 1989;3:267-270
185. Edvinsson L, Ekman R, Thulin T. Increased plasma levels of neuropeptide y-like immunoreactivity and catecholamines in severe hypertension remain after treatment to normotension in man. *Regul Pept*. 1991;32:279-287
186. Stahl MM, Vaara I, Hedner P, Ekman R. Vasoactive peptides in Bartter's syndrome. *Eur J Clin Invest*. 1993;23:80-83
187. Valdemarsson S, Edvinsson L, Ekman R, Hedner P, Sjöholm A. Increased plasma level of substance p in patients with severe congestive heart failure treated with ace inhibitors. *J Intern Med*. 1991;230:325-331
188. Heiberg E, Sjögren J, Ugander M, Carlsson M, Engblom H, Arheden H. Design and validation of segment - freely available software for cardiovascular image analyses. *BMC Med Imaging*. 2010;10:1
189. Carlsson M, Cain P, Holmqvist C, Stahlberg F, Lundback S, Arheden H. Total heart volume variation throughout the cardiac cycle in humans. *Am J Physiol Heart Circ Physiol*. 2004;287:H243-250
190. Hamilton WR, JH. Movement of the base of the ventricle and the relative constancy of the cardiac volume. *Am J Physiol*. 1932;102:559-565
191. Hoffman EA, Ritman EL. Invariant total heart volume in the intact thorax. *Am J Physiol*. 1985;249:H883-890
192. Hoffman EA, Ritman EL. Heart-lung interaction: Effect on regional lung air content and total heart volume. *Ann Biomed Eng*. 1987;15:241-257
193. Lundback S. Cardiac pumping and function of the ventricular septum. *Acta Physiol Scand Suppl*. 1986;550:1-101
194. Gotberg M, Olivecrona GK, Engblom H, Ugander M, van der Pals J, Heiberg E, Arheden H, Erlinge D. Rapid short-duration hypothermia with cold saline and endovascular cooling before reperfusion reduces microvascular obstruction and myocardial infarct size. *BMC Cardiovasc Disord*. 2008;8:7
195. Curran-Everett D. Explorations in statistics: Standard deviations and standard errors. *Adv Physiol Educ*. 2008;32:203-208

196. Nagele P. Misuse of standard error of the mean (sem) when reporting variability of a sample. A critical evaluation of four anaesthesia journals. *Br J Anaesth.* 2003;90:514-516
197. Greene AK, Puder M, Roy R, Arsenault D, Kwei S, Moses MA, Orgill DP. Microdeformational wound therapy: Effects on angiogenesis and matrix metalloproteinases in chronic wounds of 3 debilitated patients. *Ann Plast Surg.* 2006;56:418-422
198. Lindstedt S, Ingemansson R, Malmso M. A rigid barrier between the heart and sternum protects the heart and lungs against rupture during negative pressure wound therapy. *J Cardiothorac Surg.* 2011;6:90
199. Apostoli A, Caula C. [pain and basic functional activities in a group of patients with cutaneous wounds under V.A.C therapy in hospital setting]. *Prof Inferm.* 2008;61:158-164
200. Kuklinska AM, Mroczko B, Musial WJ, Sawicki R, Kaminski K, Usowicz-Szarynska M, Szmitkowski M. Endothelial dysfunction and sympathetic nervous system activation in young patients with essential arterial hypertension and without hypercholesterolaemia. *Acta Cardiol.* 2010;65:535-540
201. Snyder EM, Wong EC, Foxx-Lupo WT, Wheatley CM, Cassuto NA, Patanwala AE. Effects of an inhaled beta2-agonist on cardiovascular function and sympathetic activity in healthy subjects. *Pharmacotherapy.* 2011;31:748-756
202. Morykwas MJ, Simpson J, Pungert K, Argenta A, Kremers L, Argenta J. Vacuum-assisted closure: State of basic research and physiologic foundation. *Plast Reconstr Surg.* 2006;117:121S-126S
203. Reuter DA, Goresch T, Goepfert MS, Wildhirt SM, Kilger E, Goetz AE. Effects of mid-line thoracotomy on the interaction between mechanical ventilation and cardiac filling during cardiac surgery. *Br J Anaesth.* 2004;92:808-813
204. Petzina R, Ugander M, Gustafsson L, Engblom H, Hetzer R, Arheden H, Ingemansson R, Malmso M. Topical negative pressure therapy of a sternotomy wound increases sternal fluid content but does not affect internal thoracic artery blood flow: Assessment using magnetic resonance imaging. *J Thorac Cardiovasc Surg.* 2008;135:1007-1013
205. Isago T, Nozaki M, Kikuchi Y, Honda T, Nakazawa H. Effects of different negative pressures on reduction of wounds in negative pressure dressings. *J Dermatol.* 2003;30:596-601
206. FDA, Communication S. Update on serious complications associated with negative pressure wound therapy systems. 2011;February 24
207. FDA PPHN. Serious complications associated with negative pressure wound therapy systems. 2009 November 13

208. Ingemansson R, Malmsjo M, Lindstedt S. A protection device that reduces the risk of right ventricular rupture in patients with deep sternal wound infection *J Thorac Cardiovasc Surg.* 2012;In press
209. Ingemansson R, Malmsjo M, Lindstedt S. CRP and leukocyte counts drops faster in patients treated with NPWT using a rigid barrier disc for DSWI *Plast Reconstr Surg.* 2012;In press
210. Ingemansson R, Malmsjo M, Lindstedt S. The duration of npwt can be reduced using the device in patients with deep sternal wound infection. *J Plast Reconstr Aesthet Surg.* 2012;In press
211. Lindstedt S, Malmsjo M, Ingemansson R. Effects on drainage of the mediastinum and pleura during negative pressure wound therapy when using a rigid barrier to prevent heart rupture. *Int Wound J.* 2011;8:454-458





# Pressure transduction to the thoracic cavity during topical negative pressure therapy of a sternotomy wound

Christian Torbrand, Richard Ingemansson, Lotta Gustafsson, Per Paulsson, Malin Malmjö

Torbrand C, Ingemansson R, Gustafsson L, Paulsson P, Malmjö M. Pressure transduction to the thoracic cavity during topical negative pressure therapy of a sternotomy wound. *Int Wound J* 2008;5:579–584.

## ABSTRACT

The present study was performed to examine pressure transduction to the thoracic cavity during topical negative pressure (TNP) therapy of a sternotomy wound. Seven pigs underwent median sternotomy. Pressure transduction catheters were placed on the anterior surface of the heart (under the foam), in the pericardium (under the heart), in the left pleura and in the oesophagus at the level of the heart. The wound was sealed as for TNP therapy. The vacuum source was set to deliver negative pressures between  $-50$  and  $-200$  mmHg. The pressure on the anterior surface of the heart changed in a linear relationship with the applied negative pressure and was slightly lower than the applied negative pressure ( $-102 \pm 9$  mmHg at delivered  $-125$  mmHg). Further down in the thoracic cavity, in the pericardium (under the heart), in the left pleura and in the oesophagus, the wound pressure was only slightly affected by TNP therapy. In conclusion during TNP therapy, negative pressure is effectively transmitted to anterior portions of the heart. This may explain our recent findings that TNP increases microvascular blood flow in the myocardium. The pressure difference between the anterior and the posterior portions of the heart causes the right ventricle to be sucked up towards the posterior parts of the sternum, where it might be exposed to the sharp edges of the sternal bone, which may result in heart injury.

**Key words:** Experimental surgery • Mediastinal infection • Wound healing

## INTRODUCTION

Cardiac surgery is complicated by poststernotomy mediastinitis in 1–5% of all procedures (1), and this is a potentially life-threatening complication (2). The reported early mortality in poststernotomy mediastinitis following coro-

nary bypass surgery grafting is between 8% and 25% (3,4). Established treatment of poststernotomy mediastinitis includes surgical debridement, drainage, irrigation and reconstruction using pectoral muscle flap or omentum transposition. In 1999, Obdeijn *et al.* described a new mode of treatment for poststernotomy mediastinitis using a vacuum-assisted closure technique (5), which is based on the principle of applying subatmospheric pressure by controlled suction to a sealed, airtight wound through a porous dressing. The technique, also known as topical negative pressure (TNP) therapy, has resulted in excellent clinical outcome (1–5). Scientific evidence regarding the mechanisms by which TNP promotes wound healing has started to emerge. The suction force

## Key Points

- scientific evidence regarding the mechanisms by which TNP promotes wound healing has started to emerge

**Authors:** C Torbrand, MD, Department of Medicine, Lund University Hospital, Lund, Sweden; R Ingemansson, MD, PhD, Department of Cardiothoracic Surgery, Lund University Hospital, Lund, Sweden; L Gustafsson, MSc, PhD, Department of Medicine, Lund University Hospital, Lund, Sweden; P Paulsson, MD, Department of Cardiothoracic Surgery, Lund University Hospital, Lund, Sweden; M Malmjö, MD, PhD, Department of Medicine, Lund University Hospital, Lund, Sweden

**Address for correspondence:** M Malmjö, MD, PhD, Vascular Research, Lund University, BMC A13, SE-221 84 Lund, Sweden

**E-mail:** malin.malmjo@med.lu.se

### Key Points

- the present study was designed to examine to which extent negative pressure is transduced to the anterior portions of the heart and also to deeper parts of the thoracic cavity
- a porcine sternotomy wound model was used

created by TNP therapy enables the drainage of excessive fluid and debris, which leads to the removal of wound oedema, reduction in bacterial count and enhanced granulation tissue formation (6–9). Knowledge of the effects of TNP in a sternotomy wound is limited (10).

It is known that blood flow to the muscle tissue of the wound edge is increased by TNP therapy (7–9). We recently show that TNP of a sternotomy wound stimulates blood flow to the myocardium (10). The present study was designed to examine to which extent negative pressure is transduced to the anterior portions of the heart and also to deeper parts of the thoracic cavity. A porcine sternotomy wound model was used, and pressure was recorded on the anterior portions of the heart, in the pericardium (behind the heart), in the left pleura and in the oesophagus during the application of TNP therapy at pressures between –50 and –200 mmHg.

## MATERIALS AND METHODS

### Animals

A porcine sternotomy wound model was used. Seven domestic landrace pigs with a mean weight of 70 kg were fasted overnight with free access to water. The study was approved by the Ethics Committee for Animal Research, Lund University, Sweden. The investigation complied with the 'Guide for the Care and Use of Laboratory Animals' as recommended by the US National Institutes of Health and published by the National Academies Press (1996). The anaesthesia was induced, and the surgical procedure was performed as previously described (11).

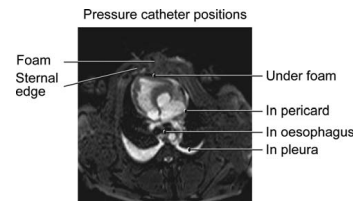
### Anaesthesia and surgical preparation

An intramuscular injection of ketamine (Ketaminol vet<sup>TM</sup> 100 mg/ml; Farmaceutici Gellini S.p.A, Aprilia, Italy) 15 mg/kg body weight, in combination with midazolam (Dormicum 1 mg/ml; Roche, Stockholm, Sweden) and xylazine (Rompun vet<sup>TM</sup> 20 mg/ml; Bayer AG, Leverkusen, Germany) 2 mg/kg, was used for premedication. Anaesthesia was induced by continuous intravenous infusion of propofol (Diprivan<sup>TM</sup> 20 mg/ml; AstraZeneca, Södertälje, Sweden) at a dosage of 0.1–0.2 mg/kg/minute in combination with intermittent fentanyl (Leptanal<sup>TM</sup>; Lilly, France) and atracurium besylate (Tracrium<sup>TM</sup>; Glaxo, Täby, Sweden) at doses of 0.02 µg/kg and 0.2–0.5 mg/kg, respectively. Before surgery, a trache-

otomy (Portex endotracheal tube 7.5 mm internal diameter) was performed.

A ventilator (Servo-Ventilator 900; Elema-Schönander, Stockholm, Sweden) was used for mechanical ventilation. The same settings were used for all animals: volume-controlled, pressure-regulated ventilation, 8.5 l/minute, 15 breaths/minute and an inhaled oxygen fraction of 35%. A lower midline abdominal incision was made over the urinary bladder. The urinary bladder was exposed, and a urinary catheter (Silicone Foley Catheter; Tyco Healthcare, Tullamore, Ireland) was inserted, sutured and connected to a urinary bag (Unomedical a/s, Haarlev, Denmark). The abdominal incision was continuously sutured with Dermalon 2.0 (Davis-Geck, Hampshire, UK).

A midline sternotomy was performed. The tip of a saline-filled pressure catheter was placed in the left pleura, in the pericardium (under the heart) and on the surface of the heart (under foam) through the sternotomy wound. A fourth pressure transduction catheter was inserted into the oesophagus, through the mouth, so that the tip was positioned at the level of the heart. The pressure catheters were connected to a calibrated custom-built pressure gauge. For probe positions, see Figure 1. A layer of polyurethane foam (KCI, Copenhagen, Denmark) was placed between the sternal edges. A second layer of foam was placed over the first layer and secured to the surrounding skin. The wound was sealed with a transparent adhesive drape (KCI), and the



**Figure 1.** Magnetic resonance image illustrating a cross-section of the pig thoracic cavity with an open sternotomy. First, the pressure transduction catheters were placed on the anterior surface of the heart (under the foam), in the pericardium (under the heart) and in the left pleura. A polyurethane foam dressing was placed between the sternal edges, and non collapsible drainage tubes were connected to the foam. The open wound was sealed with transparent adhesive drape, and drainage tubes are connected to a purpose-built vacuum source. A fourth pressure transduction catheter was placed in the oesophagus at the level of the heart.

two evacuation tubes connected the foam with the vacuum source (V.A.C.<sup>®</sup> pump unit; KCI).

### Experimental protocol

Wound pressures were recorded on the anterior surface of the heart (under the foam), in the pericardium (under the heart), in the left pleura and in the oesophagus. Wound pressures were measured both with the respirator on and with the respirator turned off at the end of inspiration. In order to eliminate systemic errors, both the sequence of applying negative pressure (–50, –75, –100, –125, –150, –175 and –200 mmHg) and the order in which the experiments were performed with the respirator turned on and off were varied between the animals in a randomised design.

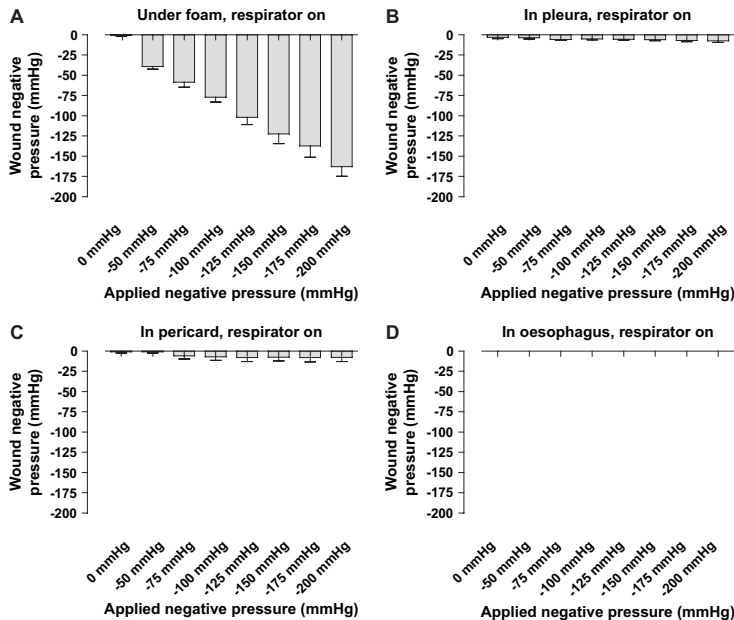
### Calculations and statistics

The experiments were performed on seven pigs. Calculations and statistical analysis were performed using GraphPad Prism<sup>®</sup> 4.0 software

(GraphPad Software Inc, San Diego, CA). Statistical analysis was performed using Kruskal–Wallis test with Dunn's test for multiple comparisons. Significance was defined as  $P < 0.05$ . Values are presented as means  $\pm$  SEM.

### RESULTS

TNP was applied to the sternotomy wound at negative pressures between –50 and –200 mmHg. The pressure over the anterior surface of the heart (under the foam) changed in a linear relationship with the applied negative pressure and was slightly lower than the applied negative pressure (–102  $\pm$  9 mmHg in the wound at delivered –125 mmHg; Figures 2 and 3). The pressure difference between the wound space and the vacuum source was larger at higher negative pressures (–39  $\pm$  3 mmHg in the wound at delivered –50 mmHg and –163  $\pm$  12 mmHg at delivered –200 mmHg).

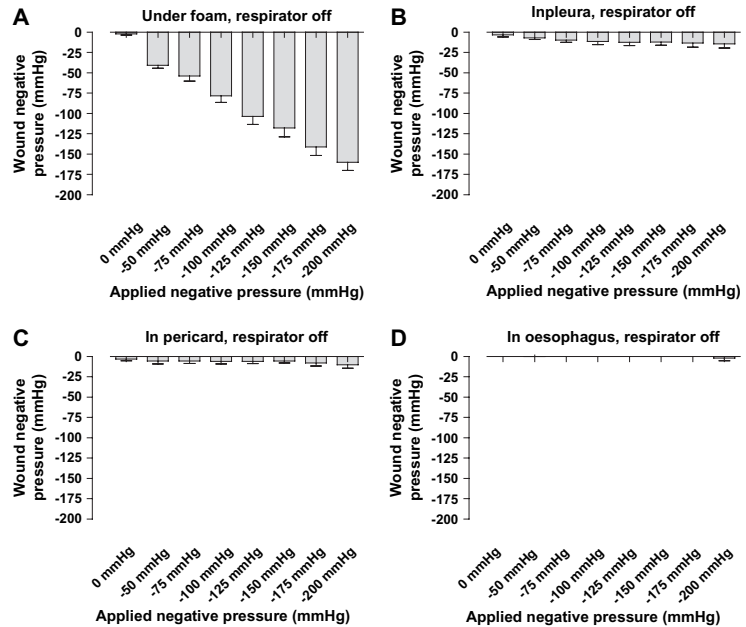


**Figure 2.** Wound pressures measured with the respirator on. The vacuum source was set to deliver negative pressures between –50 and –200 mmHg. Wound pressures were recorded using pressure transduction catheters on (A) the anterior surface of the heart (under the foam), (B) in the pericardium (under the heart), (C) in the left pleura and (D) in the oesophagus. Values are presented as means  $\pm$  SEM from seven experiments. Note how the pressure under the foam changed in a linear relationship with the applied negative pressure, while the pressure further down in the thoracic cavity was not altered.



### Key Points

- TNP is a recently introduced technique that promotes the healing of difficult wounds, including poststernotomy mediastinitis
- we show that the pressure during TNP therapy is effectively delivered to the anterior portions of the heart



**Figure 3.** Wound pressures measured after the respirator had been turned off at the end of inspiration. The vacuum source was set to deliver negative pressures between  $-50$  and  $-200$  mmHg. Wound pressures were recorded using pressure transduction catheters on (A) the anterior surface of the heart (under the foam), (B) in the pericardium (under the heart), (C) in the left pleura and (D) in the oesophagus. Values are presented as means  $\pm$  SEM from seven experiments. Note that the pressure recordings are similar to those with the respirator on.

Further down into the thoracic cavity, in the pericardium (under the heart), in the left pleura and in the oesophagus, the wound pressure was not significantly affected by TNP therapy (Figures 2 and 3). The pressure recordings were similar with the respirator turned on as with the respirator turned off at the end of inspiration (Figures 2 and 3).

### DISCUSSION

Mediastinitis is a devastating complication in open heart surgery. TNP is a recently introduced technique that promotes the healing of difficult wounds, including poststernotomy mediastinitis (4,5,8). The technique entails application of a negative pressure to a sealed, airtight wound. The suction force created by TNP therapy is known to stimulate blood flow to the wound edge and facilitate the drainage of excessive fluid and debris, which leads to the removal of

wound oedema, reduction in bacterial count and enhanced granulation tissue formation (6–9). Scientific evidence regarding the effects in a sternotomy wound is still limited (10).

The present study was performed to explore to which extent negative pressure is transduced to the anterior portions of the heart and also to deeper locations in the sternotomy wound. We show that the pressure during TNP therapy is effectively delivered to the anterior portions of the heart. This may explain our recent findings that TNP at  $-50$  mmHg increases microvascular blood flow in the myocardium (10). The blood flow effects by TNP are believed to be through mechanical stress and a pressure gradient across the tissue, which causes a surge of blood to the area (8,9,12–14). TNP is known to stimulate blood flow to the wound edge that is exposed to negative pressure, while tissue further from the vacuum source remains unaffected (8,9). This is in accordance with the

current findings that pressure is not transduced far beyond the locations of the open-pore structure dressings of TNP therapy, for example to the pericardium (behind the heart), the pleura or the oesophagus.

The present results show negative pressure on the anterior portions of the heart, at similar levels as set on the vacuum source, while there is no negative pressure beneath the heart. This pressure difference may explain the finding that, upon the delivery of negative pressure, the anterior portion of the right ventricle is sucked up towards the anterior thoracic wall. The pressure causes the right ventricle to bulge into the space between the sternal edges, which deforms the anterior portion of the heart (15). We believe that this may have two negative effects.

First, pressure on the right ventricle may mechanically hinder venous return and cardiac pumping. Indeed, cardiac output and end diastolic volume are known to be slightly decreased upon application of negative pressure (15). Interestingly, interposition of four layers of paraffin gauze dressing over the heart during TNP therapy resulted in a lesser decrease in cardiac output (15). It is known that the interface dressings prevent the delivery of TNP (16).

Second, the pressure difference between the anterior and the posterior portions of the heart causes the right ventricle to be sucked up towards the posterior parts of the sternum where it might be exposed to the sharp edges of the sternal bone. This may result in right ventricle rupture, which is an uncommon but feared complication of TNP therapy in post-sternotomy mediastinitis (17). Development of TNP therapy for sternotomy wounds by facilitating pressure transduction to the bottom of the wound may be beneficial in hindering the strong suction force on the heart. It is known that motion between the sternal edges in combination with adherent heart structures to the thoracic wall are factors that predispose for heart rupture. It is important to use surgical techniques to minimise these risk factors (18). In summary, adherences below the sternal edges must be released, and three or four layers of interface dressing should be placed over the anterior portions of the heart in order to cover and protect visible parts of the right ventricle from the sternal edges. The interface dressing reduces the formation of adherences between the sternum and the right

ventricle, and the paraffin content facilitates movement.

In conclusion, the pressure over the anterior surface of the heart (under the foam) changed in a linear relationship with the applied negative pressure. These results may explain the positive effects on myocardial blood flow by TNP (10). Further down into the thoracic cavity, in the pericardium (under the heart), in the left pleura and in the oesophagus, the wound pressure was not affected by TNP therapy. The effect of negative pressure can therefore only be anticipated to be effective in superficial parts of the wound, for example on the sternotomy wound edges and on the anterior surface of the heart and not in deeper parts of the wound. The pressure difference between the anterior and the posterior portions of the heart during TNP therapy causes the right ventricle to be sucked up towards the posterior parts of the sternum where it might be exposed to the sharp edges of the sternal bone, which may result in heart injury.

## ACKNOWLEDGEMENTS

We thank Martin Ugander, MD, PhD, for valuable contribution to the manuscript. This study was supported by the Anders Otto Swärds Foundation/Ulrika Eklunds Foundation, Anna Lisa and Sven Eric Lundgrens Foundation for Medical Research, Åke Wiberg Foundation, the M. Bergvall Foundation, the Swedish Medical Association, the Royal Physiographic Society in Lund, the Swedish Medical Research Council, the Crafoord Foundation, the Swedish Heart-Lung Foundation, the Swedish Government Grant for Clinical Research and the Swedish Hypertension Society.

## REFERENCES

- 1 Raudat CW, Pagel J, Woodhall D, Wojtanowski M, Van Bergen R. Early intervention and aggressive management of infected median sternotomy incision: a review of 2242 open-heart procedures. *Am Surg* 1997;63:238–41; discussion 241–2.
- 2 El Oakley RM, Wright JE. Postoperative mediastinitis: classification and management. *Ann Thorac Surg* 1996;61:1030–6.
- 3 Crabtree TD, Codd JE, Fraser VJ, Bailey MS, Olsen MA, Damiano RJ Jr. Multivariate analysis of risk factors for deep and superficial sternal infection after coronary artery bypass grafting at a tertiary care medical center. *Semin Thorac Cardiovasc Surg* 2004;16:53–61.

## Key Points

- the effect of negative pressure can therefore only be anticipated to be effective in superficial parts of the wound, for example on the sternotomy wound edges and on the anterior surface of the heart and not in deeper parts of the wound
- the pressure difference between the anterior and the posterior portions of the heart during TNP therapy causes the right ventricle to be sucked up towards the posterior parts of the sternum where it might be exposed to the sharp edges of the sternal bone, which may result in heart rupture

- 4 Lu JC, Grayson AD, Jha P, Srinivasan AK, Fabri BM. Risk factors for sternal wound infection and mid-term survival following coronary artery bypass surgery. *Eur J Cardiothorac Surg* 2003;23: 943–9.
- 5 Obdeijn MC, de Lange MY, Lichtendahl DH, de Boer WJ. Vacuum-assisted closure in the treatment of poststernotomy mediastinitis. *Ann Thorac Surg* 1999;68:2358–60.
- 6 Sjogren J, Gustafsson R, Nilsson J, Malmso M, Ingemansson R. Clinical outcome after poststernotomy mediastinitis: vacuum-assisted closure versus conventional treatment. *Ann Thorac Surg* 2005;79:2049–55.
- 7 Morykwas MJ, Argenta LC, Shelton-Brown EI, McGuirt W. Vacuum-assisted closure: a new method for wound control and treatment: animal studies and basic foundation. *Ann Plast Surg* 1997; 38:553–62.
- 8 Wackenfors A, Gustafsson R, Sjogren J, Algotsson L, Ingemansson R, Malmso M. Blood flow responses in the peristernal thoracic wall during vacuum-assisted closure therapy. *Ann Thorac Surg* 2005;79:1724–30; discussion 1730–1.
- 9 Wackenfors A, Sjogren J, Gustafsson R, Algotsson L, Ingemansson R, Malmso M. Effects of vacuum-assisted closure therapy on inguinal wound edge microvascular blood flow. *Wound Repair Regen* 2004;12:600–6.
- 10 Lindstedt S, Malmso M, Ingemansson R. Blood flow changes in normal and ischemic myocardium during topically applied negative pressure. *Ann Thor Surg* 2007;84:568–573.
- 11 Petzina R, Gustafsson L, Mokhtari A, Ingemansson R, Malmso M. Effect of vacuum-assisted closure on blood flow in the peristernal thoracic wall after internal mammary artery harvesting. *Eur J Cardiothorac Surg* 2006;30:85–9.
- 12 Chen SZ, Li J, Li XY, Xu LS. Effects of vacuum-assisted closure on wound microcirculation: an experimental study. *Asian J Surg* 2005;28:211–7.
- 13 Fabian TS, Kaufman HJ, Lett ED, Thomas JB, Rawl DK, Lewis PL, Summitt JB, Merryman JI, Schaeffer TD, Sargent LA, Burns RP. The evaluation of subatmospheric pressure and hyperbaric oxygen in ischemic full-thickness wound healing. *Am Surg* 2000;66:1136–43.
- 14 Fleck TM, Fleck M, Moidl R, Czerny M, Koller R, Giovanoli P, Hiesmayer MJ, Zimpfer D, Wolner E, Grabenwoger M. The vacuum-assisted closure system for the treatment of deep sternal wound infections after cardiac surgery. *Ann Thorac Surg* 2002;74:1596–600; discussion 1600.
- 15 Petzina R, Ugander M, Gustafsson L, Engblom H, Sjogren J, Hetzer R, Ingemansson R, Arheden H, Malmso M. Hemodynamic effects of vacuum-assisted closure therapy in cardiac surgery, assessment using magnetic resonance imaging. *J Thorac Cardiothorac Surg* 2007;133:1154–1162.
- 16 Jones SM, Banwell PE, Shakespeare PG. Interface dressings influence the delivery of topical negative-pressure therapy. *Plast Reconstr Surg* 2005;116: 1023–8.
- 17 Abu-Omar Y, Naik MJ, Catarino PA, Ratnatunga C. Right ventricular rupture during use of high-pressure suction drainage in the management of poststernotomy mediastinitis. *Ann Thorac Surg* 2003;76:974; author reply 974–5.
- 18 Gustafsson RI, Sjogren J, Ingemansson R. Deep sternal wound infection: a sternal-sparing technique with vacuum-assisted closure therapy. *Ann Thorac Surg* 2003;76:2048–53; discussion 2053.

## Paper II



## Institutional report - Cardiac general

# Sympathetic and sensory nerve activation during negative pressure therapy of sternotomy wounds<sup>☆</sup>

Christian Torbrand<sup>a</sup>, Angelica Wackenfors<sup>a</sup>, Sandra Lindstedt<sup>c</sup>, Rolf Ekman<sup>b</sup>, Richard Ingemansson<sup>c</sup>,  
Malin Malmström<sup>a,\*</sup>

<sup>a</sup>Department of Medicine, Lund University Hospital, Lund, Sweden

<sup>b</sup>Department of Psychiatry and Neurochemistry, Institute of Neuroscience and Physiology, The Sahlgrenska Academy at University of Gothenburg, Mölndal, Sweden

<sup>c</sup>Department of Cardiothoracic Surgery, Lund University Hospital, Lund, Sweden

Received 15 April 2008; received in revised form 22 July 2008; accepted 22 July 2008

### Abstract

Negative pressure wound therapy (NPWT) has been adopted as the first-line treatment for poststernotomy mediastinitis as a result of the excellent clinical outcome. The knowledge concerning the effects of NPWT on the cardiovascular system and homeostasis is still limited. The aim of the present study was to investigate whether the plasma levels of neurohormones change during NPWT. Six pigs underwent median sternotomy followed by NPWT at –125 mmHg. The plasma levels of noradrenaline, adrenaline, neuropeptide Y, substance P, vasoactive intestinal peptide (VIP), and calcitonin gene-related peptide (CGRP) were determined before (0 min) and 5, 20, 60 and 180 min after the application of NPWT. The results show a transient increase in the plasma levels of noradrenaline and adrenaline when NPWT was applied. The plasma level of the adrenergic co-transmitter neuropeptide Y was higher in NPWT – than in sham-treated pigs, after 180 min of negative pressure. After 180 min of NPWT there was an increase in the plasma levels of the sensory nerve transmitter substance P, while no such effect was observed for CGRP or VIP. In conclusion, the results suggest sympathetic nerve activation during NPWT. This may be the result of an increase in workload on the heart during the initial phase of NPWT.

© 2008 Published by European Association for Cardio-Thoracic Surgery. All rights reserved.

**Keywords:** Experimental surgery; Mediastinal infection; Wound healing; Noradrenaline; Adrenaline

### 1. Introduction

Negative pressure wound therapy (NPWT) has remarkable effects on the healing of chronic and difficult wounds and has drastically reduced the mortality in poststernotomy mediastinitis following cardiac surgery. The technique entails application of negative pressure to a sealed, airtight wound. The suction force created by the subatmospheric pressure enables the drainage of excessive fluid and debris, which leads to the removal of wound edema, reduction in bacterial count and enhanced granulation tissue formation [1, 2]. Knowledge of the effects of NPWT in a sternotomy wound is limited [1]. The organs in the mediastinum are hemodynamically crucial and both vulnerable bypass grafts and reduced cardiac function should be taken into consideration during NPWT of sternotomy wounds.

Recent publications have reported right ventricular rupture during NPWT in cardiac surgery [3]. Also, reduced cardiac output during NPWT has been reported [4]. No study has yet been performed to examine the effect of NPWT on neurohormones, many of which are considered to be released upon increased cardiac load. In the present study, we analyzed the plasma levels of noradrenaline, adrenaline, neuropeptide Y, substance P, vasoactive intestinal peptide (VIP), and calcitonin gene-related peptide (CGRP).

Noradrenaline is a transmitter that is released by the sympathetic nerve terminals. The sympathetic nervous system also acts on the adrenal medulla to release catecholamines including adrenaline and, to a lesser extent, noradrenaline. Neuropeptide Y is co-localized with norepinephrine in sympathetic nerve terminals and is released when the rate of nerve firing is high [5]. Neuropeptide Y enhances the effects of noradrenaline and accounts for the long-lasting effects of sympathetic nerve transmission [5]. Sympathetic nerve activation results in increased cardiac pumping, sodium retention via the kidneys and constriction and hypertrophic effects on the peripheral vasculature.

VIP is a co-transmitter in parasympathetic nerves [6]. It is involved in the autonomic regulation of the cardiovascular system, where it exerts positive inotropic and chron-

<sup>☆</sup> This study was supported by the Anders Otto Swärd Foundation/Ulrika Eklund Foundation, Anna Lisa and Sven Eric Lundgren's Foundation for Medical Research, the Åke Wiberg Foundation, the M. Bergvall Foundation, the Swedish Medical Association, the Royal Physiographic Society in Lund, the Swedish Medical Research Council, the Crafoord Foundation, the Swedish Heart-Lung Foundation, the Swedish Government Grant for Clinical Research and the Swedish Hypertension Society.

\*Corresponding author. Associate Professor, Vascular Research, Lund University, BMC A13, SE-221 84 Lund, Sweden. Tel.: +46 733 565650, fax: +46 46 222 0616.

E-mail address: malin.malmstrom@med.lu.se (M. Malmström).

otropic effects, and causes coronary vasodilatation. Substance P and CGRP are released from primary afferent neurons and act in the periphery to stimulate vasodilatation and promote inflammation [7]. This mechanism, known as 'neurogenic inflammation', amplifies and sustains an inflammatory reaction.

In the present study, the effects of NPWT on the plasma levels of neurohormones were examined in a pig sternotomy wound model. Noradrenaline, adrenaline, neuropeptide Y, VIP, substance P and CGRP were analysed before (0 min) and after 5, 20, 60 and 180 min of NPWT at  $-125$  mmHg.

## 2. Material and methods

### 2.1. Animals

An uninfected porcine sternotomy wound model was used in the present study. Twelve domestic Landrace pigs of both genders, with a mean body weight of 70 kg, were fasted overnight with free access to water. The study was approved by the Ethics Committee for Animal Research, Lund University, Sweden. All animals received humane care in compliance with the European Convention on Animal Care.

### 2.2. Anesthesia

The pigs were premedicated with an intramuscular injection of ketamine (Ketaminol Vet™ 100 mg/ml, 15 mg/kg body weight, Farmaceutici Gellini SpA, Aprilia, Italy) in combination with xylazine (Rompun Vet™, 2 mg/kg body weight; Bayer AG; Leverkusen, Germany). Anesthesia was maintained by continuous intravenous infusion of propofol (Diprivan™; 0.1–0.2 mg/kg body weight/min, Astra Zeneca; Sweden) in combination with fentanyl (Leptanal™; 0.02 µg/kg body weight, Lilly, France) and atracurium besylate (Tracrium™; 0.2–0.5 mg/kg body weight, Glaxo, Täby, Sweden). The pigs were mechanically ventilated with a Siemens-Elema 900B ventilator in the volume-controlled mode.

### 2.3. Surgical procedure

A midline sternotomy was performed and the pericardium was opened. The sternotomy wound was prepared for NPWT. A polyurethane foam dressing was placed between the sternal edges and two non-collapsible drainage tubes were inserted into the foam. The open wound was then sealed with a transparent adhesive drape. The drainage tubes were connected to a purpose-built vacuum source (VAC® pump unit, KCI, Copenhagen, Denmark). The vacuum source was set to deliver a continuous negative pressure of  $-125$  mmHg. The group of control pigs was surgically prepared as described above (sham-treated), but no negative pressure was applied.

### 2.4. Biochemical analysis of neurohormones

The plasma levels of CGRP, neuropeptide Y, substance P, VIP, adrenaline and noradrenaline were analyzed, as described previously [8–10].

### 2.5. Calculations and statistics

Results were obtained from six sham-treated and six NPWT-treated pigs. Statistical analysis was performed using Students' *t*-test. Significance was defined as  $P < 0.05$ . The results are presented as mean values  $\pm$  the standard error on the mean (S.E.M.).

## 3. Results

The levels of noradrenaline and adrenaline were found to be higher in NPWT-treated than in sham-treated pigs after 20 min of negative pressure therapy at  $-125$  mmHg. This elevation was transient and after 60 and 180 min, respectively, the levels of noradrenaline and adrenaline were similar in NPWT- and sham-treated pigs (Fig. 1).

The plasma levels of neuropeptide Y were similar in NPWT- and sham-treated pigs at the beginning of NPWT. The levels then declined in both sham-treated and NPWT-treated pigs, but the decline was considerably slower in the NPWT-treated pigs, and after 180 min of negative pressure therapy, the plasma levels of neuropeptide Y were significantly higher in the NPWT-treated than in the sham-treated pigs (Fig. 1).

After 180 min of NPWT there was an increase in the plasma levels of substance P (Fig. 2). No such difference was observed for CGRP of VIP.

## 4. Discussion

### 4.1. Effects of NPWT on neurohormones

The experiment in the present study was performed in an experimental model of sternotomy wound. In the clinic, there are different approaches to treat mediastinitis; either the sternotomy is reopened and the NPWT is applied between the sternum bone edges and the soft tissue, and the wound filler will thereby be in direct contact with the heart, or only the soft tissue parts of the wound is reopened for NPWT. In the cases when the whole sternotomy wound is opened, negative pressure therapy is in direct communication with the heart. This is the setup used for the current experiments.

Following the application of NPWT, the plasma levels of noradrenaline and adrenaline were elevated. These are sympathetic nervous system transmitters and are known to be released upon increased cardiac workload [11]. Recent reports show that NPWT decreases cardiac pumping efficiency [4], while MRI measurements have revealed that the heart is drawn up towards the anterior thoracic wall and is mechanically deformed when NPWT is applied [12]. Taken together, these findings suggest that NPWT results in increased cardiac workload. The strain placed on the heart by NPWT may thus result in compensatory increases in sympathetic nerve activity. Indeed, numerous studies report elevated noradrenaline and adrenaline plasma levels in patients with heart failure, and these have been proposed as suitable biomarkers [13].

Neuropeptide Y is a co-transmitter of sympathetic nerves and is released at high rates of nerve firing [5]. In the present study, the plasma levels of neuropeptide Y were initially similar, but with increasing duration of NPWT, the

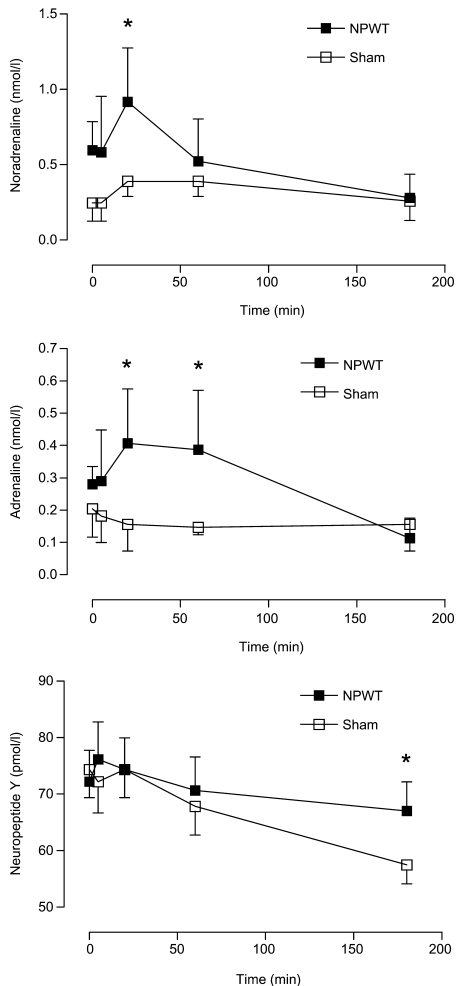


Fig. 1. The plasma levels of noradrenaline, adrenaline and neuropeptide Y in pigs subjected to negative pressure wound therapy at  $-125$  mmHg (NPWT) and sham-treated pigs (Sham). The results are presented as mean values  $\pm$  S.E.M. from six experiments. Statistical analysis was performed using Students' *t*-test. Significance was defined as  $P < 0.05$  (\*). Note that the levels of noradrenaline and adrenaline are initially increased and then decline, and then followed by a slight increase in the levels of neuropeptide Y.

levels were higher in the NPWT-treated than in the sham-treated pigs. This is in accordance with the general belief that neuropeptide Y is responsible for the long-lasting effects of sympathetic nerve activity [5]. The maintained high plasma levels of neuropeptide Y in the NPWT-treated pigs may be a consequence of the stress placed on the heart by the application of negative pressure [4, 14].

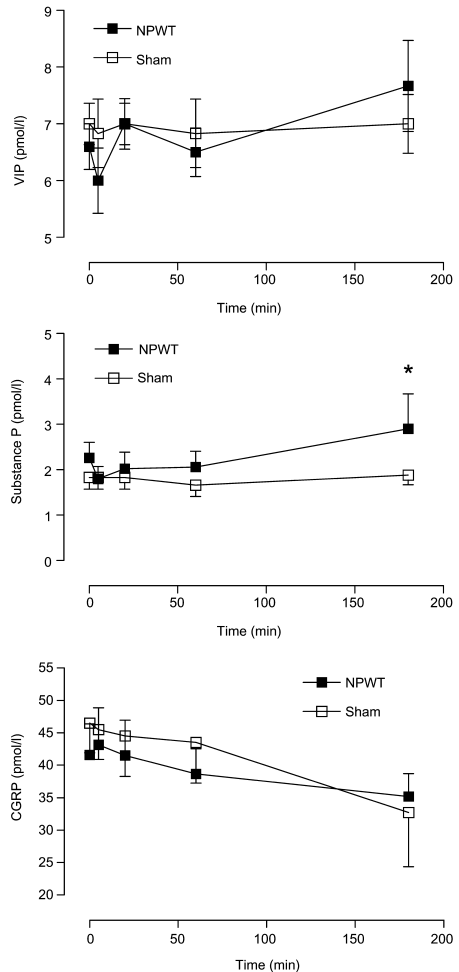


Fig. 2. The plasma levels of VIP, substance P and CGRP in pigs treated with negative pressure wound therapy at  $-125$  mmHg (NPWT) and sham-treated pigs. The results are presented as mean values  $\pm$  S.E.M. from six experiments. Statistical analysis was performed using Students' *t*-test. Significance was defined as  $P < 0.05$  (\*).

Indeed, plasma levels of neuropeptide Y are known to be high during sympathetic activation in stress-related cardiac conditions [15]. There was a steady decline in neuropeptide Y levels in the sham-treated pigs. Neuropeptide Y levels are presumably high during surgery, as a result of the trauma, and when surgery is completed, the neuropeptide Y levels decline.



#### 4.2. Transient increases in noradrenaline and adrenaline levels

The increase in noradrenaline and adrenaline plasma levels upon the application of NPWT was transient and after 60 and 180 min, respectively, the levels were similar to baseline values. The increase in noradrenaline and adrenaline may be the result of decreased cardiac output, which is known to occur immediately after the application of NPWT [4]. No study has yet been performed to analyze the long-term effects of NPWT on cardiac pumping. The changes in noradrenaline and adrenaline plasma levels may be transient because the decrease in cardiac output is transient, or may be the result of the body acclimatizing to slightly reduced cardiac output levels.

#### 4.3. Sensory nerve activation

Substance P is released from primary afferent sensory nerves upon stimulation [7]. The plasma levels of substance P were increased after 180 min of NPWT. This may be due to the sensory nerve stimulation by the negative pressure on the wound edge. It is well known that NPWT causes a mechanical deformation of the tissue in the wound edge and shearing forces at the foam – wound interface [2]. This is presumably the reason for why some patients experience pain during NPWT.

#### 4.4. Other levels of negative pressure

In the present study, we used a negative pressure level of –125 mmHg, since this is commonly used in clinical practice. The effects of other negative pressure levels on the release of neurohormones cannot be deduced from the results of the present study. However, we have previously shown that –75, –125, and –175 have similar effects on cardiac pumping [4], and we therefore believe that these levels of negative pressure may have similar effects on the release of neurohormones.

### 5. Conclusions

The results of the present study show elevated plasma levels of noradrenaline and adrenaline upon NPWT application, followed by an increase in neuropeptide Y. This enhanced sympathetic nerve activity may be the result of the increased cardiac workload on the heart during the initial phase of NPWT. However, the increase in catecholamine levels is only transient, suggesting that the body acclimatizes to negative pressure therapy. The results also show increased sensory nerve activation during NPWT. This

may be a result of the mechanical deformation of the wound edge tissue and shearing forces at the foam – wound interface during NPWT.

### References

- [1] Malmjsjo M, Ingemansson R, Sjogren J. Mechanisms governing the effects of vacuum-assisted closure in cardiac surgery. *Plast Reconstr Surg* 2007; 120:1266–1275.
- [2] Morykwas MJ, Simpson J, Pungler K, Argenta A, Kremers L, Argenta J. Vacuum-assisted closure: state of basic research and physiologic foundation. *Plast Reconstr Surg* 2006;117(7 Suppl):1215–1265.
- [3] Abu-Omar Y, Naik MJ, Catarino PA, Ratnatunga C. Right ventricular rupture during use of high-pressure suction drainage in the management of poststernotomy mediastinitis. *Ann Thorac Surg* 2003;76:974; author reply 974–975.
- [4] Petzina R, Ugander M, Gustafsson L, Engblom H, Sjogren J, Hetzer R, Ingemansson R, Arheden H, Malmjsjo M. Hemodynamic effects of vacuum-assisted closure therapy in cardiac surgery: assessment using magnetic resonance imaging. *J Thorac Cardiovasc Surg* 2007;133:1154–1162.
- [5] Lundberg JM, Franco-Cereceda A, Lacroix JS, Pernow J. Neuropeptide Y and sympathetic neurotransmission. *Ann NY Acad Sci* 1990;611:166–174.
- [6] Lucia P, Caiola S, Coppola A, Manetti LL, Maroccia E, Buongiorno AM, De Martinis C. Vasoactive intestinal peptide (VIP): a new neuroendocrine marker of clinical progression in chronic heart failure? *Clin Endocrinol (Oxf)* 2003;59:723–727.
- [7] Wallengren J. Vasoactive peptides in the skin. *J Invest Dermatol Symp Proc* 1997;2:49–55.
- [8] Edvinsson L, Ekman R, Thulin T. Reduced levels of calcitonin gene-related peptide (CGRP) but not substance P during and after treatment of severe hypertension in man. *J Human Hypertension* 1989;3:267–270.
- [9] Edvinsson L, Ekman R, Thulin T. Increased plasma levels of neuropeptide Y-like immunoreactivity and catecholamines in severe hypertension remain after treatment to normotension in man. *Regul Pept* 1991; 32:279–287.
- [10] van der Hoorn F, Boomsma F, Man in't Veld A. Determination of catecholamines in human plasma by high-performance liquid chromatography: Comparison between a new method with fluorescence detection and an established method with electrochemical detection. *J Chromatogr* 1989;487:17–28.
- [11] Milano CA, Kesler K, Archibald N, Sexton DJ, Jones RH. Mediastinitis after coronary artery bypass graft surgery. Risk factors and long-term survival. *Circulation* 1995;92:2245–2251.
- [12] Malmjsjo M, Petzina R, Ugander M, Engblom H, Gustafsson L, Mokhtari A, Hetzer R, Arheden H, Ingemansson R. Preventing heart injury during topical negative pressure therapy in cardiac surgery – assessment using real time MRI. *J Thorac Cardiovasc Surg* (in press).
- [13] Macabasco-O'Connell A, Miller PS. Biomarkers for heart failure. *Prog Cardiovasc Nurs* 2006;21:215–218.
- [14] Conquest AM, Garofalo JH, Maziarz DM, Mendelson KG, Su Sun Y, Wooden WA, Meadows WM, Nifong W, Chitwood WR. Hemodynamic effects of the vacuum-assisted closure device on open mediastinal wounds. *J Surg Res* 2003;115:209–213.
- [15] McDermott BJ, Bell D. NPY and cardiac diseases. *Curr Top Med Chem* 2007;7:1692–1703.

## Paper III



# Changes in cardiac pumping efficiency and intra-thoracic organ volume during negative pressure wound therapy of sternotomy wounds, assessment using magnetic resonance imaging

Christian Torbrand, Martin Ugander, Henrik Engblom, Göran K Olivecrona, Olof Gålne, Håkan Arheden, Richard Ingemansson, Malin Malmström

Torbrand C, Ugander M, Engblom H, Olivecrona GK, Gålne O, Arheden H, Ingemansson R, Malmström M. Changes in cardiac pumping efficiency and intra-thoracic organ volume during negative pressure wound therapy of sternotomy wounds, assessment using magnetic resonance imaging. *Int Wound J* 2010; 7:305–311

## ABSTRACT

Knowledge on the effects of negative pressure wound therapy (NPWT) on the intra-thoracic organs is limited. The present study was performed to investigate the effects of NPWT on the volume of the intra-thoracic organs, using magnetic resonance imaging (MRI), in a porcine sternotomy wound model. Six pigs underwent median sternotomy followed by NPWT at  $-75$ ,  $-125$  and  $-175$  mmHg. Six pigs were not sternotomised. MR images covering the thorax and heart were acquired. The volumes of the thoracic cavity, lungs, wound fluid and heart were then determined. The volumes of the thoracic cavity and intra-thoracic organs increased after sternotomy and decreased upon NPWT application. The total heart volume variation, which is inversely related to cardiac pumping efficiency, was higher after sternotomy and decreased during NPWT. NPWT did not result in the evacuation of wound fluid from the bottom of the wound. NPWT largely closes and restores the thoracic cavity. Cardiac pumping efficiency returns to pre-sternotomy levels during NPWT. This may contribute to the clinical benefits of NPWT over open-chest care, including the stabilizing effects and the reduced need for mechanical ventilation.

**Key words:** Experimental surgery • Negative pressure wound therapy • Post-sternotomy mediastinitis • Sternotomy wound • Wound healing

**Authors:** C Torbrand, Department of Ophthalmology, Lund University Hospital, Lund, Sweden; M Ugander, Department of Clinical Physiology, Lund University Hospital, Lund, Sweden; H Engblom, Department of Clinical Physiology, Lund University Hospital, Lund, Sweden; GK Olivecrona, Department of Cardiology, Lund University Hospital, Lund, Sweden; O Gålne, Department of Ophthalmology, Lund University Hospital, Lund, Sweden; H Arheden, Department of Clinical Physiology, Lund University Hospital, Lund, Sweden; R Ingemansson, Department of Cardiothoracic Surgery, Lund University Hospital, Lund, Sweden; M Malmström, MD, PhD, Department of Ophthalmology, Lund University Hospital, Lund, Sweden and Vascular Research, Lund University, BMC A13, SE-221 84 Lund, Sweden

**Address for correspondence:** M Malmström, MD, PhD, Vascular Research, Lund University, BMC A13, SE-221 84 Lund, Sweden

**E-mail:** malin.malmstrom@med.lu.se

### Key Points

- scientific evidence regarding the mechanisms by which NPWT promotes wound healing has started to emerge
- studies on the lung function have shown better ventilation during NPWT than during conventional open-chest care, presumably because of the sternum-stabilising effect and the reduced need for mechanical ventilation
- the aim of the present study was to examine the effects of NPWT on the cardiac pumping efficiency and the volumes of the intra-thoracic organs
- an uninfected porcine sternotomy wound model was used in the present study
- six pigs underwent sternotomy and NPWT while six pigs were not sternotomised
- after surgery, the pigs were transported from the operating room to the MRI scanner

## INTRODUCTION

Cardiac surgery is complicated by post-sternotomy mediastinitis in 1–5% of all procedures and is a life-threatening complication. The reported early mortality in post-sternotomy mediastinitis following coronary bypass graft surgery is between 8% and 25%. Traditional treatment of post-sternotomy mediastinitis includes surgical debridement, drainage, irrigation and reconstruction using pectoral muscle flaps or omentum transposition. Post-sternotomy mediastinitis can also be treated by negative pressure wound therapy (NPWT) based on the principle of applying sub-atmospheric pressure by controlled suction through a porous dressing. NPWT has resulted in reduced mortality in post-sternotomy mediastinitis (1).

Scientific evidence regarding the mechanisms by which NPWT promotes wound healing has started to emerge. The suction force created by NPWT has been found to alter the micro-vascular wound edge blood flow and stimulate granulation tissue formation and the removal of bacteria (2). However, knowledge of the effects of NPWT on the intra-thoracic organs is still limited (2). The organs in the mediastinum are vital and the heart and lung function need to be taken into consideration during NPWT. Studies on the lung function have shown better ventilation during NPWT than during conventional open-chest care (3,4), presumably because of the sternum-stabilising effect and the reduced need for mechanical ventilation. Conversely, a decrease in cardiac output has been reported during NPWT when compared with the open-chest situation (5,6). However, the effect of NPWT on cardiac output has hitherto only been studied in sternotomised pigs and no comparison has yet been made with non-sternotomised pigs (intact chest).

The aim of the present study was to examine the effects of NPWT on the cardiac pumping efficiency and the volumes of the intra-thoracic organs. Magnetic resonance imaging (MRI) was performed on non-sternotomised pigs and sternotomised pigs before and after the application of NPWT at  $-75$ ,  $-125$  and  $-175$  mmHg. Thereafter, the volumes of the thoracic cavity, heart, lungs and wound fluid were measured. Furthermore, the effects of NPWT on total heart volume variation (THVV), which is inversely related to cardiac pumping efficiency, were examined.

## MATERIALS AND METHODS

### Animals

An uninfected porcine sternotomy wound model was used in the present study. Twelve domestic landrace pigs of both genders, with a mean body weight of 50 kg, were fasted overnight with free access to water. The study was approved by the Ethics Committee for Animal Research, Lund University, Sweden. The investigation complied with the 'Guide for the Care and Use of Laboratory Animals' as recommended by the U.S. National Institutes of Health (1996). The pigs were anaesthetised as described previously (6,7).

### Surgical procedure

Six pigs underwent sternotomy and NPWT while six pigs were not sternotomised. A midline sternotomy was performed and the pericardium and pleurae were opened. The sternotomy wound was prepared for NPWT. A polyurethane foam dressing was placed between the sternal edges and two non-collapsible drainage tubes were inserted into the foam. The open wound was then sealed with a transparent adhesive drape. The drainage tubes were connected to a vacuum source (VAC<sup>®</sup> pump unit, KCI, Copenhagen, Denmark), which was set to deliver a continuous negative pressure of  $-75$ ,  $-125$  or  $-175$  mmHg.

### Magnetic resonance imaging

After surgery, the pigs were transported from the operating room to the MRI scanner. MRI was first performed at baseline (0 mmHg). A negative pressure was then applied and MRI was performed when the target pressure had been reached. This procedure was repeated for each negative pressure ( $-75$ ,  $-125$  and  $-175$  mmHg). In order to eliminate time effects, the sequence of application of the three different negative pressures was varied between the animals using a 3 by 3 Latin square design.

MRI was conducted using a 1.5T system (Philips Medical Systems, Best, the Netherlands) with a five-element cardiac coil and the pig in the supine position. All imaging was performed using steady-state free precession sequences. A survey scan was acquired including sagittal images. Typical imaging parameters were: spatial resolution  $1.8 \times 1.8$  mm, slice thickness 10 mm.

All subsequent images were acquired during ventilator-controlled end expiratory apnea at the functional residual lung capacity. Images of the thoracic anatomy were acquired in the transverse and sagittal planes, covering the entire thoracic cavity. Typical imaging parameters were: spatial resolution 1.1–1.5 × 1.1–1.5 mm, slice thickness 5–8 mm.

The heart was imaged in the short-axis, and two-, three- and four-chamber long-axis planes. Typical imaging parameters were: spatial resolution 1.4 × 1.4 mm, slice thickness 8 mm, retrospective electrocardiogram (ECG) triggering, temporal resolution 30 ms.

### MRI analysis

All images were evaluated using freely available software (Segment 1.699 <http://segment.heiberg.se>,13). Intra-thoracic volume measurements were performed in transverse images with simultaneous viewing of sagittal images and image plane inter-sections for orientation. The right lung, left lung, intra-thoracic wound fluid and total thoracic areas were manually delineated by defining dedicated regions of interest in all transverse images (Figure 1). For the non-sternotomised pigs, the intra-thoracic volumes had been imaged with ECG triggering. Quantification was performed in the first time frame at 0 ms in relation to the R-wave of the ECG.

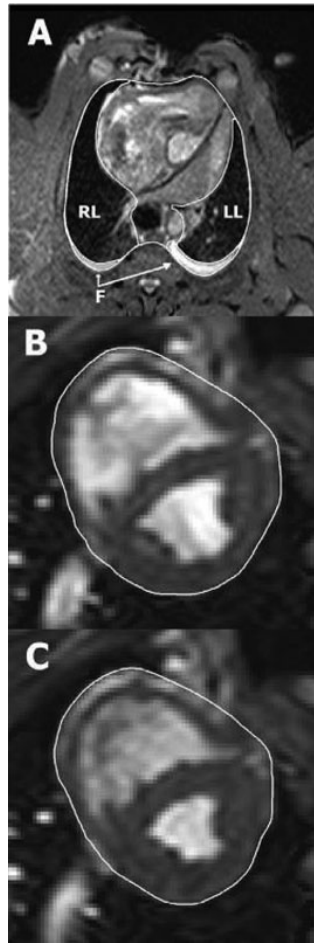
The THV was measured by manually delineating the pericardial border of the heart in short-axis images (Figure 1) in both end diastole and end systole, as previously described (7). Long-axis images and image plane inter-sections were viewed simultaneously for orientation. The THVV, expressed in percent, was calculated according to the following formula:

$THVV(\%) = [(THV \text{ in end diastole} - THV \text{ in end systole}) / THV \text{ in end diastole}] \times 100$ .

The non-sternotomised pigs were different animals than the sternotomised pigs. In order to determine whether or not the pigs were similar in size, the distance between ten vertebrae was measured in a mid-sagittal survey MRI image in all pigs.

### Calculations and statistics

The experiments were performed on six sternotomised and six non-sternotomised pigs. Statistical analysis was performed using Kruskal-Wallis test with Dunn's post-test for multiple comparisons. Significance was



**Figure 1.** Illustration of manual delineation of organ volumes. Image (A) shows how the intra-thoracic structures were outlined in a transverse magnetic resonance (MR) image through the thorax of a pig with an open sternotomy wound. The right lung (RL), left lung (LL) and intra-thoracic fluid (F) were delineated in each image throughout the entire thorax, allowing the volume of each structure to be quantified. Images (B) and (C) show short-axis MR images of the same animal's heart in end diastole and end systole, respectively. The pericardial border of the heart was manually delineated in all short-axis slices covering the entire volume within the pericardium. The total heart volume in end diastole and end systole, as well as the total heart volume variation throughout the cardiac cycle, was then quantified.

### Key Points

- upon the application of NPWT, the volume of the total thoracic cavity and intra-thoracic organs was reduced
- when NPWT was applied, the THVV decreased
- the application of negative pressure did not decrease the amount of free fluid at the bottom of the thoracic cavity
- in order to determine whether the non sternotomised pigs and the sternotomised pigs were of similar size, the distance between ten vertebrae was measured

defined as  $P < 0.05$ . The results are presented as mean values  $\pm$  the standard error on the mean.

## RESULTS

### Intra-thoracic organ volume

The volume of the thoracic cavity and the intra-thoracic organs was greater in the sternotomised pigs than in the non-sternotomised pigs,  $P = 0.0414$  and  $P = 0.0217$ , respectively (Figures 2 and 3). The lung volume was larger in the sternotomised pigs,  $P = 0.1523$  for the right lung and  $P = 0.2810$  for the left lung (Figures 2 and 3). Upon the application of NPWT, the volume of the total thoracic cavity and intra-thoracic organs was reduced,  $P = 0.0192$  and  $P = 0.0188$ , respectively, when comparing 0 mmHg with  $-125$  mmHg (Figure 3). The lung volume was decreased when NPWT was applied,  $P = 0.0850$  for the right lung and  $P = 0.0520$  for the left lung, compared with 0 mmHg (Figures 2 and 3).

### Cardiac pumping efficiency

The THVV, which reflects cardiac pumping efficiency (7), increased following sternotomy,  $P = 0.1854$  (Figure 4). When NPWT was applied, the THVV decreased,  $P = 0.1568$  when comparing 0 mmHg with  $-125$  mmHg (Figure 4).

### Wound fluid

Wound fluid had accumulated in the bottom of the thoracic cavity, in the right and left pleura because these were opened during the surgical procedure. The application of negative pressure did not decrease the amount of free fluid at the bottom of the thoracic cavity,  $P > 0.30$  when comparing 0 mmHg with  $-125$  mmHg (Figure 5).

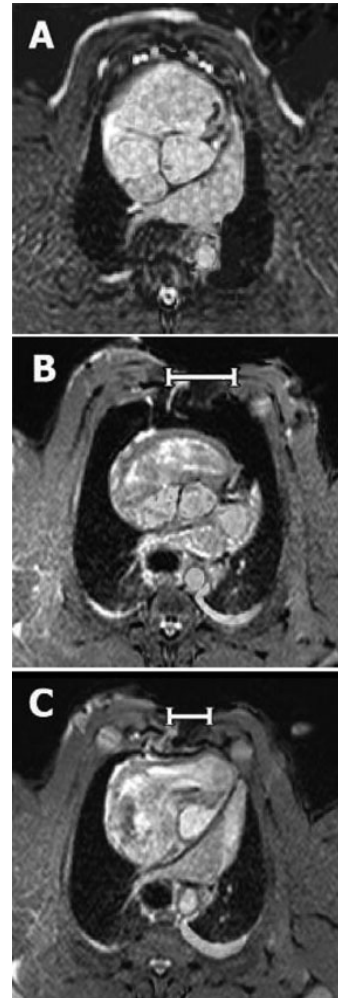### Pig size

In order to determine whether the non-sternotomised pigs and the sternotomised pigs were of similar size, the distance between ten vertebrae was measured. This distance was  $232 \pm 2$  mm in the sternotomised pigs and  $231 \pm 3$  mm in the non-sternotomised pigs ( $P > 0.30$ ), indicating similar pig size.

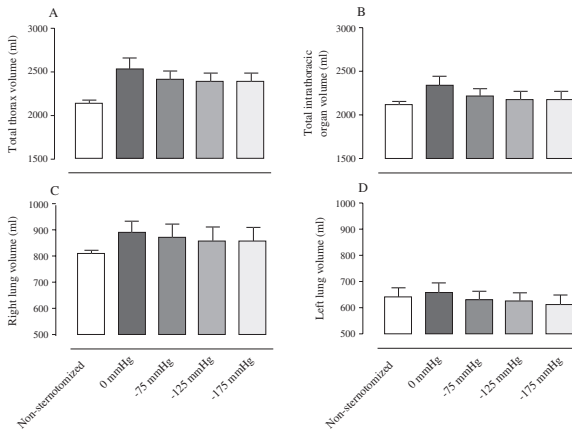
## DISCUSSION

### Intra-thoracic organ volume

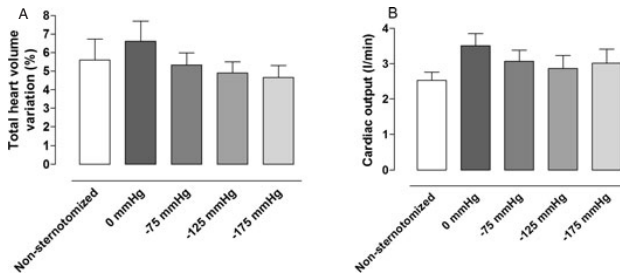
We found that the total volume of the intra-thoracic organs increases upon sternotomy.



**Figure 2.** Representative transverse MR images at the level of the aortic root selected from a stack of 50 contiguous 5-mm thick sections covering the entire thorax. The images were obtained from: (A) a non-sternotomised pig and (B) a sternotomised pig before (0 mmHg) and (C) after the application of  $-125$  mmHg. Note the differences in the size, shape and position of the intra-thoracic organs induced by sternotomy and topical negative pressure. In particular, note how negative pressure wound therapy draws the two sternal edges closer to each other (white bars), thereby decreasing the circumference of the thorax, making it similar to that of the non-sternotomised pig.



**Figure 3.** Volumes of: (A) the thoracic cavity, (B) the intra-thoracic organs, (C) right lung and (D) left lung, measured using MRI, in non-sternotomized pigs and in sternotomized pigs before (0 mmHg) and after the application of negative pressure wound therapy of  $-75$ ,  $-125$  and  $-175$  mmHg. The results are presented as mean values  $\pm$  standard error on the mean. Note how the volumes of the thorax and intra-thoracic organs decrease upon the application of negative pressure, most prominently upon the change from 0 to  $-75$  mmHg. Further increases in negative pressure only result in minor reduction in volume.



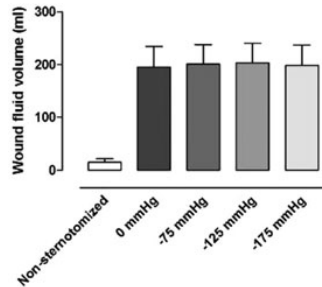
**Figure 4.** The (A) total heart volume variation and (B) cardiac output in non-sternotomized pigs and sternotomized pigs before and after the application of negative pressure wound therapy (NPWT) of  $-75$ ,  $-125$  and  $-175$  mmHg. The results are presented as mean values  $\pm$  standard error on the mean. Note that after sternotomy, the cardiac pumping efficiency appears to decrease (increase in total heart volume variation), and cardiac output increases, and these measures return to control levels upon application of NPWT.

We speculate that this reflects changes in the quantity of blood that collects in these organs as a result of a change in the pressure conditions. An alternative explanation of the increased lung volume may be that sternotomy results in increased end expiratory volumes of air in the lungs.

Upon application of NPWT, the volume of the thoracic cavity decreased. NPWT contracts the wound and draws the two sternal edges together, thereby decreasing the circumference of the thorax. Previous

studies have reported similar findings, that is, soft tissue wound contraction and 'macro-deformation' upon NPWT (8). During NPWT, air is evacuated from the thorax, decreasing the total intra-thoracic volume. NPWT thus largely restores the macroscopic anatomical conditions in the thorax, which may explain the clinical benefits of NPWT over open-chest care, including the stabilizing effects and the reduced need for mechanical ventilation (3,4).





**Figure 5.** The intra-thoracic wound fluid volume, measured using MRI, in non-sternotomised pigs and in sternotomised pigs before and after the application of negative pressure wound therapy (NPWT) at  $-75$ ,  $-125$  and  $-175$  mmHg. The results are presented as mean values  $\pm$  standard error on the mean. Note that NPWT does not result in the evacuation of fluid from the bottom of the wound.

The volume of the intra-thoracic organs decreases upon the application of NPWT, but does not return to pre-sternotomy levels. This may be explained by the fact that the NPWT foam acts as wound filler that separates the sternal edges, resulting in a larger thoracic cavity during NPWT than before sternotomy. Also, the open-heart surgery may have resulted in interstitial oedema, which may account for the organs being slightly enlarged.

### Key Points

- NPWT largely closes and restores the thoracic cavity
- this may contribute to the clinical benefits of NPWT over open-chest care, including the stabilizing effects and the reduced need for mechanical ventilation
- cardiac pumping efficiency decreased upon sternotomy and then returned to presternotomy values when the thorax was resealed by NPWT
- NPWT does not result in the evacuation of wound fluid from the bottom of the wound, presumably because the negative pressure is not transduced to the bottom of the wound
- however, NPWT is in full contact with the sternal bone edge, which may be crucial in resolving the bone infection in mediastinitis

### Cardiac pumping efficiency

The THVV, which may be regarded as a measure which inversely relates to heart pumping efficiency (7), increased after sternotomy. Upon the application of NPWT, the THVV decreased to values that are similar to those in the non-sternotomised pigs. A retrospective analysis of two previous studies suggests similar changes in cardiac output (6,9). Cardiac output is higher after sternotomy and then return to pre-sternotomy levels during NPWT. These findings are in accordance with previous reports. Cardiac output has been shown to increase upon sternotomy (10). The results suggest that this is a result of opening the thorax and pericardium, but the exact mechanism is unclear. Other reports show a decrease in cardiac output when the sternotomy wound is resealed during NPWT (5,6). Many have been concerned regarding the findings that cardiac output decreases during NPWT, and suggestions have been made of invasive monitoring

of haemodynamics. However, the results from the present study are reassuring and indicate that cardiac pumping efficiency returns to pre-sternotomy levels during NPWT.

### Wound fluid

Wound fluid is produced during surgery and there will thus be more fluid at the bottom of the thoracic cavity in the sternotomised pigs than in the non-sternotomised pigs. In the sternotomised pigs, NPWT did not decrease the amount of wound fluid in the bottom of the thoracic cavity. We have found that the negative pressure is not transduced to the bottom of the thoracic cavity (11), which may explain why the wound fluid is not evacuated. However, in the clinical situation the patient is mobilised. The wound fluid may then move around in the thoracic cavity and eventually come in contact with the foam and negative pressure and thereby be sucked out. However, drainage of the wound fluid from the thoracic cavity may not be crucial for resolving the mediastinitis. We believe that one of the most important issues in mediastinitis is the infection in the bone of the sternum. The NPWT dressing is in contact with the entire wound surface and the sternum bone is exposed to the negative pressure. We have shown previously that NPWT affects the fluid in the sternum (12). Presumably, fluid is drawn from the surrounding tissue to the sternum and into the vacuum source. This 'endogenous drainage' may be one possible mechanism by which osteitis is resolved by NPWT in post-sternotomy mediastinitis.

### Limitations of the study

The measurements in the sternotomised pigs were compared with those in the non-sternotomised pigs. We determined that the two groups of pigs were of similar size (vertebra distance). It is, therefore, unlikely the limitation of having different pigs in the two groups have affected the conclusions drawn from the study.

### Conclusions

NPWT largely closes and restores the thoracic cavity. This may contribute to the clinical benefits of NPWT over open-chest care, including the stabilizing effects and the reduced need for mechanical ventilation. The volume of the intra-thoracic organs increased

after sternotomy and decreased during NPWT. Similarly, cardiac output increased and cardiac pumping efficiency decreased upon sternotomy and then returned to pre-sternotomy values when the thorax was resealed by NPWT. NPWT does not result in the evacuation of wound fluid from the bottom of the wound, presumably because the negative pressure is not transduced to the bottom of the wound. However, NPWT is in full contact with the sternal bone edge, which may be crucial in resolving the bone infection in mediastinitis.

## REFERENCES

- 1 Sjogren J, Gustafsson R, Nilsson J, Malmso M, Ingemansson R. Clinical outcome after poststernotomy mediastinitis: vacuum-assisted closure versus conventional treatment. *Ann Thorac Surg* 2005;79:2049–55.
- 2 Malmso M, Ingemansson R, Sjogren J. Mechanisms governing the effects of vacuum-assisted closure in cardiac surgery. *Plast Reconstr Surg* 2007;120:1266–75.
- 3 Ramnarine IR, McLean A, Pollock JC. Vacuum-assisted closure in the paediatric patient with post-cardiotomy mediastinitis. *Eur J Cardiothorac Surg* 2002;22:1029–31.
- 4 Kutschka I, Frauendorfer P, Harringer W. Vacuum assisted closure therapy improves early post-operative lung function in patients with large sternal wounds. *Zentralbl Chir* 2004;129 Suppl 1:S33–4.
- 5 Conquest AM, Garofalo JH, Maziarz DM, Mendelson KG, Su Sun Y, Wooden WA, Meadows WM, Nifong W, Chitwood WR. Hemodynamic effects of the vacuum-assisted closure device on open mediastinal wounds. *J Surg Res* 2003;115:209–13.
- 6 Petzina R, Ugander M, Gustafsson L, Engblom H, Sjogren J, Hetzer R, Ingemansson R, Arheden H, Malmso M. Hemodynamic effects of vacuum-assisted closure therapy in cardiac surgery: assessment using magnetic resonance imaging. *J Thorac Cardiovasc Surg* 2007;133:1154–62.
- 7 Carlsson M, Cain P, Holmqvist C, Stahlberg F, Lundback S, Arheden H. Total heart volume variation throughout the cardiac cycle in humans. *Am J Physiol Heart Circ Physiol* 2004;287:H243–50.
- 8 Morykwas MJ, Simpson J, Pungner K, Argenta A, Kremers L, Argenta J. Vacuum-assisted closure: state of basic research and physiologic foundation. *Plast Reconstr Surg* 2006;117 Suppl 7:121S–6S.
- 9 Götberg M, Olivecrona G, Engblom H, Ugander M, van der Pals J, Heiberg E, Arheden H, Erlinge D. Rapid short-duration hypothermia before reperfusion reduces myocardial infarct size and microvascular obstruction in pigs. *BMC Cardiovascular Disorders*. In press.
- 10 Reuter DA, Goresch T, Goepfert MS, Wildhirt SM, Kilger E, Goetz AE. Effects of mid-line thoracotomy on the interaction between mechanical ventilation and cardiac filling during cardiac surgery. *Br J Anaesth* 2004;92:808–13.
- 11 Malmso M, Petzina R, Ugander M, Engblom H, Gustafsson L, Mokhtari A, Hetzer R, Arheden H, Ingemansson R. Preventing heart injury during topical negative pressure therapy in cardiac surgery – assessment using real time MRI. *J Thorac Cardiovasc Surg*. In press.
- 12 Petzina R, Ugander M, Gustafsson L, Engblom H, Hetzer R, Arheden H, Ingemansson R, Malmso M. Topical negative pressure therapy of a sternotomy wound increases sternal fluid content but does not affect internal mammary artery blood flow – assessment using MRI. *J Thorac Cardiovasc Surg*. In press.
- 13 Heiberg E, Sjogren J, Ugander M, Carlsson M, Engblom H, Arheden H. Design and Validation of Segment – freely available software for cardiovascular image analysis. *BMC Med Imaging* 2010;10:1.



## Paper IV





RESEARCH ARTICLE

Open Access

# Wound contraction and macro-deformation during negative pressure therapy of sternotomy wounds

Christian Torbrand<sup>1</sup>, Martin Ugander<sup>2</sup>, Henrik Engblom<sup>2</sup>, Håkan Arheden<sup>2</sup>, Richard Ingemansson<sup>3</sup>, Malin Malmström<sup>1\*</sup>

## Abstract

**Background:** Negative pressure wound therapy (NPWT) is believed to initiate granulation tissue formation via macro-deformation of the wound edge. However, only few studies have been performed to evaluate this hypothesis. The present study was performed to investigate the effects of NPWT on wound contraction and wound edge tissue deformation.

**Methods:** Six pigs underwent median sternotomy followed by magnetic resonance imaging in the transverse plane through the thorax and sternotomy wound during NPWT at 0, -75, -125 and -175 mmHg. The lateral width of the wound and anterior-posterior thickness of the wound edge was measured in the images.

**Results:** The sternotomy wound decreased in size following NPWT. The lateral width of the wound, at the level of the sternum bone, decreased from  $39 \pm 7$  mm to  $30 \pm 6$  mm at -125 mmHg ( $p = 0.0027$ ). The greatest decrease in wound width occurred when switching from 0 to -75 mmHg. The level of negative pressure did not affect wound contraction (sternum bone:  $32 \pm 6$  mm at -75 mmHg and  $29 \pm 6$  mm at -175 mmHg,  $p = 0.0897$ ). The decrease in lateral wound width during NPWT was greater in subcutaneous tissue ( $14 \pm 2$  mm) than in sternum bone ( $9 \pm 2$  mm), resulting in a ratio of  $1.7 \pm 0.3$  ( $p = 0.0423$ ), suggesting macro-deformation of the tissue. The anterior-posterior thicknesses of the soft tissue, at 0.5 and 2.5 cm laterally from the wound edge, were not affected by negative pressure.

**Conclusions:** NPWT contracts the wound and causes macro-deformation of the wound edge tissue. This shearing force in the tissue and at the wound-foam interface may be one of the mechanisms by which negative pressure delivery promotes granulation tissue formation and wound healing.

## Introduction

Cardiac surgery is complicated by post-sternotomy mediastinitis in 1% to 5% of all procedures [1] and is a life-threatening complication [2]. The reported early mortality in post-sternotomy mediastinitis following coronary artery bypass graft surgery is between 8% and 25% [3,4]. Conventional treatment of post-sternotomy mediastinitis includes surgical debridement, drainage, irrigation, and reconstruction using pectoral muscle flap or omentum transposition. In 1999, Obdeijn and colleagues described a new method of treatment for post-sternotomy mediastinitis using a vacuum-assisted closure technique [5],

which is based on the principle of applying subatmospheric pressure by controlled suction through a porous dressing. The technique, also known as negative pressure wound therapy (NPWT), has resulted in reduced mortality in post-sternotomy mediastinitis [6].

Scientific evidence regarding the mechanisms by which NPWT promotes wound healing has started to emerge. NPWT results in the drainage of excessive fluid and debris, removal of wound edema, reduction in bacterial counts and stimulation of wound edge microvascular blood flow [7-10]. However, it is now believed that one of the major driving forces that generate granulation tissue formation is the macro-deformation of the wound edge tissue that results from the suction force created by the negative pressure. To our knowledge, there is only sparse

\* Correspondence: malin.malmstrom@med.lu.se

<sup>1</sup>Department of Ophthalmology, Lund University and Skåne University Hospital, Lund, Sweden

Full list of author information is available at the end of the article



scientific evidence for this instantaneous mechanical effect by NPWT [11].

The present study was performed to in detail investigate the effects of NPWT on wound contraction and wound edge tissue deformation. Magnetic resonance imaging (MRI) of the thorax was performed in a porcine sternotomy wound model. The lateral width of the wound and anterior-posterior thickness of the wound edge was measured in the images taken before and after initiation of NPWT at -75, -125 and -175 mmHg.

## Materials and methods

### Animals

An uninfected porcine sternotomy wound model was used in the present study. Six domestic landrace pigs of both genders, with a mean body weight of 50 kg, were fasted overnight with free access to water. The study was approved by the Ethics Committee for Animal Research, Lund University, Sweden. The investigation complied with the "Guide for the Care and Use of Laboratory Animals" as recommended by the U.S. National Institutes of Health and published by the National Academies Press (1996).

### Anesthesia

Anesthesia was induced with ketamine hydrochloride (Ketaminol Vet™ 100 mg/ml, Farmaceutici Gellini S.p.A, Aprilia, Italy), 15 mg/kg intramuscularly, and xylazine (Rompun Vet™ 20 mg/mL, Bayer AG, Leverkusen, Germany), 2 mg/kg intramuscularly. The pigs were intubated and mechanical ventilation was established with a Siemens-Elema 900B ventilator in the volume-controlled mode. Anesthesia was maintained by continuous intravenous infusion of propofol (Diprivan™, Astra Zeneca, Sweden), 0.1-0.2 mg/kg/min, in combination with fentanyl (Leptanal™, Lilly, France), 0.05 µg/kg/min, and atracurium besylate (Tracrium™, Glaxo, Täby, Sweden), 0.2-0.5 mg/kg/hour.

### Surgical procedure

After a midline sternotomy, the pericardium was opened and a polyurethane foam dressing was placed between the sternal edges. Two non-collapsible drainage tubes were inserted into the foam. The open wound was then sealed with a transparent adhesive drape. The drainage tubes were connected to a purpose-built vacuum source (VAC® pump unit, KCI, Copenhagen, Denmark), which was set to deliver a continuous negative pressure of -75, -125 or -175 mmHg.

### Experimental procedure

MRI was first performed at baseline (0 mmHg). A negative pressure was then applied and MRI was performed when the target pressure had been reached. This procedure was

repeated for each negative pressure (-75, -125, and -175 mmHg). In order to eliminate time effects, the sequence of application of the three different negative pressures was varied between the animals using a 3 by 3 Latin square design.

### Magnetic resonance imaging

MRI was conducted using a 1.5T system (Intera CV, Philips Medical Systems, Best, the Netherlands) with a five-element cardiac coil and the pig in the supine position. The images were acquired during ventilator-controlled end expiratory apnea at the functional residual lung capacity. Images were acquired in the transverse and sagittal planes, covering the entire thoracic cavity using a steady-state free precession sequence. Typical imaging parameters were: spatial resolution 1.1 × 1.1 mm, slice thickness 5 mm, slice gap 0 mm, repetition time 3.1 ms, echo time 1.6 ms, flip angle 60°, no ECG triggering, sensitivity-encoding factor 2.

### Image analysis

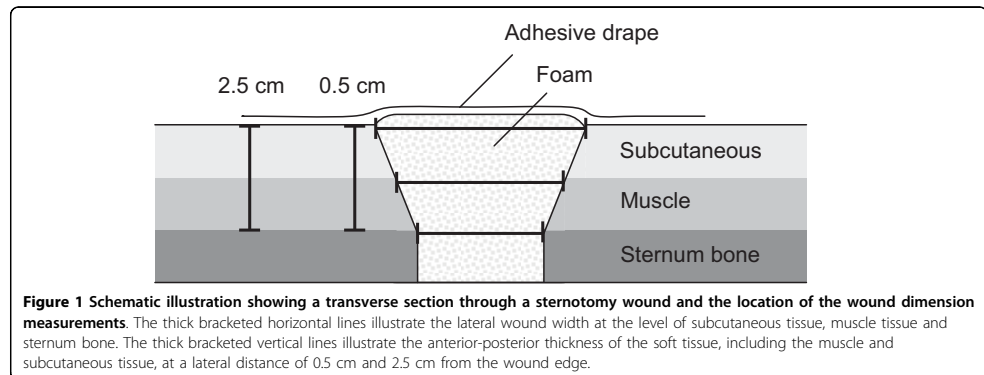
All images were evaluated using freely available software (Segment 1.699, available at <http://segment.heiberg.se>) [12]. Measurements of wound contraction and soft tissue macro-deformation were performed in the same transverse image at the cardiac midventricular level that were acquired before (0 mmHg) and after the application of -75, -125 and -175 mmHg. The distance between the two wound edges of subcutaneous tissue, muscle tissue and sternum bone were measured (lateral wound width). The anterior-posterior thickness of the soft tissue, including the subcutaneous and muscle tissue, was measured at a distance of 0.5 cm and 2.5 cm from the wound edge (Figure 1).

### Calculations and statistics

Statistical analysis was performed using paired Student's t-test. Significance was defined as  $p < 0.05$ . The results are presented as mean values ± the standard error of the mean (S.E.M.).

## Results

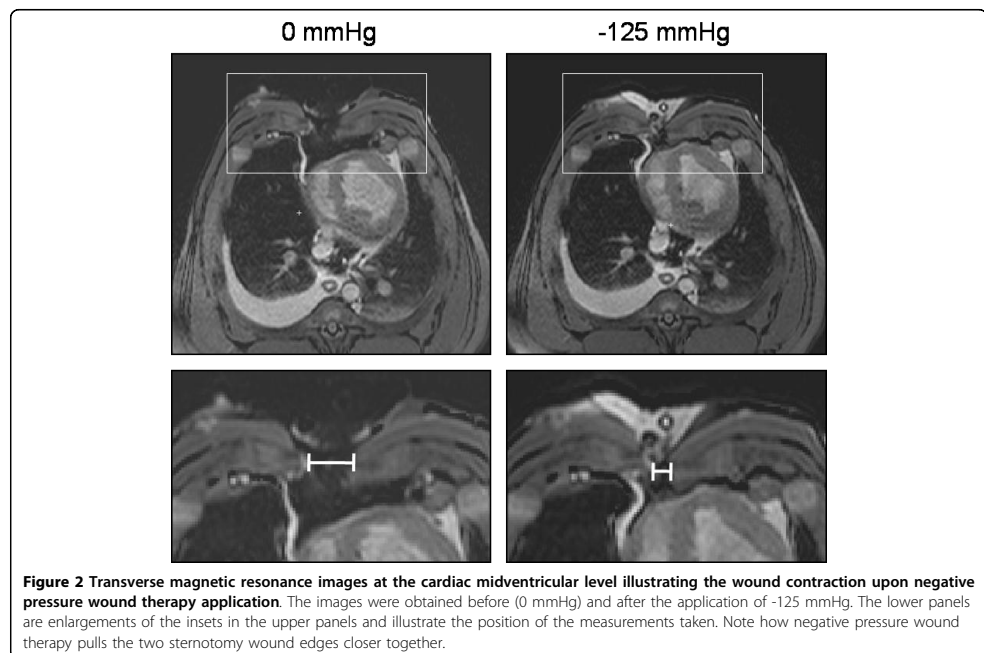
The sternotomy wound changed in appearance and the lateral wound width decreased when negative pressure was applied (Figure 2). The lateral wound width decreased from  $39 \pm 7$  mm to  $30 \pm 6$  mm, for sternum bone, upon application of -125 mmHg ( $p = 0.0027$ ,  $n = 6$ , Figure 3). The greatest decrease in lateral wound width, as measured between the sternum bone edges, occurred when switching from 0 mmHg to -75 mmHg, and the level of negative pressure did not play a role for the degree of wound contraction ( $32 \pm 6$  mm at -75 mmHg and  $29 \pm 6$  mm at -175 mmHg, for the sternum bone,  $p = 0.0897$ ,  $n = 6$ , Figure 3).



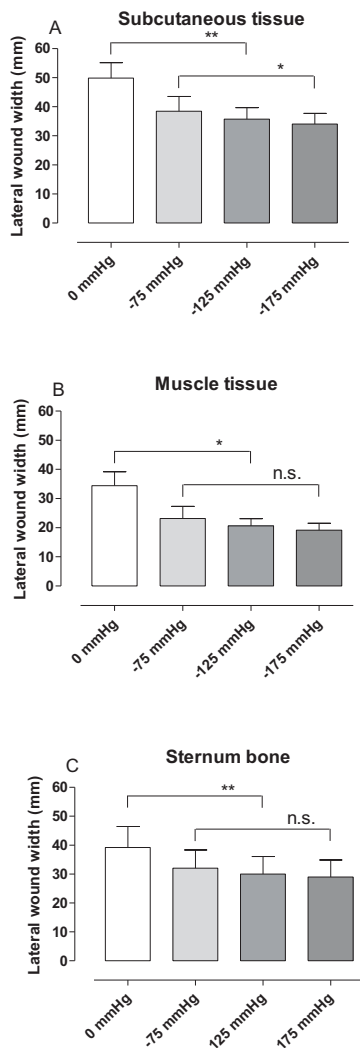
The wound edge tissue was also deformed upon application of NPWT. The decrease in lateral wound width during NPWT was greater in subcutaneous tissue ( $14 \pm 2$  mm) than in sternum bone ( $9 \pm 2$  mm), which resulted in a ratio of subcutaneous to sternal decrease in wound width of  $1.7 \pm 0.3$  ( $p = 0.0423$ ), suggesting macro-deformation of the wound edge tissue. The major decrease in lateral wound width occurred when switching from 0 to

-75 mmHg and the level of negative pressure did not play a significant role for the degree of wound contraction ( $23 \pm 4$  mm at -75 mmHg and  $19 \pm 2$  mm at -175 mmHg, for muscle tissue  $p = 0.0982$ ,  $n = 6$ , Figure 3).

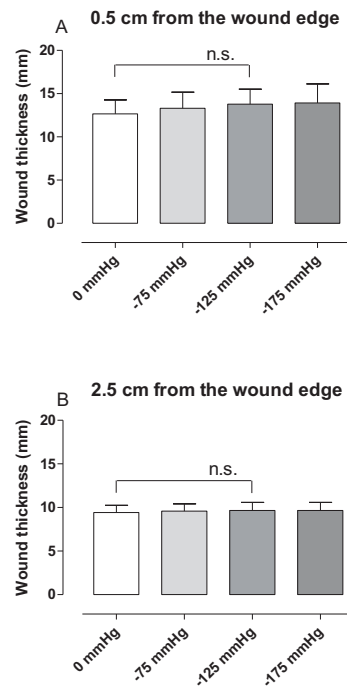
The anterior-posterior thickness of the soft tissue, including subcutaneous and muscle tissue, at 0.5 and 2.5 cm laterally from the wound edge, was not affected by negative pressure ( $13 \pm 2$  mm at 0 mmHg and  $14 \pm 2$  mm







**Figure 3** Graphs showing wound contraction upon negative pressure application. The distance between the wound edges (lateral wound width) in subcutaneous tissue (A), muscle tissue (B) and sternum bone (C), measured in transverse magnetic resonance images in sternotomized pigs before (0 mmHg) and after the application of negative pressure wound therapy (NPWT) at -75, -125 and -175 mmHg. Results are presented as mean values  $\pm$  S.E.M. Statistical comparison was performed using Student's paired t-test. Significance is defined as  $p < 0.05$  (\*) and  $p < 0.01$  (\*\*) and n.s. denotes non-significance. Note the decrease in lateral wound width upon application of NPWT.



**Figure 4** Graphs showing anterior-posterior thickness of subcutaneous tissue and muscle tissue upon negative pressure application. The anterior-posterior thickness of subcutaneous tissue and muscle tissue at 0.5 cm (A) and 2.5 cm (B) from the wound edge, measured in transverse magnetic resonance images in sternotomized pigs before (0 mmHg) and after the application of negative pressure wound therapy (NPWT) at -75, -125 and -175 mmHg. Results are presented as mean values  $\pm$  S.E.M. Statistical comparison was performed using Student's paired t-test. Significance is defined as  $p < 0.05$  and n.s. denotes non-significance.

at -125 mmHg, 0.5 cm from the wound edge,  $p = 0.1111$ ,  $n = 6$ , Figure 4).

## Discussion

The present study shows wound contraction upon application of NPWT in a porcine sternotomy wound model. Furthermore, it provides detailed evidence for the

deformation of the wound edge tissue. Pulling forces by the negative pressure move the subcutaneous tissue wound edges together to a greater extent than the wound edges of the sternum bone. This presumably creates shearing forces in the tissue and at the wound-foam interface. This so called macro-deformation of the tissue is believed to be one of the fundamental mechanisms by which NPWT results in wound healing [11]. This mechanical effect of NPWT is thought to initiate a cascade of inter-related biological effects including the promotion of wound edge microvascular blood flow, removal of bacteria and stimulation of granulation tissue formation [7,10,13,14].

#### **Shearing forces at the foam-wound interface**

Contraction of the wound and macro-deformation of the wound edge tissue upon NPWT, as shown in the present study, causes mechanical stress in the tissue. Mechanical stress is known to promote the expression of growth factors (e.g., vascular endothelial growth factor and fibroblast growth factor-2) and to stimulate granulation tissue formation and angiogenesis [15-17]. In a computerized model of negative pressure-induced wound deformation, most elements were stretched five to twenty percent by NPWT [11], which is similar to *in vitro* strain levels shown to promote cellular proliferation. The beneficial effects of NPWT on healing may depend on these macro-mechanical effects and the shearing forces at the foam-wound interface.

#### **Blood flow**

The mechanical effect of NPWT on the wound edge tissue is also believed to alter microvascular blood flow. Close to the wound edge there is contraction of the tissue resulting in hypoperfusion [18-20]. Factors released in response to hypoperfusion are strong stimulators of angiogenesis and granulation tissue formation, which may be one of the mechanisms governing the positive effects of NPWT. Pressure against the wound wall may also be beneficial since it has been shown to tamponade superficial bleedings during surgical procedures [18] and reduce wound edge edema. Further away from the wound edge, microvascular blood flow is increased upon negative pressure application. It may be speculated that the pulling forces on the wound edge tissue opens up capillary beds and surges blood to the area. The present study shows differences in the wound edge tissue deformation when comparing subcutaneous and muscle tissue. Similarly, blood flow effects by NPWT are different in subcutaneous and muscle tissue [19,20]. It may be speculated that the mechanical effects that NPWT result in depend on the density of the tissue and the tissue composition of the treated wound.

#### **Sternum stability**

In sternotomy wounds, there are underlying vital structures and an important aspect during treatment of these wounds is the heart and lung function and the reconstruction of a stable thorax. The present study shows that the sternotomy wound contracts during NPWT. This is in concordance with one of our previous studies showing that the sternum is stabilised and can withstand external forces during NPWT [21]. Stabilization of the sternum enables early mobilization which is crucial for the clinical outcome [22,23].

#### **Heart and lung function**

As shown by the present study, NPWT contracts the wound and draws the two sternal edges together, thereby resealing the thoracic cavity. NPWT thus largely restores the macroscopic anatomical conditions in the thorax, which may explain the clinical benefits of NPWT over open-chest care, including reduced need for mechanical ventilation [24,25]. Sternotomy wound contraction and resealing of the sternum also has effects on the heart pumping function. The findings that cardiac output decreases during NPWT [26,27] have been a reason for concern. However, we now believe that cardiac output increases and the energy efficiency of cardiac pumping decreases upon sternotomy and both these measures return to pre-sternotomy levels when the thorax is resealed by NPWT [28]. It is reassuring to know that the effects on cardiac pumping function upon resealing of the thorax is physiological since many patients with deep sternal wound infections suffer impaired cardiac function and heart failure and may thereby be especially vulnerable to increased cardiac load.

#### **Different levels of negative pressure**

In the present study, the greatest change in wound diameter was observed between 0 and -75 mmHg, and the level of negative pressure did not play a significant role for the degree of wound contraction. Similar findings were shown in a study by Isago et al [29], carried out in peripheral rat wounds and using polyurethane foam. Negative pressures of -50, -75 and -125 mmHg caused similar reduction in wound area. Furthermore, in a pig sternotomy wound model [21], the wound contraction upon NPWT application was similar in wounds treated with low (-50 to -100 mmHg) and high (-150 to -200 mmHg) negative pressures. Thus, both low and high levels of negative pressure will induce macro-mechanical deformation during NPWT.

#### **Conclusions**

In conclusion, NPWT contracts the wound and causes macro-deformation of the wound edge tissue. This

mechanical stress in the tissue and at the wound-foam interface creates shearing forces that is known to promote granulation tissue formation and facilitate healing.

#### Acknowledgements

We thank Einar Heiberg, PhD, for valuable help and advice regarding image analysis. This study was supported by the Swedish Medical Research Council, Lund University Faculty of Medicine, the Swedish Government Grant for Clinical Research, Lund University Hospital Research Grants, the Swedish Medical Association, the Royal Physiographic Society in Lund, the Åke Wiberg Foundation, the Anders Otto Swärd Foundation/Ulrika Eklund Foundation, the Magnus Bergvall Foundation, the Crafoord Foundation, the Anna-Lisa and Sven-Erik Nilsson Foundation, the Jeansson Foundation, the Swedish Heart-Lung Foundation, Anna and Edvin Berger's Foundation, the Märta Lundqvist Foundation, and the Lars Hierta Memorial Foundation.

#### Author details

<sup>1</sup>Department of Ophthalmology, Lund University and Skåne University Hospital, Lund, Sweden. <sup>2</sup>Department of Clinical Physiology, Lund University and Skåne University Hospital, Lund, Sweden. <sup>3</sup>Department of Cardiothoracic Surgery, Lund University and Skåne University Hospital, Lund, Sweden.

#### Authors' contributions

CT performed the image analysis, data analysis and drafted the manuscript. MU participated in the design of the study, image acquisition and analysis, data analysis and drafting the manuscript. HE participated in the design of the study and image acquisition. HA participated in the design of the study. RI participated in the design of the study and performed the surgical procedures. MM conceived of the study, participated in the surgical procedures, data analysis, drafting the manuscript and participated in its design and coordination. All authors critically revised the manuscript for important intellectual content, and approved the final manuscript.

#### Competing interests

The authors declare that they have no competing interests.

Received: 5 August 2010 Accepted: 30 September 2010  
Published: 30 September 2010

#### References

1. Raudat CW, Pagel J, Woodhall D, et al: Early intervention and aggressive management of infected median sternotomy incision: a review of 2242 open-heart procedures. *Ann Surg* 1997, **63**(3):238-41, discussion 241-2.
2. El Oakley RM, Wright JE: Postoperative mediastinitis: classification and management. *Ann Thorac Surg* 1996, **61**(3):1030-6.
3. Crabtree TD, Codd JE, Fraser VJ, et al: Multivariate analysis of risk factors for deep and superficial sternal infection after coronary artery bypass grafting at a tertiary care medical center. *Semin Thorac Cardiovasc Surg* 2004, **16**(1):53-61.
4. Lu JC, Grayson AD, Jha P, et al: Risk factors for sternal wound infection and mid-term survival following coronary artery bypass surgery. *Eur J Cardiothorac Surg* 2003, **23**(6):943-9.
5. Obdeijn MC, de Lange MY, Lichtendahl DH, et al: Vacuum-assisted closure in the treatment of poststernotomy mediastinitis. *Ann Thorac Surg* 1999, **68**(6):2358-60.
6. Sjogren J, Gustafsson R, Nilsson J, et al: Clinical outcome after poststernotomy mediastinitis: vacuum-assisted closure versus conventional treatment. *Ann Thorac Surg* 2005, **79**(6):2049-55.
7. Argenta LC, Morykwas MJ: Vacuum-assisted closure: a new method for wound control and treatment: clinical experience. *Ann Plast Surg* 1997, **38**(6):563-76, discussion 577.
8. Clare MP, Fitzgibbons TC, McMullen ST, et al: Experience with the vacuum assisted closure negative pressure technique in the treatment of non-healing diabetic and dysvascular wounds. *Foot Ankle Int* 2002, **23**(10):896-901.
9. Domkowski PW, Smith ML, Gonyon DL Jr, et al: Evaluation of vacuum-assisted closure in the treatment of poststernotomy mediastinitis. *J Thorac Cardiovasc Surg* 2003, **126**(2):386-90.

10. Morykwas MJ, Argenta LC, Shelton-Brown EI, et al: Vacuum-assisted closure: a new method for wound control and treatment: animal studies and basic foundation. *Ann Plast Surg* 1997, **38**(6):553-62.
11. Saxena V, Hwang CW, Huang S, et al: Vacuum-assisted closure: microdeformations of wounds and cell proliferation. *Plast Reconstr Surg* 2004, **114**(5):1086-96, discussion 1097-8.
12. Heiberg E, Sjogren J, Ugander M, et al: Design and Validation of Segment - freely available software for cardiovascular image analyses. *BMC Med Imaging* 2010, **10**:1.
13. Morykwas MJ, Simpson J, Pungler K, et al: Vacuum-assisted closure: state of basic research and physiologic foundation. *Plast Reconstr Surg* 2006, **117**(7 Suppl):1215-1265.
14. Malmso J, Ingemansson R, Sjogren J: Mechanisms governing the effects of vacuum-assisted closure in cardiac surgery. *Plast Reconstr Surg* 2007, **120**(5):1266-75.
15. Quinn TP, Schlueter M, Soifer SJ, et al: Cyclic mechanical stretch induces VEGF and FGF-2 expression in pulmonary vascular smooth muscle cells. *Am J Physiol Lung Cell Mol Physiol* 2002, **282**(5):L897-903.
16. Rivilis I, Milkiewicz M, Boyd P, et al: Differential involvement of MMP-2 and VEGF during muscle stretch - versus shear stress-induced angiogenesis. *Am J Physiol Heart Circ Physiol* 2002, **283**(4):H1430-8.
17. Urschel JD, Scott PG, Williams HT: The effect of mechanical stress on soft and hard tissue repair: a review. *Br J Plast Surg* 1988, **41**(2):182-6.
18. Sjogren J, Gustafsson R, Koul B, et al: Selective mediastinal tamponade to control coagulopathic bleeding. *Ann Thorac Surg* 2003, **75**(4):1311-3.
19. Wackenfors A, Gustafsson R, Sjogren J, et al: Blood flow responses in the peristernal thoracic wall during vacuum-assisted closure therapy. *Ann Thorac Surg* 2005, **79**(5):1724-30, discussion 1730-1.
20. Wackenfors A, Sjogren J, Gustafsson R, et al: Effects of vacuum-assisted closure therapy on inguinal wound edge microvascular blood flow. *Wound Repair Regen* 2004, **12**(6):600-6.
21. Mokhtari A, Petzina R, Gustafsson L, et al: Sternal stability at different negative pressures during vacuum-assisted closure therapy. *Ann Thorac Surg* 2006, **82**(3):1063-7.
22. Gustafsson RI, Sjogren J, Ingemansson R: Deep sternal wound infection: a sternal-sparing technique with vacuum-assisted closure therapy. *Ann Thorac Surg* 2003, **76**(6):2048-53, discussion 2053.
23. Hersh RE, Jack JM, Dahman MI, et al: The vacuum-assisted closure device as a bridge to sternal wound closure. *Ann Plast Surg* 2001, **46**(3):250-4.
24. Kutschka I, Frauendorfer P, Harringer W: [Vacuum assisted closure therapy improves early postoperative lung function in patients with large sternal wounds]. *Zentralbl Chir* 2004, **129**(Suppl 1):S33-4.
25. Ramnarine IR, McLean A, Pollock JC: Vacuum-assisted closure in the paediatric patient with post-cardiotomy mediastinitis. *Eur J Cardiothorac Surg* 2002, **22**(6):1029-31.
26. Conquest AM, Garofalo JH, Maziarz DM, et al: Hemodynamic effects of the vacuum-assisted closure device on open mediastinal wounds. *J Surg Res* 2003, **115**(2):209-13.
27. Petzina R, Ugander M, Gustafsson L, et al: Hemodynamic effects of vacuum-assisted closure therapy in cardiac surgery: assessment using magnetic resonance imaging. *J Thorac Cardiovasc Surg* 2007, **133**(5):1154-62.
28. Torbrand C, Ugander M, Engblom H, et al: Changes in cardiac pumping efficiency and intra-thoracic organ volume during negative pressure wound therapy of sternotomy wounds, assessment using magnetic resonance imaging. *Int Wound J* 7(4):305-11.
29. Isago T, Nozaki M, Kikuchi Y, et al: Effects of different negative pressures on reduction of wounds in negative pressure dressings. *J Dermatol* 2003, **30**(8):596-601.

doi:10.1186/1749-8090-5-75

Cite this article as: Torbrand et al: Wound contraction and macro-deformation during negative pressure therapy of sternotomy wounds. *Journal of Cardiothoracic Surgery* 2010 **5**:75.



