



# LUND UNIVERSITY

## Morphological alterations in frontotemporal dementia:

Santillo, Alexander

2014

[Link to publication](#)

*Citation for published version (APA):*

Santillo, A. (2014). *Morphological alterations in frontotemporal dementia*: [Doctoral Thesis (compilation), Clinical Memory Research]. Clinical Memory Research Unit, Lund University.

*Total number of authors:*

1

### General rights

Unless other specific re-use rights are stated the following general rights apply:

Copyright and moral rights for the publications made accessible in the public portal are retained by the authors and/or other copyright owners and it is a condition of accessing publications that users recognise and abide by the legal requirements associated with these rights.

- Users may download and print one copy of any publication from the public portal for the purpose of private study or research.
- You may not further distribute the material or use it for any profit-making activity or commercial gain
- You may freely distribute the URL identifying the publication in the public portal

Read more about Creative commons licenses: <https://creativecommons.org/licenses/>

### Take down policy

If you believe that this document breaches copyright please contact us providing details, and we will remove access to the work immediately and investigate your claim.

LUND UNIVERSITY

PO Box 117  
221 00 Lund  
+46 46-222 00 00

# Morphological alterations in frontotemporal dementia:

pathophysiological models and behavioural  
consequences

Alexander Frizell Santillo



**LUNDS**  
**UNIVERSITET**

DOCTORAL DISSERTATION

by due permission of the Faculty of Medicine, Lund University, Sweden.

To be defended at GK-salen, Biomedicinskt Centrum, Lund, 2014-10-03, 13:00

*Faculty opponent*

*Professor John van Swieten, Departement of Neurology, Erasmus Universiteit, Rotterdam,  
Holland*

Organization LUND UNIVERSITY  Author(s) Alexander Frizell Santillo	Document name	
	Date of issue 2014-08-20	
	Sponsoring organization	
Title and subtitle  Morphological alterations in frontotemporal dementia: pathophysiological models and behavioural consequences		
Abstract  <p>The present thesis explores alterations in brain morphology in the neurodegenerative disorder of frontotemporal dementia (FTD). With the aim to improve the clinical diagnostics of FTD, we explored the diagnostic potential of measuring morphological alterations in the white matter by diffusion tensor imaging (DTI)- MRI, compared with the more commonly used assessment of grey matter thickness and volume. DTI-MRI was better at separating FTD cases from controls than grey matter parameters, and may thus be a promising supplementary imaging tool for the diagnostic work in FTD. We used DTI in combination with grey matter imaging to explore the morphological underpinnings of one of the central behavioural symptoms in FTD, disinhibition. Our results show that this symptom appears related to the integrity of an orbitofrontal-temporal network, as opposed to the prevailing view of a degeneration of the orbitofrontal cortex. An important question in FTD is what constitutes the morphological link between the molecular pathologies and the characteristic frontotemporal pattern of cortical degeneration. The von Economo neurons (VENs), are a particular type of neurons that are proposed to constitute this link. We confirm results from others, showing that these neurons are selectively degenerated in FTD. In addition we show that these neurons are more afflicted than pyramidal neurons in the superficial cortical layers, previously thought to be the most selectively degenerated in the cortex of FTD. The findings presented in this thesis will hopefully contribute both to improved diagnostics, understanding of clinico-pathological relationships, and of the pathophysiology of this condition.</p>		
Key words: Frontotemporal dementia, diffusion tensor imaging, von Economo neurons		
Classification system and/or index terms (if any)		
Supplementary bibliographical information	Language English	
ISSN and key title  1652-8220, Lund University Faculty of Medicine Doctoral Dissertation Series 2014:112	ISBN  978-91-7619-041-8	
Recipient's notes	Number of pages	Price
	Security classification	

I, the undersigned, being the copyright owner of the abstract of the above-mentioned dissertation, hereby grant to all reference sources permission to publish and disseminate the abstract of the above-mentioned dissertation.

Signature \_\_\_\_\_ Date \_\_\_\_\_

# Morphological alterations in frontotemporal dementia:

pathophysiological models and behavioural  
consequences

Alexander Frizell Santillo



**LUNDS**  
UNIVERSITY



Copyright Alexander Frizell Santillo

Faculty of Medicine, Department of Clinical Sciences, Malmö  
ISBN 978-91-7619-041-8  
ISSN 1652-8220

Printed in Sweden by Media-Tryck, Lund University  
Lund 2014



# Contents

Abbreviations	p 1
List of publications and manuscripts	p 3
Introduction and overview of the thesis	p 5
Frontotemporal dementia	p 6
Neuropathology	p 8
Genetics	p 9
White matter changes	p 10
Topography of bvFTD	p 10
Diffusion Tensor Imaging in bvFTD	p 11
The anterior cingulate cortex	p 15
Anatomy	p 15
Function	p 16
The anterior cingulate cortex in bvFTD	p 17
The orbitofrontal cortex	p 18
Anatomy	p 18
Function	p 19
The orbitofrontal cortex in bvFTD	p 19
Von Economo neurons	p 21
Evolutionary and ontogenetic perspective	p 22
Possible functions	p 23
VENs in disease	p 23
The present investigation	p 25
Study I	p 25

Study II	p 28
Study III and IV	p 34
Erratum	p 34
General summary and conclusion	p 34
Populärvetenskaplig sammanfattning på svenska	p 35
Acknowledgements	p 37
References	p 39
Appendix (Study I-IV)	





# Abbreviations

ACC: anterior cingulate cortex  
AD: Alzheimer's disease  
ATR: anterior thalamic radiation  
BA: Brodmann Area  
bvFTD: behavioural variant frontotemporal dementia  
Ci or CB: cingulum bundle  
CC: corpus callosum  
CST: corticospinal tract  
C9orf72: chromosome 9 open reading frame 72  
DTI: diffusion tensor imaging  
EC: external capsule  
GM: grey matter  
FBI: frontal behavioural inventory  
FI: frontoinsular cortex  
FTD: frontotemporal dementia  
FTLD: frontotemporal lobar degeneration  
FUS: fused in sarcoma protein  
IC: internal capsule  
IFOF inferior frontooccipital fasciculus  
ILF: inferior longitudinal fasciculus  
MAPT: microtubule associated protein tau  
MND: motor neuron disease  
MRI: magnetic resonance imaging  
OFC: orbitofrontal cortex  
PET: positron emission tomography  
PCC: posterior cingulate cortex  
PFC: prefrontal cortex  
PGRN: progranulin  
PNFA: progressive non-fluent aphasia  
PPA: primary progressive aphasia  
PSP: progressive supranuclear paralysis  
ROI: region of interest  
SD: semantic dementia  
SPECT: single-photon emission computed tomography

TDP: TAR DNA binding protein 43  
UF: uncinat fasciculus  
VBM: voxel based morphometry  
VEN: von Economo neuron  
WMH: white matter hyperintensities

# List of publications and manuscripts

This thesis is based on the following publications and manuscripts, which will be referred to by roman numerals:

Study I. *Diffusion tensor tractography versus volumetric imaging in the diagnosis of behavioural variant frontotemporal dementia*. Santillo AF, Mårtensson J, Lindberg O, Nilsson M, Manzouri A, Landqvist Waldö M, van Westen D, Wahlund L-O, Lätt J, Nilsson C. PLoS ONE. 8: e66932, 2013.

Study II. Grey and white matter clinico-anatomical correlates of disinhibition in behavioural variant frontotemporal dementia and progressive supranuclear palsy. Alexander Frizell Santillo, Karl Lundblad, Markus Nilsson, Maria Landqvist Waldö, Danielle van Westen, Jimmy Lätt, Erik Blennow Nordström, Susanna Vestberg, Olof Lindberg, Christer Nilsson (submitted manuscript).

Study III. *Von Economo neurons are selectively targeted in frontotemporal dementia*. Santillo AF, Nilsson C, Englund E. Neuropathology and applied neurobiology. 2013; 39: 572-579.

Study IV. *Greater loss of Von Economo neurons than loss of layer II and III neurons in behavioural variant frontotemporal dementia*. Alexander Frizell Santillo, Elisabet Englund. American Journal of Neurodegenerative Disease 2014, in press.

## Publications not part of the present thesis

*In vivo imaging of astrocytosis in Alzheimer's disease: an (11)C-L-deuteriodeprenyl and PIB PET study.* Santillo AF, Gambini JP, Lannfelt L, Langstrom B, Ulla-Marja L, Kilander L, Engler H. Eur J Nucl Med Mol Imaging. 2011; 38: 2202-8.

*In vivo amyloid imaging with PET in frontotemporal dementia.* Engler H, Santillo AF, Wang SX, Lindau M, Savitcheva I, Nordberg A, Lannfelt L, Langstrom B, Kilander L. Eur J Nucl Med Mol Imaging. 2008; 35: 100-6. Shared first authorship.

*Cerebrospinal fluid neurofilament light chain protein levels in subtypes of frontotemporal dementia.* Landqvist Waldö M, Santillo AF, Passant U, Zetterberg H, Rosenngren L, Nilsson C, Englund E. BMC Neurology 2013; 13: 54

*Age-related incidence and family history in frontotemporal dementia: Data from the Swedish Dementia Registry.* Nilsson C, Landqvist Waldö M, Nilsson K, Santillo AF, Vestberg S. PLoS ONE 9: e94901, 2014.

# Introduction and overview of the thesis

The present thesis explores specific alterations in brain morphology in frontotemporal dementia (FTD) with the aim to improve diagnostic methodology, and to increase the understanding of the underlying pathophysiology and behavioural consequences of these morphological alterations.

The thesis is based on four original studies (Study I-IV, see Appendix). The remaining part of the thesis is divided in two main sections. FTD as a clinical and pathological entity will be introduced. I will focus on neuroimaging findings, especially the recent developments of diffusion tensor imaging, since this method is central for Study I and II. This is followed by a short description of two anatomical regions pertinent for the studies in this thesis, the anterior cingulate cortex and the orbitofrontal cortex, and their involvement in FTD. Von Economo neurons, which are the subject of Study III and IV, are then introduced. In the second part, a short overview of each study is given, with an extended discussion of methodological limitations, the findings in context, and future directions.

# Frontotemporal dementia

Frontotemporal dementia (FTD) is a clinical syndrome resulting from a neurodegenerative process affecting mainly the frontal and temporal brain regions. Among the dementias, FTD accounts for approximately 5% of the cases in total (Brunnstrom, Gustafson et al. 2009; Hodges 2010). FTD has a lower mean age of onset than AD, which makes it relatively more common in patients with dementia <65 years of age (Hodges 2010; Nilsson, Landqvist Waldo et al. 2014), where it may account for up to 20% of dementia cases (Neary, Snowden et al. 1998). However, as for all neurodegenerative dementias, it appears that the incidence of FTD increases with age, and in several recent studies the majority of cases were diagnosed >65 years of age (Garre-Olmo, Genis Batlle et al. 2010; Nilsson, Landqvist Waldo et al. 2014). FTD appears to be evenly distributed among the sexes (Hodges 2010; Nilsson, Landqvist Waldo et al. 2014). A high proportion of cases have a positive family history, and associated genetic mutations account for 10-30% of cases (described below). As will be seen, FTD is a heterogeneous disorder and its prognosis variable, but the estimated median duration from symptom onset until death is around 6 years (Grasbeck, Englund et al. 2003; Hodges 2010).

Patients with FTD are usually classified according to the main clinical presentation into a behavioural variant frontotemporal dementia (bvFTD), and two language variants, semantic dementia (SD) and progressive non fluent aphasia (PNFA), the latter two collectively known as primary progressive aphasia (PPA). Of patients with FTD, bvFTD constitute approximately two thirds of the FTD group, while SD and PNFA are equally divided between the remaining third (Hodges 2010). FTD overlaps with several other neurological conditions. There is a firm clinical, pathological and genetic overlap with motor neuron disease (MND, or ALS), with a proportion of FTD patients developing MND and vice versa (FTD-MND). There is also an overlap with the “parkinsonian” disorders progressive supranuclear palsy (PSP) and corticobasal degeneration (CBD) which can present with or develop signs of FTD, and to some extent share neuropathological and genetics features. This thesis will mainly focus on bvFTD.

Symptom onset in FTD is generally insidious and gradual. Common behavioural symptoms in bvFTD are apathy, disinhibition, abnormal eating behaviour and stereotypic and ritualistic behaviour. Cognitive symptoms are those of mental rigidity,

executive deficits, reduced verbal output, and poor memory. Impaired insight is a common symptom, important to acknowledge, since this limits the clinician from eliciting an adequate history from the patient, and increases the need to rely on the history provided by the informant. History taking from the informant can be structured with the use of a clinical rating scale, such as the frontal behavioural inventory (FBI) (Kertesz, Davidson et al. 1997), neuropsychiatric inventory (NPI) (Cummings, Mega et al. 1994) and others (Gustafson, Englund et al. 2010). Not all symptoms are present in every case, which is reflected by the current diagnostic criteria of the international FTD consortium (FTDC) criteria (Table 1)(Rascovsky, Hodges et al. 2011). Here 3/6 of core symptoms are sufficient for a diagnosis of possible bvFTD. These symptoms should be elicited from history or observation in the clinical context. Neuropsychological examination can be conducted with screening tests such as the mini-mental status examination (MMSE) and Addenbrooke's Cognitive Examination (ACE) and/or formal neuropsychological testing. It is important to note that even the latter can be normal at the initial presentation (Hodges 2010). Although the criteria emphasize a "relative sparing of memory functions", the issue of memory impairment in bvFTD is under evaluation (Hornberger and Piguet 2012).

**Table 1. The international consensus criteria for behavioural variant FTD (FTDC).**

From Rascovsky et al. 2011. "Early" refers to symptom presentation within the first three years. bvFTD: behavioural variant FTD.

<p>I. Neurodegenerative disease</p> <p>The following symptom must be present.</p> <p>A. Progressive deterioration of behaviour and/or cognition by observation or history.</p>
<p>II. Possible bvFTD</p> <p>Three of the following behavioural/cognitive symptoms must be present.</p> <p>A. Early behavioural disinhibition</p> <p>B. Early apathy or inertia</p> <p>C. Early loss of sympathy or empathy</p> <p>D. Early perseverative, stereotyped or compulsive/ritualistic behaviour</p> <p>E. Hyperorality and dietary changes</p> <p>F. Neuropsychological profile: executive generation deficits with relative sparing of memory and visuospatial functions.</p>
<p>III. Probable bvFTD</p> <p>All following symptoms must be present.</p> <p>A. Meets criteria for possible bvFTD</p> <p>B. Exhibits significant functional decline</p>



C. Imaging results consistent with bvFTD

IV. bvFTD with definite FTLN pathology

Criterion A and either criterion B or C must be present.

A. Meets criteria for possible or probable bvFTD

B. Histopathological evidence of FTLN on biopsy or postmortem

C. Presence of a known pathogenetic mutation

V. Exclusion criteria for bvFTD

Criteria A and B must be answered negatively for any bvFTD diagnosis. Criterion C can be positive for possible bvFTD but must be negative for probable bvFTD.

A. Pattern of deficits is better accounted for by other non-degenerative nervous system or medical disorders

B. Behavioural disturbance is better accounted for by a psychiatric diagnosis

C. Biomarkers strongly indicative of Alzheimer's disease or other neurodegenerative process

To make a diagnosis of probable bvFTD according to FTDC criteria, the patient also needs to display a significant functional decline, and, importantly, show imaging results consistent with bvFTD: frontal and/or temporal atrophy on CT/MRI, hypoperfusion on CBF-SPECT or hypometabolism on FDG-PET examination. Thus the diagnosis of bvFTD relies heavily on neuroimaging, both by showing that the symptoms seen probably are caused by a frontotemporal pathological process, and also by potentially excluding other causes, such as cerebrovascular disease. A large proportion of bvFTD cases however have a normal structural imaging (CT/MRI) at presentation without signs of frontal and/or temporal atrophy; this portion may account for up to 50-64% (Knopman, Boeve et al. 2005; Mendez, Shapira et al. 2007; Pijnenburg, Mulder et al. 2008) and a number of individuals retain a macroscopically normal brain structure even at time of death. Generally, functional modalities (CBF-SPECT and particularly FDG-PET) appear to be more sensitive (McNeill, Sare et al. 2007; Mendez, Shapira et al. 2007) and are therefore recommended in diagnostic work up if structural imaging is negative (Piguet, Hornberger et al. 2011). Clearly, a more sensitive type of MRI imaging could be of clinical use, and there are several under evaluation (Bron, Steketee et al. 2014). Currently, a definitive diagnosis of bvFTD is either made at neuropathological examination or linking the clinical syndrome with a known pathogenic mutation (see below).

### *Neuropathology*

In order to separate the clinical and neuropathological classification, the current nomenclature uses FTD to denote the clinical syndrome, while the neuropathological condition is described as frontotemporal lobar degeneration (FTLD). The classical

histopathological description of FTLD is that of frontotemporal cortical neuronal loss, astrocytic gliosis and microvacuolisation (Brun 1987; Cairns, Bigio et al. 2007). The superficial cortical layers (I, II and III) are generally more affected by these changes than deeper layers of the cortex (V, VI). In FTLD, both projection neurons and local-circuitry interneurons (mainly calbindin protein binding) are affected, including their dendritic trees and neuron synapses (Ferrer, Tunon et al. 1993) (Liu, Erikson et al. 1996). Microglia are activated in FTLD, both in the cortex and in white matter (Schofield, Kersaitis et al. 2003; Kersaitis, Halliday et al. 2004)

The neuropathological diagnosis of FTLD relies not only on the morphological-histological characteristics described above, but the identification of inclusions of particular pathological proteins by immunohistochemistry (Cairns, Bigio et al. 2007; Mackenzie, Neumann et al. 2010; Mackenzie, Neumann et al. 2011). These pathological proteins are not only a nosological feature but have important linkage with the clinical syndrome, as well as with genetics, and are one way to understand the pathophysiology. Today, the main neuropathological types of FTLD recognized are: FTLD-tau, FTLD-TDP, FTLD-UPS (ubiquitin proteasome system) and FTLD-FUS (fused in sarcoma). FTLD-TDP is further subdivided into types A-D (Mackenzie, Neumann et al. 2011). Although there are important exceptions, a general clinicopathological correspondence can be made (Josephs, Hodges et al. 2011; Sieben, Van Langenhove et al. 2012):

- bvFTD is equally divided between FTLD-tau and FTLD-TDP (Type A, B)
- FTD with motor neuron disease is associated with FTLD-TDP (Type B)
- PNFA is most commonly seen with FTLD-tau pathology
- SD is most commonly due to FTLD-TDP (Type C) pathology
- PSP and CBD are associated with FTLD-tau pathology

### *Genetics*

bvFTD can be caused by mutations in several genes (Rademakers, Neumann et al. 2012), the most common being mutations in the genes for microtubule associated protein tau (MAPT) and progranulin (PGRN), or chromosome 9 open reading frame 72 (C9orf72) expansions, with the latter also being the cause for a substantial part of hereditary MND. In a large family, restricted to Denmark, bvFTD is caused by a mutation in the charged multivesicular body protein 2B gene (CHMP2B). There is a clear gene-protein pathology correspondence, with MAPT mutations leading to tau pathology, PGRN mutations leading mainly to FTLD-TDP pathology Type A, C9orf72 mutations leading to FTLD-TDP pathology Type B, and CHMP2B mutations leading to FTLD-UPS.

### *White matter changes*

In FTLTD, white matter changes are characteristically those of astrocytic gliosis and myelin loss, with or without discrete oligodendrocyte cell loss (Englund and Brun 1987). The regional involvement of white matter generally matches that of grey matter, i.e the most affected parts of the cortex have the most affected white matter. White matter changes, however, tend to be more widely distributed, affecting regions where cortical involvement is not seen (such as in the occipital lobe), albeit to a lesser degree. Studies have shown an increase of both glia and microglia in the white matter in FTD (Schofield, Kersaitis et al. 2003; Tartaglia 2010), which stain for the characteristic disease proteins (tau, TDP-43) (Zhukareva, Mann et al. 2002; Schofield, Kersaitis et al. 2003; Neumann, Kwong et al. 2007; Tartaglia 2010). The same appears to be the case in PSP (Zhukareva, Mann et al. 2002) and CBD (Forman, Zhukareva et al. 2002). It's an open question if the white matter changes are to be interpreted as a result of Wallerian degeneration per se, or if it is caused by a combination of Wallerian degeneration and direct pathology of the white matter (Neumann, Kwong et al. 2007; Agosta, Scola et al. 2012).

### *Topography of bvFTD*

In early descriptions the cortical atrophy and histological changes in FTD are described to involve the frontal lobes (sparing motor areas), including the anterior part of the cingulate gyrus and insula, and the anterior parts of the temporal lobes (Brun 1987). Quantitative post-mortem analyses confirmed these findings but also showed considerable involvement of subcortical structures such as hippocampus and basal ganglia (Mann, South et al. 1993). The distribution and sequential development of macroscopic atrophy has been developed into a staging scheme, (Broe, Hodges et al. 2003). This emphasizes that early atrophy occurs in orbital and frontal medial cortex, along with hippocampus and anterior insula. Subsequently, the atrophy involves the remaining part of the frontal cortex, as well as the anterior temporal cortex and basal ganglia.

Numerous in vivo neuroimaging studies have largely confirmed findings from post-mortem studies. The most consistently affected regions, as described in imaging metaanalyses (Schroeter, Raczka et al. 2008; Schroeter, Laird et al. 2014), are the frontomedian cortex (including the cingulate gyrus, the paracingulate and medial superior frontal gyrus), the subcallosal area, anterior insula, orbitofrontal cortex, thalami and the basal ganglia, particularly caudate head, putamen and nucleus accumbens. Generally, individual studies describe affliction of wider areas than those listed above, including the anterior temporal lobes, frontopolar and dorsolateral prefrontal cortex (Rabinovici, Seeley et al. 2007). In an attempt to highlight the regions of earliest affliction in bvFTD, one study was particularly focused on very

early bvFTD, with patients having a clinical dementia rating (CDR) of 0.5 (Seeley, Crawford et al. 2008). This showed grey matter loss in the frontomedian, orbital, dorsolateral and anterior insular cortex, hippocampus, thalamus and the subcallosal area (Seeley, Crawford et al. 2008). There are variations in between studies, probably depending on different degrees of severity, diagnostic criteria, and on a variable extent of inclusion of patients with related conditions such as PPA, CBD, and FTD-MND. Also, it appears that bvFTD can be clustered into different atrophy patterns, with patients showing predominantly frontal, frontotemporal, frontotemporoparietal or temporal atrophy (Whitwell, Przybelski et al. 2009). Genetic variants exhibit different atrophy profiles where patients with MAPT mutation characteristically show a temporal dominant pathology, PGRN mutations show asymmetrical frontotemporoparietal atrophy and C9orf72 mutations have widespread atrophy also involving the parieto-occipital lobes and the cerebellum (Whitwell, Przybelski et al. 2009; Rohrer, Ridgway et al. 2010; Simon-Sanchez, Dopper et al. 2012; Whitwell, Weigand et al. 2012).

#### *Diffusion Tensor Imaging in bvFTD*

Diffusion tensor imaging (DTI) (Johansen-Berg and Behrens 2009) is a MRI technique based on quantification of water diffusion in tissue. In an unrestricted condition, water molecules move at random, but in biological tissue these movements are limited by different tissue structures. Thus, the properties of the tissue will influence the rate and direction of water diffusion and tissue microstructure can be partly inferred from measuring main strength and direction of water diffusion. In the brain, large constraints on water diffusion is set by axons and their myelin sheets of the white matter, which will facilitate diffusion along the main direction of axons and hinder perpendicular diffusion.

By measuring diffusion in several directions in a single voxel the predominant diffusion direction in each voxel can be calculated. The strength of the diffusion in the predominant direction in each voxel can be expressed as the degree of anisotropy of each voxel, the fractional anisotropy (FA). Dense, highly organised white matter bundles will have a higher FA compared with less densely packed fiber bundles. Accepting a number of assumptions, the anatomy of white matter pathways can be reconstructed based on the FA of adjoining voxels, a method used in tractography. (fig) The use of DTI is a considerable step forward in the study of white matter anatomy in neuroscience. Previously, study of white matter connections was limited to post-mortem dissections, or tracing studies in non-human animals (Catani and Thiebaut de Schotten 2012). Also, DTI gives the possibility to study disease processes that affect the white matter in vivo, by measuring alterations in diffusion parameters (Johansen-Berg and Behrens 2009). Commonly used diffusion parameters are the FA, reflecting the strength of preferential direction in each voxel, axial diffusivity (aD:

reflecting the diffusion along the preferential direction) and radial diffusivity (rD: reflecting the diffusion perpendicular to the preferential direction). The mean diffusivity (MD) is the mean of the diffusivity in all directions in each voxel. An attractive idea is that changes in the different diffusion parameter represent different pathological processes, which has been explored in experimental studies. As an often quoted example, myelin deficient mice show more alterations in rD than aD, which has been interpreted as myelin sheets being the structures that mainly hinder perpendicular diffusion (Song, Sun et al. 2002). However, this is very controversial (Wheeler-Kingshott and Cercignani 2009; Jones, Knosche et al. 2013) and today the interpretation of what pathological process cause changes in the diffusion parameters is based on indirect evidence from neuropathology.

As described previously, white matter involvement is a part of the disease process in FTD, and a number of studies have used DTI to study this phenomenon. A summary of published studies until March 2014 is presented below. There is a substantial variation in study design, but some conclusions can be made:

- The most consistently replicated white matter fiber bundles, tracts, in which DTI parameters are altered in bvFTD are the anterior corpus callosum (aCC), anterior cingulum bundle (aCi), uncinate fasciculus (UF) and superior longitudinal fasciculus (SLF, which in the commonly used nomenclature includes the arcuate fasciculus) (Borroni, Brambati et al. 2007; Matsuo, Mizuno et al. 2008; Zhang, Schuff et al. 2009; Avants, Cook et al. 2010; Whitwell, Avula et al. 2010; Zhang, Schuff et al. 2011; Agosta, Scola et al. 2012; Lillo, Mioshi et al. 2012; McMillan, Brun et al. 2012; McMillan, Irwin et al. 2013; Zhang, Tartaglia et al. 2013; Lam, Halliday et al. 2014; Mahoney, Ridgway et al. 2014)
- A number of studies also report changes in the inferior longitudinal fasciculus (ILF) (Borroni, Brambati et al. 2007; Matsuo, Mizuno et al. 2008; Whitwell, Avula et al. 2010; Agosta, Scola et al. 2012; Lillo, Mioshi et al. 2012; McMillan, Brun et al. 2012; Lam, Halliday et al. 2014; Mahoney, Ridgway et al. 2014), the inferior frontooccipital fasciculus (IFOF) (Avants, Cook et al. 2010; Agosta, Scola et al. 2012; McMillan, Brun et al. 2012; Lam, Halliday et al. 2014), the internal capsule (Agosta, Scola et al. 2012), the anterior thalamic radiation (Agosta, Scola et al. 2012; Lam, Halliday et al. 2014; Mahoney, Ridgway et al. 2014) and the corticospinal tract (Lillo, Mioshi et al. 2012; McMillan, Brun et al. 2012; Mahoney, Ridgway et al. 2014).
- Discrepancies that emerge are that some studies show a more limited involvement, notably the study by Borroni et al. (Borroni, Brambati et al. 2007), while some show a clearly larger involvement including the posterior

corpus callosum, posterior cingulum bundle, and parietal, occipital and brainstem white matter (Agosta, Scola et al. 2012).

- Partly these discrepancies could be explained by different diagnostic criteria, severity and selection of cases, but it also appears that bvFTD due to genetic dominant mutations (MAPT, C9orf72) show different involvement on DTI (Dopper, Rombouts et al. 2013; Mahoney, Ridgway et al. 2014).
- In disease progression over time DTI shows increasingly more severe and more extended involvement (Lam, Halliday et al. 2014).
- Studies comparing FTD with AD show that tracts that generally are more affected in FTD are the aCC, aCi, and UF (Zhang, Schuff et al. 2009; Avants, Cook et al. 2010; Zhang, Schuff et al. 2011; McMillan, Brun et al. 2012; Mahoney, Ridgway et al. 2014). AD shows more involvement of posterior tracts or part of tracts such as posterior corpus callosum, posterior cingulum bundle, and posterior SFL compared with FTD (Zhang, Schuff et al. 2009; Avants, Cook et al. 2010; Zhang, Schuff et al. 2011), or no differences (McMillan, Brun et al. 2012).
- The white matter involvement is associated with areas of grey matter (GM) atrophy (Avants, Cook et al. 2010; Zhang, Schuff et al. 2011; Agosta, Scola et al. 2012; Zhang, Tartaglia et al. 2013; Lam, Halliday et al. 2014; Mahoney, Ridgway et al. 2014), and DTI and GM atrophy do correlate (Avants, Cook et al. 2010; Zhang, Schuff et al. 2011; Zhang, Tartaglia et al. 2013). DTI involvement also correlates with perfusion (Zhang, Schuff et al. 2011) and FDG-PET hypometabolism (Acosta-Cabronero, Patterson et al. 2011). In some studies the white matter involvement extend clearly beyond the involvement of the cortex (Agosta, Scola et al. 2012; Lam, Halliday et al. 2014; Mahoney, Ridgway et al. 2014) but some studies show no extension (Zhang, Schuff et al. 2011; Zhang, Tartaglia et al. 2013). DTI variables seem to be more sensitive for disease progression than cortical atrophy (Lam, Halliday et al. 2014).
- Different diffusion parameters (FA, MD, aD, rD) are more/less sensitive for change, with the most sensitive parameter generally being rD (Zhang, Schuff et al. 2009; Agosta, Scola et al. 2012; Zhang, Tartaglia et al. 2013; Mahoney, Ridgway et al. 2014). Also, the different DTI parameters show different sensitivity for progression (Lam, Halliday et al. 2014), and the change seen show different profiles in bvFTD caused by different genetic mutations (Dopper, Rombouts et al. 2013; Mahoney, Ridgway et al. 2014).
- DTI parameters can be used to discriminate bvFTD and healthy controls on an individual basis, with sensitivity around 85% and specificity around 75% (Agosta, Scola et al. 2012; Zhang, Tartaglia et al. 2013; Mahoney, Ridgway et al. 2014). The most distinguishing tracts are the UF and CC (Avants, Cook et al. 2010; Agosta, Scola et al. 2012; Mahoney, Ridgway et al. 2014), and the most distinguishing parameter appears to be rD (Zhang, Tartaglia et

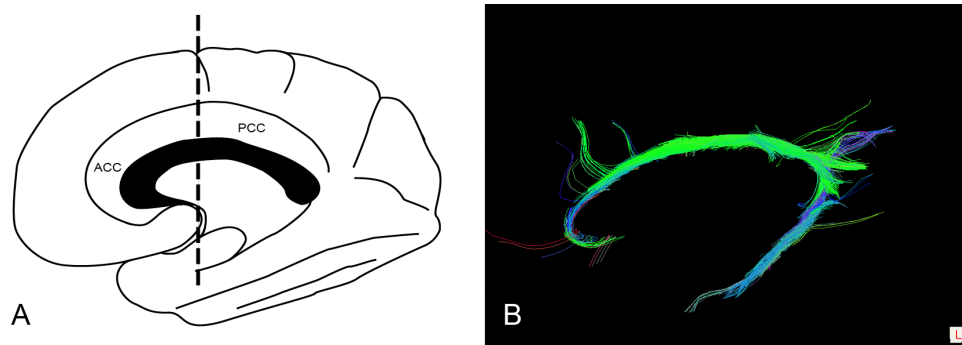
al. 2013; Mahoney, Ridgway et al. 2014). DTI seems to be better to distinguish FTD from controls than imaging measures of GM atrophy (Zhang, Tartaglia et al. 2013), and DTI gives added power in the discrimination between FTD and AD, compared with GM atrophy only (McMillan, Brun et al. 2012).

- In presymptomatic mutation carriers (MAPT, PGRN) DTI, together with resting-state fMRI, seems to be a more sensitive MRI modality than GM atrophy alone (Dopper, Rombouts et al. 2013).
- DTI variables seem to be able to differentiate between the underlying pathology (TDP-43/Tau) ante mortem in some regions, with Tau pathology showing larger changes in DTI parameters than cases with TDP-43 pathology (McMillan, Irwin et al. 2013).

# The anterior cingulate cortex

## *Anatomy*

The gyrus cinguli is a cortical fold stretching along and circling the corpus callosum in its full length on the medial surface of each hemisphere (Figure 1). On a cytoarchitectural basis the gyrus cinguli is classically divided into an anterior and posterior part, the anterior cingulate cortex (ACC; BA 24, 25, 32 and 33) and posterior cingulate cortex (PCC; BA 23, 31), the division roughly being mid-callosal. The distinction between these areas is based on ACC being an agranular cortex (lacking a cytoarchitectural layer IV), and the PCC is not (von Economo 1925). There is a cytoarchitectural change ventro-dorsally in the ACC: from the callosal sulcus the ACC contains a region 33, then 24a, 24b (covering the crown of the gyrus) and 24c, usually in the banks of the cingulate sulcus (Vogt, Nimchinsky et al. 1995). The ACC also has a ventro-dorsal subdivision (ventral and dorsal ACC), the latter also designated the mid-cingulate cortex (MCC) (Vogt, Berger et al. 2003). Different regions of the ACC display variances in cytoarchitecture, cytology, receptor profiles, connectivity and function (Palomero-Gallagher, Vogt et al. 2009). A characteristic feature of the ACC is the presence of a neuronal type almost exclusively found in the ACC and frontal insula, the von Economo neurons (VENs), which will be described in detail below.



**Figure 1.**

A. Illustration of the medial surface of the right hemisphere, with the main divisions of the gyrus cinguli: the anterior cingulate cortex (ACC, BA24) and posterior cingulate cortex (PCC, BA 23). B. The cingulum bundle of the right hemisphere, as rendered by diffusion tensor tractography.



The corresponding white matter tract of the cingulate cortex is the cingulum tract, or cingulum bundle (CB) (Schmahmann and Pandya 2006; Nieuwenhuys 2007; Beckmann, Johansen-Berg et al. 2009; Catani and Thiebaut de Schotten 2012), which stretches along the cingulate cortex, from its most anterior part to the splenium of the corpus callosum. It then exits the PCC to form a ventral branch that continues in the medial temporal lobe. The CB contains both fibers going to/from the cingulate cortex itself (bidirectionally), but also fibers “passing through” from other parts of the cortex, as well as short U-fibers connecting the cingulate cortex with adjacent gyri. It is known, mainly from post-mortem injection studies in the monkey, and largely confirmed with DTI, that the ACC connects to the orbitofrontal, dorsolateral frontal and anterior insular cortices, posteriorly to the parietal cortex and ventrally to the temporal lobe, more specifically parahippocampal and entorhinal cortices. The ACC also has connections with the basal ganglia, thalamus, amygdala, as well as prominent connections to more inferiorly located regions such as the hypothalamus, the mesencephalon (including periaqueductal grey, monoaminergic nuclei), and pons (ventral tegmental area, parabrachial nucleus). There are differences in the connections between the divisions of the ACC: the ventral part of the ACC has more connections with orbitofrontal cortex, amygdala, ventral striatum and hypothalamus, while the dorsal ACC/MCC has direct connections to cortical motor areas and spinal cord.

### *Function*

The ACC participates in a vast array of mental processes. There have been many attempts to provide a coherent summary of its functions, which are a matter of controversy (Gasquoin 2013). From an anatomical perspective it is clear that the divisions of the ACC have different cytoarchitecture, receptor profiles, and connectivity. The most popular is the view by Bush et al. (Bush, Luu et al. 2000), that the ACC also functionally is separated into a ventral ACC and a dorsal ACC/MCC, where the latter is involved in motor functions, pain physiology and cognitive conflict monitoring while the ventral ACC is more involved in reward, decision making and in the experience of negative affect. In this context it should be pointed out that the ACC is, dependent on task, very frequently coactivated with the dorsolateral prefrontal cortex, the orbitofrontal cortex, and the insula.

Another important way of understanding ACC function that has emerged during the last years is the analysis of the so called intrinsic functional network connectivity. By analysis of which fMRI correlations that arise spontaneously in the resting brain, there appears to be different basic functional networks in the cerebrum. The default mode network (DMN) has its main hubs in the posterior cingulate cortex/precuneus and the medial prefrontal cortex/ventral ACC, (Raichle, MacLeod et al. 2001). When activity occurs, the DMN is attenuated and other networks are recruited, most

notably the “executive-control-network”, and the “salience” network, the latter having its main hubs in the dorsal ACC and the frontal insula (Fox, Snyder et al. 2005; Seeley, Menon et al. 2007; Taylor, Seminowicz et al. 2009).

#### *The anterior cingulate cortex in bvFTD*

The ACC is involved in a large variety of clinical conditions: pain physiology, drug addiction, depression, obsessive compulsive disorder, ADHD, schizophrenia, and neurodegenerative disorders (Gasquoin 2013). The ACC involvement appears central in bvFTD, which has consistently been demonstrated in bvFTD imaging metaanalyses (Schroeter, Raczka et al. 2008; Schroeter, Laird et al. 2014). Commonly, the atrophy dominates in dorsal ACC/MCC, extends to the frontomedian cortex, and involves the subcallosal and subgenual cortex. The ACC is affected in both sporadic and genetic variants of bvFTD (Whitwell, Przybelski et al. 2009; Whitwell, Weigand et al. 2012). Involvement of the cingulum bundle is one of the most consistent finding in DTI studies of bvFTD (see above). Involvement of this structure seems to be an early finding in bvFTD, with ACC and frontomedian atrophy demonstrated in very early bvFTD (Seeley, Crawford et al. 2008), and diffusion changes in the cingulum bundle shown in presymptomatic mutation carriers (MAPT) (Dopper, Rombouts et al. 2013). In FTD, ACC atrophy is associated with core symptoms of this condition, such as apathy, (Rosen, Allison et al. 2005; Massimo, Powers et al. 2009; Borroni, Grassi et al. 2012), disinhibition (Franceschi, Anchisi et al. 2005; Hornberger, Geng et al. 2011; Borroni, Grassi et al. 2012), aberrant motor behaviour (Rosen, Allison et al. 2005) and executive deficits (Chiu, Papma et al. 2012). Also, the salience network, anchored in the dorsal ACC/MCC, is affected in bvFTD (Seeley, Crawford et al. 2009; Zhou, Greicius et al. 2010; Dopper, Rombouts et al. 2013) and is coupled to key symptoms (Zhou, Greicius et al. 2010; Chiong, Wilson et al. 2013)(Zhou 2010, Chiong et al 2013).

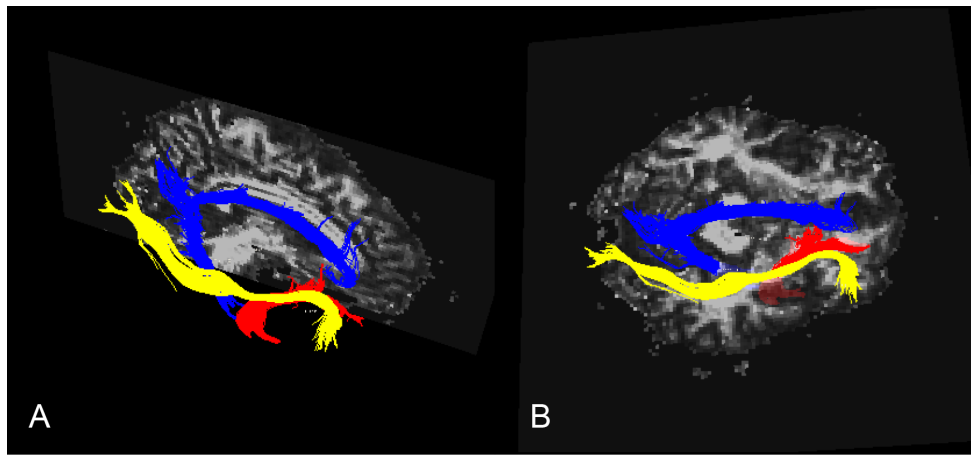
# The orbitofrontal cortex

## *Anatomy*

The orbitofrontal cortex (OFC) is the ventral part of the prefrontal cortex (PFC) facing the orbital roof. The medial OFC, together with the ventral parts of the medial PFC, is also delineated as the ventromedian prefrontal cortex vmPFC (Bechara, Damasio et al. 2000). The OFC is perhaps the most polymodal region of the cortex, receiving sensory inputs from five different sources: olfactory, gustatory, auditive, visual and somatosensory (Mesulam 2000; Schmahmann and Pandya 2006; Nieuwenhuys 2007; Catani and Thiebaut de Schotten 2012). The OFC is also interconnected with association cortices, importantly the anterior and superior temporal lobe, occipital cortex, and the insula. The OFC (as the ACC) has dense projections to structures such as the amygdala, entorhinal cortex/hippocampus, hypothalamus, periaqueductal grey, mesencephalic monoaminergic and cholinergic nuclei, basal ganglia, and thalami. The OFC connections (Figure 2) can be divided in the following tracts: the inferior frontooccipital fasciculus (IFOF), the uncinate fasciculus (UF), the cingulum (Ci), and the anterior thalamic radiation, while the connections to the brainstem are organised in the medial forebrain bundle. In addition, it has contralateral connections through the corpus callosum. The IFOF and UF will be discussed here briefly.

The IFOF originates from the occipital lobe (lingual gyrus and cuneus) and has two main subdivisions, one terminating in the inferior frontal gyrus and one terminating in the OFC (Catani and Thiebaut de Schotten 2012; Forkel, Thiebaut de Schotten et al. 2012; Sarubbo, De Benedictis et al. 2013). It should be noted that as most association fibre systems, the connections of the IFOF are bidirectional, and thus “to/from” and “originate/terminate” are interchangeable. It runs, together with the UF, in the external and extreme capsule. Its precise function is unknown, but it appears to be involved in visual perception, attention and semantic processing.

The UF runs more ventral to the IFOF in the extreme and external capsule. It connects the abovementioned structures of the temporal lobe with the OFC and ACC, in addition to the insula (Schmahmann and Pandya 2006; Catani and Thiebaut de Schotten 2012; Von Der Heide, Skipper et al. 2013). Not surprisingly, given the areas it connects, the UF is implicated in a number of mental functions: emotional processing, memory, behavioural regulation, social cognition and language.



**Figure 2.**

Association tracts to/from the orbitofrontal cortex, as rendered by diffusion tensor imaging tractography. Blue is the cingulum bundle, yellow the inferior frontooccipital fasciculus, and red is the uncinate fasciculus, all in the right hemisphere. A is lateral and B superior view.

### *Function*

As with the ACC, the precise function of the OFC is under debate. A standard view (Kringelbach 2005; Nieuwenhuys 2007; Fuster 2009) is that the OFC integrates motor, cognitive and emotional information to regulate behaviour, either by promoting goal-directed, reward seeking behavior or by inhibiting behaviour. Damage to the OFC is classically associated with the “orbital prefrontal syndrome”, a disinhibited syndrome with disturbed attention, stimulus bound behaviour, perseveration, hyperactivity, impulsivity, and inappropriate social behaviour with disregard for others (Bechara, Damasio et al. 2000; Mesulam 2000; Fuster 2009). These are all characteristic symptoms in bvFTD where many of the core symptoms needed for diagnosis can be formulated as a failure to inhibit behavioural patterns (Viskontas, Possin et al. 2007).

### *The orbitofrontal cortex in bvFTD*

Involvement of the OFC is an early and consistent finding in bvFTD (Schroeter, Raczka et al. 2008; Seeley, Crawford et al. 2008; Schroeter, Laird et al. 2014). Clinico-anatomical correlation studies in bvFTD have mainly linked OFC atrophy to disinhibition (Franceschi, Anchisi et al. 2005; Rosen, Allison et al. 2005; Peters, Perani et al. 2006; Massimo, Powers et al. 2009; Hornberger, Geng et al. 2011; Borroni, Grassi et al. 2012). However, there are inconsistencies: one VBM study (Zamboni, Huey et al. 2008), did not show an association with OFC atrophy, but instead temporal lobe atrophy only, while others have related both disinhibition and

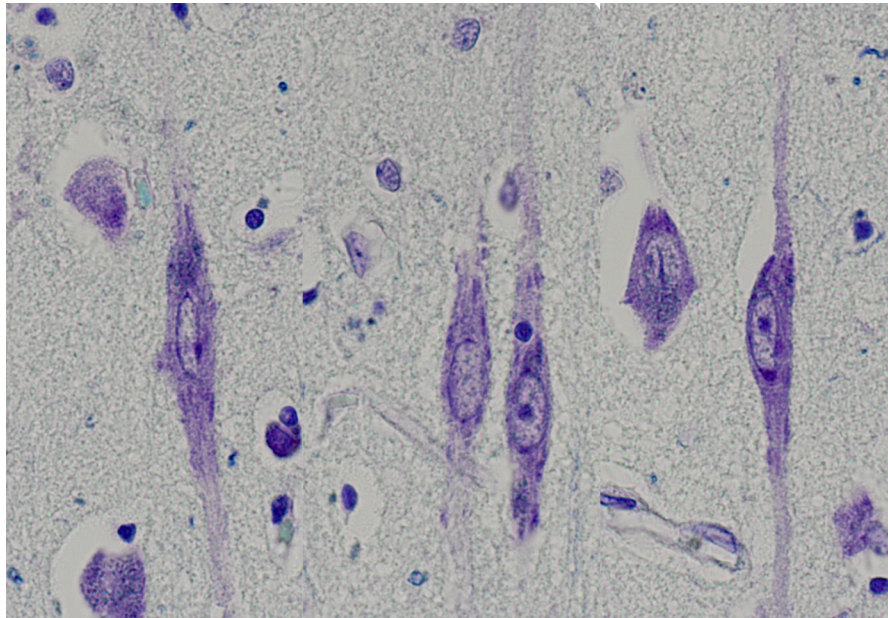
apathy related to the OFC (Peters, Perani et al. 2006; Massimo, Powers et al. 2009). Also, atrophy of the right temporal lobe alone seems to be sufficient, in the (relative) absence of OFC pathology, to cause behavioural disturbances with disinhibition. In FTD this is seen in right temporal variants (including MAPT mutations) and patients with SD (Bozeat, Gregory et al. 2000; Snowden, Bathgate et al. 2001; Thompson, Patterson et al. 2003; Passant, Ostojic et al. 2004; Seeley, Bauer et al. 2005), consistent with the role of the temporal lobe and amygdala for regulation of behaviour and emotion (Olson, McCoy et al. 2013).

# Von Economo Neurons

The large bipolar cells of the anterior cingulate cortex (ACC) and frontoinsular cortex (FI) that we today call von Economo neurons (VENs), have been described by several authors in the history of neuroscience (Butti, Santos et al. 2013). The first detailed description of these cells, however, was given in 1926 by Constantin von Economo (von Economo 1925; Economo 1926; Seeley, Merkle et al. 2012), who named them “spindle cells”. To avoid confusion with the fusiform spindle cells of cortical layer VI, the name von Economo neurons (VENs) was adopted (Seeley, Merkle et al. 2012).

The classical description of a VEN is an elongated, large, fusiform neuron, with one apical and one basal process of approximately the same size (von Economo 1925; Nimchinsky, Vogt et al. 1995; Seeley, Merkle et al. 2012) (Figure 3). “Variants” have also been described: with shorter, less slender, and curved VENs, as well as VENs with bifid basal dendrite and VENs with occasional processes emerging from the soma (Nimchinsky, Vogt et al. 1995). The dendritic tree is sparse regarding ramification, intersections and spines in comparison with ordinary pyramidal neurons, and seem to preferentially sample supragranular layers (Watson, Jones et al. 2006). VENs are generally larger than layer V pyramidal neurons (Nimchinsky, Gilissen et al. 1999; Allman, Tetreault et al. 2010; Evrard, Forro et al. 2012). In their detailed description of the human cerebral cortex von Economo and Koskinas only noted VENs in the ACC and FI, however they have also been described in the subiculum, entorhinal cortex (Butti, Santos et al. 2013) and in the dysgranular dorsolateral prefrontal cortex (BA9) (Fajardo, Escobar et al. 2008). Characteristically, VENs are located in layer Vb in clusters of three to six neurons (Nimchinsky, Gilissen et al. 1999). Both in the ACC (Nimchinsky, Vogt et al. 1995) and FI (Allman, Tetreault et al. 2010) there is a rostro-caudal gradient in VEN density. In the ACC, they are more common in subarea 24b than 24a or 24c (Nimchinsky, Vogt et al. 1995). VENs are not labelled with calcium binding proteins such as parvalbumin, calbindin or calretinin, but strongly express nonphosphorylated neurofilament protein (NFL) (Nimchinsky, Vogt et al. 1995). This, in combination with VEN staining in retrograde tracing studies from the cingulum bundle, has led to the conclusion that VENs most likely are projection neurons (i.e. a neuron that projects to a distant location outside the area where it is found). VENs are strongly labeled by antibodies against vasopressin 1a, dopamine D3 and serotonin 2b receptors (Allman, Watson et al. 2005), and, intriguingly, by antibodies against disrupted in

schizophrenia-1 (DISC1) (Allman, Tetreault et al. 2010). Studies vary in their estimation of VEN density relative non-VEN neurons, in the ACC from 0.5-1% (Kaufman, Paul et al. 2008) to 5.6% in layer V (Nimchinsky, Gilissen et al. 1999). Generally they are denser in the FI than the ACC. A study of transcription factor content showed that VENs preferentially express the subcortical projection neuron markers, (Cobos and Seeley 2013), which is indicative of subcortical projections neurons. To this day no tracing study has determined their axonal termination.



**Fig 3**

Von Economo neurons of the anterior cingulate cortex, at x400 magnification , stained with LFB. Second right is a non-VEN (pyramidal) neuron.

#### *Evolutionary and ontogenetic perspective*

Initially, based on the study by Nimchinsky et al. (Nimchinsky, Gilissen et al. 1999), VENs were thought to be a specialization of higher primates, since these authors only found VENs in the human and great apes (bonobos, chimpanzees, gorillas and the orangutan) and not in other primates. Later, VENs were described in elephants and cetaceans (Hof and Van der Gucht 2007; Butti, Sherwood et al. 2009; Hakeem, Sherwood et al. 2009), which lead to the idea of VENs being a parallel-evolved specialized cell for more complex social life, or an adaptation to greater brain size. However, since then VENs have been described in several other mammals (Butti and Hof 2010) including a lesser primate, the macaque (Evrard, Forro et al. 2012). A current interpretation is that VENs have evolved several times under comparable

evolutionary pressures for social survival in very diverse species (Butti, Santos et al. 2013). Ontogenetically, VENs appear only in small numbers in both ACC and FI during prenatal development (gestational week 36) but increase after birth and reach adult numbers first at four years of age (Allman, Tetreault et al. 2010). This is in contrast with neurogenesis of “normal” pyramidal neurons in layer V that peaks in the first trimester.

### *Possible functions*

At present, there is only limited evidence for the functional role of VENs, derived from the data presented above. Some current hypotheses are involvement in social-emotional development (Butti, Santos et al. 2013), conscious emotional awareness (Craig 2009), perception of bodily states and integration in decision making (Allman, Watson et al. 2005), self-awareness and insight (Brune, Schobel et al. 2011; Kim, Sidhu et al. 2012), or a role as motoneurons of the cortico-autonomic pathway (Butti et al 2011). Given the overlap between areas of VEN distribution and the anchoring regions of the salience network, one hypothesis is that VEN somehow contributes to the establishment of this network (Seeley 2008; Seeley, Crawford et al. 2009), to facilitate or augment social-emotional functioning. Particularly, based on possible “distant subcortical transmission” VENs have been hypothesized to connect the ACC and FI to the subcortical anchor points of the salience network, the periaqueductal grey (PAG) and parabrachial nucleus (PBN) (Zhou, Greicius et al. 2010).

### *VENs in disease*

VEN pathology has been proposed to have an important role in the pathophysiology of several psychiatric and neurological conditions, and a brief summary will follow. Two initial studies examined VENs in autism (Kennedy, Semendeferi et al. 2007; Simms, Kemper et al. 2009), and found almost identical VEN density in cases of autism and controls in the FI and ACC. However, a subset of cases seem to have unusually high VEN numbers, with irregular distribution in layer VI and white matter (Simms, Kemper et al. 2009). This was partially confirmed by Santos et al (Santos, Uppal et al. 2011) who showed that the ratio between VEN and normal pyramidal neurons were considerably higher in children with autism compared with controls. VENs have also been studied in schizophrenia. Brüne et al (Brune, Schobel et al. 2010) found no differences in mean VEN density in the ACC across groups of schizophrenia, bipolar disorder and healthy controls, but lower density in cases of early onset schizophrenia. However, when duration of illness was taken as a cofactor, these finding did not remain significant. The same research group (Brune, Schobel et al. 2011) divided their bipolar disease and schizophrenia cohort in cases whose death



was caused by suicide and those that were not, and found a higher VEN density in the suicide group.

In 2006 a group of researchers tested the hypothesis that VENs were selectively affected in bvFTD, and found a marked, 74%, reduction of VEN density in the ACC of 7 patients with bvFTD, compared with controls, while neighbouring normal pyramidal neurons were unaffected (Seeley, Carlin et al. 2006). VEN density in AD was only slightly affected. The change was seen across all protein pathology subtypes. In a follow-up study of the FI in 9 cases with bvFTD the same group showed a selective loss of VEN of 56% compared with controls (Kim, Sidhu et al. 2012). In this study, antemortem behavioural rating was available, and VEN levels showed a negative correlation with behavioural scores (disinhibition).

# The present investigation

The present thesis is based on four separate studies (Study I-IV), which are found in the appendix. For the full description of each study, the reader is referred to the appendix. What follows is a short summary of the content of each paper, with an extended discussion. The extended discussion concentrates on some of the more important methodological aspects of the papers, discusses the findings in a general context, and suggests possible directions for future research.

## Study I

### *Aim*

As described in the background, evaluating the presence of cortical atrophy on morphological MRI images has a suboptimal sensitivity for FTD, and the clinician is recommended to use supplementary functional imaging examinations such as SPECT and FDG-PET when there is clinical suspicion of FTD and the MRI is judged as normal. MRI-DTI studies of white matter in bvFTD have consistently shown involvement of frontal and temporal white matter. Thus, DTI might be used to enhance the diagnostic potential of the MRI examination. However, to explore the potential of DTI in this context, direct comparison between DTI of white matter and structural measurements of grey matter is needed, which is the design used in Study I.

### *Methods*

Patients and controls were recruited from the Lund Prospective Frontotemporal Dementia Study (LUPROFS), a longitudinal study of patients with any of the frontotemporal dementia spectrum disorders. We examined the anterior cingulum bundle in 14 patients with behavioral variant frontotemporal dementia diagnosed according to the FTDC criteria and 22 healthy controls using deterministic manual diffusion tensor tractography. DTI parameters (FA, MD, aD and rD) were extracted from the white matter tract and compared with two measures of grey matter structure, voxel based morphometry (VBM) and cortical thickness, in the anterior cingulate cortex (ACC).

### *Results*

Statistically significant changes between patients and controls were detected in all DTI parameters, with large effect sizes. ROC-AUC was for the DTI parameters: 0.92 (FA) to 0.97 (rD), compared with 0.82 for the best cortical parameter (VBM). Results from the AUC were confirmed with binary logistic regression analysis including demographic variables, but only for FA and MD. Ability to classify patient/non-patient status was significantly better for MD vs. VBM, and borderline significant for FA vs. VBM.

### *Conclusion*

The results indicate that DTI assessment of white matter could offer advantages in comparison with the assessment of cortical grey matter in differentiating patients with bvFTD and controls.

### *Discussion of methodological issues*

Several methodological aspects of the study are discussed in the paper, such as the potential influence of partial volume effects, the issue of cingulate/paracingulate variability, choice of approaches to diffusion imaging, and the lack of definitive diagnosis or stratification of patients according to genetics or molecular neuropathology.

I would like to emphasize two other issues. Firstly, the issue of concomitant “vascular” pathology as a confounder. In Study I our aim was to measure diffusion changes in white matter secondary to the neurodegenerative process, and not white matter changes secondary to concomitant vascular pathology. To show that the patient and control groups were similarly affected by vascular burden, white matter hyperintensities (WMH) were rated according to the scales of Fazekas (Fazekas, Chawluk et al. 1987) and Wahlund (Wahlund, Barkhof et al. 2001) and compared. WMH burden was higher among bvFTD patients, but did not show any statistically significant difference. However, this approach does not strictly demonstrate that there is no relationship between WMH and diffusion parameters in the bvFTD group. Also, if a relationship between WMH and diffusion parameters is shown, the problem remains to interpret the origin of the WMH which may, but need not, be vascular (Papma, de Groot et al. 2014). Studies in FTD, using post-mortem follow up or post-mortem MRI have shown that it is difficult to determine the type of white matter disease process (neurodegenerative vs. vascular) based on visual assessment of MRI in FTD (Larsson, Passant et al. 2000), although mostly the origin will be neurodegenerative (De Reuck, Deramecourt et al. 2012; De Reuck, Deramecourt et al. 2012). Unless patients die unexpectedly and undergo a post mortem follow-up, determining the origin of the WMH in single cases will be by inference, and this remains a potentially biasing factor in this and similar studies.

Secondly, a methodological issue not discussed in the published article (Study I) is that of selection and representativeness. The selection process could influence how representative the diagnostic potential is for the larger, “general” bvFTD population. In the LUPROFS study, only approximately 50% of the patients with suspected bvFTD that were screened for participation in the study were de facto included in the study cohort. The main reasons for exclusion were unwillingness to participate, not being able to perform the MRI scan, or meeting general exclusion criteria such as availability of close informant, geographical limitations, concomitant alcohol abuse, and cerebrovascular burden. Also, the use of FTDC bvFTD criteria might potentially exclude patients with less typical presentations of bvFTD (sensitivity being 86%) (Rascovsky, Hodges et al. 2011). In summary this will probably limit generalizability of the findings to a more “prototypical” type of bvFTD case. Also, the healthy controls in Study I are recruited on a convenience manner, which has resulted in a control group with higher education than patients. Possibly, these controls also have less risk factors for general cerebral pathology and higher cognitive reserve (with different structural counterpart in the make-up of grey vs. white matter) that could exaggerate the differences seen in the study.

*Discussion: the findings in context and future prospects*

The main finding of Study I, i.e. that DTI has greater discriminatory potential than grey matter imaging in a direct comparison, has been demonstrated in parallel by Zhang et al. 2013 (Zhang, Tartaglia et al. 2013). Also, studies have shown that the combination of GM imaging and DTI has greater classification accuracy than grey matter alone (McMillan, Brun et al. 2012), and that DTI is more sensitive for progression than grey matter (Lam, Halliday et al. 2014). Also, the study by Dopper et al (Dopper, Rombouts et al. 2013) in a group of asymptomatic (PGRN and MAPT) mutation carriers, demonstrated that DTI shows change earlier than grey matter atrophy. Together, these studies provide an impetus for exploring the direct clinical utility of DTI imaging in a naturalistic clinical setting. In clinical practice, the majority of patients with suspected bvFTD undergo an MR as part of the work-up, and adding the extra diffusion sequence is feasible, which make diffusion imaging practical and economical, comparing to adding SPECT or PET when the conventional MRI is “negative”. Questions that should be explored are: what diffusion sequence is the most robust? How do we post-process diffusion sequences and quantify diffusion changes to be easily interpreted for the clinician? Also, we would need comparisons with other clinical entities (vascular dementia, alcohol dementia, psychiatric disorders), and take into account the genetics and the protein pathology of bvFTD.

## Study II

### *Aim*

Despite a large number of previous studies on this subject, the clinico-anatomical underpinnings of disinhibition in bvFTD remain controversial. The aim of study II was to examine this clinico-anatomical relationship with two (possible) methodological improvements: the use of a) neuropsychological assessment in addition to symptom rating scales and b) structural network examination of white matter tracts (with DTI) in addition to assessment of cortical grey matter.

### *Methods*

In 12 patients with behavioural variant frontotemporal dementia and 9 patients with progressive supranuclear palsy from the LUPROFS cohort, disinhibition was assessed with a neuropsychological test (the Hayling test) and the frontal behavioural inventory (FBI), a caregiver information-based clinical rating scale. Results were correlated to cortical thickness and with diffusion parameters of selected tracts.

### *Results*

Disinhibition as assessed with the Hayling test and FBI was related to the diffusion properties of the UF and anterior Ci of the right hemisphere, in addition to the forceps minor of the corpus callosum. The neuropsychological and rating scale measures of disinhibition were also correlated with cortical thickness of the right parahippocampal gyrus, right orbitofrontal cortex and right posterior insula.

### *Conclusion*

The results support an associative model of inhibitory control, anchored in a medial temporal lobe/orbitofrontal network, interconnected by the uncinate fasciculus. These findings can explain some divergences among previous studies.

### *Discussion: methodological issues.*

Several methodological aspects of the study are discussed in the paper, such as selection of cases, lack of definitive diagnosis, and lack of the possibility to stratify patients according to genetics or molecular neuropathology. Choice and segmentation of the white matter tracts studied is discussed, and limitations of the DTI methods used for delineations of tracts. Additional methodological issues of importance will be discussed below.

Although (dis)inhibition is a commonly used term in neuroscience, some comment is needed. The phenomenon of inhibition is firmly established in neuroscience on some levels, such as biochemical and system levels (i.e. inhibitory function of GABA,

inhibition in the cortico-subcortico-thalamic circuits). The situation is different for behaviour. In the commonly used model “lower” (primitive) behaviours (i.e. urge to take the candy, urge to hit someone, urge to flee), are inhibited by “higher” (more sophisticated) centers (Huey, Zahn et al. 2007). However attractive, the existence of such an inhibitory mechanism in a strict neuroscientific sense is demonstrated experimentally only for a limited set of behaviours, such as motor tasks (Aron 2007). Thus behavioural inhibition and disinhibited behaviour could be explained by other mechanisms, such as a failure to choose when there is conflict, a failure to amplify the most rewarding stimuli, or to value short term versus long term consequences of behaviour.

The choice of caregiver information based rating scales for measurement of disinhibition is motivated by the possibility to measure behaviour over long time periods, and in the natural environment of the person, presumably leading to a high ecological validity. A problem common to these scales is the reliance on the caregiver, and that there is little evaluation of the contextual influence on the behaviour. In the case of Study II we employed the Frontal Behavioural Inventory (FBI). The FBI does not have a single “disinhibition” item, but the item impulsivity most strictly captures this symptom. We regarded the use of a single item as probably too insensitive and with too little range. We used an often employed pragmatic solution, to collapse all items that include aspects of decreased inhibitory control into a composite item, the FBI 12-22, with the risk of losing validity. In our case, although the team making the FBI assessments is limited, a drawback is that we had no common training or testing of reliability among the raters.

The neuropsychological test can solve some of the problems of the caregiver information based rating scales. Although verbal, the Hayling task (Burgess and Shallice 1997) is close to a simple motor inhibition task. However, as with many neuropsychological tests, how performance on the Hayling relates to behavioural inhibition outside the office is not examined. In the context of correlational anatomy, one could also question to which extent even a neuropsychological inhibition measure such as the Hayling test, Stroop, Wisconsin Card Sorting Test, etc. can be completely separated from social cognitive functions, since eventually external rules are given and are to be followed with the testing being in a social context.

#### *Discussion: the findings in context and future prospects*

We found disinhibition to be coupled to a medial temporal–orbitofrontal network, including its structural connection, the UF. The finding of disinhibition coupled to grey matter of the OFC and temporal lobe, has been shown in a large number of studies (see above), and an association with the UF is emerging in both bvFTD (Hornberger, Geng et al. 2011) as in psychopathy (Von Der Heide, Skipper et al. 2013), which together strengthens the notion of this network being central in

behavioural inhibition. Lack of inhibitory control/impulsiveness is an important clinical problem in a number of neurologic and psychiatric conditions, from cerebrovascular disease to addiction, neuropsychiatric and personality disorders. We believe that combining grey and white matter assessment holds promise to better explore what networks are affected in these conditions.

The use of DTI in the anatomical correlation method could probably be enhanced in future studies. Novel DTI sequences offers possibilities of a higher spatial resolution than that employed in the current studies (Jones 2008). Various approaches to the problem of “kissing” and crossing fibres have also been developed (Tournier, Mori et al. 2011), which offers a better tract delineation and increases anatomical precision. In parallel, combining information from tracing studies in non-human primates (Thiebaut de Schotten, Dell'Acqua et al. 2012) and post-mortem dissections in humans (Sarubbo, De Benedictis et al. 2013) with DTI is leading to an increased level of anatomical understanding of the white matter tracts. In summary, this could lead to the possibility of a more detailed disentanglement of structural networks, with possibilities to improve the clinico-anatomical correlation method.

Future studies of disinhibition in neurodegenerative disease could aim at a more stringent operationalization of (dis)inhibition, particularly how this phenomenon is related to functions such as social cognition, decision making and evaluation of positive/negative reinforcement over time. The use of rating scales constructed for such a purpose and not primarily for diagnostics or clinical symptom monitoring, would likely constitute an improvement. Future studies would likely benefit from further use of neuropsychological tests for assessment of behaviour, and in the context of bvFTD non-verbal inhibitory tests clearly would be an improvement (O'Callaghan, Hodges et al. 2013).

## Study III and IV

### *Aims*

Previous studies have shown a selective reduction of von Economo neurons (VENs) in the ACC and FI in bvFTD. However, these results came from one single research group, and with a limited number of patients (Seeley, Carlin et al. 2006; Kim, Sidhu et al. 2012). The aim of Study III was to independently replicate these findings in a larger cohort. Also, the alleged selectivity rests on the comparison between VENs and other neurons in cortical layer V, while it's established that neurons in the superficial cortical layers (I-III) are particularly affected in bvFTD (Brun 1987). Thus selectivity of VEN loss in bvFTD needs to be compared with the loss of neurons in superficial cortical layers; this was the aim of study IV.

### *Methods*

Study III. VENs and neighbouring neurons (NN) were quantified in layer Va and Vb of the right dorsal ACC in 21 post-mortem cases of behavioural variant FTD, 10 cases of AD and 10 non-demented controls. VENs and NN were defined by morphological criteria, and counted on digitalized images scanned from a single slice at x 200 in light microscopy.

Study IV. VENs and non-VEN-neurons of cortical layer V and corresponding layer II+III were quantified in the anterior cingulate cortex in 16 cases of neuropathologically early bvFTD, 12 non demented controls and 10 cases of AD.

### *Results*

Study III. A marked VEN reduction in the ACC was seen in bvFTD cases compared with controls (53% loss). A smaller and statistically non-significant reduction was seen in AD. The difference between AD and bvFTD was statistically significant only in a post-hoc analysis, including only cases with neuropathologically early (mild) bvFTD. TDP-43 and tau positive cases did not differ statistically with regard to VEN reduction.

Study IV. In bvFTD VENs were more depleted than non-VEN-neurons of layers V and II+III. Also, non-VEN-neurons of layer II+III showed a greater density reduction than those of layer V in bvFTD. VEN density was also reduced in AD, albeit to a lesser extent than in bvFTD, the difference between bvFTD and AD being significant only when relating VEN loss to that of layer V neurons, but not to neurons in layer II+III.

### *Conclusion*

The studies strengthen the view of VENs as a particularly sensitive neuronal type in bvFTD, also when compared to AD and non-demented controls. VEN reduction appears to be prevalent in all major protein pathology subtypes. VEN loss is accompanied by the reduction of other neurons, but is in terms of proportionality more pronounced than loss of other neurons in the deeper parts of the cortex.

### *Discussion: methodological issues*

Several methodological aspects of the study are discussed in the papers and will be only briefly mentioned here. Important aspects concern employment of a non-stereological method for neuron quantification, potential loss of blinding, retrospective nature of clinical diagnosis and assessment of duration, and inability to determine clinical severity at time of death. In study IV we aimed at selectively investigating neuropathologically early cases. With the generally lower age at onset and disease duration found in neuropathological series of FTD, an age-matched AD



cohort resulted in the finding of an AD group with longer disease duration. Apart from the cases with a neurodegenerative disorder without dementia, clinical ante-mortem assessment of our non-demented controls was lacking, which is a limitation.

*Discussion: the findings in context and future prospects.*

With the original studies, the replication in Study III, and subsequent replication from others (Tan, Wong et al. 2014), the notion of a selective vulnerability of VENs in bvFTD seems to be established. Also, Study IV shows that VEN loss also appears greater than loss of non-VEN neurons in cortical layer II and III, which previously were considered to be the most vulnerable neurons. There remains a multitude of questions regarding the role of VENs in FTD.

Where and when in the neurodegenerative process does the VEN loss occur? There is emerging evidence for a transsynaptic “prion like” spread of aggregating molecules in neurodegenerative disease (Li, Englund et al. 2008; Hardy and Revesz 2012). This is especially important with the emerging notion of neurodegenerative disease targeting defined functional-structural networks of the healthy brain (Seeley, Crawford et al. 2009; Raj, Kuceyeski et al. 2012). However, proteins that aggregate in a pathological fashion in the neurodegenerative diseases (tau, amyloid, TDP-43) are present in most neurons. Thus there is a need to find the morphological missing link that shows a particular propensity for protein aggregation, and that shows correspondence with healthy functional-structural networks and disease patterns (Seeley 2008; Warren, Rohrer et al. 2012). Due to VEN morphology, their overlap with functional networks, overlap with early affected regions in bvFTD and now evidence of selective loss of VENs in bvFTD, VENs appear to be a candidate for being such a link. Such a neuron would be a candidate structure when developing therapies to halt disease progression (Warren, Rohrer et al. 2012). However, to demonstrate this with more stringency, much remains to be resolved. First, there needs to be sharper evidence of VEN selectivity. We have shown that VENs are more selectively targeted than a collapsed layer II and III cell population, but these cortical layers may very well harbour other cell types, either defined by morphology, biochemistry or connectivity which may be more selective. Also, VEN selectivity for the molecular pathological processes should be proven, which for example could be made by measuring the intraneuronal TDP-43 aggregates in FTLD-TDP-43 (Mackenzie type A and B). Further, we need stronger evidence of which are the most early affected regions in bvFTD disease progression. Today the concept of “earliest” regions affected rely on studies of very early bvFTD (Seeley, Crawford et al. 2008), or presymptomatic PGRN/MAPT mutation carriers (Dopper, Rombouts et al. 2013). While the study of Seeley indicates early FI/ACC atrophy, critical points can be made: the medial prefrontal involvement appears more frontomedian rather than purely cingulate (BA 32, BA24c, > BA 24a/b). The same study also highlights several other structures (hippocampus, thalamus). In the study by Dopper the presymptomatic patients show

a relatively widespread frontal involvement of association and commissural bundles tracts in MAPT carriers, not particularly centred on the FI/ACC. However they also show that the salience network anchored in the dorsal ACC/FI is targeted early. A classical approach in neurodegenerative disease is to derive a disease propagation scheme from a systematic cross-sectional neuropathologic examination of cases with varying disease stages at death. The most famous example is the Braak staging for AD (Braak, Alafuzoff et al. 2006) and Parkinson's disease (Braak, Del Tredici et al. 2003). In TDP-43-positive bvFTD the first attempts to develop a similar staging indicate that FI and ACC are not the regions first affected, but rather the amygdala and olfactory gyri (Brettschneider, Del Tredici et al. 2014). Third, it remains to be examined the full relationship between VENs and different neurodegenerative diseases. Today, most studies have focused on cases with TDP-43 pathology, but relationship with TDP-43 subtype or genetic status in bvFTD is not examined. There is a selective loss of VENs being reported in SD (Tan, Wong et al. 2014), but in end stage cases only, which makes the interpretation difficult. Our results indicate that tau-positive bvFTD have less VEN loss than do TDP-43-positive cases, however greater than in AD, but this finding has limitations being based on a limited number of cases. Other tau-positive conditions such as PSP remain to be studied.

Regardless of when VEN loss occurs in the disease progression, VENs may be an important cellular target for symptomatic treatment attempts. An analogy could be made with the nigrostriatal neurons in PD, which may not be the earliest affected cell type of the neurodegenerative process in Parkinson's disease (Braak, Del Tredici et al. 2003) but yet are important for symptomatology and treatment. This would need a more detailed understanding of VEN biology and function. Currently the lines of evidence from ontogeny ("late developing"), evolutionary biology ("late in phylogeny"), distribution (FI and ACC- "paralimbic" and with overlap with the salience network"), morphology (large, sparse dendritic trees, long transmission sites) and preliminary findings of receptor makeup, can only quite indirectly point to VEN functions. The vast array of techniques in molecular biology could enable further, systematic assessment of molecular and morphological makeup. Clearly, determination of the termination of their axonal termination would be a great step forward. Recently, VENs have been described in a laboratory animal, the macaque (Evrard, Forro et al. 2012), which would enable such studies.

## Erratum

In Study III, the level of VENs/10000 NN in bvFTD of Broe stages 1 and 2 is said to be 53%, compared with controls. This should be 63%.

## General summary and conclusion

The present thesis has explored morphological alterations on the micro- and macrostructural level in behavioural variant frontotemporal dementia (bvFTD) with the aim to improve diagnostic methodology, increase the understanding of behavioural consequences of the morphological alterations, and understanding the pathophysiology of this condition. Regarding the first aim, we show that DTI is a promising tool to improve the use of MRI in the diagnostic procedure of bvFTD. Secondly, the thesis show that imaging of pathology of structural brain networks, again using DTI, can improve understanding of how morphological alterations lead to behavioural disturbances seen in bvFTD. Lastly, we show how in bvFTD there is a selective degeneration of VENs, which is an attractive cellular candidate in elucidating the pathophysiological process from genetic/cellular pathology to alterations in brain morphology and thus the clinical condition.

# Populärvetenskaplig sammanfattning på svenska

Frontotemporal demens är ett sjukdomstillstånd där nervceller i hjärnans pann- ("fronto") och tinninglober ("temporal") förtvinar, vilket leder till en tilltagande cellförlust och uttunning av hjärnbarken i dessa områden. Till skillnad från Alzheimers sjukdom, den vanligaste demenssjukdomen, leder frontotemporal demens i första hand inte till försämrat minne och orienteringsförmåga, utan till förändringar av personlighet och beteende hos den drabbade. Orsakerna till sjukdomen är till största delen okända, det finns idag ingen bot och begränsade möjligheter till lindrande behandling. Det övergripande syftet med denna avhandling är att studera strukturella hjärnförändringar på såväl mikroskopisk nivå som med nyare bildgivande metoder, för att bättre kunna diagnosticera sjukdomen, för att belysa hur förändringarna leder till några av de typiska symtomen och hur dessa kan hjälpa oss att förstå de underliggande mekanismerna vid frontotemporal demens.

Avhandlingens första del rör hjärnavbildande tekniker. Diagnosen frontotemporal demens kan vara svår att ställa och läkaren tar idag alltid hjälp av en hjärnavbildande undersökning ("röntgen"), såsom skiktröntgen (datortomografi) eller magnetkameraundersökning (MR) av hjärnan, för att påvisa en uttunning av hjärnbarken i pann- och tinninglober. MR anses vara den känsligare av de två undersökningarna. Den typ av MR som används idag är dock inte alltid tillräckligt känslig för att i tidigt skede av sjukdomen kunna svara på om patienten har tecken till frontotemporal demens eller inte. Det finns alltså ett behov av att utveckla andra typer av MR undersökningar som lättare kan påvisa tidiga sjukdomsförändringar. Vid frontotemporal demens drabbas hjärnbarken (den grå substansen), men också de nervtrådar som går till och från barken, och som tillsammans utgör den så kallade vita substansen. Den vita substansen kan idag undersökas på ett detaljerat sätt med hjälp av en ny MR metod, så kallad "diffusion tensor imaging" (DTI). Huruvida MR-DTI har fördelar jämfört med att mäta uttunning av hjärnbarken för att diagnosticera frontotemporal demens vet man inte. Syftet med den första delstudien i avhandlingen var att undersöka om MR-DTI var bättre på att särskilja en grupp patienter med frontotemporal demens från en grupp friska individer jämfört med mätning av barkens tjocklek och volym, vilket visade sig vara fallet. DTI används idag inte för

diagnostik inom rutinsjukvård men studien är ett incitament till att anpassa och vidareutveckla metoden för vardagligt kliniskt bruk.

I avhandlingens andra del var syftet att undersöka bakgrunden till ett av de viktigaste symtomen vid frontotemporal demens, nämligen bristande hämning. Bristande hämning innebär att en person följer impulser som den tidigare kunde kontrollera och tar risker, gör oöverbägda handlingar och tar mindre social hänsyn. Tidigare har bristande hämning framförallt kopplats till skada och uttunning i pannlobens nedre delar. Bristande hämning har undersökts med tester och frågeformulär hos patienter med frontotemporal demens, och kopplingarna till sjukliga förändringar av den vita och grå substansen har undersökts. Vi fann att bristande hämning inte endast är kopplat till förändring av pannlobens nedre delar, utan till ett större nätverk bestående av pann- och tinningloben i höger hjärnhalva, och de nervtrådar som kopplar samman dessa områden. Resultaten har betydelse för att förstå flera tillstånd i hjärnan där bristande hämning förekommer, till exempel olika psykiatriska sjukdomstillstånd.

Varför drabbas just pann- och tinningloberna vid frontotemporal demens, i alla fall i sjukdomens tidiga skeden? Om vi kunde påvisa att det är någon särskild nervcell eller egenskap hos nervceller som förklarar detta, skulle detta kunna bidra till att hitta angreppspunkter för att utveckla sjukdomsmodifierande behandling. I avhandlingens tredje och fjärde del studeras en typ av nervceller, som nästan enbart finns i de områden som drabbas tidigast vid frontotemporal demens. Dessa nervceller kallas von Economo neuron efter den person som först beskrev dem. I tidigare, mindre studier har von Economo neuron visat sig vara särskilt drabbade vid frontotemporal demens, men inte vid exempelvis Alzheimers sjukdom. I avhandlingens tredje delstudie bekräftas de tidigare fynden från andra forskare, men i ett betydligt större material än tidigare. I den fjärde delstudien visas att von Economo neuron är mer drabbade än de nervceller som tidigare ansågs vara den absolut mest känsliga vid frontotemporal demens. Forskningsresultaten stärker hypotesen om att von Economo neuron kan vara en av förklaringarna till att frontotemporal demens drabbar just pann- och tinningloberna, och pekar på vikten av fortsatt forskning för att fördjupa vår förståelse av dessa nervcellers funktion i både den sjuka och friska hjärnan.

# Acknowledgements

A large number of scholars and colleagues have in various ways been of fundamental importance for this work.

Christer Nilsson, my main supervisor. Christer has been an excellent supervisor who has given me the opportunity to work as independently as possible, which I am very grateful for. Also, we have had ample opportunities to discuss various pros and cons of being split between clinical work, teaching, research, and family life, and Christer has generously shared his experience.

Elisabet Englund, my first co-tutor. If I had half the capacity of Elisabet I would consider myself very lucky. Elisabet is full of confidence and enthusiasm, which she has the capacity to let on to us surrounding her. This has proved to be invaluable. Thank you.

Lena Kilander, my second co-tutor. Thank you for your humour, scepticism and for introducing me to the subject of FTD and clinical research. My research in FTD started at Uppsala University, and I wish to thank the team there: Malin Degerman Gunnarsson, Maria Lindau, Johan Sundelöv, Elina Rönnemaa, Lena Skoglund, Hans Basun, Lars Lannfelt, Martin Ingelsson. At Uppsala PET centre/IMANET (old days): Henry Engler, Irina Savitcheva, Bengt Långström, and Juan Pablo (“JP”) Gambini.

I wish to thank the team at the Department of Geriatric Psychiatry which have been very important for me during these years: Karin Nilsson, Ulla Passant, Lars Gustafson, Helena Andersson, Susanna Vestberg, Madeleine Liljegren. Particularly I wish to thank Maria Landqvist Waldö for all the opportunities to share hopes and frustration of residency and PhD studies.

In a similar manner the staff at the Department of Pathology have been very helpful, and this thesis could not have been completed without their assistance, thank you Annette Persson, Anna Härfstrand, Camilla Lidman, Sanaz Mojighashghaei, and Hans Brunnström.

The team in at my present academic affiliation has been very helpful. Thank you particularly Carina Wattmo, Sebastian Palmqvist, Oskar Hansson and Lennart Minthön

The collaboration with the “MRI people” in Lund has been crucial for this thesis, both fun and inspiring. Thanks to Markus Nilsson, Jimmy Lätt, Johanna Mårtensson and Danielle van Westen. Working together with the “Huddinge people” has been very inspiring thanks to Olof (“the violinmaker”) Lindberg, Amir, and Lars-Olof Wahlund.

Thank you also to all master students who have had patience with me as a co-tutor during the years: particularly Karl (“Ove Knausgård”) Lundblad.

Conducting clinical research relies on having a professional clinical team. Thanks to you all present, and past (none mentioned, none forgotten)! Particular gratitude goes to my clinical tutor Cecilia Holmstrand.

I wish to thank my halftime review opponents Nenad Bogdanovic and Peter Johanssen, my research mentor David Erlinge, the statisticians Helene and Jonas, and the administrative staff at the faculty and the departments. Thank you Mediatryck and Regiondata for obvious reasons. Thanks to professor Howie Rosen and Bruce Miller for having me as a guest at University of California San Francisco.

I am grateful to the ALF committee, The Swedish Dementia Foundation, BAGADILICO and MULTIPARK research networks, The Ellen and Henrik Sjöbring foundation and the Trolle-Wachtmeister foundation for financial support.

Thanks also to Stefan B for showing me what this thesis is not about. Several good friends have put up with being a “help line” during these years, thank you all, particularly Fredrik.

Lastly, this would not have been possible without the support from my family—particularly during the last year, thank you Alexandra and Barbro. And to Carla and little Filiberto, thank you for being there.

# References

- Acosta-Cabronero, J., Patterson, K., et al. (2011). "Atrophy, hypometabolism and white matter abnormalities in semantic dementia tell a coherent story." *Brain* **134**(Pt 7): 2025-2035.
- Agosta, F., Scola, E., et al. (2012). "White matter damage in frontotemporal lobar degeneration spectrum." *Cereb Cortex* **22**(12): 2705-2714.
- Allman, J. M., Tetreault, N. A., et al. (2010). "The von Economo neurons in frontoinsula and anterior cingulate cortex in great apes and humans." *Brain Struct Funct* **214**(5-6): 495-517.
- Allman, J. M., Watson, K. K., et al. (2005). "Intuition and autism: a possible role for Von Economo neurons." *Trends Cogn Sci* **9**(8): 367-373.
- Aron, A. R. (2007). "The neural basis of inhibition in cognitive control." *Neuroscientist* **13**(3): 214-228.
- Avants, B. B., Cook, P. A., et al. (2010). "Dementia induces correlated reductions in white matter integrity and cortical thickness: a multivariate neuroimaging study with sparse canonical correlation analysis." *Neuroimage* **50**(3): 1004-1016.
- Bechara, A., Damasio, H., et al. (2000). "Emotion, decision making and the orbitofrontal cortex." *Cereb Cortex* **10**(3): 295-307.
- Beckmann, M., Johansen-Berg, H., et al. (2009). "Connectivity-based parcellation of human cingulate cortex and its relation to functional specialization." *J Neurosci* **29**(4): 1175-1190.
- Borroni, B., Brambati, S. M., et al. (2007). "Evidence of white matter changes on diffusion tensor imaging in frontotemporal dementia." *Arch Neurol* **64**(2): 246-251.
- Borroni, B., Grassi, M., et al. (2012). "Neuroanatomical correlates of behavioural phenotypes in behavioural variant of frontotemporal dementia." *Behav Brain Res* **235**(2): 124-129.
- Bozeat, S., Gregory, C. A., et al. (2000). "Which neuropsychiatric and behavioural features distinguish frontal and temporal variants of frontotemporal dementia from Alzheimer's disease?" *J Neurol Neurosurg Psychiatry* **69**(2): 178-186.
- Braak, H., Alafuzoff, I., et al. (2006). "Staging of Alzheimer disease-associated neurofibrillary pathology using paraffin sections and immunocytochemistry." *Acta Neuropathol* **112**(4): 389-404.
- Braak, H., Del Tredici, K., et al. (2003). "Staging of brain pathology related to sporadic Parkinson's disease." *Neurobiol Aging* **24**(2): 197-211.
- Brettschneider, J., Del Tredici, K., et al. (2014). "Sequential distribution of pTDP-43 pathology in behavioral variant frontotemporal dementia (bvFTD)." *Acta Neuropathol* **127**(3): 423-439.
- Broe, M., Hodges, J. R., et al. (2003). "Staging disease severity in pathologically confirmed cases of frontotemporal dementia." *Neurology* **60**(6): 1005-1011.
- Bron, E. E., Steketee, R. M., et al. (2014). "Diagnostic classification of arterial spin labeling and structural MRI in presenile early stage dementia." *Hum Brain Mapp* **35**(9): 4916-4931.
- Brun, A. (1987). "Frontal lobe degeneration of non-Alzheimer type. I. Neuropathology." *Arch Gerontol Geriatr* **6**(3): 193-208.
- Brune, M., Schobel, A., et al. (2010). "Von Economo neuron density in the anterior cingulate cortex is reduced in early onset schizophrenia." *Acta Neuropathol* **119**(6): 771-778.
- Brune, M., Schobel, A., et al. (2011). "Neuroanatomical correlates of suicide in psychosis: the possible role of von Economo neurons." *PLoS One* **6**(6): e20936.



- Brunnstrom, H., Gustafson, L., et al. (2009). "Prevalence of dementia subtypes: a 30-year retrospective survey of neuropathological reports." *Arch Gerontol Geriatr* **49**(1): 146-149.
- Burgess, P. and Shallice, T. (1997). *The Hayling and Brixton tests*. Thurston Suffolk, Pearson.
- Bush, G., Luu, P., et al. (2000). "Cognitive and emotional influences in anterior cingulate cortex." *Trends Cogn Sci* **4**(6): 215-222.
- Butti, C. and Hof, P. R. (2010). "The insular cortex: a comparative perspective." *Brain Struct Funct* **214**(5-6): 477-493.
- Butti, C., Santos, M., et al. (2013). "Von Economo neurons: clinical and evolutionary perspectives." *Cortex* **49**(1): 312-326.
- Butti, C., Sherwood, C. C., et al. (2009). "Total number and volume of Von Economo neurons in the cerebral cortex of cetaceans." *J Comp Neurol* **515**(2): 243-259.
- Cairns, N. J., Bigio, E. H., et al. (2007). "Neuropathologic diagnostic and nosologic criteria for frontotemporal lobar degeneration: consensus of the Consortium for Frontotemporal Lobar Degeneration." *Acta Neuropathol* **114**(1): 5-22.
- Catani, M. and Thiebaut de Schotten, M. (2012). *Atlas of Human Brain Connections*. New York, Oxford University Press.
- Chiong, W., Wilson, S. M., et al. (2013). "The salience network causally influences default mode network activity during moral reasoning." *Brain* **136**(Pt 6): 1929-1941.
- Chiu, W. Z., Papma, J. M., et al. (2012). "Midcingulate involvement in progressive supranuclear palsy and tau positive frontotemporal dementia." *J Neurol Neurosurg Psychiatry* **83**(9): 910-915.
- Cobos, I. and Seeley, W. W. (2013). "Human von Economo Neurons Express Transcription Factors Associated with Layer V Subcortical Projection Neurons." *Cereb Cortex*.
- Craig, A. D. (2009). "How do you feel--now? The anterior insula and human awareness." *Nat Rev Neurosci* **10**(1): 59-70.
- Cummings, J. L., Mega, M., et al. (1994). "The Neuropsychiatric Inventory: comprehensive assessment of psychopathology in dementia." *Neurology* **44**(12): 2308-2314.
- De Reuck, J., Deramecourt, V., et al. (2012). "Detection of microbleeds in post-mortem brains of patients with frontotemporal lobar degeneration: a 7.0-Tesla magnetic resonance imaging study with neuropathological correlates." *Eur J Neurol* **19**(10): 1355-1360.
- De Reuck, J. L., Deramecourt, V., et al. (2012). "Cerebrovascular lesions in patients with frontotemporal lobar degeneration: a neuropathological study." *Neurodegener Dis* **9**(4): 170-175.
- Dopper, E. G., Rombouts, S. A., et al. (2013). "Structural and functional brain connectivity in presymptomatic familial frontotemporal dementia." *Neurology* **80**(9): 814-823.
- Economo, C. V. (1926). "Eine neue Art Spezialzellen des Lobus cinguli und Lobus insulae." *Zeitschrift des Neurologie und Psychiatrie* **100**: 706-712.
- Englund, E. and Brun, A. (1987). "Frontal lobe degeneration of non-Alzheimer type. IV. White matter changes." *Arch Gerontol Geriatr* **6**(3): 235-243.
- Evrard, H. C., Forro, T., et al. (2012). "Von Economo neurons in the anterior insula of the macaque monkey." *Neuron* **74**(3): 482-489.
- Fajardo, C., Escobar, M. I., et al. (2008). "Von Economo neurons are present in the dorsolateral (dysgranular) prefrontal cortex of humans." *Neurosci Lett* **435**(3): 215-218.
- Fazekas, F., Chawluk, J. B., et al. (1987). "MR signal abnormalities at 1.5 T in Alzheimer's dementia and normal aging." *AJR Am J Roentgenol* **149**(2): 351-356.
- Ferrer, I., Tunon, T., et al. (1993). "Calbindin D-28k and parvalbumin immunoreactivity in the frontal cortex in patients with frontal lobe dementia of non-Alzheimer type associated with amyotrophic lateral sclerosis." *J Neurol Neurosurg Psychiatry* **56**(3): 257-261.
- Forkel, S. J., Thiebaut de Schotten, M., et al. (2012). "The anatomy of fronto-occipital connections from early blunt dissections to contemporary tractography." *Cortex*.

- Forman, M. S., Zhukareva, V., et al. (2002). "Signature tau neuropathology in gray and white matter of corticobasal degeneration." *Am J Pathol* **160**(6): 2045-2053.
- Fox, M. D., Snyder, A. Z., et al. (2005). "The human brain is intrinsically organized into dynamic, anticorrelated functional networks." *Proc Natl Acad Sci U S A* **102**(27): 9673-9678.
- Franceschi, M., Anchisi, D., et al. (2005). "Glucose metabolism and serotonin receptors in the frontotemporal lobe degeneration." *Ann Neurol* **57**(2): 216-225.
- Fuster, J. (2009). *The Prefrontal Cortex*. London, Academic Press.
- Garre-Olmo, J., Genis Batlle, D., et al. (2010). "Incidence and subtypes of early-onset dementia in a geographically defined general population." *Neurology* **75**(14): 1249-1255.
- Gasquoin, P. G. (2013). "Localization of function in anterior cingulate cortex: from psychosurgery to functional neuroimaging." *Neurosci Biobehav Rev* **37**(3): 340-348.
- Grasbeck, A., Englund, E., et al. (2003). "Predictors of mortality in frontotemporal dementia: a retrospective study of the prognostic influence of pre-diagnostic features." *Int J Geriatr Psychiatry* **18**(7): 594-601.
- Gustafson, L., Englund, E., et al. (2010). "The accuracy of short clinical rating scales in neuropathologically diagnosed dementia." *Am J Geriatr Psychiatry* **18**(9): 810-820.
- Hakeem, A. Y., Sherwood, C. C., et al. (2009). "Von Economo neurons in the elephant brain." *Anat Rec (Hoboken)* **292**(2): 242-248.
- Hardy, J. and Revesz, T. (2012). "The spread of neurodegenerative disease." *N Engl J Med* **366**(22): 2126-2128.
- Hodges, J. (2010). *Frontotemporal Dementia Syndromes*. Cambridge, Cambridge University Press.
- Hof, P. R. and Van der Gucht, E. (2007). "Structure of the cerebral cortex of the humpback whale, *Megaptera novaeangliae* (Cetacea, Mysticeti, Balaenopteridae)." *Anat Rec (Hoboken)* **290**(1): 1-31.
- Hornberger, M., Geng, J., et al. (2011). "Convergent grey and white matter evidence of orbitofrontal cortex changes related to disinhibition in behavioural variant frontotemporal dementia." *Brain* **134**(Pt 9): 2502-2512.
- Hornberger, M. and Piguet, O. (2012). "Episodic memory in frontotemporal dementia: a critical review." *Brain* **135**(Pt 3): 678-692.
- Huey, E. D., Zahn, R., et al. (2007). "[H]E is no more a person now but a whole climate of opinion" (Auden, 1940)." *Cortex* **43**(8): 1097-1098; discussion 1116-1021.
- Johansen-Berg, H. and Behrens, T. E. J. (2009). *Diffusion MRI : from quantitative measurement to in-vivo neuroanatomy*. London, Academic.
- Jones, D. K. (2008). "Studying connections in the living human brain with diffusion MRI." *Cortex* **44**(8): 936-952.
- Jones, D. K., Knosche, T. R., et al. (2013). "White matter integrity, fiber count, and other fallacies: the do's and don'ts of diffusion MRI." *Neuroimage* **73**: 239-254.
- Josephs, K. A., Hodges, J. R., et al. (2011). "Neuropathological background of phenotypical variability in frontotemporal dementia." *Acta Neuropathol* **122**(2): 137-153.
- Kaufman, J. A., Paul, L. K., et al. (2008). "Selective reduction of Von Economo neuron number in agenesis of the corpus callosum." *Acta Neuropathol* **116**(5): 479-489.
- Kennedy, D. P., Semendeferi, K., et al. (2007). "No reduction of spindle neuron number in frontoinsular cortex in autism." *Brain Cogn* **64**(2): 124-129.
- Kersaitis, C., Halliday, G. M., et al. (2004). "Regional and cellular pathology in frontotemporal dementia: relationship to stage of disease in cases with and without Pick bodies." *Acta Neuropathol* **108**(6): 515-523.
- Kertesz, A., Davidson, W., et al. (1997). "Frontal behavioral inventory: diagnostic criteria for frontal lobe dementia." *Can J Neurol Sci* **24**(1): 29-36.
- Kim, E. J., Sidhu, M., et al. (2012). "Selective frontoinsular von Economo neuron and fork cell loss in early behavioral variant frontotemporal dementia." *Cereb Cortex* **22**(2): 251-259.

- Knopman, D. S., Boeve, B. F., et al. (2005). "Antemortem diagnosis of frontotemporal lobar degeneration." *Ann Neurol* **57**(4): 480-488.
- Kringelbach, M. L. (2005). "The human orbitofrontal cortex: linking reward to hedonic experience." *Nat Rev Neurosci* **6**(9): 691-702.
- Lam, B. Y., Halliday, G. M., et al. (2014). "Longitudinal white matter changes in frontotemporal dementia subtypes." *Hum Brain Mapp* **35**(7): 3547-3557.
- Larsson, E., Passant, U., et al. (2000). "Magnetic resonance imaging and histopathology in dementia, clinically of frontotemporal type." *Dement Geriatr Cogn Disord* **11**(3): 123-134.
- Li, J. Y., Englund, E., et al. (2008). "Lewy bodies in grafted neurons in subjects with Parkinson's disease suggest host-to-graft disease propagation." *Nat Med* **14**(5): 501-503.
- Lillo, P., Mioshi, E., et al. (2012). "Grey and white matter changes across the amyotrophic lateral sclerosis-frontotemporal dementia continuum." *PLoS One* **7**(8): e43993.
- Liu, X., Erikson, C., et al. (1996). "Cortical synaptic changes and gliosis in normal aging, Alzheimer's disease and frontal lobe degeneration." *Dementia* **7**(3): 128-134.
- Mackenzie, I. R., Neumann, M., et al. (2011). "A harmonized classification system for FTLTD-TDP pathology." *Acta Neuropathol* **122**(1): 111-113.
- Mackenzie, I. R., Neumann, M., et al. (2010). "Nomenclature and nosology for neuropathologic subtypes of frontotemporal lobar degeneration: an update." *Acta Neuropathol* **119**(1): 1-4.
- Mahoney, C. J., Ridgway, G. R., et al. (2014). "Profiles of white matter tract pathology in frontotemporal dementia." *Hum Brain Mapp*.
- Mann, D. M., South, P. W., et al. (1993). "Dementia of frontal lobe type: neuropathology and immunohistochemistry." *J Neurol Neurosurg Psychiatry* **56**(6): 605-614.
- Massimo, L., Powers, C., et al. (2009). "Neuroanatomy of apathy and disinhibition in frontotemporal lobar degeneration." *Dement Geriatr Cogn Disord* **27**(1): 96-104.
- Matsuo, K., Mizuno, T., et al. (2008). "Cerebral white matter damage in frontotemporal dementia assessed by diffusion tensor tractography." *Neuroradiology* **50**(7): 605-611.
- McMillan, C. T., Brun, C., et al. (2012). "White matter imaging contributes to the multimodal diagnosis of frontotemporal lobar degeneration." *Neurology* **78**(22): 1761-1768.
- McMillan, C. T., Irwin, D. J., et al. (2013). "White matter imaging helps dissociate tau from TDP-43 in frontotemporal lobar degeneration." *J Neurol Neurosurg Psychiatry* **84**(9): 949-955.
- McNeill, R., Sare, G. M., et al. (2007). "Accuracy of single-photon emission computed tomography in differentiating frontotemporal dementia from Alzheimer's disease." *J Neurol Neurosurg Psychiatry* **78**(4): 350-355.
- Mendez, M. F., Shapira, J. S., et al. (2007). "Accuracy of the clinical evaluation for frontotemporal dementia." *Arch Neurol* **64**(6): 830-835.
- Mesulam, M. (2000). Behavioral Neuroanatomy: Large-Scale Networks, Association Cortex, Frontal Syndromes, the Limbic System, and Hemispheric specializations. *Principle of Behavioural and Cognitive Neurology*. M. Mesulam. New York, Oxford University Press: 1-91.
- Neary, D., Snowden, J. S., et al. (1998). "Frontotemporal lobar degeneration: a consensus on clinical diagnostic criteria." *Neurology* **51**(6): 1546-1554.
- Neumann, M., Kwong, L. K., et al. (2007). "TDP-43-positive white matter pathology in frontotemporal lobar degeneration with ubiquitin-positive inclusions." *J Neuropathol Exp Neurol* **66**(3): 177-183.
- Nieuwenhuys, R., Voogd J., van Huijzen C. (2007). *The Human Central Nervous System*. Berlin, Springer Verlag.
- Nilsson, C., Landqvist Waldo, M., et al. (2014). "Age-related incidence and family history in frontotemporal dementia: data from the Swedish dementia registry." *PLoS One* **9**(4): e94901.
- Nimchinsky, E. A., Gilissen, E., et al. (1999). "A neuronal morphologic type unique to humans and great apes." *Proc Natl Acad Sci U S A* **96**(9): 5268-5273.

- Nimchinsky, E. A., Vogt, B. A., et al. (1995). "Spindle neurons of the human anterior cingulate cortex." J Comp Neurol **355**(1): 27-37.
- O'Callaghan, C., Hodges, J. R., et al. (2013). "Inhibitory dysfunction in frontotemporal dementia: a review." Alzheimer Dis Assoc Disord **27**(2): 102-108.
- Olson, I. R., McCoy, D., et al. (2013). "Social cognition and the anterior temporal lobes: a review and theoretical framework." Soc Cogn Affect Neurosci **8**(2): 123-133.
- Palomero-Gallagher, N., Vogt, B. A., et al. (2009). "Receptor architecture of human cingulate cortex: evaluation of the four-region neurobiological model." Hum Brain Mapp **30**(8): 2336-2355.
- Papma, J. M., de Groot, M., et al. (2014). "Cerebral small vessel disease affects white matter microstructure in mild cognitive impairment." Hum Brain Mapp **35**(6): 2836-2851.
- Passant, U., Ostojic, J., et al. (2004). "Familial presenile dementia with bitemporal atrophy." Dement Geriatr Cogn Disord **17**(4): 287-292.
- Peters, F., Perani, D., et al. (2006). "Orbitofrontal dysfunction related to both apathy and disinhibition in frontotemporal dementia." Dement Geriatr Cogn Disord **21**(5-6): 373-379.
- Piguet, O., Hornberger, M., et al. (2011). "Behavioural-variant frontotemporal dementia: diagnosis, clinical staging, and management." Lancet Neurol **10**(2): 162-172.
- Pijnenburg, Y. A., Mulder, J. L., et al. (2008). "Diagnostic accuracy of consensus diagnostic criteria for frontotemporal dementia in a memory clinic population." Dement Geriatr Cogn Disord **25**(2): 157-164.
- Rabinovici, G. D., Seeley, W. W., et al. (2007). "Distinct MRI atrophy patterns in autopsy-proven Alzheimer's disease and frontotemporal lobar degeneration." Am J Alzheimers Dis Other Dement **22**(6): 474-488.
- Rademakers, R., Neumann, M., et al. (2012). "Advances in understanding the molecular basis of frontotemporal dementia." Nat Rev Neurol.
- Raichle, M. E., MacLeod, A. M., et al. (2001). "A default mode of brain function." Proc Natl Acad Sci U S A **98**(2): 676-682.
- Raj, A., Kuceyeski, A., et al. (2012). "A network diffusion model of disease progression in dementia." Neuron **73**(6): 1204-1215.
- Rascovsky, K., Hodges, J. R., et al. (2011). "Sensitivity of revised diagnostic criteria for the behavioural variant of frontotemporal dementia." Brain **134**(Pt 9): 2456-2477.
- Rohrer, J. D., Ridgway, G. R., et al. (2010). "Distinct profiles of brain atrophy in frontotemporal lobar degeneration caused by progranulin and tau mutations." Neuroimage **53**(3): 1070-1076.
- Rosen, H. J., Allison, S. C., et al. (2005). "Neuroanatomical correlates of behavioural disorders in dementia." Brain **128**(Pt 11): 2612-2625.
- Santos, M., Uppal, N., et al. (2011). "Von Economo neurons in autism: a stereologic study of the frontoinsula cortex in children." Brain Res **1380**: 206-217.
- Sarubbo, S., De Benedictis, A., et al. (2013). "Frontal terminations for the inferior fronto-occipital fascicle: anatomical dissection, DTI study and functional considerations on a multi-component bundle." Brain Struct Funct **218**(1): 21-37.
- Schmahmann, J. D. and Pandya, D. N. (2006). Fiber pathways of the brain. New York ; Oxford, Oxford University Press.
- Schofield, E., Kersaitis, C., et al. (2003). "Severity of gliosis in Pick's disease and frontotemporal lobar degeneration: tau-positive glia differentiate these disorders." Brain **126**(Pt 4): 827-840.
- Schroeter, M. L., Laird, A. R., et al. (2014). "Conceptualizing neuropsychiatric diseases with multimodal data-driven meta-analyses - The case of behavioral variant frontotemporal dementia." Cortex **57C**: 22-37.
- Schroeter, M. L., Raczka, K., et al. (2008). "Neural networks in frontotemporal dementia--a meta-analysis." Neurobiol Aging **29**(3): 418-426.
- Seeley, W. W. (2008). "Selective functional, regional, and neuronal vulnerability in frontotemporal dementia." Curr Opin Neurol **21**(6): 701-707.

- Seeley, W. W., Bauer, A. M., et al. (2005). "The natural history of temporal variant frontotemporal dementia." *Neurology* **64**(8): 1384-1390.
- Seeley, W. W., Carlin, D. A., et al. (2006). "Early frontotemporal dementia targets neurons unique to apes and humans." *Ann Neurol* **60**(6): 660-667.
- Seeley, W. W., Crawford, R., et al. (2008). "Frontal paralimbic network atrophy in very mild behavioral variant frontotemporal dementia." *Arch Neurol* **65**(2): 249-255.
- Seeley, W. W., Crawford, R. K., et al. (2009). "Neurodegenerative diseases target large-scale human brain networks." *Neuron* **62**(1): 42-52.
- Seeley, W. W., Menon, V., et al. (2007). "Dissociable intrinsic connectivity networks for salience processing and executive control." *J Neurosci* **27**(9): 2349-2356.
- Seeley, W. W., Merkle, F. T., et al. (2012). "Distinctive neurons of the anterior cingulate and frontoinsula cortex: a historical perspective." *Cereb Cortex* **22**(2): 245-250.
- Sieben, A., Van Langenhove, T., et al. (2012). "The genetics and neuropathology of frontotemporal lobar degeneration." *Acta Neuropathol* **124**(3): 353-372.
- Simms, M. L., Kemper, T. L., et al. (2009). "The anterior cingulate cortex in autism: heterogeneity of qualitative and quantitative cytoarchitectonic features suggests possible subgroups." *Acta Neuropathol* **118**(5): 673-684.
- Simon-Sanchez, J., Dopfer, E. G., et al. (2012). "The clinical and pathological phenotype of C9ORF72 hexanucleotide repeat expansions." *Brain* **135**(Pt 3): 723-735.
- Snowden, J. S., Bathgate, D., et al. (2001). "Distinct behavioural profiles in frontotemporal dementia and semantic dementia." *J Neurol Neurosurg Psychiatry* **70**(3): 323-332.
- Song, S. K., Sun, S. W., et al. (2002). "Dysmyelination revealed through MRI as increased radial (but unchanged axial) diffusion of water." *Neuroimage* **17**(3): 1429-1436.
- Tan, R. H., Wong, S., et al. (2014). "Beyond the temporal pole: limbic memory circuit in the semantic variant of primary progressive aphasia." *Brain* **137**(Pt 7): 2065-2076.
- Tartaglia, M. C., Luk M., Miller B., MacKenzie I. (2010). "White Matter Pathology in FTLTD-TDP." *Dement Geriatr Cogn Disord*.
- Taylor, K. S., Seminowicz, D. A., et al. (2009). "Two systems of resting state connectivity between the insula and cingulate cortex." *Hum Brain Mapp* **30**(9): 2731-2745.
- Thiebaut de Schotten, M., Dell'Acqua, F., et al. (2012). "Monkey to human comparative anatomy of the frontal lobe association tracts." *Cortex* **48**(1): 82-96.
- Thompson, S. A., Patterson, K., et al. (2003). "Left/right asymmetry of atrophy in semantic dementia: behavioral-cognitive implications." *Neurology* **61**(9): 1196-1203.
- Tournier, J. D., Mori, S., et al. (2011). "Diffusion tensor imaging and beyond." *Magn Reson Med* **65**(6): 1532-1556.
- Viskontas, I. V., Possin, K. L., et al. (2007). "Symptoms of frontotemporal dementia provide insights into orbitofrontal cortex function and social behavior." *Ann N Y Acad Sci* **1121**: 528-545.
- Vogt, B. A., Berger, G. R., et al. (2003). "Structural and functional dichotomy of human midcingulate cortex." *Eur J Neurosci* **18**(11): 3134-3144.
- Vogt, B. A., Nimchinsky, E. A., et al. (1995). "Human cingulate cortex: surface features, flat maps, and cytoarchitecture." *J Comp Neurol* **359**(3): 490-506.
- Von Der Heide, R. J., Skipper, L. M., et al. (2013). "Dissecting the uncinate fasciculus: disorders, controversies and a hypothesis." *Brain* **136**(Pt 6): 1692-1707.
- von Economo, K. (1925). *Die Cytoarchitektonik der Hirnrinde des Erwachsenen Menschen*. Berlin, Springer.
- Wahlund, L. O., Barkhof, F., et al. (2001). "A new rating scale for age-related white matter changes applicable to MRI and CT." *Stroke* **32**(6): 1318-1322.
- Warren, J. D., Rohrer, J. D., et al. (2012). "Disintegrating brain networks: from syndromes to molecular nexopathies." *Neuron* **73**(6): 1060-1062.

- Watson, K. K., Jones, T. K., et al. (2006). "Dendritic architecture of the von Economo neurons." Neuroscience **141**(3): 1107-1112.
- Wheeler-Kingshott, C. A. and Cercignani, M. (2009). "About "axial" and "radial" diffusivities." Magn Reson Med **61**(5): 1255-1260.
- Whitwell, J. L., Avula, R., et al. (2010). "Gray and white matter water diffusion in the syndromic variants of frontotemporal dementia." Neurology **74**(16): 1279-1287.
- Whitwell, J. L., Przybelski, S. A., et al. (2009). "Distinct anatomical subtypes of the behavioural variant of frontotemporal dementia: a cluster analysis study." Brain **132**(Pt 11): 2932-2946.
- Whitwell, J. L., Weigand, S. D., et al. (2012). "Neuroimaging signatures of frontotemporal dementia genetics: C9ORF72, tau, progranulin and sporadics." Brain **135**(Pt 3): 794-806.
- Zamboni, G., Huey, E. D., et al. (2008). "Apathy and disinhibition in frontotemporal dementia: Insights into their neural correlates." Neurology **71**(10): 736-742.
- Zhang, Y., Schuff, N., et al. (2011). "Joint assessment of structural, perfusion, and diffusion MRI in Alzheimer's disease and frontotemporal dementia." Int J Alzheimers Dis **2011**: 546871.
- Zhang, Y., Schuff, N., et al. (2009). "White matter damage in frontotemporal dementia and Alzheimer's disease measured by diffusion MRI." Brain **132**(Pt 9): 2579-2592.
- Zhang, Y., Tartaglia, M. C., et al. (2013). "MRI signatures of brain macrostructural atrophy and microstructural degradation in frontotemporal lobar degeneration subtypes." J Alzheimers Dis **33**(2): 431-444.
- Zhou, J., Greicius, M. D., et al. (2010). "Divergent network connectivity changes in behavioural variant frontotemporal dementia and Alzheimer's disease." Brain **133**(Pt 5): 1352-1367.
- Zhukareva, V., Mann, D., et al. (2002). "Sporadic Pick's disease: a tauopathy characterized by a spectrum of pathological tau isoforms in gray and white matter." Ann Neurol **51**(6): 730-739.