



LUND UNIVERSITY

Normal cervical changes in parous women during the second half of pregnancy--a prospective, longitudinal ultrasound study.

Bergelin, Ingrid; Valentin, Lil

Published in:
Acta Obstetricia et Gynecologica Scandinavica

DOI:
[10.1046/j.0001-6349.2001.00311.x](https://doi.org/10.1046/j.0001-6349.2001.00311.x)

2002

[Link to publication](#)

Citation for published version (APA):
Bergelin, I., & Valentin, L. (2002). Normal cervical changes in parous women during the second half of pregnancy--a prospective, longitudinal ultrasound study. *Acta Obstetricia et Gynecologica Scandinavica*, 81(1), 31-38. <https://doi.org/10.1046/j.0001-6349.2001.00311.x>

Total number of authors:
2

General rights

Unless other specific re-use rights are stated the following general rights apply:
Copyright and moral rights for the publications made accessible in the public portal are retained by the authors and/or other copyright owners and it is a condition of accessing publications that users recognise and abide by the legal requirements associated with these rights.

- Users may download and print one copy of any publication from the public portal for the purpose of private study or research.
- You may not further distribute the material or use it for any profit-making activity or commercial gain
- You may freely distribute the URL identifying the publication in the public portal

Read more about Creative commons licenses: <https://creativecommons.org/licenses/>

Take down policy

If you believe that this document breaches copyright please contact us providing details, and we will remove access to the work immediately and investigate your claim.

LUND UNIVERSITY

PO Box 117
221 00 Lund
+46 46-222 00 00

Normal cervical changes in parous women during the second half of pregnancy – a prospective, longitudinal ultrasound study

INGRID BERGELIN and LIL VALENTIN

From the Department of Obstetrics and Gynecology, University Hospital MAS, Lund University, Malmö, Sweden

Acta Obstet Gynecol Scand 2002; 81: 31–38. © Acta Obstet Gynecol Scand 2002

Objective. To determine what constitutes normal cervical changes during the second half of pregnancy in parous women delivering at term.

Design. The study comprises 21 healthy, pregnant parous women who all gave birth at term. They were examined with transvaginal ultrasound every two weeks from 24 gestational weeks until delivery. Cervical length and width were measured. The inner cervical os was assessed as being closed or open, the length and width of any opening were measured, and dynamic cervical changes (i.e. opening and closing of the inner cervical os during examination) were noted.

Results. Median cervical length was 41 mm (range 26–55) at the first examination and 29 mm (range 8–56) at the last examination. The corresponding figures for cervical width were 38 mm (range 29–47) and 46 mm (range 38–64). Cervical length decreased in 18 women but remained unchanged in three. Three patterns of change in cervical length were observed: in 12 women there was a steady, continuous decrease in cervical length (median decrease rate 1.1 mm/week, range 0.6–2.4); in four women the decrease rate accelerated towards the end of pregnancy, the median decrease rate after the change being 3.0 mm/week (range 1.5–4.8); and in two women there was a sudden drop in cervical length at term. Cervical width increased in 16 women but remained unchanged in five. Two patterns of change in cervical width were seen: 14 women manifested a steady continuous increase in cervical width (median 0.8 mm/week, range 0.4–1.8); in two women the increase rate accelerated from around 34 gestational weeks, the increase rate after the change being 4.1 and 5.9 mm/week, respectively. Opening of the internal cervical os was observed at least once in 11 (52%) women and was seen as early as at 24 and 25 gestational weeks in two women. The opening was always V-shaped (median length 6 mm, range 4–17; median width 7 mm, range 3–20). Dynamic changes of the internal cervical os were seen in three women (14%) at 25, 30 and 41 gestational weeks, respectively.

Conclusion. The cervix of parous women decreases in length and increases in width from midpregnancy to term, but the pattern of change varies between individuals. Knowledge of the different patterns of normal change forms the basis of transvaginal ultrasound studies of pathological cervical changes during pregnancy.

Keywords: cervix uteri; pregnancy; ultrasonography

Submitted 23 July, 2001

Accepted 5 September, 2001

The use of transvaginal ultrasound examination of the cervix is nowadays widely recommended as a part of the surveillance of women at high risk of pre-term delivery (1–4). Its use as a screening tool in a low risk population is more debatable (5, 6). Normograms for cervical length and width during pregnancy as measured by ultrasound have been

been published (7–10), but there are few ultrasound studies describing normal individual changes in the cervix during pregnancy (11). Knowledge of what constitutes normal cervical changes throughout pregnancy forms the basis of longitudinal studies of the cervix in high risk pregnancies.

The aim of this study was to determine what constitutes normal changes in the cervix observable at transvaginal ultrasound examination from 24 gestational weeks until delivery in parous women.

Subjects and methods

The study was approved by the Ethics Committee of the Medical Faculty, Lund University (Malmö, Sweden) and all participants consented to take part in the study, after the nature of the procedures had been fully explained. The women were recruited in the first half of pregnancy by midwives at the antenatal care units or at the ultrasound department of the Department of Obstetrics and Gynecology, University Hospital (Malmö, Sweden). Healthy, Swedish speaking parous women ≥ 18 -year-old, and with no pregnancy complications at the time of recruitment were eligible. In all pregnancies gestational age was determined on the basis of ultrasound measurement of the fetal biparietal diameter and femur length at around 18 gestational weeks (12). Gestational age is given in completed gestational weeks.

Twenty-two women agreed to participate and completed the study. One woman was excluded because of premature delivery at 32 gestational weeks. Thus, our study comprises 21 women, all Caucasian, who delivered at term at a mean gestational age of 40 weeks ± 1.4 (SD; range 37–42). Sixteen women were uniparous, and five women had undergone two or more deliveries. One woman who had previously been delivered by Caesarean section because of cephalic pelvic disproportion underwent elective Caesarean section at 38 gestational weeks because of inadequate pelvis. The remaining 20 women, who had all delivered vaginally before, went into labor spontaneously and delivered vaginally. The mean maternal age at delivery was 32 years ± 5.1 (range 22–43). Twelve women had undergone at least one early termination of pregnancy. None had been operated with conization of the cervix.

Ultrasound examination of the cervix was carried out every two weeks starting at 24 gestational weeks. All the examinations were performed by the first author (IB). The examinations were carried out with the woman in the lithotomy position with an empty bladder. A standardized measurement technique was used, the length and width of the cervix being measured as described in Fig. 1 and 2. All measurements were taken three times, the mean of the measurements being used for analysis. The internal os was described as being closed or open, any opening being classified as V-shaped or U-shaped. The length and width of the opening were measured as shown in Fig. 1 and 2. Dynamic

changes, i.e. opening or closing of the inner cervical os observed during the examination were noted. We defined 'opening and closing of the inner cervical os' as changes seen to engage the endocervical mucosa. The duration of the examinations was 5–10 min.

The ultrasound examinations were carried out using an Acuson 128XP ultrasound system equipped with a 7-MHz transvaginal transducer (Acuson Inc., Mountain View, CA, USA), an Aloka SSD 620 ultrasound system with a 5-MHz transvaginal transducer, or an Aloka SSD 500 with a 5-MHz transvaginal transducer (Aloka Co. Ltd, Mitaka-shi, Tokyo, Japan).

For each woman cervical length and width were plotted against gestational age. The graphs were visually assessed. At visual inspection all plots manifested linear changes and were characterized by a linear regression coefficient, this coefficient being equal to the weekly change in mm in cervical length or width. The statistical significance of differences in continuous data was determined using the Mann–Whitney test. Two-tailed *P*-values were used with 5% as the level of significance. Statistical analyzes were carried out with a Macintosh computer using the STATVIEW 4.5 statistical program (Abacus Concepts Inc., Berkeley, CA, USA, 1992–95).

Results

Sixteen women underwent their first examination at 23 or 24 gestational weeks, three women at 25 or 26 gestational weeks, one woman at 28 gestational weeks, and one woman at 31 gestational weeks. The median number of examinations per woman was 7 (range 4–10), and the median examination period was 14 weeks (range 8–18). The last examination was carried out at 34–41 gestational weeks (median 38) corresponding to 0–35 days (median 8) before delivery.

In three women cervical length remained unchanged (39, 41, and 55 mm at the first examination and 37, 39, and 56 mm at the last examination), their last examination being performed 1, 7 and 13 days before delivery. In the remaining 18 women cervical length decreased from mean 41 mm ± 8.1 (SD) (median 42, range 26–54) at the first examination to mean 25 mm ± 9.2 (median 28, range 8–44) at the last examination. Median cervical length 0–6 days before spontaneous start of labor was 17 mm (range 8–30; *n* = 7). Individual changes in cervical length are shown in Fig. 3. Twelve of the 18 women manifested a steady, continuous shortening of the cervix with a median shortening rate of 1.1 mm/week (range 0.6–2.4). In four women the shortening rate accelerated to-

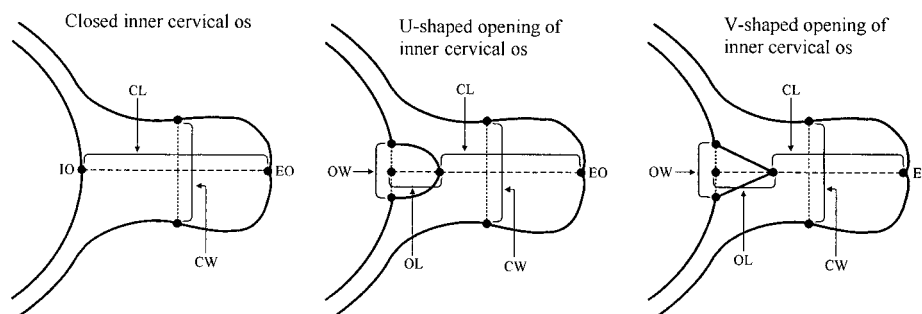


Fig. 1. Schematic drawing illustrating the technique of measuring cervical length, width, and opening of the inner cervical os. Cervical length was measured on a true longitudinal view of the cervix, care being taken to include only that segment of the cervical canal that was bordered by the endocervical mucosa (4). Cervical width was measured in the same plane as cervical length at the midpoint between the inner and outer cervical os and perpendicular to the longitudinal axis of the cervical canal as described by others (4, 10, 11, 13–15). IO, inner cervical os; EO, external cervical os; CL, cervical length; CW, cervical width; OL, length of opening of inner cervical os; OW, width of opening of inner cervical os.

wards the end of pregnancy, the accelerated shortening rate starting at 30–33 gestational weeks. The median shortening rate of these four women was 0.6 mm/week (range 0.3–1.2) before the change versus 3 mm/week (range 1.5–4.8) after the change in shortening rate. In the remaining two women a sudden drop in cervical length was seen between the last two examinations, i.e. a drop from 44 mm to 30 mm between 36 and 38 gestational weeks (one day before delivery), and from 35 mm to 20 mm between 36 and 39 gestational weeks (10 days before delivery). Women with different patterns of change in cervical length (i.e. steady shortening rate versus accelerated shortening rate versus unchanged cervical length) were similar to each other with regard to cervical length at the first and last examination (except the three women with unchanged cervical length, who had longer cervix at the last examination), gestational age at the first and last examination, gestational age at delivery, duration of the examination period, and the number of examinations.

In five women cervical width remained unchanged during the observation period, median cervical width at the first and last examination being 39 mm (range 32–47) and 39 mm (range 38–48). In the remaining 16 women cervical width increased, mean cervical width at the first and last examinations being $37 \text{ mm} \pm 5.3$ (median 37, range 29–46) and $51 \text{ mm} \pm 8.0$ (median 49, range 40–64). Individual changes in cervical width are shown in Fig. 4. A steady continuous increase in cervical width was seen in 14 women, the median broadening rate being 0.8 mm/week (range 0.4–1.8). In two women the broadening rate accelerated after 33 and 35 gestational weeks, respectively, the broadening rate before and after the change being 0.4 versus 4.1 mm/week in the first woman and 1.5 versus 5.9 mm/week in the second. There

were no obvious differences between women with unchanged cervical width and those with increasing cervical width with regard to gestational age at the first examination, duration of the examination period, or the number of examinations. However, women with unchanged cervical width tended to have a wider cervix at the first examination (median 39 mm versus 37; $P=0.41$), to have their last examination earlier (median 37 gestational weeks versus 39; $P=0.43$), and to give birth earlier (median 38 gestational weeks versus 40; $P=0.22$).

An open cervical os was observed at least once in 11 (52%) women. In six of these the os was open at the last examination. All openings were V-shaped, the median length of the opening being 6 mm (range 4–17) and the median width 7 mm (range 3–20). In two women the opening was seen as early as at gestational weeks 24 and 25, at a cervical length of 35 mm and 36 mm (the opening length and width being 5 mm and 9 mm in the first woman, and 4 mm and 8 mm in the second), whereafter the opening was observed only intermittently. In five women the opening was first seen between 30 and 34 gestational weeks (median opening length 6 mm, range 5–7; median opening width 9 mm, range 3–12; median cervical length when the opening was first observed 30 mm, range 20–43), and in three of them the os remained open until delivery at 38–41 gestational weeks. There was no tendency for the opening to become longer or wider as gestation progressed. In three women the cervical os was seen to be open only at the last examination at 38–41 gestational weeks, and in one woman an open os was observed only at 39 weeks but not at 41 weeks, one day before delivery.

Dynamic cervical changes were seen once in each of three women, at 25, 30 and 41 gestational weeks, when the cervical length was 36 mm, 26 mm and 17 mm. These women gave birth at 38, 42 and 42 weeks.

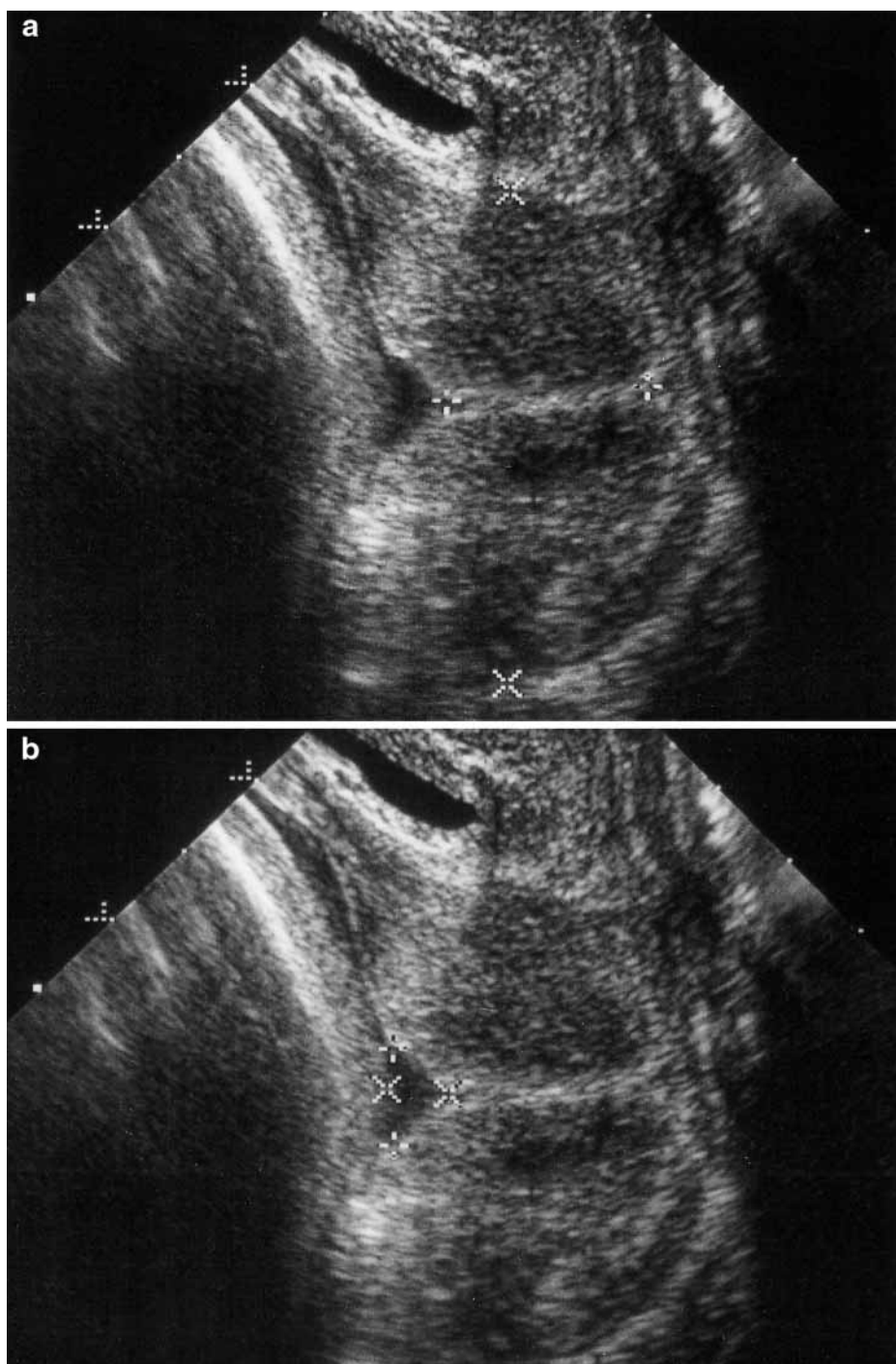


Fig. 2. (a) Ultrasound image showing measurement of cervical length and width. For measurement of cervical length, the calipers are placed at the inner and outer cervical os. The measurement includes only that part of the cervical canal that is bordered by endocervical mucosa (4). The measurement of cervical width is taken at the midpoint between the inner and outer cervical os and perpendicular to the longitudinal axis of the cervical canal (4, 10, 11, 13–15). (b) Ultrasound image showing a measurement of a V-shaped inner cervical os. The apex of the V borders the endocervical canal.

The woman not included because of preterm delivery at 32 gestational weeks was examined twice, i.e. at 25 and 28 weeks. She had previously undergone one termination of pregnancy in the first trimester and one normal pregnancy with vaginal de-

livery at term. The reason why she did not return for ultrasound examination of the cervix at 30 and 32 weeks is unclear. She was not hospitalized during the period between the last examination and delivery. Cervical length at her first and last exami-

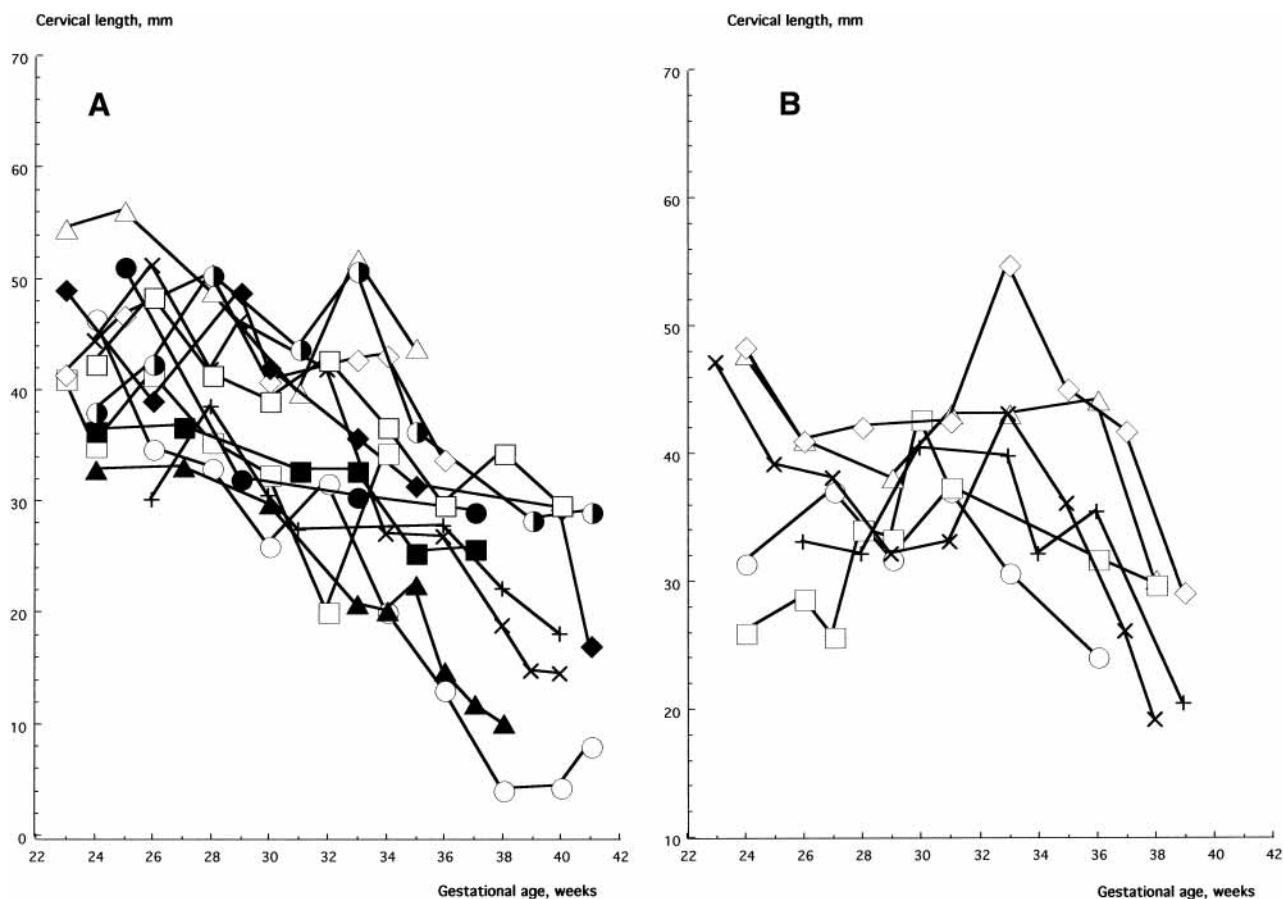


Fig. 3. Individual changes in cervical length with advancing gestation (a) in women with a steady, continuous decrease in cervical length (b) in women with accelerated cervical shortening rate towards the end of pregnancy. The different symbols represent different individuals.

nation was 39 mm and 32 mm, respectively, and cervical width 40 mm and 43 mm, respectively. The internal os was open at both examinations, and the opening was U-shaped. Its length measured 15 mm at the first examination and 37 mm at the last examination and its width 22 mm and 27 mm.

Discussion

The reported cervical length at different gestational ages vary in the literature. Only few studies include measurements of cervical length at the end of gestation (10). Our results are similar to those found in two other studies reporting results for parous women in the first part of the third trimester (13, 16). However, Iams and co-workers found the cervix of parous women to be shorter than we did at 24 and 28 gestational weeks (17).

We observed three patterns of change in cervical length: a steady, continuous shortening, an accelerated shortening rate starting at around 30 gestational weeks, and a sudden drop in cervical length shortly before delivery. Our results suggest

that a shortening rate of between 0.5 and 5 mm per week may be normal in parous women, the higher figure referring to women manifesting an increased shortening rate in the latter half of the third trimester. Moreover, a sudden drop in length of up to 15 mm shortly before delivery is to be expected in some women. To the best of our knowledge, no other research teams have studied individual changes in cervical length during pregnancy, possibly with one exception: Zorzoli and colleagues, who seem to have studied individual changes, found that cervical length did not change in multiparous women between 12 and 31 gestational weeks (11). Several research teams report the cervix to become shorter with advancing gestation in mixed groups of both nulliparae and multiparae (7, 9, 18, 19), and some describe accelerated shortening rate in the third trimester (7, 9), even though they did not study individual changes in cervical length and did not specify the decrease rate in mm/week. Others report of unchanged cervical length during pregnancy in both nulliparous and multiparous women, a finding which might be explained

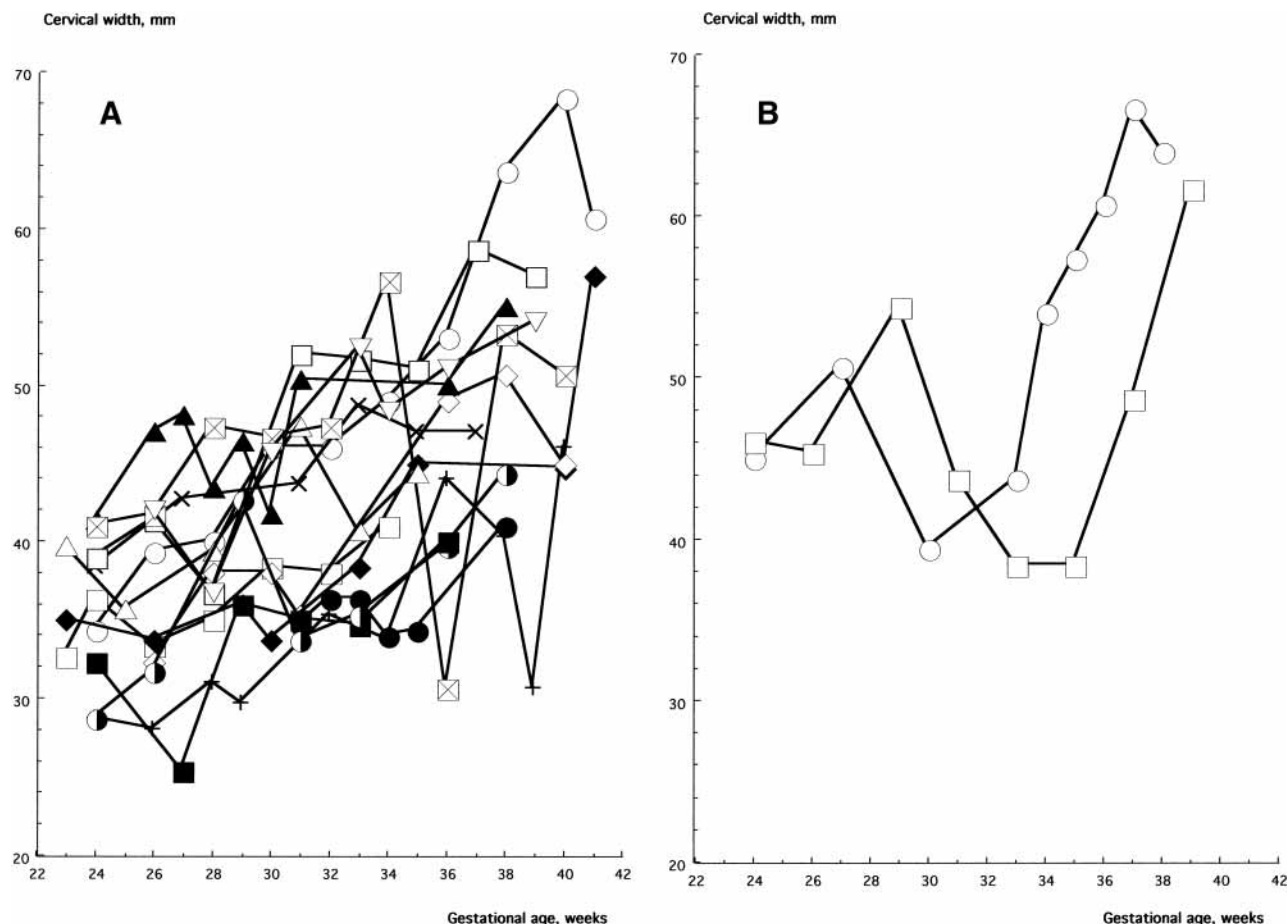


Fig. 4. Individual changes in cervical width with advancing gestation (a) in women with a steady increase in cervical width b/in women with accelerated cervical broadening rate towards the end of pregnancy. The different symbols represent different individuals.

by shorter and/or earlier examination periods in these studies (11, 13, 16).

We observed two patterns of change in cervical width: a steady broadening, and an accelerated broadening rate starting after 32 gestational weeks. Our results suggest that the cervix may increase in width by between 0.4 and 6 mm/week, the higher figure referring to women with an accelerated broadening rate in the latter part of the third trimester. No other research teams seem to have studied individual changes in cervical width during normal pregnancy with the exception of Zorzoli and co-workers (11). They found that the cervix changed from cylindrical to conic as gestation advanced (i.e. it became broader in its upper part), this change being more pronounced in nulliparae than in parous women (11). Very few studies report results of cervical width measurements for the latter half of pregnancy, but Brieger and co-workers observed a continuous increase in cervical width from 30 gestational weeks until delivery in a group of nulliparous women (10). Smith and co-workers, too, reported cervical width to increase with in-

creasing gestational age up to 37 gestational weeks in a group of women with unknown parity (14). On the other hand, Cook and co-workers and Epel and colleagues, who examined parous women from 18 to 30 gestational and from 16 to 34 gestational weeks, respectively, found cervical width to remain constant during the observation period (13, 16).

Funneling, i.e. protrusion of various dimensions of the amniotic membranes into the cervical canal, have been reported to be associated with preterm delivery (17, 20, 21). Berghella and co-workers defined funneling as any opening of the internal cervical os and found that a funnel length of ≥ 16 mm and a funnel width of ≥ 14 mm at a mean gestational age 21.4 weeks (range 16–28) were significantly associated with preterm delivery in a high risk population (22). A dilatation of the inner os of > 5 mm before 30 gestational weeks was associated with a 33% risk of preterm delivery in another study on high risk women (23), and a dilated internal os of ≥ 5 mm at 18–24 gestational weeks was associated with a 28-fold increase in the risk of

delivery before 35 gestational weeks in an unselected population of both nulliparous and multiparous women (6). Iams and co-workers, too, found funneling to be a significant predictor of premature delivery in high risk women but emphasized that the ability to identify the funnel was not consistent among different study centers (17). Some authors state that measurements of a "funnel" are difficult to standardize, and that the presence of a funnel may be disputed in certain circumstances, especially if the funnel is very short (<6 mm; 4). Our results suggest that a small V-shaped open internal cervical os may occur normally long before term in parous women. We observed an opening of the inner cervical os in 11 (52%) of the women, the first observation being made as early as at 24 gestational weeks. Other authors, too, have reported the inner cervical os to be open before term in pregnancies resulting in term delivery (8, 10). However, comparison between our results and those of others are difficult to make, because most studies contain insufficient information about how the measurements were taken, at what gestational age the opening was first observed, and in what proportion of women an open cervical os was seen.

The clinical significance of the different patterns of opening of the inner cervical os – i.e. V-shaped versus U-shaped – has been discussed (4, 24, 25). It seems plausible that the different shapes are different stages of one process – i.e. progressive cervical effacement, where the V-shape gradually turns into a U-shape – as described by Ziliani and co-workers in a study of the cervix at the beginning of labor (26). The U-shaped inner cervical os in the woman who delivered prematurely at 32 gestational weeks in our study, might have been the endstage of such a process.

We observed dynamic changes in the cervix in three women (14%), and in two of them the observation was made ≥ 30 gestational weeks. Okitsu and co-workers found dynamic changes in only 1.5% of women in a mixed pregnant population of nulliparae and multiparae delivering at term (23). This difference in results is possibly to be explained by different definitions of dynamic changes having been used in the two studies, alternatively the difference might be attributable to different durations of the ultrasound examinations. Hertzberg and co-workers, who examined a group of 27 women at high risk of preterm delivery, found that the average time needed to detect substantial dynamic cervical changes was around 12 min. They emphasized that it might not be sufficient to obtain a single 'snapshot' image of the cervix during obstetric sonography (27). Iams considered dynamic changes after 32 gestational weeks to be a normal finding and suggested that dynamic changes seen

together with funneling reflected effacement in progress (20).

The results we report here for multiparae with regard to cervical changes during pregnancy are similar to those of a study with identical design that we performed in nulliparous women (29) with two possible exceptions: a V-shaped open inner cervical os was seen more often before 36 weeks in multiparae than in nulliparae (7/21 versus 2/19, $P=0.13$; Fisher's exact test), a finding concordant with the observations made by Boozarjomehri and co-workers (28); moreover unchanged cervical width was more common in parous women (5/21 versus 1/19, $P=0.19$; Fisher's exact test). Cervical length and width were similar in our nulliparous and multiparous women. This is in agreement with observations made by others (7–9, 18).

To sum up, the results of this study show that the cervix of parous women usually decreases in length and increases in width from midpregnancy to term, but that the pattern of change varies between individuals. Knowledge of the different patterns of normal change forms the basis of studies of pathological cervical changes during pregnancy.

Acknowledgments

The study was supported by grants from funds administered by the Malmö Health Care Administration, a government grant for clinical research (ALF-medel and Landstingsfinansierad regional forskning) and the Swedish Medical Research Council (grants numbers B96–17X – 11605–01 A, K98–17X – 11605–03 A and K2001–72X – 11605–06 A).

References

1. Guzman ER, Mellon C, Vintzileos AM, Ananth CV, Walters C, Gipson K. Longitudinal assessment of endocervical canal length between 15 and 24 weeks' gestation in women at risk for pregnancy loss or preterm birth. *Obstet Gynecol* 1998; 92: 31–7.
2. Leitich H, Brunbauer M, Kaider A, Egarter C, Husslein P. Cervical length and dilatation of the internal cervical os detected by vaginal ultrasonography as markers for preterm delivery: a systematic review. *Am J Obstet Gynecol* 1999; 181: 1465–72.
3. Hagberg H, Wennerholm U – B. Spontaneous premature birth. physiopathology, predictors and management. The frequency is constant — early detection can improve therapeutic possibilities. *Läkartidningen* 2000; 97: 301–10.
4. Sonek J, Shellhaas C. Cervical sonography: a review. *Ultrasound Obstet Gynecol* 1998; 11: 71–8.
5. Heath VCF, Southall TR, Souka AP, Elisseou A, Nicolaides KH. Cervical length at 23 weeks of gestation: prediction of spontaneous preterm delivery. *Ultrasound Obstet Gynecol* 1998; 12: 312–7.
6. Taipale P, Hiilesmaa V. Sonographic measurement of uterine cervix at 18–22 weeks' gestation and the risk of preterm delivery. *Obstet Gynecol* 1998; 92: 902–7.
7. Kushnir O, Vigil DA, Izquierdo L, Schiff M, Curet LB. Vaginal ultrasonographic assessment of cervical length changes during normal pregnancy. *Am J Obstet Gynecol* 1990; 162: 991–3.

8. Hasegawa I, Tanaka K, Takahashi K, Tanaka T, Aoki K et al. Transvaginal ultrasonographic cervical assessment for the prediction of preterm delivery. *J Matern-Fetal Med* 1996; 5: 305–9.
9. Tongsong T, Kamprapanth J, Pitaksakorn J. Cervical length in normal pregnancy as measured by transvaginal sonography. *Int J Gynaecol Obstet* 1997; 58: 313–5.
10. Brieger GM, Xie Hong Ning, Dawkins R R, Kong Qui Ying, Cai Weng, Chang A M Z et al. Transvaginal sonographic assessment of cervical dynamics during the third trimester of normal pregnancy. *Acta Obstet Gynecol Scand* 1997; 76: 118–22.
11. Zorzoli A, Soliani A, Perra M, Caravelli E, Galimberti A, Nicolini U. Cervical changes throughout pregnancy as assessed by transvaginal sonography. *Obstet Gynecol* 1994; 84: 960–4.
12. Persson P-H, Weldner B-M. Reliability of ultrasound fetometry in estimating gestational age in the second trimester. *Acta Obstet Gynecol Scand* 1986; 65: 481–3.
13. Cook C-M, Ellwood DA. A longitudinal study of the cervix in pregnancy using transvaginal ultrasound. *Br J Obstet Gynaecol* 1996; 103: 16–8.
14. Smith CV, Anderson JC, Matamoros A, Rayburn WF. Transvaginal sonography of cervical width and length during pregnancy. *J Ultrasound Med* 1992; 11: 465–7.
15. Eppel W, Schurz B, Frigo P, Adler A, Asseryanis E, Kudielka I, Vavra N, Reinold E. Vaginosonography of the cervix in twin pregnancies. *Geburtshilfe Frauenheilkd* 1994; 54: 20–6.
16. Eppel W, Schurz B, Frigo P, Reinold E. Vaginosonographic observations of the cervix with particular reference to parity. *Geburtshilfe Frauenheilkd* 1992; 52: 148–51.
17. Iams JD, Goldenberg RL, Meis PJ, Mercer B, Moawad A, Das A, Thom E et al. the National Institute of Child Health and Human Development Maternal Fetal Medicine Unit Network. The length of cervix and the risk of spontaneous premature delivery. *N Engl J Med* 1996; 334: 567–72.
18. Murakawa H, Utumi T, Hasegawa I, Tanaka K, Fuzimori R. Evaluation of threatened preterm delivery by transvaginal ultrasonographic measurement of cervical length. *Obstet Gynecol* 1993; 82: 829–32.
19. Andersen HF. Transvaginal and transabdominal ultrasonography of the uterine cervix during pregnancy. *J Clin Ultrasound* 1991; 19: 77–83.
20. Iams JD, Opinion. Cervical sonography. *Ultrasound Obstet Gynecol* 1997; 10: 156–60.
21. Berghella V, Daly SF, Tolosa JE, DiVito MM, Chalmers R, Garg N, Bhullar A et al. Prediction of preterm delivery with transvaginal ultrasonography of the cervix with high-risk pregnancies: does cerclage prevent prematurity? *Am J Obstet Gynecol* 1999; 181: 809–15.
22. Berghella V, Kuhlman K, Weiner S, Texeira L, Wapner RJ. Cervical funneling. sonographic criteria predictive of preterm delivery. *Ultrasound Obstet Gynecol* 1997; 10: 161–6.
23. Okitsu O, Mimura T, Nakayama T, Aono T. Early prediction of preterm delivery by transvaginal ultrasonography. *Ultrasound Obstet Gynecol* 1992; 2: 402–9.
24. Gomez R, Galasso M, Romero R, Mazor M, Sorokin Y, Goncalves L et al. Ultrasonographic examination of the uterine cervix is better than cervical digital examination as a predictor of the likelihood of premature delivery in patients with preterm labor and intact membranes. *Am J Obstet Gynecol* 1994; 171: 956–64.
25. Andersen HF, Karimi A, Sakala EP, Kalugdan R. Prediction of cervical cerclage outcome by endovaginal ultrasonography. *Am J Obstet Gynecol* 1994; 171: 1102–6.
26. Ziliani M, Azuaga A, Calderon F, Pagés G, Mendoza G. Monitoring the effacement of the uterine cervix by transperineal sonography: a new perspective. *J Ultrasound Med* 1995; 14: 719–24.
27. Hertzberg BS, Kliewer MA, Farrell TA, DeLong DM. Spontaneously changing gravid cervix: clinical implications and prognostic features. *Radiology* 1995; 196: 721–4.
28. Boozarjomehri F, Timor-Tritsch I, Chao CR, Fox HE. Transvaginal ultrasonographic evaluation of the cervix before labor: Presence of cervical wedging is associated with shorter duration of induced labor. *Am J Obstet Gynecol* 1994; 171: 1081–7.
29. Bergelin I, Valentin L. Patterns of normal change in cervical length and width during pregnancy in nulliparous women – a prospective, longitudinal ultrasound study. *Ultrasound Obstet Gynecol* 2001; 18: 217–22.

Address for correspondence:

Dr Ingrid Bergelin
Department of Obstetrics and Gynecology
Mora Hospital
SE-792 85 Mora,
Sweden
e-mail: ingrid.bergelin@ltdalarna.se