



# LUND UNIVERSITY

## Strong lymphoid nuclear expression of SOX11 transcription factor defines lymphoblastic neoplasms, mantle cell lymphoma and Burkitt's lymphoma.

Dictor, Michael; Ek, Sara; Sundberg, Maria; Warenholt, Janina; György, Czabafy; Sernbo, Sandra; Gustavsson, Elin; Abu Al-Soud, Waleed; Wadström, Torkel; Borrebaeck, Carl

*Published in:*  
Haematologica

*DOI:*  
[10.3324/haematol.2009.008474](https://doi.org/10.3324/haematol.2009.008474)

2009

[Link to publication](#)

### *Citation for published version (APA):*

Dictor, M., Ek, S., Sundberg, M., Warenholt, J., György, C., Sernbo, S., Gustavsson, E., Abu Al-Soud, W., Wadström, T., & Borrebaeck, C. (2009). Strong lymphoid nuclear expression of SOX11 transcription factor defines lymphoblastic neoplasms, mantle cell lymphoma and Burkitt's lymphoma. *Haematologica*, 94(11), 1563-1568. <https://doi.org/10.3324/haematol.2009.008474>

*Total number of authors:*  
10

### **General rights**

Unless other specific re-use rights are stated the following general rights apply:  
Copyright and moral rights for the publications made accessible in the public portal are retained by the authors and/or other copyright owners and it is a condition of accessing publications that users recognise and abide by the legal requirements associated with these rights.

- Users may download and print one copy of any publication from the public portal for the purpose of private study or research.
- You may not further distribute the material or use it for any profit-making activity or commercial gain
- You may freely distribute the URL identifying the publication in the public portal

Read more about Creative commons licenses: <https://creativecommons.org/licenses/>

### **Take down policy**

If you believe that this document breaches copyright please contact us providing details, and we will remove access to the work immediately and investigate your claim.

LUND UNIVERSITY

PO Box 117  
221 00 Lund  
+46 46-222 00 00

# Strong lymphoid nuclear expression of *SOX11* transcription factor defines lymphoblastic neoplasms, mantle cell lymphoma and Burkitt's lymphoma

Michael Dictor,<sup>1</sup> Sara Ek,<sup>3</sup> Maria Sundberg,<sup>1</sup> Janina Warenholt,<sup>1</sup> Czabafy György,<sup>1</sup> Sandra Sernbo,<sup>3</sup> Elin Gustavsson,<sup>3</sup> Waleed Abu-Alsoud,<sup>2\*</sup> Torkel Wadström,<sup>2</sup> and Carl Borrebaeck<sup>3</sup>

Departments of <sup>1</sup>Pathology and <sup>2</sup>Medical Microbiology, Lund University Hospital; <sup>3</sup>Department of Immunotechnology, CREATE Health, BioMedical Center (BMC) D13, Lund University, Lund, Sweden

\*Present address: Department of Biology, University of Copenhagen, Copenhagen, Denmark

*Funding: this work was supported by a grant from the Swedish Research Council (16x-04723, to TW), ALF grants from Lund University Hospital to MD and TW, and by grants from the Lund Institute of Technology (LTH), Bioinvent International AB, the Leukemia and Lymphoma Society (Grant n. 6085-06 and R6189-09), Smärtafonden and CREATE Health, a strategic Center for Translational Cancer Research (www.createhealth.se) to CB and SE*

*Acknowledgments: the authors would like to thank Kristina Lövgren, Christina Andersson, Alicja Flasch, Helen Svensson and Ihab Dahi for their technical assistance.*

*Manuscript received on March 13, 2009. Revised version arrived on May 23, 2009. Manuscript accepted on June 1, 2009.*

*Correspondence: Michael Dictor, Department of Pathology, Lund University Hospital, Sölvegatan 25, 22185 Lund, Sweden. E-mail: michael.dictor@med.lu.se*

## ABSTRACT

### Background

We surveyed lymphomas to determine the range of expression of the mantle cell lymphoma-associated *SOX11* transcription factor and its relation to cyclin D1.

### Design and Methods

On hundred and seventy-two specimens were immunostained for the *SOX11* N and C termini. Cyclin D1 was detected by immunohistochemistry and quantitative reverse transcriptase polymerase chain reaction; *in situ* hybridization for t(11;14) was applied when needed.

### Results

Nuclear *SOX11* was strongly expressed in most B and T-lymphoblastic leukemia/lymphomas and half of childhood Burkitt's lymphomas, but only weakly expressed in some hairy cell leukemias. Chronic lymphocytic leukemia/lymphoma, marginal zone, follicular and diffuse large B-cell lymphomas were negative for *SOX11*, as were all cases of intermediate Burkitt's lymphomas/diffuse large B-cell lymphoma, myeloma, Hodgkin's lymphomas and mature T-cell and NK/T-cell lymphomas.

### Conclusions

In addition to mantle cell lymphoma, *SOX11* is strongly expressed only in lymphoblastic malignancies and Burkitt's lymphomas. Its expression is independent of cyclin D1 (except for weak expression in hairy cell leukemias) and unlikely to be due to translocations in lymphoid neoplasia.

Key words: lymphoid, *SOX11* transcription factors, lymphoblastic neoplasms, mantle cell lymphoma, Burkitt's lymphoma.

*Citation: Dictor M, Ek S, Sundberg M, Warenholt J, György C, Sernbo S, Gustavsson E, Abu-Alsoud W, Wadström T, and Borrebaeck T. Strong lymphoid nuclear expression of *SOX11* transcription factor defines lymphoblastic neoplasms, mantle cell lymphoma and Burkitt's lymphoma. Haematologica 2009; 94:1563-1568. doi:10.3324/haematol.2009.008474*

©2009 Ferrata Storti Foundation. This is an open-access paper.

## Introduction

The *SOX11* transcription factor, normally expressed in the developing central nervous system, is aberrantly transcribed and expressed in mantle cell lymphoma (MCL)<sup>1</sup> and has been suggested to correlate with overall survival.<sup>2</sup> Common MCL simulators do not express nuclear SOX11 but questions remain as to its relation to cyclin D1 (*CCND1*) and whether SOX11 is restricted to MCL. We surveyed most categories of B- and T-cell lymphomas for SOX11, including plasmacytoma/myeloma<sup>3</sup> and hairy cell leukemia, which are characterized by elevated levels of *CCND1*.<sup>4,6</sup>

## Design and Methods

Current World Health Organization (WHO) clinical, histological and immunophenotypic criteria<sup>7</sup> were used to diagnose 172 previously unreported cases of lymphoma on formalin-fixed paraffin sections, with or without ancillary flow cytometric and molecular studies. All biological material was used according to the research ethics principles established for our institution. The samples came from patients aged less than 1 year old to 89 years old. The male: female ratio was 1.7:1.

B-cell lymphoma, T-cell lymphoma, NK/T-cell lymphoma and Hodgkin's lymphoma comprised mature (peripheral) lymphomas and B/T lymphoblastic leukemia/lymphoma comprised the immature category (Table 1). CD5<sup>+</sup> B-cell lymphomas comprise subgroups within recognized lymphoma entities. Burkitt's lymphoma was distinguished by typical starry-sky and nuclear morphology, predominantly intra-abdominal origin, a Ki-67 index greater than 95% and consistent CD10<sup>+</sup> and BCL2<sup>-</sup> staining.<sup>7</sup> Intermediate Burkitt's lymphoma/diffuse large B-cell lymphoma had a similar proliferation index and starry-sky pattern but were largely nodal and showed nuclear, cellular and immunophenotypic features (strong BCL2<sup>+</sup> or CD10<sup>-</sup> in all cases) inconsistent with Burkitt's lymphoma.

### Immunohistochemistry

Sections were microwaved for antigen retrieval in Tris/EDTA, pH 9, for 8+7 min and then stained on an automatic immunostainer using SOX11 antibodies, as detailed below and, as needed, a rabbit monoclonal anti-*CCND1* antibody (1:70, NeoMarkers, USA). Signals were detected using Envision (Dako) and 3, 3'-diaminobenzidine.

### Characterization of SOX11 antibodies

Two primary rabbit anti-human SOX11 antibodies were raised by the HPR-project.<sup>8,9</sup> The first, SOX11<sup>N-term</sup>, targets the N-terminus of SOX11 and was used successfully in MCL.<sup>1</sup> The immunogen shows some homology with SOX4 but SOX11<sup>N-term</sup> shows no nuclear reactivity in tonsil sections, known to express SOX4.

SOX11<sup>C-term</sup> was raised against the immunogen EDDDDDDDDDELQLQIKQEPDEEDEEPPHQQLQPPGQQPSQLRRYNAVAKVPASPTLSSSAESPEGASLYDEV RAGATSGAGGGSRLYYSFKNITKQHPPPLAQ-

PALSPASSRSVSTSSS, a 121 amino acid carboxy terminal peptide, specific for SOX11. The specificity of both antibodies was verified in the MCL cell lines, SP53 and Granta-519, using a western blot of extracted proteins, which were separated by reducing sodium dodecyl sulphate polyacrylamide gel electrophoresis (SDS-PAGE) (NuPAGE 10% Bis-Tris gels, Invitrogen, CA, USA). Each well was loaded with lysate from approximately 6×10<sup>6</sup> cells and the gel was blotted onto a PVDF membrane (Amersham Hybond-P, GE Healthcare, Sweden) for 30 min (15 V) and blocked overnight in 5% milk/phosphate-buffered saline (PBS). SOX11<sup>N-term</sup> or SOX11<sup>C-term</sup> was applied diluted 1:500 for 30 min. After washing with PBS a horseradish peroxidase (HRP)-labeled goat anti-rabbit antibody, diluted 1:10,000 was applied. Bands were detected with SuperSignal West Femto Max Sensitivity Substrate (Pierce) according to the manufacturer's protocol.

### Short interfering RNA knockdown study

Washed Granta-519 cells were suspended in 100 µL nucleofector solution (Reactionlab, Sweden) at 5×10<sup>6</sup> cells/sample. Each cuvette was then loaded with 50 pmol of small interfering RNA (siRNA) (Ambion, Austin, USA) consisting of antisense SOX11.1 [pool] UAACGU-ACCAACAUACUUGuu, UGCGUCACG ACAUCU-UAUCuu, UCUUCGAGGAGCCUAGAGGuu and AGA-CCGACAAGCUUCAAAACuu (or controls using complementary sense oligoRNA), transfected (Amaxa Biosystems, Germany), then incubated in R-10 medium at 37°C for 3 h, plated at a density of 0.50-0.75×10<sup>6</sup> cells/mL and grown for 2-3 days.

### Quantitative real-time polymerase chain reaction

Briefly, reverse transcribed RNA template was used in a fluorogenic 5' nuclease assay to determine C<sub>T</sub> values on a Rotorgene cyler (Corbett Research). Primers and probes for *CCND1* and the reference gene *TBP* and cycling conditions have been published previously.<sup>10</sup> Each sample was run in triplicate with Granta-519 cDNA as a positive control, one negative water control and two no template controls using DNase I-treated RNA.

Gene expressions were calculated to determine the fold increase in normalized *CCND1* C<sub>T</sub> values relative to a benign node calibrator using the appropriate formulae.<sup>11</sup>

### Interphase fluorescent in situ hybridization and chromogenic in situ hybridization

We isolated whole nuclei from thick sections digested in 0.5% pepsin. Filtered nuclei were spread on a glass slide, after-fixed in Carnoy's fixative, pre-hybridized in 0.1% Triton-100, digested in 0.3 mg/mL pronase, rinsed in glycine/PBS, dehydrated in ethanol and air-dried. A dual-color, dual-fusion translocation probe (Vysis, USA) was hybridized as previously reported.<sup>1</sup> Yellow fusion signals are evidence of t(11;14). For each specimen 50 nuclei were scored for the number of fusion signals using the cut-off value of six, which was based on fusion counts in 350 total nuclei from benign nodes and follicular lymphoma.

Chromogenic *in situ* hybridization (CISH), was performed according to the manufacturer's protocol using a mixture of Texas Red- and fluorescein isothiocyanate

(FITC)-labeled probes (Dako DuoCISH™) which target sequences flanking the *CCND1* locus. Overlapping blue and red signals indicate co-localization and a split signal indicates a break at the *CCND1* locus. Several MCL were used as positive controls.

## Results

Both antibodies yielded an approximately 60 kDa band on western blots, corresponding to SOX11 (Figure

**Table 1.** Lymphoid neoplasias studied for nuclear SOX11 expression.

	N.	Site	Anti-SOX11 <sup>N-term</sup> nuclear signal	Anti-SOX11 <sup>C-term</sup> nuclear signal	CCND1 mRNA (Mean fold increase)	FISH/CISH for chromosome 11 translocation
<b>B-cell lymphoma</b>						
Mantle cell <sup>1</sup> CCND1 <sup>+</sup>	23	2 marrow, 1 salivary gland, 1 mucosa, 1 spleen, 1 chest wall, 17 node	18/23 pos	ND	5/5 pos (15-99)	5/5 pos
CLL/SLL <sup>2</sup>						
CD23 <sup>+</sup>	4	3 node, 1 mucosa	0/4 pos	ND	0/1 pos	0/1 pos
CD23 <sup>-</sup>	3	3 node	0/2 pos	ND	0/1 pos	0/3 pos
Marginal zone						
CD5 <sup>-</sup>	13	4 spleen, 4 node, 1 thyroid, 2 dermis, 1 rectum, 1 conjunctiva	0/13 pos	ND	ND	0/1 pos
CD5 <sup>+</sup>	3	1 conjunctiva, 1 breast, 1 orbit	0/3 pos	ND	0/1 pos	0/1 pos
Diffuse large B-cell						
CD5 <sup>-</sup>	26	15 node, 3 testis	0/26 pos	ND	ND	ND
CD5 <sup>+</sup>	5	5 node	0/5 pos	ND	ND	0/5 pos
Intermediate BL/DLBCL <sup>3</sup>						
Follicular	6	6 node	0/6 pos	ND	ND	ND
	5	5 node: 1 grade I, 2 grade II, 2 grade III	0/4 pos	ND	ND	ND
Myeloma						
CCND1- CCND1 <sup>+</sup>	2	2 marrow	0/2 pos	ND	ND	ND
	7	1 dermis, 1 node, 5 marrow	0/7 pos	0/1 pos	ND	N
Lymphoplasmacytic	1	nasopharynx	0/1 pos	ND	ND	ND
Burkitt <sup>4</sup>	14	2 distal ileum, 1 ovaries/cecum, 7 abdomen, 2 neck node, 1 marrow, 1 tonsil	7/14 pos	3/4 pos	ND	ND
B-cell, NOS, low grade	1	1 node	0/1 pos	ND	ND	0/1 pos
	N.	Site	Anti-SOX11 <sup>N-term</sup> nuclear signal	Anti-SOX11 <sup>C-term</sup> nuclear signal	Comments	
<b>T-cell lymphoma</b>						
Angioimmunoblastic	3	3 node	0/3 pos	ND		
ALCL, ALK1 <sup>+</sup>	4	4 node	0/4 pos	ND		
nuclear/cytoplasmic						
ALCL, ALK1 <sup>+</sup> cytoplasmic	1	1 node	0/1 pos	ND		
Mycosis fungoides	1	1 skin	0/1 pos	ND		
PTCL, NOS	4	4 node	0/4 pos	ND		
TCL, enteropathy type	2	2 small bowel	0/2 pos	ND		
TCL, hepatosplenic	1	1 spleen	0/1 pos	ND	TCRα/β <sup>+</sup>	
TCL, large granular cell	1	1 spleen	0/1 pos	ND		
T/NK	4	3 nasopharynx, 1 nose	0/4 pos	ND		
<b>Lymphoblastic neoplasia</b>						
B-lymphoblastic	9	4 leukemia, 5 lymphoma	8/9 pos	3/5 pos	Age range <1 to 69 years	
T-lymphoblastic lymphoma	10	8 thymus, 2 node	10/10 pos	4/5 pos	Age range 1 to 70 years; TdT weak in 1 case with strong SOX11 <sup>C-term</sup>	
<b>Hodgkin</b>						
Classic	5	5 node	0/5 pos	ND		
Lymphocyte predominance	2	2 node	0/2 pos	ND		

CLL/SLL, chronic lymphocytic leukemia/small lymphocytic lymphoma; BL/DLBCL, Burkitt's lymphoma/diffuse large B-cell lymphoma; NOS, not otherwise specified; ALCL, anaplastic large cell lymphoma; PTCL, peripheral T-cell lymphoma; TCL, T-cell lymphoma; TCR, T-cell receptor; Pos, positive; ND, not determined. <sup>1</sup>Three cases had blastoid morphology. <sup>2</sup>Includes a composite CCND1<sup>+</sup>/SOX11<sup>+</sup> MCL with SOX11<sup>+</sup> CLL/SLL in the same node. <sup>3</sup>age range 49 to 82 years (median 76). <sup>4</sup>age range 5 to 56 years (median 11.5) with all but one still alive (median survival 8 years); two of three cases with t(8;14) were SOX11<sup>+</sup>.

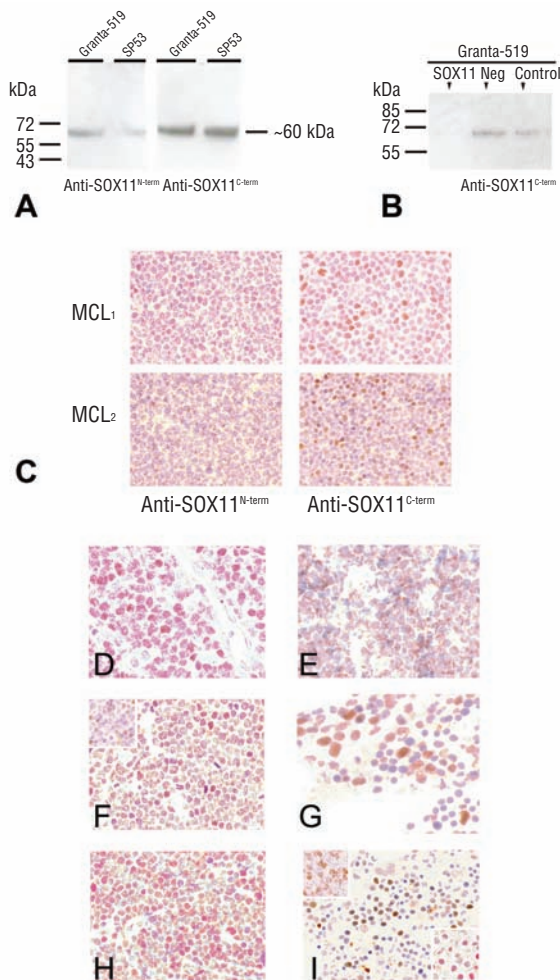


1A); after SOX11 knock-down the band was not detectable using SOX11<sup>C-term</sup> (Figure 1B). Nineteen MCL in the original report<sup>1</sup> were reanalyzed with SOX11<sup>C-term</sup> and results between the two antibodies were concordant to a high degree apart from occasional differences in staining intensity: one case remained negative with

both antibodies, one converted to being positive (Figure 1C) and two became immunonegative. Cytoplasmic staining<sup>1</sup> appeared to be reciprocally related to nuclear intensity for both antibodies and was not scored. Of 23 new MCL specimens, 19 (83%) expressed nuclear SOX11. Five of the 23 specimens were studied with molecular techniques and showed 15 to 99-fold increases in *CCND1* expression and between 14 and 72% of nuclei with fluorescent *in situ* hybridization (FISH) fusion signals, confirming the presence of t(11;14). No consistent relation between *CCND1* staining intensity, *CCND1* transcription level and the intensity of SOX11 staining was apparent. For example, two MCL showing 22 and 34-fold increases of *CCND1* mRNA lacked nuclear SOX11 protein.

Both SOX11 and molecular analysis could differentiate CD5<sup>+</sup> simulators from MCL (Table 1). Despite a lack of *CCND1*, there were challenges in distinguishing 29 cases of CD5<sup>+</sup> non-MCL, including cases of marginal zone lymphoma, CD23<sup>+</sup> chronic lymphocytic leukemia/small lymphocytic lymphoma, CD5<sup>+</sup> diffuse large B-cell lymphoma and B-cell lymphoma not otherwise specified, from MCL. Twelve of these were analyzed further and all were negative for t(11;14) by FISH and/or had normal levels of *CCND1* transcription. All 12 cases were also immunonegative for nuclear SOX11, whereas all six *CCND1*<sup>+</sup> MCL tested with molecular techniques expressed SOX11. As expected, other typical cases of chronic lymphocytic leukemia/small lymphocytic lymphoma and follicular, mantle zone and diffuse large B-cell lymphomas also lacked SOX11 in the nuclei. Hodgkin's lymphoma and T-cell lymphoma subtypes, including NK/T-cell lymphoma, were similarly negative. Most tumors in all categories which lacked nuclear SOX11 showed variably intense cytoplasmic signals, as previously reported.<sup>1</sup>

Unexpectedly, we found strong nuclear SOX11 staining in both childhood Burkitt's lymphoma and acute lymphoblastic leukemia/lymphoma, regardless of phenotype (B- or T-cell). Seven of fourteen cases of Burkitt's lymphoma were positive and this was reconfirmed with SOX11<sup>C-term</sup> staining (Figure 1D). Importantly, none of six



**Figure 1.** (A) A Western blot of proteins extracted from two MCL cell lines showing bands of approximately 60 kDa for SOX11 using either anti-SOX11 antibody. (B) The lane labeled SOX11 denotes Granta-519 cell extract after knock-down with specific siRNA and staining with anti-SOX11<sup>C-term</sup>, which yielded no band, in contrast to the SOX11 bands noted in negative and control lanes; these lanes contain extracts after nucleofection with scrambled sequence siRNA and untransfected cells, respectively. (C) A case of MCL (MCL<sub>1</sub>) with weak nuclear signals after applying SOX11<sup>N-term</sup> showed stronger signals using SOX11<sup>C-term</sup>. Another case of MCL (MCL<sub>2</sub>) showed only cytoplasmic signals until immunoreacted with SOX11<sup>C-term</sup>, after which nuclear signals appeared (DAB with hematoxylin counterstain, Olympus BX45, magnification x125, colors corrected after acquisition with Adobe Photoshop). (D) Strong nuclear SOX11 signals after staining with anti-SOX11<sup>C-term</sup> is seen in a true Burkitt's lymphoma. (E) Intermediate Burkitt's lymphoma/diffuse large B-cell lymphoma shows no nuclear stain (signal is limited to cytoplasm). (F) Positive nuclear staining in lymphoblastic neoplasia is exemplified by a case of adult nodal T-cell lymphoblastic lymphoma (inset, TdT stain). (G) Signals are present in the bone marrow from a patient with B-cell acute lymphoblastic leukemia. (H) A case of childhood orbital B-cell lymphoblastic lymphoma also expresses SOX11. (I) Bone marrow in hairy cell leukemia, case 9, expressing DBA.44 (inset, upper left), *CCND1* (inset, lower right) and SOX11 detected with anti-SOX11<sup>C-term</sup> (DAB with hematoxylin counterstain, magnification x125, except D, x230).

**Table 2.** Expression of *CCND1* and SOX11 in cases of hairy cell leukemia.\*

Case	Biospy site	<i>CCND1</i>	SOX11 <sup>N-term</sup>	SOX11 <sup>C-term</sup>
1.	Spleen	-	-	ND
2.	Marrow	(+)	(+)	-
3.	Spleen	-	-	ND
4.	Marrow	(+)	(+)	(+)
5.	Marrow	+	(+)	ND
6.	Marrow	(+)	-	ND
7.	Marrow	+	-	ND
8.	Marrow	(+)	(+)	ND
9.	Marrow	+	(+)	+
10.	Node	(+)	-	ND
11.	Marrow	-	-	ND
12.	Marrow	(+)	(+)	ND

\*Clinical, morphological and immunophenotypic (DBA44<sup>+</sup>/annexin-1<sup>+</sup>) hairy cell leukemia. ND: not determined.

high-grade adult B-cell lymphomas intermediate between Burkitt's lymphoma and diffuse large B-cell lymphoma (see footnote in Table 1) was positive with the SOX11<sup>N-term</sup> antibody (Figure 1E). Even more strikingly, all ten cases of T-cell lymphoblastic lymphoma (Figure 1F) and eight of nine stained B-cell acute lymphoblastic leukemia/lymphoblastic lymphomas (Figure 1G) were positive for SOX11<sup>N-term</sup>. SOX11<sup>C-term</sup> also confirmed the presence of the protein in three cases of B-cell lymphoblastic lymphoma but was negative in both stained B-cell acute lymphocytic leukemias; four of five tested T-cell lymphoblastic lymphomas were also positive with SOX11<sup>C-term</sup>. It was notable that two T-cell lymphoblastic lymphomas produced no or weak immunohistochemical signals for terminal deoxynucleotidyl transferase (TdT), despite their otherwise typical morphological and immunophenotypic features. The apparent slight decrease in sensitivity of SOX11<sup>C-term</sup> compared with SOX11<sup>N-term</sup> could not be further evaluated due to limited availability of SOX11<sup>C-term</sup>.

Hairy cell leukemia typically shows modestly elevated *CCND1* transcription with weak immunostaining for the protein. Our previous study showed no upregulation of *SOX11* transcription but we nevertheless found very weak SOX11<sup>N-term</sup> immunostaining in six of 12 (DBA44<sup>+</sup>/annexin-1<sup>+</sup>) cases (Table 2), which generally paralleled the strength of the *CCND1* signal, in contrast to the lack of staining covariation noted in MCL. Moreover, in two of three cases of hairy cell leukemia tested the presence of SOX11 protein was confirmed with the SOX11<sup>C-term</sup> antibody but only a single specimen (case 9 in Table 2) produced a moderately strong signal (Figure 1H-I). The third subtype with frequent modestly upregulated *CCND1* transcription was represented by seven cases of *CCND1*<sup>+</sup> myeloma (n=5)/plasmacytoma (n=2) and two cases of *CCND1*<sup>-</sup> myeloma (Table 1). Regardless of *CCND1* status, the nuclear SOX11 signal was consistently absent.

## Discussion

The Sox family of transcription factors is widely distributed in animals and SOX proteins are implicated in fundamental developmental processes such as differentiation of murine embryonic stem cells,<sup>12</sup> neurogenesis and chondrogenesis.<sup>13</sup> SOX11 is expressed in the developing human nervous system,<sup>14</sup> medulloblastoma<sup>15</sup> and glioma<sup>16</sup> but has no defined role in B-lymphocyte ontogeny. We have previously shown that SOX11 is aberrantly expressed in both MCL<sup>1</sup> and epithelial ovarian cancer<sup>17</sup> in which SOX11 predicts recurrence-free survival. Although the functional effect and downstream genes activated by SOX11 are yet to be described, it is intriguing that the strong nuclear expression of SOX11 in lymphoid neoplasia appears limited to three disparate categories, which include the two mature B-cell tumors, MCL and true Burkitt's lymphoma, and immature lymphoblastic neoplasms. Further study of the biology of this cohort may reveal common pathways to neoplasia related to SOX11 expression.

Interestingly, frequent nuclear SOX11 expression in clinically, morphologically and genetically typical Burkitt's lymphoma was not matched by expression in adult intermediate Burkitt's lymphoma/diffuse large B-cell lymphoma. The number of cases was too small to draw firm conclusions but the potential difference merits more extensive investigation.

We reconfirmed nuclear SOX11 expression in the vast majority of prospectively studied MCL. Rare clinically and morphologically typical cases of MCL with or without t(11;14)(q13;q32) may fail to stain for *CCND1*, using a sensitive rabbit monoclonal antibody.<sup>1,18</sup> This study confirms the consistent SOX11 immunonegativity in the nuclei of common MCL simulators, including the problematic CD5<sup>+</sup> variants of common peripheral B-cell lymphoma subtypes, for which ancillary molecular techniques may not be available to rule out *CCND1*-MCL. It remains to be determined whether SOX11 is expressed in MCL variants lacking the t(11;14) translocation and expressing cyclin D2 or cyclin D3, which are said to maintain the MCL gene expression signature.<sup>19</sup>

The mechanism of SOX11 dysregulation is unclear but our negative immunostaining for nuclear SOX11 in *CCND1*<sup>+</sup> myeloma cells indicates that the protein is not dependent on *CCND1*. In myeloma, upregulated *CCND1* is due to a polysomic chromosome 11 in half of cases, while in about one in six cases it is due to the same translocation as in MCL: t(11;14)(q13;q32).<sup>3</sup> Moreover, strong SOX11-specific signals occurred at high frequency in Burkitt's lymphoma and T and B-lymphoblastic neoplasms, tumors devoid of t(11;14) but which may contain a variety of other translocations, including those involving transcription factors. These facts make it unlikely that any recognized structural or numerical chromosomal changes are a direct cause of elevated SOX11. Hairy cell leukemia differed markedly from all the above neoplasms in that nuclear SOX11 staining, present in about half of the specimens, was generally very weak and paralleled that of weak or negative cyclin D1, the regulation of which is not due to altered gene dosage or t(11;14).<sup>4</sup> It should be noted that the presence of SOX11 in lymphoblastic leukemia/lymphoma introduces an important cause for caution in the use of this marker for MCL given that adult lymphoblastic lymphoma is a rare morphological mimic of MCL.

In conclusion, strong nuclear SOX11 expression in lymphoma is extended to include even lymphoblastic and Burkitt's lymphomas, indicating a wider role for the protein in lymphomagenesis than previously reported.

## Authorship and Disclosures

MD wrote the paper and takes primary responsibility for it. SE and CB were the principal investigators and responsible for developing the antibodies with SE, SS, EG performing the special laboratory work involved with testing the antibodies. MD and JW developed protocols and performed *in situ* hybridization experiments. MS, CG, WA-A and TW ran the RT-PCR assay.

The authors reported no potential conflicts of interest.

## References

- Ek S, Dictor M, Jerkeman M, Jirstrom K, Borrebaeck CA. Nuclear expression of the non B-cell lineage Sox11 transcription factor identifies mantle cell lymphoma. *Blood* 2008;111:800-5.
- Wang X, Asplund AC, Porwit A, Flygare J, Smith CI, Christensson B, et al. The subcellular Sox11 distribution pattern identifies subsets of mantle cell lymphoma: correlation to overall survival. *Br J Haematol* 2008;143:248-52.
- Troussard X, Avet-Loiseau H, Macro M, Mellerin MP, Malet M, Roussel M, et al. Cyclin D1 expression in patients with multiple myeloma. *Hematol J* 2000;1:181-5.
- Bosch F, Campo E, Jares P, Pittaluga S, Munoz J, Nayach I, et al. Increased expression of the PRAD-1/CCND1 gene in hairy cell leukaemia. *Br J Haematol* 1995;91:1025-30.
- de Boer CJ, Kluin-Nelemans JC, Dreef E, Kester MG, Kluin PM, Schuurin E, et al. Involvement of the CCND1 gene in hairy cell leukemia. *Ann Oncol* 1996;7:251-6.
- Miranda RN, Briggs RC, Kinney MC, Veno PA, Hammer RD, Cousar JB. Immunohistochemical detection of cyclin D1 using optimized conditions is highly specific for mantle cell lymphoma and hairy cell leukemia. *Mod Pathol* 2000;13:1308-14.
- Swerdlow SH, Campo E, Harris NL, Jaffe E, Pileri SA, Stein H, et al. WHO Classification of Haematopoietic and Lymphoid Tumours. 4<sup>th</sup> edition. Lyon: IARC, 2008.
- Agaton C, Galli J, Hoiden Guthenberg I, Janzon L, Hansson M, Asplund A, et al. Affinity proteomics for systematic protein profiling of chromosome 21 gene products in human tissues. *Mol Cell Proteomics* 2003;2:405-14.
- Ek S, Andréasson U, Hober S, Kampf C, Ponten F, Uhlen M, et al. From gene expression analysis to tissue microarrays: a rational approach to identify therapeutic and diagnostic targets in lymphoid malignancies. *Mol Cell Proteomics* 2006;5:1072-81.
- Specht K, Kremer M, Muller U, Dirnhofner S, Rosemann M, Hofler H, et al. Identification of cyclin D1 mRNA overexpression in B-cell neoplasias by real-time reverse transcription-PCR of microdissected paraffin sections. *Clin Cancer Res* 2002;8:2902-11.
- Livak KJ, Schmittgen TD. Analysis of relative gene expression data using real-time quantitative PCR and the 2<sup>-ΔΔC(T)</sup> method. *Methods* 2001;25:402-8.
- Kuroda T, Tada M, Kubota H, Kimura H, Hatano SY, Suemori H, et al. Octamer and Sox elements are required for transcriptional cis regulation of Nanog gene expression. *Mol Cell Biol* 2005;25:2475-85.
- Ng LJ, Wheatley S, Muscat GE, Conway-Campbell J, Bowles J, Wright E, et al. SOX9 binds DNA, activates transcription, and coexpresses with type II collagen during chondrogenesis in the mouse. *Dev Biol* 1997;183:108-21.
- Hargrave M, Wright E, Kun J, Emery J, Cooper L, Koopman P. Expression of the SOX11 gene in mouse embryos suggests roles in neuronal maturation and epithelio-mesenchymal induction. *Dev Dyn* 1997;210:79-86.
- Lee CJ, Appleby VJ, Orme AT, Chan WI, Scotting PJ. Differential expression of SOX4 and SOX11 in medulloblastoma. *J Neurooncol* 2002;57:201-14.
- Weigle B, Ebner R, Temme A, Schwind S, Schmitz M, Kiessling A, et al. Highly specific overexpression of the transcription factor SOX11 in human malignant gliomas. *Oncol Rep* 2005;13:139-44.
- Brennan DJ, Ek S, Doyle E, Drew T, Foley M, Flannelly G, et al. The transcription factor SOX11 is a prognostic factor for improved recurrence-free survival in epithelial ovarian cancer. *Eur J Cancer* 2009;45:1510-7.
- Cheuk W, Wong KO, Wong CS, Chan JK. Consistent immunostaining for cyclin D1 can be achieved on a routine basis using a newly available rabbit monoclonal antibody. *Am J Surg Pathol* 2004;28:801-7.
- Fu K, Weisenburger DD, Greiner TC, Dave S, Wright G, Rosenwald A, et al. Cyclin D1-negative mantle cell lymphoma: a clinicopathologic study based on gene expression profiling. *Blood* 2005;106:4315-21.