



LUND UNIVERSITY

Breast cancer screening with tomosynthesis

Tingberg, Anders; Zackrisson, Sophia

Published in:
Hospital Imaging & Radiology Europe

2010

[Link to publication](#)

Citation for published version (APA):
Tingberg, A., & Zackrisson, S. (2010). Breast cancer screening with tomosynthesis. *Hospital Imaging & Radiology Europe*, 5(2), 44-46.

Total number of authors:
2

General rights

Unless other specific re-use rights are stated the following general rights apply:
Copyright and moral rights for the publications made accessible in the public portal are retained by the authors and/or other copyright owners and it is a condition of accessing publications that users recognise and abide by the legal requirements associated with these rights.

- Users may download and print one copy of any publication from the public portal for the purpose of private study or research.
- You may not further distribute the material or use it for any profit-making activity or commercial gain
- You may freely distribute the URL identifying the publication in the public portal

Read more about Creative commons licenses: <https://creativecommons.org/licenses/>

Take down policy

If you believe that this document breaches copyright please contact us providing details, and we will remove access to the work immediately and investigate your claim.

LUND UNIVERSITY

PO Box 117
221 00 Lund
+46 46-222 00 00

Breast cancer screening with tomosynthesis

Results from studies carried out at Malmö University Hospital show that breast tomosynthesis has the potential to improve the sensitivity and specificity of breast cancer screening

Mammography is not perfect – between 15 and 30% of all cancers are missed at mammography screening and detection is particularly difficult in dense breasts.¹ There are several reasons for the non-detection of tumours; the normal anatomy being the major one. In two-dimensional (2D) mammography, all structures along the path of the x-rays are superimposed, and tumours may be hidden by the normal tissue (resulting in false negative mammography) or, in some cases, the normal tissue may appear as if a tumour were present in the breast (false positive mammography). Both of these situations are highly undesirable as they might result in incorrect diagnosis. It would be advantageous to use a tomographic technique to suppress the appearance of the overlapping tissue, and thus increase the detection of tumours.

Over the last decade, tomosynthesis has achieved a lot of attention, particularly for breast examinations. The x-ray tube moves around a stationary detector and acquires several so called projection images from different angles of the compressed breast. These images are reconstructed into an image volume, from which individual slices can be studied. The slice images contain little of the overlapping tissue and detection of tumours is increased.

Some groups have investigated the clinical value of breast tomosynthesis (BT), ie, in diagnostic work-up in women selected from screening, but there are already several techniques including conventional 2D digital mammography (DM), ultrasonography (US), needle biopsies, MRI available in the diagnostic setting. A combination of these methods usually yields high sensitivity and specificity.

It is, however, our strong belief that the greatest value of BT will be in screening examinations. We

base this hypothesis on several reasons: The sensitivity and specificity of DM in a screening setting is not high enough. A tomosynthesis examination is fairly similar to a conventional mammography examination, both for the woman who is examined and for the radiographer, both with respect to examination time and to the image acquisition procedure. The tomosynthesis images are comparable to mammograms making comparisons with older images possible. The radiation dose in a tomosynthesis examination is comparable to a conventional mammography examination; the dose from one tomosynthesis projection is approximately the same as a conventional two-view examination (CC + MLO). In this paper we are presenting some of the studies that we have performed in our group in order to investigate the possibilities of using breast tomosynthesis as a screening modality. In 2006, Siemens Healthcare installed a BT prototype unit, one of a few in the world at that time, at our laboratory at Malmö University Hospital. To investigate the difference between BT and DM, we collected images of patients where we believed that difference between the two modalities would be maximised. The inclusion criteria were as follows: Unclear or negative mammography, and palpable and/or visible on ultrasound. We had permission from the local ethics committee at Lund University and all patients underwent informed consent. During roughly two and a half years we collected over 250 cases, forming one of the largest breast tomosynthesis tumour banks in the world, and over 150 normal or benign cases. The cancers were verified with needle biopsy and pathology, and the normal or benign cases with two-year follow-up.

Clinical value of breast tomosynthesis

In a pilot study we evaluated 40 cases containing confirmed cancers system in a non-blinded

Anders Tingberg

Department of Radiation Physics
Skåne University Hospital, Malmö
205 02, Malmö, Sweden

Sophia Zackrisson

Diagnostic Centre of Imaging and
Functional Medicine, Skåne University
Hospital, Malmö
205 02, Malmö, Sweden



Have **your** say ...

Email us at:
hire-feedback@campden.com



For more therapeutic radiology, visit ...
hospitalradiologyeurope.com/therapeutic_radiology

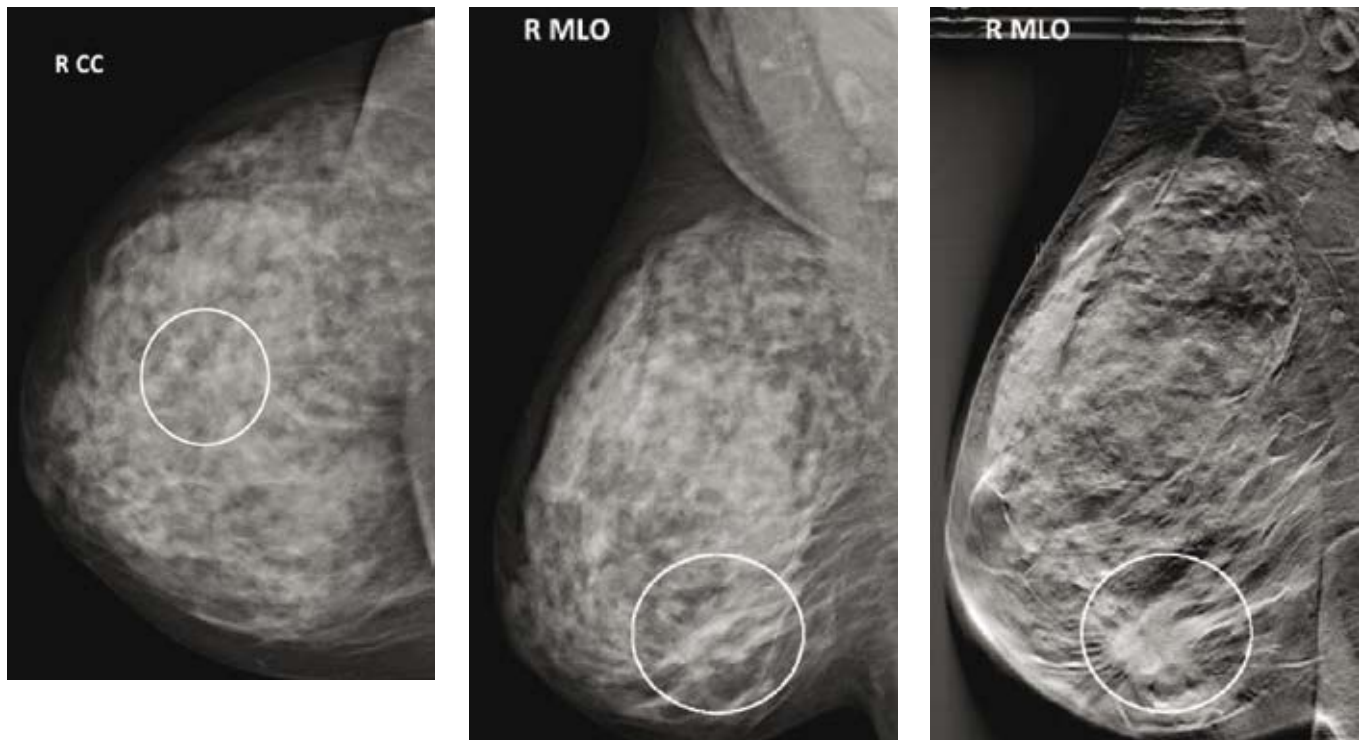


Figure 1. Left and middle are mammograms in the CC and MLO projections, respectively, of the right breast of a 57 year-old woman. To the right is the same breast imaged with tomosynthesis. Note that the tumour, a 2.8 cm grade 3 ductal cancer, (marked with circle) is clearly visible in the tomosynthesis image, but difficult to detect in the two mammography images.

study. Two experienced radiologists evaluated these cases in consensus based on the following imaging modalities or combined modalities; 1-view mammography, 2-view mammography, 2-view mammography and US, and BT. Only steps 1–5 of the BIRADS scale were used (0 and 6 are not applicable on existing images). A perfect performance would thus be five for all cases, but the observers overlooked this prior knowledge and based the evaluations solely on the images. Differences between the three first modalities and BT were evaluated with VGC.² The results of this study showed that BT was significantly better than 1-view mammography and 2-view mammography, and equal to the combination of 2-view mammography and US.³

We performed a more detailed study comparing breast tomosynthesis and mammography in 200 cases (110 normal and 90 abnormal) examined both with DM (CC & MLO projections) and BT. All cases were verified with two-year follow-up on the normal and histopathology on the abnormal. Five experienced radiologists evaluated all cases according to the FROC procedure: search for suspicious locations and rank these locations with the BIRADS scale. The results of this study indicated that BT was significantly better than DM at finding and classifying breast lesions. This study was presented at RSNA 2009.

Accuracy of tumour size measurements

Accurate size prediction of an invasive breast cancer is important in preoperative planning and as a prognostic indicator. With the increased use of breast-conserving surgery and neoadjuvant chemotherapy, the ability to correctly determine maximum tumour extent noninvasively is essential. Preoperative tumour size is commonly measured on DM and/or US, and subsequently during the pathological examination of the tumour. We investigated the accuracy of size measurements with BT, DM and US compared to PAD on 73 malignant breast tumours. The results showed that the measurements were more accurate for BT than for DM and US.⁴

Detectability in DM and BT

In a more theoretical setting we studied the detectability of malignant lesions with DM compared to BT. We varied the contrast of lesions of different sizes and added them in disease-free breasts imaged with DM and BT. The sizes of the lesions were 0.2 (corresponding to microcalcifications), 1, 3, 8 and 25mm, resulting in a range of typical tumour sizes. The observers were presented with four images, where one of them contained a lesion, and the task of the observer was to select the image containing the tumour. The results of the study showed that the detectability of BT was significantly better for

lesions bigger than or equal to 1mm, whereas for the smallest lesion size (0.2mm), DM was equal to BT. In many diagnostic tasks, it is the overlapping anatomy that limits detection of pathologic lesions. With the removal of overlapping structures in BT the detectability of lesions increases. However, for microcalcifications, it is the quantum noise in the image that limits the detection, and thus making the two modalities perform equally well.

Optimal compression in breast tomosynthesis

Compression is necessary in conventional DM for several reasons: to reduce the thickness of the breast in order to improve the image quality by reducing the amount of scattered radiation produced, and to reduce the required radiation dose and last but not least to fixate the breast and thus avoid motion blur. The compression of the breast causes pain and in some cases this may cause women not to participate in the screening program. Since tomosynthesis allows depth resolution, it might even be an advantage to use less compression force compared to DM. In a study by Förnvik et al, 45 women were investigated with standard compression (ie, the compression force that is used at an ordinary mammography examination) and half of that force. The quality of the images was evaluated in a visual grading analysis⁵ study by three experienced radiologists

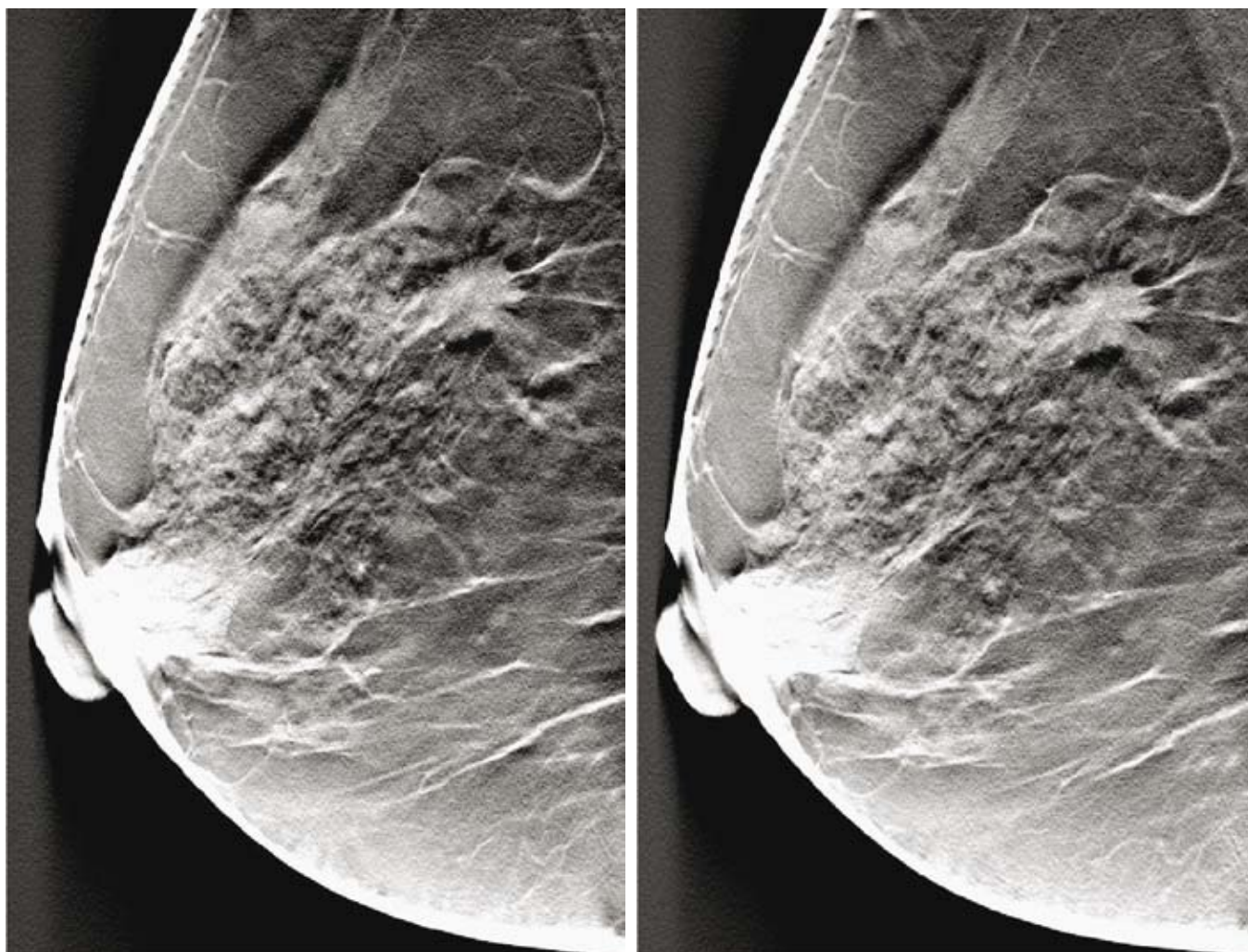


Figure 2. Example of an image pair obtained with standard compression (left) and half compression (right). The quality of the two images is similar.

and the results showed no significant difference in image quality.⁶ Figure 2 shows an example of a breast imaged with standard (left) and half (right) compression force.

Breast cancer screening with tomosynthesis

All of these studies suggest that BT could complement or even replace DM in a screening situation. But before any definite conclusions could be drawn on this, BT must be tested in a real screening situation, ie, in large, population based studies. In December 2009, Siemens replaced the tomosynthesis prototype system with a commercial version of the tomosynthesis system, Mammomat Inspiration Tomo. Several shortcomings with the prototype unit were fixed with the new machine, eg, shortening the reconstruction time and the time for the machine to change between DM and BT mode. The new machine is thus possible to use in breast cancer screening with the requirements of high patient throughput. We have planned to evaluate the sensitivity and specificity of BT compared to DM in a one-armed, paired study by examining

15,000 women, randomly selected from the regular screening programme, with the two methods. After getting approval from the local ethics committee at Lund University, we have started to perform some initial examinations. Currently, we have performed over 200 examinations, including three confirmed cancers. Since the size of the image data is significantly larger than from other modalities (typically in the range of 0.5 GB per breast, one projection), the speed of the network and PACS (picture archiving and communications system) and also the storage capacity of the PACS will be challenged. This will probably be a problem for most current PACS systems. The examination time for BT is roughly the same as for DM. However, the image reading time is one of the major concerns if BT should gain a general acceptance for clinical routine use in breast cancer screening, with its extremely high patient throughput. Based on the experiences so far, we believe that the reading time of BT is at least twice the reading time of DM. It is often the PACS system that limits the reading time, since retrieving of the BT image volume is much more time consuming

than for the DM images. The reading time could be decreased by optimised viewing tools, quicker PACS systems, etc.

Conclusions

Based on the results of the studies presented above, we conclude that breast tomosynthesis has the potential to improve the sensitivity and specificity of breast cancer screening, but this must be investigated in large screening studies. ■

1. Laming D, et al. *J Med Screen* 2000;7(1):24–30.
2. Båth M, et al. *Br J Radiol* 2007;80:169–76.
3. Andersson I, et al. *Eur Radiol* 2008 Dec;18(12):2817–25.
4. Föörvik D, et al. *Acta Radiol* 2010 Jan 28;51(3):240–7.
5. Tingberg A. Quantifying the quality of medical x-ray images. An evaluation based on normal anatomy for lumbar spine and chest radiography. Thesis. Malmö: Lund University; 2000.
6. Föörvik D, et al. *Radiat Prot Dosimetry* 2010 Mar 11.