



# LUND UNIVERSITY

## Acromioclavicular joint dislocations. Epidemiology, radiography and outcome

Nordin, Jonas

2020

*Document Version:*

Publisher's PDF, also known as Version of record

[Link to publication](#)

*Citation for published version (APA):*

Nordin, J. (2020). *Acromioclavicular joint dislocations. Epidemiology, radiography and outcome*. [Doctoral Thesis (compilation), Department of Clinical Sciences, Lund]. Lund University, Faculty of Medicine.

*Total number of authors:*

1

### General rights

Unless other specific re-use rights are stated the following general rights apply:

Copyright and moral rights for the publications made accessible in the public portal are retained by the authors and/or other copyright owners and it is a condition of accessing publications that users recognise and abide by the legal requirements associated with these rights.

- Users may download and print one copy of any publication from the public portal for the purpose of private study or research.
- You may not further distribute the material or use it for any profit-making activity or commercial gain
- You may freely distribute the URL identifying the publication in the public portal

Read more about Creative commons licenses: <https://creativecommons.org/licenses/>

### Take down policy

If you believe that this document breaches copyright please contact us providing details, and we will remove access to the work immediately and investigate your claim.

LUND UNIVERSITY

PO Box 117  
221 00 Lund  
+46 46-222 00 00

# Acromioclavicular joint dislocations

## Epidemiology, radiography and outcome

---

JONAS NORDIN

CLINICAL SCIENCES, LUND | FACULTY OF MEDICINE | LUND UNIVERSITY





## Acromioclavicular joint dislocations

Acromioclavicular joint dislocations are common injuries predominantly affecting young adults injured during sports or in traffic. In the available evidence there are controversies regarding both epidemiological data, diagnosis and treatment methods. This thesis aimed to investigate the epidemiology, radiography and outcome after surgical and conservative treatment of acromioclavicular joint dislocations.

We have calculated the incidence of acromioclavicular joint dislocations in a mostly urban population, and showed that young men are the most commonly injured, while older age and traffic accidents were risk factors for high-grade dislocations. In a study on radiographic techniques we report that internal rotation, or weighted, radiographs are not useful in the classification of acromioclavicular joint dislocations compared to non-weighted radiographs. The outcome after low-grade dislocations was investigated and one third of the patients were unsatisfied with their shoulder two years after the injury. In a surgical case series we present a high complication rate using the AC-GraftRope device and suggest that this technique should be avoided. Finally, we studied the outcome after gracilis tendon autograft harvest and found that patients seemed to tolerate this procedure well but suffered a slightly reduced knee flexion strength. I hope these results will be of interest to caregivers consulting patients with acromioclavicular joint dislocations.



## Acromioclavicular joint dislocations



# Acromioclavicular joint dislocations

Epidemiology, radiography and outcome

Jonas Nordin



**LUND**  
UNIVERSITY

DOCTORAL DISSERTATION


by due permission of the Faculty of Medicine, Lund University, Sweden.  
To be defended at Medicinhistoriska museet, Bergaliden 20, Helsingborg.  
December 18<sup>th</sup> 2020, at 9.00 a.m.

*Faculty opponent*  
Professor Lars Adolfsson  
Linköping University, Sweden

<b>Organization</b> LUND UNIVERSITY Department of Clinical Sciences, Lund Orthopaedics Author Jonas Nordin		<b>Document name</b> DOCTORAL DISSERTATION	
		<b>Date of issue</b> 2020-11-04	
		Sponsoring organization	
<b>Title and subtitle</b> Acromioclavicular joint dislocations: Epidemiology, radiography and outcome.			
<b>Abstract</b> <p><b>Background:</b> Acromioclavicular joint (ACJ) dislocations are common and frequently affecting young adults injured during sports. The Rockwood classification system is used to grade the dislocations according to the extent of injury to the soft tissues stabilizing the joint. Rockwood type 1 and 2 are not proper dislocations but partial ligamentous injuries without complete ACJ separation and regarded as low-grade injuries. Rockwood type 3-6 are high-grade injuries with complete dislocation of the joint. There is a lack of epidemiological knowledge and controversy regarding how to best radiograph and how to treat ACJ dislocations.</p> <p><b>Aims:</b> To increase the knowledge regarding epidemiology, radiography and outcome after ACJ dislocation.</p> <p><b>Patients and methods:</b> This thesis is based on 2 patient cohorts. The first consists of prospectively included patients with ACJ dislocations within the last 2 weeks. Epidemiologic data was obtained, patients underwent study radiographs and were followed using the patient related outcome measures (PROMs); the disabilities of the arm, shoulder, and hand (DASH) score, and the EuroQol-5 dimension (EQ-5D) visual analogue scale (VAS) for life quality. The second cohort included patients with chronic ACJ dislocations planned for reconstructive surgery. Patients were operated using the AC-GraftRope device, a technique that uses an autologous gracilis tendon graft. The shoulder was evaluated using radiographs and computed tomography (CT) scans, as well as DASH score, Constant-Murley score and EQ-5D VAS. The graft donor leg was assessed using measurement of isometric knee flexion strength, and the knee injury and osteoarthritis outcome score (KOOS).</p> <p><b>Results:</b> Paper I describe the epidemiology of ACJ dislocations. The incidence was 2.0 per 10,000 person-years decreasing with higher age. Sports activity was the most common trauma mechanism and men were injured more often than women. Higher age and traffic accidents were risk factors for high-grade injury. Paper II shows that weighted, or internal rotation radiographs are not useful in uncovering high-grade ACJ dislocations. In paper III patients with Rockwood type 1 and 2 injuries were assessed at 2 years and almost one third were unsatisfied with their shoulder. The trial for paper IV was halted prematurely due to a high rate of complications with 4 out of 8 patients suffering a loss of reduction. In 3 cases the reason was a fracture through the drill tunnel in the coracoid process. Paper V evaluated the donor leg after gracilis tendon harvest and there was no evidence that subjective knee function was affected, but a slight decrease in knee flexion strength compared to the contralateral leg was seen.</p> <p><b>Conclusions:</b> The incidence of ACJ dislocations is 2.0 per 10,000 person-years. Men are injured more often than women and injury during sports is common. Higher age and traffic accidents are risk factors for high-grade injuries. Weighted or internal rotation radiographs are not useful in the classification of ACJ dislocations. Rockwood type 1 and 2 dislocations are not insignificant injuries with one third of the patients unsatisfied with their shoulder. The AC-GraftRope is not a safe treatment method and should be avoided. Patients seem to tolerate gracilis tendon harvesting well.</p>			
<b>Key words</b> Acromioclavicular joint, dislocation, separation, epidemiology, radiography			
Classification system and/or index terms (if any)			
Supplementary bibliographical information Lund University, Faculty of Medicine Doctoral Dissertation Series 2020:133.		<b>Language</b> English	
<b>ISSN</b> 1652-8220		<b>ISBN</b> 978-91-8021-000-3	
Recipient's notes	<b>Number of pages</b>		Price
	Security classification		

I, the undersigned, being the copyright owner of the abstract of the above-mentioned dissertation, hereby grant to all reference sources permission to publish and disseminate the abstract of the above-mentioned dissertation.

Signature



Date 2020-11-04

# Acromioclavicular joint dislocations

Epidemiology, radiography and outcome

Jonas Nordin



**LUND**  
UNIVERSITY



Cover illustration by Louise Betsholtz

Copyright pp 1-84 Jonas Nordin

Paper 1 © the authors (open access)

Paper 2 © the foundation Acta Radiologica

Paper 3 © the authors (manuscript unpublished)

Paper 4 © the Nordic Orthopaedic Federation

Paper 5 © the authors (open access)

Faculty of Medicine  
Department of Clinical Sciences, Lund

ISBN 978-91-8021-000-3

ISSN 1652-8220

Printed in Sweden by Media-Tryck, Lund University  
Lund 2020



Media-Tryck is a Nordic Swan Ecolabel  
certified provider of printed material.  
Read more about our environmental  
work at [www.mediatryck.lu.se](http://www.mediatryck.lu.se)

**MADE IN SWEDEN** 

*To my family*



# Table of Contents

<b>Abstract .....</b>	<b>11</b>
<b>Abbreviations.....</b>	<b>13</b>
<b>List of papers.....</b>	<b>15</b>
<b>Thesis at a glance .....</b>	<b>17</b>
<b>Populärvetenskaplig sammanfattning .....</b>	<b>19</b>
<b>Background .....</b>	<b>21</b>
History .....	21
Anatomy .....	21
Biomechanics .....	23
Assessment of the acromioclavicular joint.....	24
Clinical examination.....	24
Radiographic examination.....	26
Other imaging modalities .....	27
Classification.....	28
History .....	28
The Rockwood classification .....	29
Epidemiology .....	31
Treatment .....	32
Treatment according to Rockwood classification .....	32
Conservative or surgical treatment? .....	34
Early or delayed surgery? .....	35
Surgical techniques .....	36
Surgery for acute ACJ dislocations .....	36
Surgery for chronic ACJ dislocations.....	38
Measuring outcome .....	39
PROMs .....	39
<b>Aims .....</b>	<b>41</b>
Specific aims .....	41

<b>Patients and Methods .....</b>	<b>43</b>
The patient cohorts .....	43
The acute cohort .....	43
The surgical cohort .....	45
Imaging techniques .....	46
Study radiographs .....	46
Follow-up radiographs .....	47
Computed tomography (CT) .....	47
Surgical techniques .....	47
CC ligament reconstruction .....	47
Gracilis tendon harvest .....	48
Follow-up .....	48
Outcome measures .....	49
PROMs .....	49
Knee flexion strength .....	50
Statistical methods .....	50
Ethical considerations .....	51
<b>Results in summary .....</b>	<b>53</b>
Paper I .....	53
Paper II .....	54
Paper III .....	55
Paper IV .....	56
Paper V .....	57
<b>General discussion .....</b>	<b>59</b>
Epidemiology .....	59
Weighted and internal rotation radiographs .....	60
Outcome after Rockwood type 1 and 2 ACJ dislocations .....	61
Surgical treatment of chronic ACJ dislocations .....	62
Outcome after gracilis tendon harvest .....	63
Limitations .....	64
<b>Conclusions .....</b>	<b>67</b>
<b>Future perspectives .....</b>	<b>69</b>
<b>Acknowledgements .....</b>	<b>71</b>
<b>References .....</b>	<b>73</b>

# Abstract

## *Background*

Acromioclavicular joint (ACJ) dislocations are common and frequently affecting young adults injured during sports. The Rockwood classification system is used to grade the dislocations according to the extent of injury to the soft tissues stabilizing the joint. Rockwood type 1 and 2 are not proper dislocations but partial ligamentous injuries without complete ACJ separation and regarded as low-grade injuries. Rockwood type 3-6 are high-grade injuries with complete dislocation of the joint. There is a lack of epidemiological knowledge and controversy regarding how to best radiograph and how to treat ACJ dislocations.

## *Aims*

To increase the knowledge regarding epidemiology, radiography and outcome after ACJ dislocation.

## *Patients and methods*

This thesis is based on 2 patient cohorts. The first consists of prospectively included patients with ACJ dislocations within the last 2 weeks. Epidemiologic data was obtained, patients underwent study radiographs and were followed using the patient related outcome measures (PROMs); the disabilities of the arm, shoulder, and hand (DASH) score, and the EuroQol-5 dimension (EQ-5D) visual analogue scale (VAS) for life quality. The second cohort included patients with chronic ACJ dislocations planned for reconstructive surgery. Patients were operated using the AC-GraftRope device, a technique that uses an autologous gracilis tendon graft. The shoulder was evaluated using radiographs and computed tomography (CT) scans, as well as DASH score, Constant-Murley score and EQ-5D VAS. The graft donor leg was assessed using measurement of isometric knee flexion strength, and the knee injury and osteoarthritis outcome score (KOOS).

## *Results*

Paper I describe the epidemiology of ACJ dislocations. The incidence was 2.0 per 10,000 person-years decreasing with higher age. Sports activity was the most common trauma mechanism and men were injured more often than women. Higher age and traffic accidents were risk factors for high-grade injury. Paper II shows that weighted, or internal rotation radiographs are not useful in uncovering high-grade

ACJ dislocations. In paper III patients with Rockwood type 1 and 2 injuries were assessed at 2 years and almost one third were unsatisfied with their shoulder. The trial for paper IV was halted prematurely due to a high rate of complications with 4 out of 8 patients suffering a loss of reduction. In 3 cases the reason was a fracture through the drill tunnel in the coracoid process. Paper V evaluated the donor leg after gracilis tendon harvest and there was no evidence that subjective knee function was affected, but a slight decrease in knee flexion strength compared to the contralateral leg was seen.

### *Conclusions*

The incidence of ACJ dislocations is 2.0 per 10,000 person-years. Men are injured more often than women and injury during sports is common. Higher age and traffic accidents are risk factors for high-grade injuries. Weighted or internal rotation radiographs are not useful in the classification of ACJ dislocations. Rockwood type 1 and 2 dislocations are not insignificant injuries with one third of the patients unsatisfied with their shoulder. The AC-GraftRope is not a safe treatment method and should be avoided. Patients seem to tolerate gracilis tendon harvesting well.

# Abbreviations

AC	Acromioclavicular
ACCR	Anatomic coracoclavicular reconstruction
ACJ	Acromioclavicular joint
AI	Anteroinferior
AP	Anteroposterior
CA	Coracoacromial
CC	Coracoclavicular
CI	Confidence interval
CT	Computed tomography
DASH	Disabilities of the arm, shoulder, and hand
EQ-5D	EuroQol-5 dimension
KOOS	Knee injury and osteoarthritis outcome score
MRI	Magnetic resonance imaging
PROM	Patient related outcome measure
SP	Superoposterior
VAS	Visual analogue scale





# List of papers

This thesis is based on the following papers, referred to in text by their roman numerals.

- Paper I. **Acromioclavicular joint dislocations: incidence, injury profile, and patient characteristics from a prospective case series.** Jonas S Nordin, Ola Olsson, Karl Lunsjö. JSES International, 4, 246-250, 2020.
- Paper II. **Weighted or internal rotation radiographs are not useful in the classification of acromioclavicular joint dislocations.** Jonas S Nordin, Felicia Mogianos, Anders Hauggaard, Karl Lunsjö. Acta Radiologica, online ahead of print, 2020 Jul 13;284185120939270.
- Paper III. **A prospective study of Rockwood type 1 and 2 acromioclavicular joint dislocations in a general population: radiological and patient related outcome at two years.** Jonas S Nordin, Ola Olsson, Karl Lunsjö. In manuscript.
- Paper IV. **Chronic acromioclavicular joint dislocations treated by the GraftRope device. A prospective trial halted prematurely due to a high rate of complications.** Jonas S Nordin, Knut E Aagaard, Karl Lunsjö. Acta Orthopaedica, 86(2), 225-228, 2015.
- Paper V. **The gracilis tendon autograft is a safe choice for orthopedic reconstructive procedures: a consecutive case series studying the effect of tendon harvesting.** Jonas S Nordin, Ola Olsson, Karl Lunsjö. BMC Musculoskeletal Disorders, 20, Article number: 138, 2019.



# Thesis at a glance

Paper	Aim	Method	Results	Conclusion
I	To describe the epidemiology of ACJ dislocations in a general population.	Prospective study of 157 patients aged 18-75 years with acute ACJ dislocations classified according to Rockwood.	The incidence was 2.0 per 10,000 person-years decreasing with age. Older age and injury from traffic accidents were risk factors for high-grade dislocations.	The incidence of ACJ dislocations in a general population was 2.0 per 10,000 person-years decreasing with higher age.
II	To evaluate if weighted or internal rotation radiographs are useful in the classification of ACJ dislocations.	Classifications from non-weighted radiographs were compared to weighted and internal rotation radiographs in 138 patients	Weighted or internal rotation radiographs did not uncover more high grade ACJ dislocations compared to non-weighted radiographs.	Weighted or internal rotation radiographs are not useful in the classification of ACJ dislocations.
III	To assess the 2 year outcome in patients with Rockwood type 1 and 2 ACJ dislocations.	65 prospectively included patients were evaluated. Outcome measures were DASH, EQ-5D VAS and radiographs.	7 patients required surgery before follow-up. For the remainder median DASH and EQ-5D were good but one third were not satisfied with their shoulder. Radiographic findings did not correlate with satisfaction or PROMs.	Rockwood type 1 and 2 injuries are not insignificant with almost one third of patients unsatisfied with their shoulder.
IV	To evaluate the AC-GraftRope surgical method for treatment of chronic ACJ dislocations	Prospective case series with planned 2 year follow-up using Constant-Murley, DASH, EQ-5D VAS, radiographs and CT scans.	The trial was halted prematurely because 4 out of 8 patients suffered a loss of reduction. In 3 of these the reason was a fracture of the coracoid process.	The AC-GraftRope technique is not safe for the treatment of ACJ dislocations.
V	To study the outcome after autologous gracilis tendon harvesting	Case series of 22 patients. Follow-up with KOOS and isometric knee flexion strength compared between the operated and contralateral leg.	KOOS scores were not significantly worse at 12 months compared to baseline. Knee flexion strength of the operated leg was decreased.	Gracilis tendon harvesting seems to be well tolerated but knee flexion strength is decreased.



# Populärvetenskaplig sammanfattning

Nyckelbenet möter skulderbladet i akromioklavikularleden (AC-leden) som utgör den enda leden mellan arm och skulderblad och resten av skelettet. När AC-leden går ur led (luxerar) skadas stabiliserande ledkapsel och ligament vilket innebär att armen blir hängande i de muskler som förbinder överarmsbenet och skulderbladet med bröstkorgen. Detta resulterar i att armen och skulderbladet sjunker ner och en felställning där nyckelbensänden täftar huden på axelns ovansida uppkommer.

AC-ledsluxationer är vanliga och utgör ca 10% av alla axelskador. Förekomst av skadan och patientkaraktäristika finns beskrivet i flera studier av sportutövare så som ishockeyspelare, amerikanska fotbollsspelare och alpina skidåkare. Det finns dock endast två tidigare publikationer med motsvarande uppgifter från en mer generell population.

AC-ledsluxationer graderas efter allvarlighet enligt en skala med 6 steg som kallas för Rockwoods klassifikationssystem. Vid klassifikation används röntgen och klinisk undersökning för att uppskatta skadans utbredning i ledkapseln och de ligament som stabiliserar leden. Vid Rockwood typ 1 och 2 är ligamentskadorna partiella och leden inte helt luxerad, dessa skador kan betraktas som låggradiga. Vid Rockwood typ 3-6 är skadan mer omfattande och AC-leden helt luxerad, dessa skador är höggradiga. Vilken sorts röntgenundersökning som bäst avbildar instabiliteten i AC-leden är inte fastställt.

Låggradiga skador behandlas alltid icke-kirurgiskt (konservativt), ofta med gott resultat. Det finns dock studier som antyder att restsymtom är vanligt. För höggradiga skador är behandlingen i det akuta skedet oftast konservativ med fysioterapi, men för vissa patienter fungerar inte detta och operation kan bli nödvändig. Det finns idag ingen standardmetod för hur höggradiga AC-ledsluxationer bör opereras i kroniskt skede och många kirurgiska tekniker är behäftade med en hög komplikationsfrekvens varför nya metoder eftersöks.

Denna avhandling baseras på två patientgrupper. Den första består av patienter mellan 18 och 75 år med akuta AC-ledsluxationer. När patienterna inkluderades i projektet genomfördes röntgen med särskilda studieröntgenbilder och olika uppgifter om patientkaraktäristika och skademekanism samlades in. Den andra gruppen består av patienter med kroniska AC-ledsluxationer där kirurgi planeras.

I studie 1 kartläggs förekomst av AC-ledsluxationer, skademekanismer, gradfördelning och patientkaraktäristika. Analysen består av 157 patienter från vårt sjukhus upptagningsområde vilket innebär att skadefrekvensen är ungefär 2 AC-ledsluxationer per 10 000 personer och år. Män skadar sig betydligt oftare än kvinnor och olika typer av sport är den vanligaste orsaken. Patienter som skadar sig i trafikolyckor eller är äldre får fler höggradiga skador än andra. I studie 2 jämförs 138 patienters röntgenbilder och resultaten visar att undersökningar med vikter hängande runt handlederna eller med armarna i inåtrotation inte är bättre än vanliga röntgenbilder på att identifiera höggradiga AC-ledsluxationer. I studie 3 följs 65 patienter med låggradiga skador under 2 år. Sju patienter opererades på grund av smärta och funktionsbortfall, och av de resterande är nästan en tredjedel missnöjda med sin axel.

I studie IV utvärderas AC-GraftRope, en ny kirurgisk behandlingsmetod för att operera kroniska AC-ledsluxationer. Operationen innebär att ett implantat och en sena fästs mellan nyckelbenet och korpnäbbsutskottet på skulderbladet i den skadade axeln, den plats där de avslitna ledbanden tidigare funnits. Implantatet ska sedan skydda reparationen under tiden som senan läker fast. Senan är en av knäböjarna (gracilis) som transplanteras från patientens eget ben till axeln. Denna studie fick avbrytas i förtid på grund av att AC-leden luxerade på nytt för 4 av 8 patienter. 3 av dessa komplikationer berodde på en fraktur i korpnäbbsutskottet. Vi bytte därefter operationsmetod till en som också utnyttjar samma sena men där den axelkirurgiska tekniken är annorlunda. Studie 5 kartlägger hur patienterna påverkas av att gracilissenan använts som transplantat. Vi kunde inte påvisa någon effekt på den subjektiva knäfunktionen men däremot blev den uppmätta böjstyrkan något svagare i det opererade knät jämfört med det friska.

Sammanfattningsvis inträffar AC-ledsluxationer hos 2 per 10 000 personer och år. Skadan är vanligare hos unga och män, men äldre och de som skadas i trafiken har större risk för höggradiga skador. Vid klassificering av skadan räcker det med vanliga röntgenbilder, belastade eller inåtroterade bilder tillför ingen information. Låggradiga skador är möjligtvis underskattade och nästan en tredjedel av patienterna är missnöjda med sin axel. AC-GraftRope är en olämplig operationsmetod men att gracilissenan används som transplantat verkar patienterna tåla väl.

# Background

## History

Acromioclavicular joint (ACJ) dislocations have posed a challenge to medical practitioners since the birth of modern medicine. Hippocrates (460-370 BC) described the injury in his works and recognized the risk of confusing it with a glenohumeral dislocation since “the top of the shoulder appears low and hollow.” The suggested treatment involved bandages applied to push the projecting clavicle down and fasten the upper arm to the torso in an elevated position to reduce the joint. Hippocrates further described that no disability would be expected after such an injury but that the deformity would remain [1]. Galen (129-210 AD), who suffered an ACJ dislocation himself during a wrestling match, seems to have studied the regime suggested by Hippocrates. He treated himself with “such a tight bandage as no man else could have borne; and after having the bandage upon him for a long while, was cured at last” [1].

The first surgical treatment of an ACJ dislocation is credited to Samuel Cooper, who, in 1861, operated three patients using a cerclage technique with silver wire to secure the acromion to the clavicle after removing the cartilage from the joint surfaces. The wire was extracted after six weeks, and excellent results were reported [2, 3]. In 1917 Cadenat described the transfer of the coracoacromial ligament from the acromion to the lateral clavicle as a method of reconstructing a chronic ACJ dislocation [3]. Weaver and Dunn further developed this procedure in 1972 into the widely used technique that bear their names [4]. Today there are more than 60 surgical techniques to treat ACJ dislocations, indicating that a superior “gold standard” is yet to be discovered [5-7].

## Anatomy

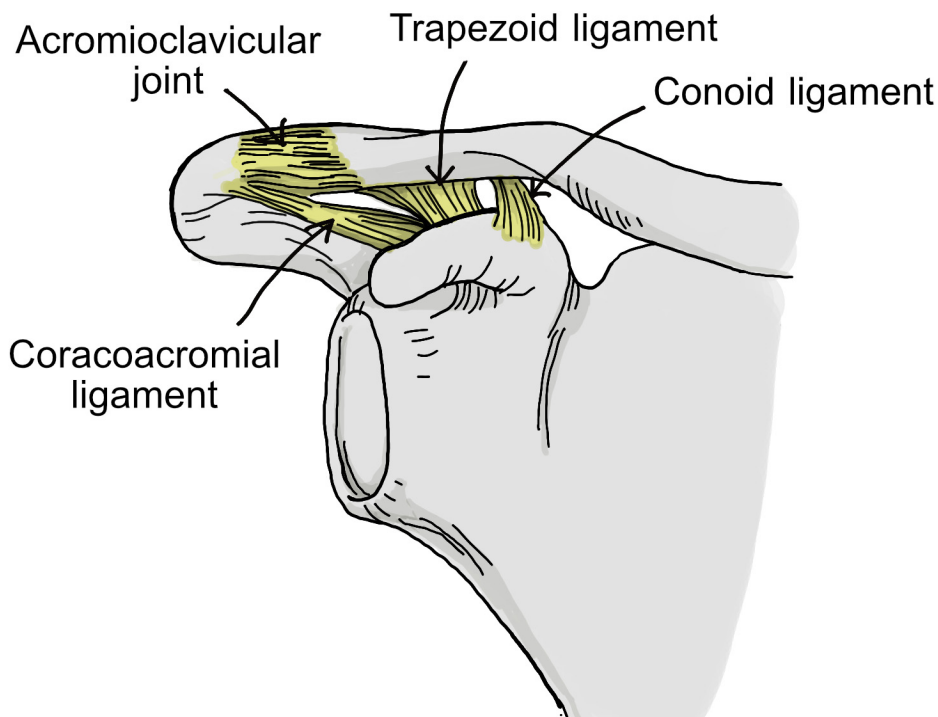
The ACJ is a synovial joint between the lateral end of the clavicle and the medial acromion. The bony anatomy of both the acromion and clavicle and, thus, the orientation of the joint, show high inter-individual variation [8-10]. The joint surfaces are covered by cartilage, and an intra-articular fibrocartilaginous disc is normally present [11]. Degeneration leading to the obliteration of the intra-articular disc and reducing joint space occur with increasing age and is considered normal [12].



Surrounding the ACJ is a capsule containing the acromioclavicular (AC) ligaments (figure 1). These ligaments have traditionally been described as thickenings of the joint capsule on all its sides, resulting in four bundles; a superior, inferior, anterior, and posterior [11, 13]. More recent anatomical studies have shown that there are, in fact, two bundles, the superoposterior (SP) and the anteroinferior (AI). The former is the sturdiest and runs superiorly from the posterior surface of the lateral clavicle to the anterior of the acromion. The latter shows more variation in its anatomy and connects the anterior clavicle to the anterior acromion, sometimes running more inferiorly and sometimes more superiorly [14].

Further stabilizing the joint is the coracoclavicular (CC) ligaments that consist of two separate structures, the trapezoid, and the conoid ligaments (figure 1). Both run between the superior surface of the coracoid process to the inferior clavicle, thereby suspending the scapula and shoulder girdle from the clavicle. The trapezoid ligament originates from the top of the coracoid process and has a superior, anterior, and lateral direction. The centre of its insertion is 26 mm medial to the lateral end of the clavicle on the anterior half of the bone's inferior surface. The conoid ligament originates on the coracoid process, posteriorly and medial to the trapezoid, and it runs superiorly and medially to the conoid tubercle on the clavicle. The insertion is 45 mm medial to the lateral end of the clavicle [11, 15, 16].

The ACJ is covered by the deltotrapezoid fascia, also known as the deltotrapezoid aponeurosis, referring to the common insertion of the anterior deltoid and upper trapezoid muscles. This fascia blends with the ACJ capsule and the superoposterior bundle of the AC ligaments adding to the stability of the ACJ [14, 17, 18].



**Figure 1. The anatomy of the ACJ.**

Illustration by Louise Betsholtz, with permission from the artist.

## Biomechanics

The shoulder girdle is a complex unit consisting of the glenohumeral, the acromioclavicular, and the sternoclavicular joints. The thoracoscapular interaction can be viewed functionally as the fourth joint of the shoulder. Together, these joints allow a large range of motion that is important for the full use of the arm. The clavicle is the only bony connection between the axial skeleton and the upper extremity and works as a strut, providing leverage and support for many of the muscles acting across the shoulder. During elevation of the arm, the ACJ undergoes 20-30° of axial rotation and the same amount of angulation in the coronal plane contributing significantly to the normal range of motion [19-21].

The ACJ is stabilized by the AC ligaments, the CC ligaments, and the deltotrapezoid fascia. Biomechanical studies have provided insight into the properties of each of these structures [18, 21-25]. The AC ligaments are the primary restraints to AP translation of the clavicle with the SP bundle mainly resisting posterior translation and the AI bundle resisting anterior translation. Transecting the AC ligaments

results in a significantly increased in situ force in the CC ligaments, a near doubling of AP-translation of the clavicle, but only a slight increase in SI instability [21-23, 25]. The CC ligaments are stiffer and more robust than the AC ligaments and constitute the primary stabilizers in the SI plane. In the absence of the AC ligaments, the trapezoid becomes the main restraint to posterior translation, and the conoid to superior and anterior translation of the clavicle. The trapezoid is slightly larger and stronger than the conoid [22, 23, 25].

The deltotrapezoid fascia reinforces the SP bundle of the AC ligaments; however, the fascia's biomechanical importance is not well understood. Only one previous laboratory study with substantial limitations has attempted to shed light on this topic and found that transection of the deltotrapezoid fascia led to a slight increase in ACJ instability. The clinical relevance of this finding is questioned by the authors [18].

A final contributor to the stability of the ACJ is the contact between the bony surfaces of the joint. There is evidence that compressive forces over the joint, as occur during normal use of the arm, result in a reduced load on the AC ligaments, potentially protecting them from injury [25, 26].

## Assessment of the acromioclavicular joint

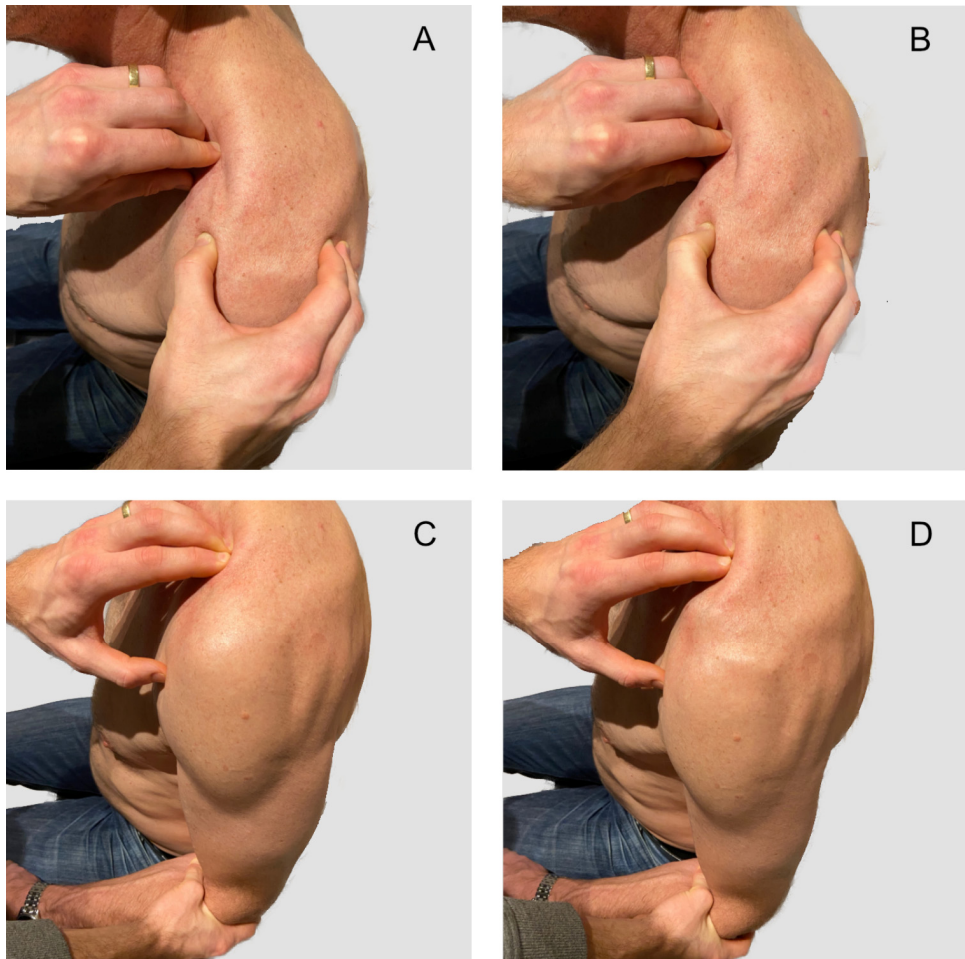
### Clinical examination

The subcutaneous position of the ACJ makes it accessible for clinical examination; therefore, swelling or dislocation can usually be easily identified. Pain from the ACJ is distinctly centred over the joint and radiates along the trapezius muscle and the anterior deltoid [27]. Examination of the injured ACJ must always include a complete shoulder assessment as concomitant pathologies are common [28].

Specific examination of the ACJ is carried out with inspection and palpation of the joint to identify swelling, hematoma, tenderness, and suspected dislocations or fractures. The most common test is the cross-arm adduction test. It is performed by elevating the arm to 90° and adducting it across the body with the elbow bent at 90°, thus causing a compression of the ACJ. The test is positive if pain in the joint is exacerbated. It is important to ask the patient where the pain is felt as the test can otherwise be falsely interpreted as positive because of pain caused by a stretch in the dorsal structures of the shoulder. Pain on palpation, a positive cross-body adduction test, and relief of pain after intraarticular injection of local anaesthetic is considered diagnostic for ACJ pathology [29-31].

To examine a suspected ACJ dislocation stability testing is performed (figure 2). To test for horizontal instability the examiner stabilizes the acromion between the thumb and fingers, grasp the clavicle with the other hand and move it in the AP

plane. When comparing to the uninjured side an increased laxity can be identified. Vertical instability is tested by placing one hand on top of the clavicle with the index finger over the ACJ. The other hand is used to indirectly move the acromion in the vertical plane by lifting under, or pulling on, the elbow. An instability is usually easily detectable [29-31].



**Figure 2. Clinical examination of the ACJ.**

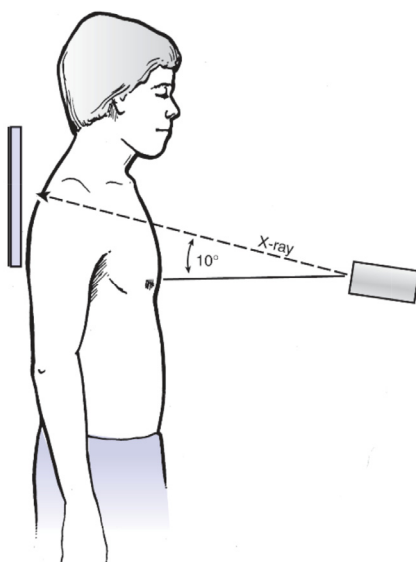
Patient with a chronic Rockwood type 3 ACJ dislocation of the left shoulder. In the top row examination of horizontal instability. A. Reduced clavicle. B. Posteriorly dislocated clavicle. In the bottom row examination of vertical instability. C. Upward force on the elbow and reduced ACJ. D. Downward force on the elbow with exaggerated dislocation. Authors' photographs, with permission from the model.

## Radiographic examination

Despite the development and increased accessibility of modern imaging techniques, plain radiographs remain the mainstay for examination of the injured ACJ. It is important to note that normal shoulder radiographs are not adequate for visualizing the ACJ because of overpenetration and improper perspective. A protocol for specific ACJ images should be used [32-34].

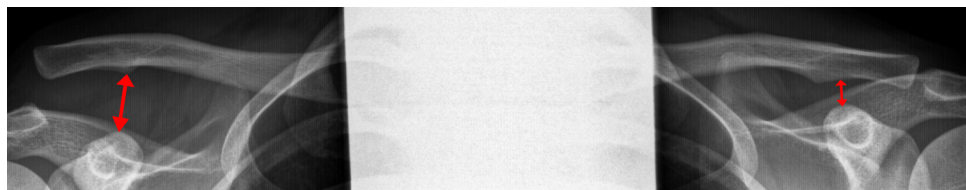
### *Anteroposterior views*

AP views are performed to assess ACJ pathology such as osteoarthritis, osteolysis, fractures or dislocations. The patient should be standing or sitting with the arms hanging freely. If the arm is supported, or the patient supine, a vertical displacement could be masked. The radiographs are taken with a 10-15° cephalic tilt to avoid superimposing the ACJ on the spine of the scapula, a so called Zanca view (figure 3) [32-34]. As there is great individual variation in ACJ anatomy it is important that the unaffected side is imaged for comparison [9, 29]. It is also preferable if both ACJs are included in the same wide radiograph to achieve as similar projections as possible [29, 34]. To evaluate vertical displacement the CC interval is measured and compared to the unaffected side (figure 4). This interval is usually defined as the closest distance between the superior cortex of the coracoid process and the inferior of the clavicle, and can be measured with high inter- and intra-observer reliability [29, 30, 35].



**Figure 3. Zanca view radiographic set up.**

With permission from Wolters Kluwer Health, Inc [36].



**Figure 4. Zanca view panorama radiograph.**  
CC intervals are marked by red doubleheaded arrows.

Weighted radiographs or stress-views can be performed by suspending weights from the patients' wrists. Usually 10 pounds or 5 kg weights are used. This technique is advocated by some because it is believed that involuntary muscle shielding can reduce a dislocated ACJ risking that the injury is underestimated [34, 37]. However, the evidence regarding the usefulness of such radiographs is conflicting and surveys among shoulder surgeons indicate that the popularity of stress-views is declining [37-40]. Results from a laboratory study indicate that radiographs with the shoulder in internal rotation could help to exaggerate the vertical instability of an ACJ dislocation and thus replace weighted radiographs, however, this has not been clinically evaluated [41].

#### *Views to evaluate horizontal instability*

A basic rule of radiography is that at least two perpendicular views should be used. The AP view of the ACJ cannot diagnose horizontal displacement of the joint. For a complete assessment it is therefore logical to add a radiograph that allows this. However, despite much research, there is so far no technique that can accomplish a reproducible way to evaluate horizontal instability. The axillary view is commonly used but has a tendency to overestimate posterior translation of the clavicle relative to the acromion and has poor reproducibility. Alternative radiographic views including dynamic examinations have been studied but so far none is superior [35, 42-44].

## **Other imaging modalities**

### *Computed tomography*

Computed tomography (CT), with its excellent contrast and resolution, is superior for fracture evaluation. However, the examinations are typically performed in the supine position, and without the effect of gravity ACJ dislocations can appear less displaced than they truly are. There is evidence that CT scans are not useful in the classification or diagnosis of ACJ dislocations [33, 45, 46].

### *Magnetic resonance imaging*

Magnetic resonance imaging (MRI) with its superior soft tissue resolution has been proven to adequately depict the stabilizing structures surrounding the ACJ and studies have shown that it can be used to grade the severity of acute dislocations [47, 48]. Since the individual ligaments can be visualized one is not dependant on displacement to infer if they are ruptured, and therefore the supine position is not as problematic as with other modalities for the diagnosis of acute ACJ dislocations. However, for chronic injuries there might be ligamentous healing presenting as a continuous structure that can only be proven to have inadequate tension if stress is applied [49].

MRI provides more detail than other modalities, for example partial injuries of the ligaments can be visualized. Because of this a separate MRI-based classification system has been suggested [50, 51]. The clinical relevance or implication of this higher level of detail is, however, unknown.

### *Ultrasound*

Ultrasound can be used to visualize both the superior part of the AC ligaments, the CC ligaments and to dynamically evaluate instability of the ACJ. The main benefit of the technique is the ability to perform a dynamic examination, its low cost and wide availability. The downsides are the steep learning curve and user dependence [33, 52, 53].

## Classification

### **History**

The need of a classification system for ACJ dislocations was recognized in 1917 by Cadenat when he wrote “To proclaim the good functional result of a method of treatment for dislocation of the clavicle without specifying whether the lesion was complete or not, is absolutely illusory”. In Cadenats practice the dislocations were classified as incomplete if the CC ligaments were intact or stretched, clinically evident as a normal, or subluxated, ACJ. Injuries with ruptures of both the AC- and CC ligaments were classified as complete. Cadenat further described the sequential injury pattern to the stabilizing structures of the ACJ that has been the foundation of all classification systems since. Experiments showed that with increasing force rupture occurred first in the AC ligaments, followed by the CC ligaments and finally the deltotrpezoid fascia [3].

In 1963 Tossy et al. introduced a new classification system with three grades according to the extent of damage to the stabilizing soft tissues. Classification was performed using weighted AP-radiographs and clinical examination. The importance

of comparison to the intact side was emphasized. Grade 1 was defined as a strain of the ACJ without complete ligament injuries and with no discernible dislocation. Grade 2 was described as a complete rupture of the AC ligaments and partial injury to the CC ligaments, radiographically visible as a 50% increase in the CC distance on the injured side compared to the intact. Grade 3 injuries were defined as complete dislocations clearly visible both clinically and radiographically [54]. In 1967 Allman described a classification system similar to that of Tossy et al. except that in grade 2 injuries the CC ligaments were described as intact and not partially torn [31].

## The Rockwood classification

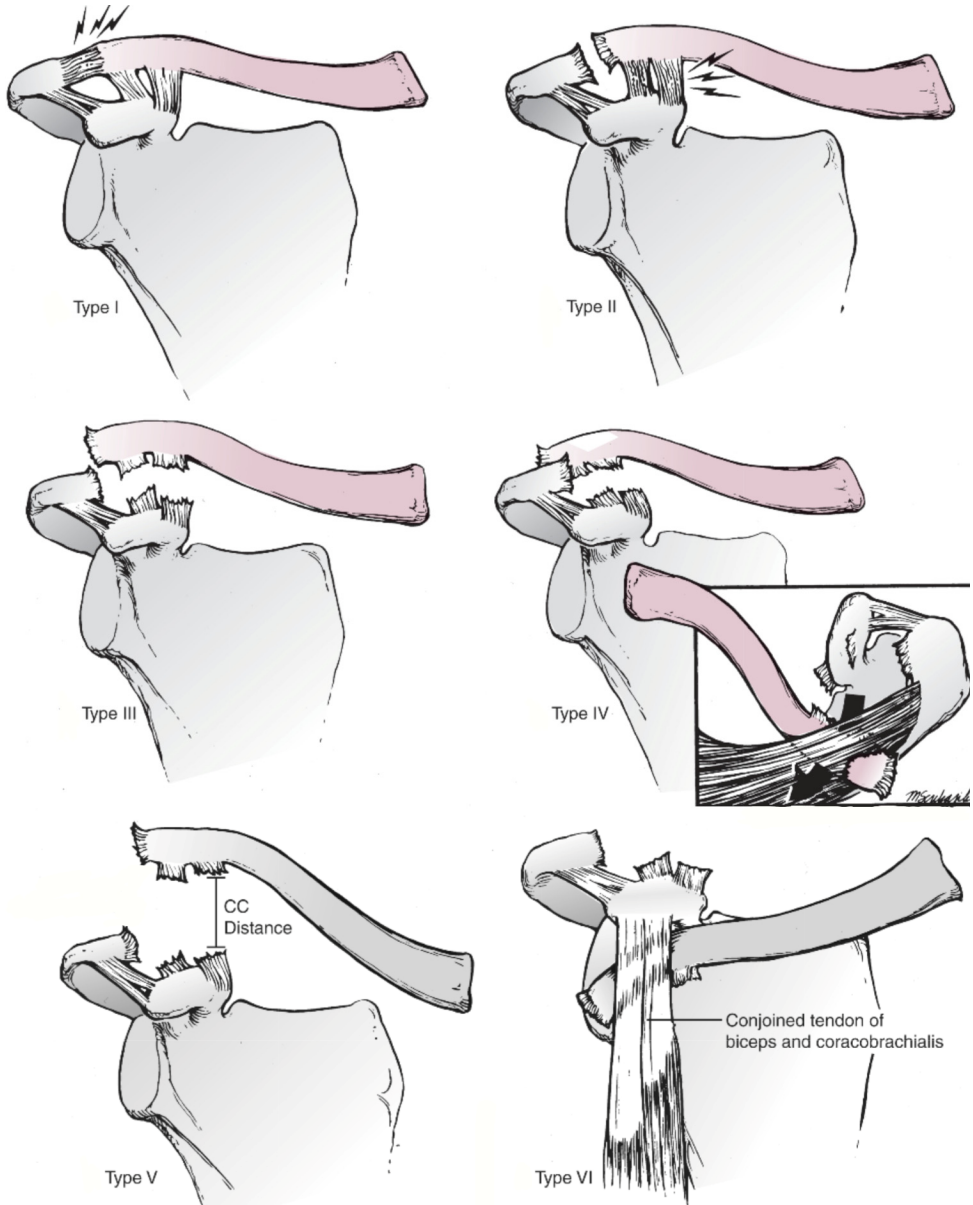
Today, the Rockwood classification system is the most commonly used. It expands the previous classifications to include six different types of ACJ dislocations. Rockwood recognized the need to include disruption of the deltotrapezoid fascia in the assessment as these injuries are more severe than those only affecting the ligaments [30, 55]. He also added the rare inferior dislocation of the clavicle. The Rockwood classification system is described in table 1 and figure 5.

**Table 1. The Rockwood classification.**

The change in CC distance is calculated by comparison to the uninjured side.

Rockwood type	AC ligaments	CC ligaments	Deltotrapezoid fascia	Radiographs	Clinical examination of ACJ
1	Intact or partial injury	Intact	Intact	Normal	Stable
2	Ruptured	Intact or partial injury	Intact	Normal or widening of ACJ and/or <25% increase in CC distance	Horizontal instability
3	Ruptured	Ruptured	Intact or lateral detachment	25-100% increase in CC distance	Horizontal and vertical instability
4	Ruptured	Ruptured	Detached with dorsal injury	Increased or normal CC distance. Possibly visible on axial view	Large horizontal instability
5	Ruptured	Ruptured	Large detachment or rupture	>100% increased CC distance	Horizontal and large vertical instability
6	Ruptured	Ruptured	Varying injury	Inferior dislocation of the clavicle	Risk of neurovascular injury





**Figure 5. The Rockwood classification.**  
With permission from Wolters Kluwer Health, Inc [36].

### *Limitations*

While widely used, there is agreement that the Rockwood classification has limitations. The ability of the classification to guide in treatment choice is questioned and despite numerous studies there is still no consensus on the indications for surgery [6, 7, 56, 57]. Modifications to the classification system has been suggested to make it more clinically useful [56].

The injuries to the ligaments and fascia used to classify according to Rockwood are inferred using plain radiographs and clinical examination. MRI studies have shown that there is inaccuracy in this assessment and that partial injuries to stabilizing structures complicate classification even further [50, 51].

Several authors have reported on the inter- and intra-observer reliability of the system and presented differing results. However, in studies where a digital ruler is used to measure the CC distance, as opposed to only visual assessment, reliability is good [45, 58, 59].

## Epidemiology

ACJ dislocations typically occur from a direct force to the top of the shoulder driving the acromion inferiorly. More rarely they occur through an indirect trauma transmitted via the arm to the ACJ, for example a fall onto the elbow driving the head of the humerus into the acromion. With increasing force, the stabilizing structures are ruptured sequentially as described above [30, 60, 61].

The epidemiology of ACJ dislocations has been extensively studied in different groups of athletes [62-71]. The injuries commonly occur during high speed events or during contact sports. ACJ dislocations are the most common shoulder injuries reported in sports such as rugby, ice-hockey, snowboarding and in American football quarter backs [64, 66, 67, 69, 70, 72]. The gender difference reported from general populations, where men are more at risk than women, has been studied in snowboarders and collegiate ice-hockey players, with reciprocal results [61, 62, 66, 67, 72, 73].

The epidemiology of ACJ dislocations in general populations is less well described and comprise four studies on three separate cohorts. Two of these reports provide details regarding patients suffering from ACJ injuries while the others present data on various shoulder injuries in a broader perspective. The studies show that ACJ dislocations have an incidence of 0.8-4.5 per 10 000 person-years and accounts for 4-10% of all shoulder injuries. Men suffer ACJ dislocations significantly more often than women, the male:female ratio is 4.6-8.5:1. Young adults are the most frequently injured, with average age for injury reported to be in the thirties. However, the age distribution seems to be explained by men being injured predominantly in their twenties. For women the incidence is more evenly distributed

with similar rates from age 20 to 60. Injury during sports is the most common mechanism closely followed by road accidents. The panorama of sports reported differ between cohorts, likely depending on geographical and cultural differences [61, 62, 73, 74].

## Treatment

There is a plethora of studies on the treatment of ACJ dislocations, however, their level of evidence is generally low, and many questions remain unanswered.

### **Treatment according to Rockwood classification**

The purpose of the Rockwood classification system is to provide guidelines that assist in treatment choice and recovery prediction after ACJ dislocations. Despite numerous studies there is still a lack of consensus regarding many important questions such as treatment indications, appropriate surgical and conservative techniques, and expected recovery [5-7, 30, 55, 75, 76]. These questions are discussed further below in this section.

#### *Rockwood type 1 and 2 dislocations*

Rockwood type 1 and 2 ACJ dislocations can be considered low-grade injuries, and there is wide consensus that patients with these injuries should be treated conservatively [5, 7, 75]. There are, however, no randomized trials comparing different treatment protocols and there is no evidence to support a specific conservative method. In textbooks and studies reporting on the outcome after low-grade ACJ dislocations similar treatment protocols are described. A sling is used for comfort, non-narcotic analgesics are recommended, range of motion is resumed as pain subsides, followed by strengthening exercises [29, 60, 77-80].

The outcome after low-grade ACJ dislocations is reported as excellent by many authors [60, 81, 82]. However, there are studies indicating that residual symptoms might be underestimated and that up to 50% of patients suffer sequela [79, 80, 83, 84]. Further, there is one study reporting that surgery is indicated in 27% of patients with low-grade ACJ dislocations [78].

There are no authors that recommend surgery as a primary treatment for low-grade ACJ dislocations. However, a lateral clavicle excision is commonly performed on patients who suffer persistent disability and ACJ pain. Favourable post-operative results can be expected [85, 86].

### *Rockwood type 3 dislocations*

For decades, it has been debated if patients with Rockwood type 3 ACJ dislocations should be treated conservatively or surgically. Today, most authors suggest initial conservative treatment with surgery reserved for patients suffering persisting symptoms [5, 7, 57, 75, 76]. There are, however, current authors who recommend primary surgery [87]. The arguments and evidence of this debate are described further below in the section titled “Conservative or surgical treatment?”

As for low-grade injuries, there is not enough evidence to support a specific conservative treatment regime. In the acute phase recommendations are similar to those for low-grade injuries. A typical regime includes a sling for comfort, non-narcotic analgesics and early start of range of motion exercises [29, 60, 77].

However, type 3 injuries differ from the lower grades in that the scapula is completely separated from the rest of the skeleton, and therefore dependent solely on its musculature to maintain position and rhythm during arm movement. It has been shown that scapulothoracic dyskinesia after ACJ separation is common and might be associated with poor outcome [88]. A rehabilitation protocol focusing on scapular positioning and strengthening of the muscles controlling the scapula has been suggested and promising results have been reported from a case series [89, 90].

For patients suffering persistent symptoms surgery is an option. When the conservative regime should be abandoned depends on the severity of the symptoms and recommendations in the literature differ [60, 76]. The large number of operative techniques available, and the lack of a “gold standard”, make it difficult to give general recommendations regarding the use of surgery as a treatment for ACJ dislocations [5-7, 76]. Different aspects of surgical treatment are described below in the section “Surgical techniques”.

The outcome for patients with Rockwood type 3 injuries has been reported by several authors [91-94]. After conservative treatment 80-88% of patients have favourable results, also athletes and manual labourers can achieve acceptable shoulder function. Even when conservative treatment is considered successful some residual symptoms can be present. Most commonly, fatigue with overhead activities, reduced bench press strength, trouble carrying heavy loads and cosmetic complaints [91-94]. For patients that fail conservative treatment pain is the main problem [95].

### *Rockwood type 4 to 6 dislocations*

For patients with high-grade injuries, Rockwood type 4-6, surgery is widely recommended [5, 29, 60, 75, 76]. However, the recommendation does not rest on solid evidence as there is a lack of studies.

For patients with a Rockwood type 4 dislocation where the clavicle is incarcerated in the trapezius muscle the need for active treatment is obvious as pain is often

substantial. However, a Rockwood type 4 injury can also be defined as a situation where the clavicle has a large horizontal instability and special dynamic radiographic techniques have been suggested to depict this [44]. This definition of a type 4 dislocation makes it less distinguishable from type 3 or type 5 injuries. Regardless of Rockwood classification, large horizontal instability seems to be associated with worse outcome and for such patients surgical treatment might be preferable although further research is warranted [96, 97].

For Rockwood type 5 dislocations the general recommendation is surgical treatment. This recommendation is based on only a few studies with partially contradictive conclusions [93, 98-101]. The long-term outcome after acute surgery for type 5 dislocations is excellent in one retrospective case series, although early complications occurred in 18 out of 50 patients [98]. Two studies with a maximum of 5 years follow-up indicate that patients with type 5 injuries suffer significant symptoms if treated conservatively [93, 99]. In a retrospective comparative study with at least 2 years follow-up 20 patients with Rockwood type 5 injuries were treated surgically and compared to 21 conservatively treated patients. The surgical group had better quality of life and functional outcome measures [101]. These results are, however, contradicted by a long-term 20 year follow-up study in which surgery did not result in superior outcome compared to conservative treatment [100]. Again, further research is warranted.

Rockwood type 6 injuries are very rare and only case reports are available. With a subcoracoid position of the clavicle, and possible neurovascular insult, only surgical treatment is feasible.

### **Conservative or surgical treatment?**

The debate regarding if ACJ dislocations should be treated surgically or conservatively has been ongoing for decades and mostly focused on Rockwood type 3 dislocations. However, older comparative studies also included Rockwood type 4 and 5 injuries as these were not distinguished from type 3 in the previous classification systems[30, 31, 54, 55]. Summarizing evidence is difficult as studies use different treatment protocols and outcome measures.

There are three prospective randomized trials comparing a total of 119 patients treated conservatively to 114 treated operatively [93, 102, 103]. The majority of the studied patients had Rockwood type 3 injuries but patients with type 4 and 5 were also included. Conservative treatment was similar between the studies with the use of a sling for 2-4 weeks and early start of physiotherapy. The surgical techniques differed in that the reduction of the joint was maintained by Kirschner wires and CC ligament suture [102], a CC transfixation screw [93], or a hook plate [103]. Follow-up was continued for up to two years and results were similar for all of the studies with faster recovery for the conservatively treated patients and minimal differences

between groups at final follow-up. The study using CC screws reported the largest discrepancies between groups at final follow-up with good or excellent results in 88% of the conservatively treated patients versus 77% for the surgically group. All of the reports had high complication rates of up to 50% for surgically treated patients, significantly higher than for conservative treatment.

In addition, there are many retrospective studies comparing different operative techniques to conservative treatment. Most of these show no difference in clinical results and recommend conservative treatment to avoid the risks associated with surgery [95, 97, 100, 104-108]. The majority of the patients in these studies have Rockwood type 3 injuries; however, in some reports higher grades are also included.

There is one current study recommending primary surgery for Rockwood type 3 dislocations. The conclusion is based on a retrospective analysis of 24 patients operated with a hook plate and 17 treated conservatively with a mean follow-up of 3 years. The surgically treated patients subjectively rated their outcome as slightly better and had a median Constant-Murley score that was 10 points higher compared to the conservative group [87, 109].

Two of the prospective randomized trials make separate observations on patients with severely displaced ACJ dislocations, corresponding to Rockwood type 5, and suggest that primary surgery could be beneficial for these patients. However, the subgroups consisted of a maximum of 12 subjects [93, 102].

In one retrospective analysis comparing surgical to conservative treatment the majority of the included patients had Rockwood type 5 injuries. 21 patients were treated conservatively and 20 surgically using a CC suspension device and arthroscopic technique. The surgically treated patients had better quality of life, shoulder related outcome measures, lower pain and showed less scapular dyskinesis compared to the conservative group [101].

To summarize, for Rockwood type 3 ACJ dislocations surgical treatment does not seem to improve outcome and conservative treatment in the acute setting is reasonable. For higher grade injuries the evidence is less clear and the risk of poor outcome with conservative treatment is likely higher, although more research is needed.

### **Early or delayed surgery?**

An argument often used by those favouring operative treatment of ACJ dislocations is that surgery in the acute setting gives superior outcome compared to delayed reconstruction. While seemingly logical that healing of the native ligaments would be preferable to late reconstruction, with the generally good outcome of conservative treatment solid evidence would be necessary in order to recommend early surgery.

There are a few studies investigating this topic. However, the conclusions that can be drawn are severely limited by the retrospective designs, differences in surgical techniques, definitions of what is considered an early repair, and inclusion criteria for the study subjects [110-114].

The reports that show superior outcome for acutely operated patients compare varying techniques for early surgery to the coracoacromial (CA) ligament transfer, also known as the Weaver-Dunn procedure, for late reconstruction [4, 110, 112, 113]. The Weaver-Dunn procedure has previously been widely used for treating chronic ACJ dislocations but is today considered inferior to other techniques. [75, 115-117].

A comparison of modern surgical techniques showed no difference in outcome between early and delayed treatment. Both groups were operated using arthroscopically assisted techniques. In the acutely treated patients two CC suspension devices were implanted to maintain reduction, and in the delayed treatment group a tendon graft was used to reconstruct the injured CC ligaments and a single CC suspension device was implanted for augmentation [114].

To summarize, there is not enough evidence to support the use of early surgical treatment for the majority of ACJ dislocations. However, some patients will have unacceptable symptoms after conservative treatment and identifying these in the acute setting to allow for early surgery would be beneficial.

## **Surgical techniques**

Since the first recorded surgery for an ACJ dislocation in 1861 more than 60 operative techniques have been described. While there is a myriad of studies on the subject there is not enough evidence for a single method to be considered superior [5-7, 75, 76].

### **Surgery for acute ACJ dislocations**

Surgery is defined as acute when the ruptured native ligaments still have the ability to heal. The time limit used for this distinction differs between studies from three to six weeks [110-114]. The aim of acute surgery is to reduce and secure the ACJ to approximate the torn AC and CC ligaments and allow them to heal. In addition to this the ligaments can be sutured. To date, all conceivable surgical implants and techniques have been used to achieve this goal. Below, the most common procedures are discussed.

### *The Bosworth screw*

In 1941 Bosworth introduced the technique of using a distally threaded screw inserted from a superior incision through the clavicle with purchase in the coracoid process, thereby reducing the ACJ [118]. He presented promising results in his own first cases, and the technique reached widespread use [119]. Today the method has fallen out of favour because of a high rate of complications and the availability of superior techniques [120-122].

### *Fixation with Kirschner wires*

Fixation with two threaded Kirschner wires introduced from the lateral acromion across the ACJ was introduced by Phemister in 1942 [123]. Implant removal is usually performed 2-3 months post-operatively. With different variations the technique has been in widespread use. The most common modifications are the addition of CC ligament repair, the use of smooth instead of threaded Kirschner wires, and addition of suture slings securing the coracoid process to the clavicle [102, 105, 124]. Complication rates are high with the most common problems being wire migration and redislocation [105, 125]. Severe complications are rare but there are case reports of catastrophic wire migration, for example into the spinal canal [126].

### *The hook plate*

The hook plate is secured to the superior of the lateral clavicle and uses a hook inferior to the acromion to keep the ACJ reduced. Because of common problems with pain and the risk of erosion of the acromion implant removal is necessary and usually performed 2-3 months post-operatively. Many studies show excellent results but the need for implant removal is a downside. The most common complication is redislocation which occurs in 10-35% of cases [87, 113, 125, 127].

### *CC suspension devices*

CC suspension devices consist of two endobuttons connected by a strong, non-absorbable suture. The buttons are placed between the inferior coracoid process and the superior clavicle, and as the suture is tightened the ACJ is reduced. This method is widely used today and often performed using arthroscopic technique for the possible benefit of less soft tissue dissection [125]. There are a plethora of studies evaluating this technique and many show promising results with good outcome and low complications rates. Some retrospective comparative reports suggest that CC suspension devices are preferable to Kirschner wires and Bosworth screws [122, 128-130].



## **Surgery for chronic ACJ dislocations**

In the chronic situation the native ligaments are no longer able to heal, and a reconstructive procedure is necessary. This procedure can be anatomic or non-anatomic, use tendon grafts, synthetic grafts or ligament transfers, and include different kinds of augmentations to protect the reconstruction during healing. There are countless reports on different surgical techniques available but very few with a high level of evidence [131]. Below two main concepts and techniques are described.

### *Non-anatomic reconstructions*

Arguably the most used reconstruction for ACJ dislocations is the CA ligament transfer. It was first described by Cadenat in 1917 and is today known as the Weaver-Dunn procedure after the authors of a report from 1972 [3, 4]. The technique involves a distal clavicle excision followed by a transfer of the CA ligament, with or without its bony insertion, from the acromion to the end of the clavicle. To protect the reconstruction during healing the technique is usually modified to include an augmentation, commonly a suture loop around the coracoid process, Kirschner wires across the ACJ or a hook plate [5-7, 125].

Biomechanical research has shown that the Weaver-Dunn construct is significantly weaker and less stiff compared to both the native ligaments and anatomical reconstructions using tendon grafts. It also allows more movement in the ACJ compared to other, anatomic, reconstruction techniques [132-136]. Clinical studies report good patient related outcomes after Weaver-Dunn procedures, although with a complication rate of around 20%. In comparative studies anatomic reconstructions using tendon grafts have shown superior outcome. [115, 117, 136, 137]. These reports have caused the Weaver-Dunn technique to fall out of favour

### *Anatomic reconstructions*

Encouraging results from biomechanical and clinical research have caused the popularity of anatomic reconstructions using tendon grafts to grow in the past two decades [5-7, 117, 132, 134, 136]. The definition of an anatomic reconstruction and the technique used varies between studies making the evidence heterogenous. There are reports using allograft or autograft, reconstructing only the CC ligaments, or the AC ligaments as well, through open surgery or an arthroscopically assisted technique, including different types of augmentation, and different ways to pass the graft. While most of the techniques can achieve good clinical results, some carry an unacceptably high risk of complications [138-143].

A procedure with promising clinical and biomechanical results that is currently widely used is the anatomic CC reconstruction (ACCR) [29, 81, 140, 144-146]. It is performed using a tendon autograft or allograft, usually from the semitendinosus or gracilis tendons. The graft is passed around the coracoid process and through drill

tunnels corresponding to the insertion sites of the native CC ligaments. The ACJ is then reduced, the graft tightened and secured using tenodesis screws in the clavicular bone tunnels. The remaining graft tail can be used to reconstruct the AC ligament. A strong non-absorbable suture is passed together with the graft to augment the repair [144, 145].

Studies have shown excellent patient related outcome measures (PROMs) after ACCR with near normal shoulder function [115, 140, 147, 148]. However, the complication rate is concerning and may be as high as 25%, although most of these adverse events are minor and do not necessitate reoperation or cause disability [131, 136, 140].

A possible problem with the ACCR is residual horizontal instability which may correlate with poor results. It has been suggested that a reconstruction of the AC ligaments in addition to the CC ligaments could improve outcome, but this is controversial and further research is needed [96, 149, 150].

## Measuring outcome

Measuring outcome is complicated as the tool needs to be both relevant to the patient, clinically applicable and consistent. Objective measures such as strength testing or radiographic changes can be used but do not always correlate with patient symptoms or satisfaction. Therefore, patient related outcome measures (PROMs) are increasingly popular.

### PROMs

PROMs are commonly used in orthopaedic research to evaluate shoulder function after injury or treatment. There are many to choose from, each with its pros and cons, and currently no gold standard exists. In studies on ACJ dislocations the most common is the Constant-Murley score. However, many others are also in use, making comparison between studies difficult [151]. Today, there are scores specifically designed to evaluate ACJ pathology, although, these are not available in Swedish and need further validation [152-154]. As the upper extremity can be considered to work as a unit it is questioned if joint specific PROMs are suitable as outcome measures [155].



# Aims

The overall aim of the thesis was to prospectively study different aspects of ACJ dislocations including epidemiology, diagnosis and treatment.

## Specific aims

- I. To describe the epidemiology of ACJ dislocations in a general population, including incidence, patient demographics, injury mechanisms, and distribution of classifications.
- II. To evaluate if weighted or internal rotation radiographs are useful in the classification of ACJ dislocations, specifically, if they uncover more high-grade dislocations than non-weighted radiographs.
- III. To study the patient related and radiographic outcome after Rockwood type 1 and 2 ACJ dislocations.
- IV. To evaluate the outcome and complications for patients with chronic Rockwood type 3-5 ACJ dislocations reconstructed using the AC-GraftRope device.
- V. To evaluate the knee related outcome and morbidity after gracilis tendon harvesting in patients with no previous knee complaints operated for chronic ACJ dislocation using an autologous gracilis graft.



# Patients and Methods

## The patient cohorts

The patients for this thesis were included at Helsingborg hospital that resides in the north-western part of Skåne, in the south of Sweden. The hospital has the only orthopaedic emergency department in the area and provided service to 280 251 inhabitants by the end of the study period (December 31<sup>st</sup>, 2016). To maximize recruitment all general practitioners and a majority of physiotherapists in the area were contacted and asked to refer patients matching the inclusion criteria to us. Papers I-III prospectively included patients with acute ACJ dislocations, the acute cohort. Papers IV and V included patients with chronic ACJ dislocations planned for surgical treatment, the surgical cohort.

### The acute cohort

Consecutive patients for papers I-III were prospectively included from January 2012 to December 2016. For details on the cohort, see the consort diagram (figure 6).

#### *Inclusion criteria*

- Patient age 18-75 years.
- Shoulder trauma with suspected ACJ dislocation within the last 2 weeks.
- Fractures excluded on standard radiographs.

#### *Inclusion process*

Patients meeting the inclusion criteria were referred to specially trained shoulder physiotherapists involved in the research group. The physiotherapist confirmed the suspicion of an ACJ dislocation and informed about the study. Patients willing to participate gave verbal and written consent. Data regarding demography and trauma mechanism were registered, the PROMs used for follow-up were provided, and patients were referred to perform study radiographs.

Subsequently, the patients were seen by one of 4 orthopaedic surgeons involved in the study; the main author reviewed the majority of cases. Using clinical examination and radiographs the ACJ dislocations were classified according to

Rockwood, and, if needed, the treatment initiated during the emergency visit was amended.

### *Exclusion criteria*

All patients completing the inclusion process were analysed in paper I (epidemiologic study). For papers II (radiographic study) and III (outcome after low-grade ACJ dislocations) patients with previous or ongoing shoulder problems, or other physical and psychiatric disorders, that could potentially affect classification or outcome were excluded. For paper II inclusion was halted in the end of October 2016, 2 months earlier than for the rest of the studies.

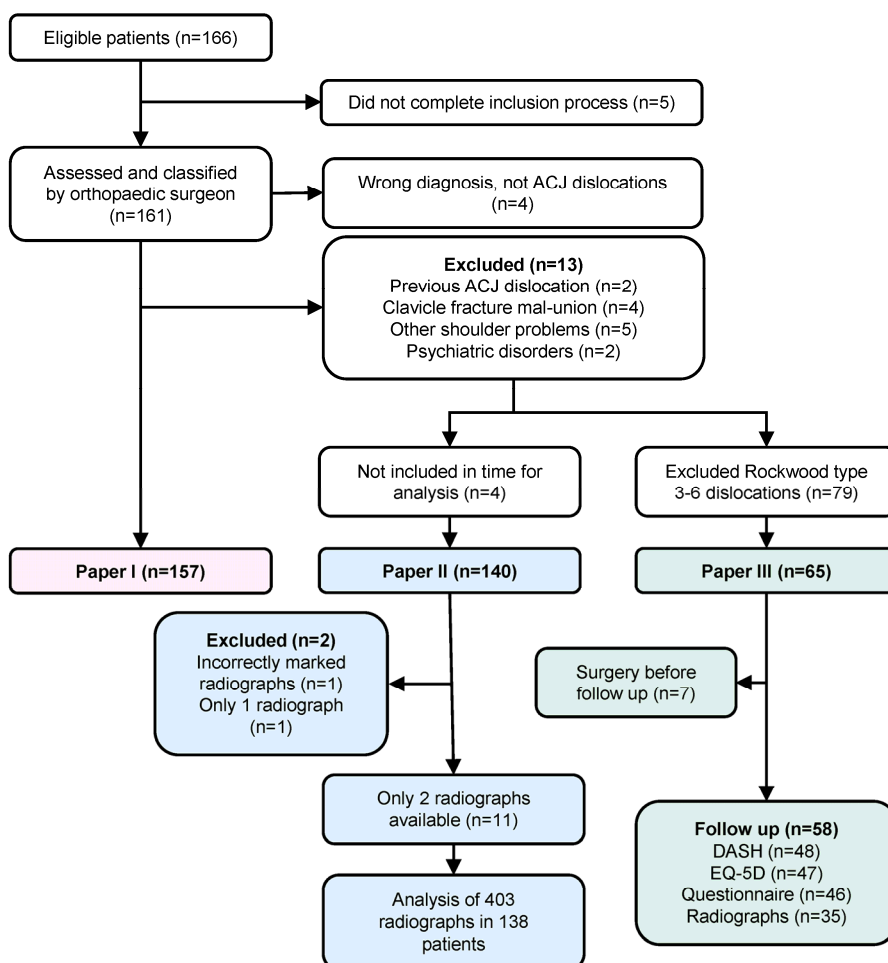


Figure 6. Consort diagram for papers I-III.

## The surgical cohort

The patients for papers IV (outcome after ACJ reconstruction) and V (outcome after gracilis tendon harvest) were consecutively included between March 2011 and December 2016. Paper V was designed in the end of 2011 and the first 5 patients were included retrospectively in this study; the rest of the cohort was prospectively included. For details on the cohort, see the consort diagram (figure 7).

### *Inclusion criteria*

- Patient age 18-75 years.
- Rockwood type 3-5 ACJ dislocation that was planned for reconstructive surgery using a gracilis tendon autograft after at least 6 months of conservative treatment had failed.

### *Inclusion process*

All patients with ACJ dislocations planned for surgery at our institution were matched to the inclusion criteria and eligible patients were asked to participate. The patients were thoroughly informed about the risks and benefits of operative treatment by one of four orthopaedic surgeons involved in the study and then referred to the shoulder physiotherapists. The physiotherapist completed the inclusion process and informed about follow-up procedures, obtained written consent and pre-operative PROMs.

### *Exclusion criteria*

Patients with psychiatric disorders or language barriers preventing them from understanding the study protocol or performing adequate physiotherapy were excluded. Paper IV investigated shoulder function after ACJ reconstruction and patients with previous or ongoing shoulder problems likely to affect outcome were excluded. Paper V evaluated lower limb function after gracilis tendon harvesting and patients with previous or ongoing knee, or lower limb problems that would potentially affect outcome were excluded.

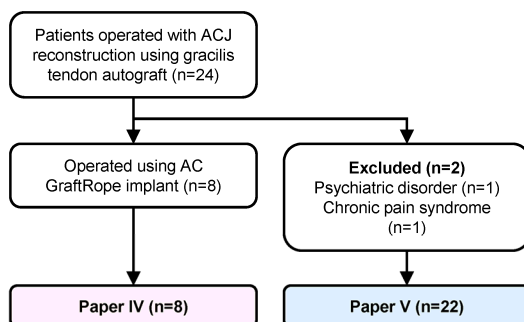


Figure 7. Consort diagram for papers IV-V.

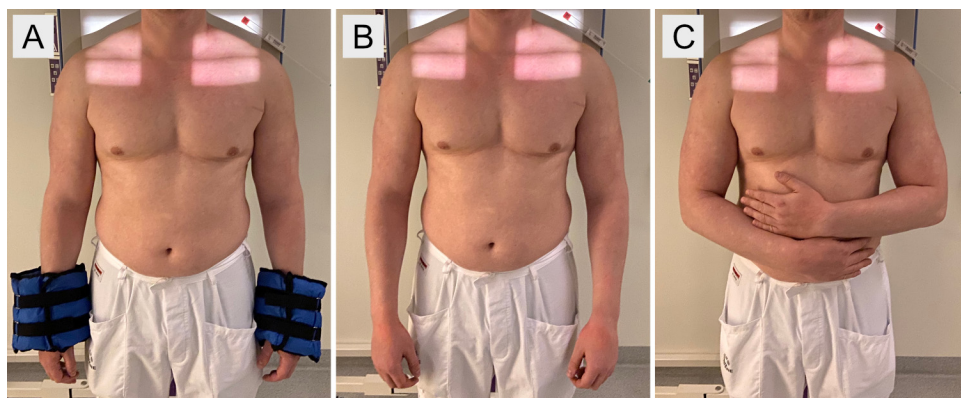


# Imaging techniques

## Study radiographs

The radiographic examinations used in the acute cohort were developed in cooperation with radiologists and radiographers at the Helsingborg hospital radiology department. A pilot study of 15 patients was performed to adjust the imaging technique and ascertain that it was reproducible and provided radiographs with similar projections of both shoulders allowing the CC interval to be compared between sides.

The study examinations were performed with the patient standing and supporting the upper back against a vertical surface. The patient did not move between exposures and was asked to relax the muscles in the upper body. Three panorama views including both CC intervals with a 10° cephalic tilt were taken. First a weighted radiograph with 5 kg weight bracelets attached to the patients' wrists, second a non-weighted radiograph with the arms along the sides, and third an internal-rotation radiograph where the patients' hands were placed on the abdomen (figure 8).



**Figure 8. Patient positions for the study radiographs.**

A. Weighted radiograph. B. Non-weighted radiograph. C. Internal rotation radiograph. The authors own photographs, with permission from the model.

## Measurements

The closest distance between the superior of the coracoid process and the inferior of the clavicle, the CC interval, was measured bilaterally on all images (figure 4). The increase of the CC interval on the injured side compared to the non-injured was calculated in percent. In papers I and III classifications were performed at inclusion by the orthopaedic surgeon using clinical examination and the non-weighted study radiographs.

In paper II a purely radiographic classification was used, and all images were classified separately by two independent radiologists to compare if weighted, or internal rotation radiographs uncovered more high-grade injuries than non-weighted radiographs. A less than 25% increase of the CC interval was classified as a low-grade injury, including both Rockwood type 1 and 2 dislocations as these cannot be accurately separated without a clinical examination. A 25-100% increase of the CC interval was classified as Rockwood type 3 and a more than 100% increase as type 5. In cases where the classification differed between radiographs the CC intervals were scrutinized to determine the cause of the change as it could depend on both an increase or decrease in either the injured or non-injured side.

As the aim of paper II was to evaluate if the studied radiographic techniques are useful in assessing the vertical instability of an ACJ dislocation no effort was made to radiographically diagnose horizontal instability.

All radiographs were assessed using the hospitals image viewing software (Sectra PACS, Sectra AB, Sweden) and measurements were made using the programs' digital ruler. Images were not calibrated for size.

### **Follow-up radiographs**

For paper III bilateral standard ACJ radiographs with a 10° cephalic tilt were performed 24 months after the injury. Standard radiographs were chosen as they were not intended for classification but used to diagnose radiographic changes potentially related to the trauma, for example osteoarthritis, osteolysis and heterotopic ossification.

### **Computed tomography (CT)**

Standard shoulder CT scans were performed 12 months post-operatively on the patients in paper IV to assess the position of the drill tunnels in the clavicle and coracoid process.

## **Surgical techniques**

All surgical procedures were performed by experienced consultant shoulder surgeons.

### **CC ligament reconstruction**

The patients in paper IV were operated using the AC-GraftRope device (Arthrex Inc. Naples, FL) and a gracilis tendon autograft. The device is used to incorporate a

tendon graft into a construct consisting of a clavicular washer and a coracoid flip button connected by a No.5 FiberWire non-absorbable suture. The suture and endobuttons act as a CC suspension device, augmenting the reconstruction while the tendon graft heals. For details regarding the surgical technique see the attached paper IV, below follows a summary of the key steps.

Under general anaesthesia, in a beach chair position a standard diagnostic arthroscopy was performed. Arthroscopic dissection was then carried out to identify and free the inferior surface of the coracoid process. A superior incision over the clavicle was made and a lateral clavicle excision performed. A drill guide was introduced through an anterior incision, and using arthroscopy its lower part was centralized under the base of the coracoid process and the top part on the superior clavicle, corresponding to the middle of the CC ligaments insertion. Using the drill guide, a guide pin was advanced through all 4 cortices of the clavicle and coracoid process, and over-drilled using a cannulated 6 mm drill. The GraftRope device, prepared with the gracilis autograft, was introduced through the bone tunnels until the clavicle washer was flush with the bone and the coracoid button flipped under the coracoid process. The FiberWire was tightened to hold the reduction and the tendon graft secured in the clavicle using a tenodesis screw. The deltotrapezoid fascia was repaired and the skin closed in layers.

### **Gracilis tendon harvest**

The gracilis tendon autograft was harvested immediately before the shoulder surgery. Under tourniquet an incision was made over the pes anserinus and the sartorius fascia was incised. The common insertion of the gracilis and semitendinosus tendons was located, and the gracilis was identified as the most anterior of the two. Adhesions were bluntly dissected, and the tendon was extracted using a standard tendon harvester. The wound was closed in layers.

### **Follow-up**

Follow-up radiographs of the shoulder were performed immediately post-operatively and after 6-8 weeks. Study follow-up for the shoulder surgery was planned at 3, 6, 12, and 24 months and included PROMs and clinical examination by the shoulder physiotherapists. A CT scan of the shoulder was performed 12 months post-operatively and radiographs to evaluate the repair planned at 24 months. However, because of a high rate of complications the trial was halted prematurely, and results are presented in paper IV. Follow-up of the knee was conducted using PROMs at 12 months and measurement of knee flexion strength at the end of the study period.

## Outcome measures

### PROMs

#### *Disabilities of the arm, shoulder, and hand (DASH)*

The DASH score consists of 30 items scaled 1-5 where 5 represents maximum disability. A total score ranging from 0-100 is calculated, higher score indicating more disability. The DASH score has good reliability, validity and responsiveness. The smallest difference in the score relevant to the patient, the minimal clinically important difference, is 10. The DASH score has not been specifically validated for use in patients with ACJ dislocations but is otherwise well studied [156, 157]. The DASH score is used in papers III and IV.

#### *The Constant-Murley score*

The Constant-Murley score is the most used outcome measure in research on ACJ dislocations. It is divided into 4 sections where the patient answers the first 2 regarding pain and activities of daily living. In the remaining 2 an examiner measures range of motion and strength. Pain is allotted 15 points and the worst pain during the day is used as reference. The activities of daily living section is assigned 20 points and includes subjective assessment of shoulder function, work and recreational activities, and sleep. For range of motion a maximum of 40 points is available. Both forward elevation, abduction, internal, and external rotation are evaluated. A final 25 points are allotted to strength which is measured using a dynamometer. The final score ranges from 0-100 where a higher score represents better shoulder function [109]. The Constant-Murley score was used in paper IV, functional assessment was performed by a shoulder physiotherapist and strength was measured at 90° of abduction in the scapular plane using an IsoForceControl® EVO2 dynamometer (MDS Medical Device Solutions AG, Oberburg, Switzerland).

#### *Knee injury and osteoarthritis outcome score (KOOS)*

The KOOS is an outcome measure with 42 items across 5 separately scored subscales; pain, other symptoms, function in daily living, function in sport and recreation, and knee related quality of life. Each subscale is reported separately. The function in daily living subscale is commonly more sensitive in older subjects and the sport and recreation in younger [158, 159]. The KOOS is used in paper V to evaluate subjective knee function after gracilis tendon harvest.

#### *The EuroQol-5 dimension (EQ-5D)*

The EQ-5D is a health-related quality of life outcome measure commonly used to evaluate patients with upper extremity conditions [160]. It assesses 5 dimensions of quality of life; mobility, self-care, usual activities, pain/discomfort, and

depression/anxiety. It also contains a global quality of life self-assessment VAS scale. In paper III the EQ-5D VAS scale is used to evaluate quality of life after low-grade ACJ dislocations.

### **Knee flexion strength**

In paper V knee flexion strength is measured bilaterally and the leg where the gracilis tendon has been harvested is compared to the non-operated leg. Measurements are performed isometrically in 60° and 90° of flexion using an IsoForceControl® EVO2 dynamometer (MDS Medical Device Solutions AG, Oberburg, Switzerland). Isometric and isokinetic hamstring strength has been shown to correlated and our measurements should therefore be comparable to other studies measuring isokinetic force [161].

## **Statistical methods**

Epidemiological calculations for paper I were made using population data from Statistics Sweden, the government body responsible for statistics on the Swedish society. Population at risk was defined as inhabitants between 18-75 years old living in the catchment area on the 31<sup>st</sup> of December each of the studied years 2012-2016. Incidence was calculated by dividing the total number of cases by the total number of person-years at risk. In paper I patient age was grouped into 3 groups, and Rockwood classification into low-grade injuries (types 1-2) and high-grade injuries (types 3-6). Adjusted logistic regression was used to calculate the odds ratio (OR) for high-grade injury depending on age group, gender and type of trauma. Poisson regression was used to calculate incidence rate ratios between genders and age groups.

The Wilcoxon signed rank test was used to compare radiographic classification between radiographs in paper II, and KOOS scores between baseline and follow-up in paper V. In paper II a mixed models linear regression was used to compare the measurements of the CC intervals on the injured side between radiographs.

In paper III the Mann-Whitney U test was used to compare DASH and EQ-5D VAS between subgroups and cross tabulations with chi-square tests were used to compare binary variables. Bootstrap technique was used to calculate confidence intervals (CIs) around median values.

For all papers normally distributed variables were presented as means and non-normally distributed as medians. 95% CIs were used and  $p < 0.05$  was considered statistically significant. In papers I, II, and V SAS 9.4 (SAS Institute Inc., Cary, NC, USA) was used for statistical calculations. In paper III SPSS Statistics for Macintosh

version 26 (IBM Corp, Armonk, NY) was used, and in paper IV Microsoft Excel (Microsoft, Redmond, WA).

## Ethical considerations

The studies reported in papers I-V were approved by the Regional Ethical Review Board in Lund after input from the regional committee for radiation safety (Dnr 2012/454, 2016/491, 2016/962.)

All of the patients included in the prospective cohort were subjected to an additional 3 radiographs compared to patients not participating in the study. This corresponds approximately to one day's background radiation. The patients were thoroughly informed.

The patients included in paper IV were operated using a new method with only a case series of 10 patients with no reported complications available in the literature beforehand. To evaluate the safety of this method we designed our prospective study. The cohort was closely followed, and the trial was halted prematurely when we noted a high rate of complications.



# Results in summary

## Paper I

The aim of paper I was to describe the epidemiology of ACJ dislocations in a general population. 157 patients with ACJ dislocations were included, the mean age was 39 years (range 18-74) and 139 (89%) were male. The men were slightly younger than the women with a mean age of 35 years (range 18-74) compared to 45 years (range 27-64), respectively. The overall incidence was 2.0 (95% CI 1.7-2.4) per 10 000 person-years, decreasing with higher age group-wise (table 2).

ACJ dislocations were more common in younger patients and in males, but interestingly we found an increased risk for high-grade injuries (Rockwood type 3-6) in the older age groups compared to the younger. Injury during sports was the most common trauma mechanism, but the risk for high-grade dislocation was greatest when injured in traffic, and in this group bicycle accidents were particularly common. See table 3 for a summary of trauma mechanisms.

**Table 2. The incidence of ACJ dislocations per grade, gender and age group.**

Variable	Subgroup	Subgroup	Cases (N)	Person-years at risk (10 <sup>3</sup> )	Incidence (CI)
Total			157	781	2.0 (1.7 – 2.4)
Injury type	Low grade		72	781	0.92 (0.73 – 1.2)
	High grade		85	781	1.1 (0.88 – 1.3)
Gender	Female		18	390	0.46 (0.29 – 0.73)
	Male		139	391	3.6 (3.0 – 4.2)
Age group	18-39		82	290	2.8 (2.3 – 3.5)
	40-59		61	288	2.1 (1.6 – 2.7)
	60-75		14	203	0.69 (0.41 – 1.2)
Gender and age group	Female	18-39	5	142	0.35 (0.15 – 0.84)
		40-59	10	144	0.70 (0.38 – 1.3)
		60-75	3	103	0.29 (0.09 – 0.90)
	Male	18-39	77	147	5.2 (4.2 – 6.5)
		40-59	51	144	3.5 (2.7 – 4.7)
		60-75	11	100	1.1 (0.61 – 2.0)



**Table 3. Trauma mechanisms, subgroups and the distribution of low/high-grade injuries.**

Low-grade injuries are defined as Rockwood type 1-2 and high-grade as Rockwood type 3-6.

Type of trauma	Activities	Total (%)	Low-grade ACJ dislocation (%)	High-grade ACJ dislocation (%)
	Total	157	72 (46)	85 (54)
	Soccer	19 (12)	11 (15)	8 (9)
	Martial arts	11 (7)	8 (11)	3 (4)
	Skiing	9 (6)	3 (4)	6 (7)
	Bicycle sport	8 (5)	4 (6)	4 (5)
	Ice hockey	6 (4)	4 (6)	2 (2)
	Floorball	4 (3)	2 (3)	2 (2)
	Horseback riding	5 (3)	1 (1)	4 (5)
	Rugby/American football	3 (2)	1 (1)	2 (2)
	Parkour	1 (1)	1 (1)	0
	Bicycle Transport	29 (19)	5 (7)	24 (28)
	Motorcycle/moped	16 (10)	5 (7)	11 (13)
	Car	4 (3)	2 (3)	2 (2)
	Other traffic accident	5 (3)	3 (4)	2 (2)
	Falls	32 (20)	18 (25)	14 (17)
	Miscellaneous	5 (3)	4 (6)	1 (1)
Type of trauma subgroups	Sports	66 (42)	35 (49)	31 (37)
	Traffic accidents	54 (34)	15 (21)	39 (46)
	Falls	32 (20)	18 (25)	14 (17)
	Miscellaneous	5 (3)	4 (6)	1 (1)

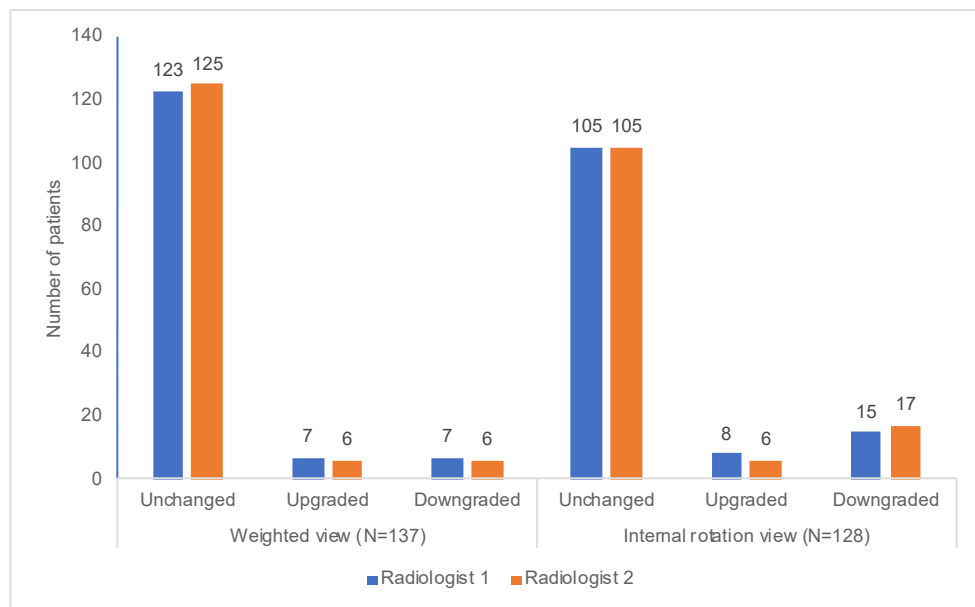
## Paper II

The purpose of paper II was to evaluate if weighted or internal rotation radiographs uncovered more high-grade dislocations compared to non-weighted radiographs. Two independent, experienced musculoskeletal radiologists measured the CC interval bilaterally on all radiographs and the measurements were converted to Rockwood classifications.

In the majority of cases the classification remained the same between radiographs (figure 9). For the weighted radiographs compared to the non-weighted there were as many upgrades as downgrades. For the internal rotation radiographs there were slightly more downgrades than upgrades. When analysing the cases that changed classification between radiographs different reasons for a change were found. The CC interval both increased and decreased in the injured and non-injured shoulder in

weighted and internal rotation radiographs and no pattern of how the type of radiograph affected the measurements could be identified.

The actual measurements of the CC intervals on the injured side were also compared between radiographs. Relative to the non-weighted views we found that the CC interval increased 0.5 mm (95% CI 0.37-0.65) in the weighted views, and 0.2 mm (95% CI 0.04-0.33) in the internal rotation view.



**Figure 9. Distribution of changes of classification by radiographic view and radiologist.**

The non-weighted radiographs are used as baseline to which the weighted and internal rotation radiographs are compared.

## Paper III

The aim of paper III was to evaluate outcome at 2 years in patients with Rockwood type 1 and 2 ACJ dislocations. 65 patients met the inclusion criteria, the mean age was 36 years (range 18-73), and there were 57 males and 8 females. Because of persistent pain 7 patients, 4 men and 3 women with a mean age of 37 years (range 26-48), underwent surgery with an open lateral clavicle excision before final follow-up.

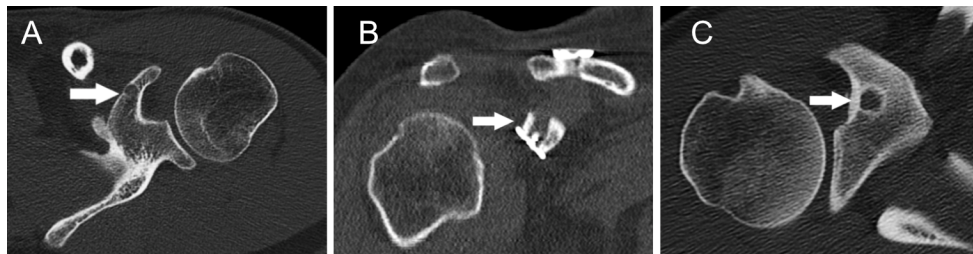
Median DASH and EQ-5D VAS scores at follow-up were 1 (95% CI 0-4) and 88 (95% CI 85-90) respectively. On the question “are you satisfied with your shoulder as it is today?” 18 out of 46 responders answered “no” and for this group Mann-Whitney U tests showed significantly worse median PROMs (DASH 13 (95% CI 5-

27), EQ-5D VAS 83 (95% CI 80-85)) compared to patients who were satisfied with their shoulder (DASH 0 (95% CI not applicable), EQ-5D VAS 90 (95% CI 90-95)). There were no significant differences in PROMs when comparing patients grouped for Rockwood type, or for the presence of radiological findings. Further, there were no associations between satisfaction with the shoulder and Rockwood type or radiological findings.

## Paper IV

The purpose of paper IV was to conduct a case series of 30 patients with follow-up at 3, 6, 12, and 24 months to evaluate the results and safety of the new surgical method AC-GraftRope (Arthrex Inc. Naples, FL). However, because of a high rate of complications the trial was halted prematurely.

After 8 patients had been operated 4 had suffered a loss of reduction. The reasons were coracoid fractures in 3 cases, and a failure of the device in one case. All complications were non-traumatic and occurred within 6 weeks of the surgery. The patients had cooperated with the prescribed post-operative immobilisation and rehabilitation. CT scans revealed that the 6 mm drill tunnel in the coracoid process was non-central in 6 out of 8 cases, possibly leading to an increased fracture risk (figure 10).



**Figure 10. CT scans showing drill tunnels in the coracoid process in three patients.**

A. Medially, and distally placed drill tunnel on transversal view. B. Laterally placed tunnel on coronary view. C. Laterally placed tunnel on transversal view.

Due to the results of paper IV we changed the surgical method for reconstruction of chronic ACJ dislocations. Today we use the ACCR and this technique is described above under the “Surgery for chronic ACJ dislocations” section. We have continued to follow patients according to the protocol designed for paper IV and between 2012-2017 16 patients have been evaluated after ACCR for 2 years post-operatively. In this group we observed 3 partial losses of reduction without trauma and with moderate symptoms that did not require revision surgery. Further, after a minor trauma 6 weeks post-operatively there was one complete loss of reduction with return of preoperative pain and impaired function. Conservative treatment was

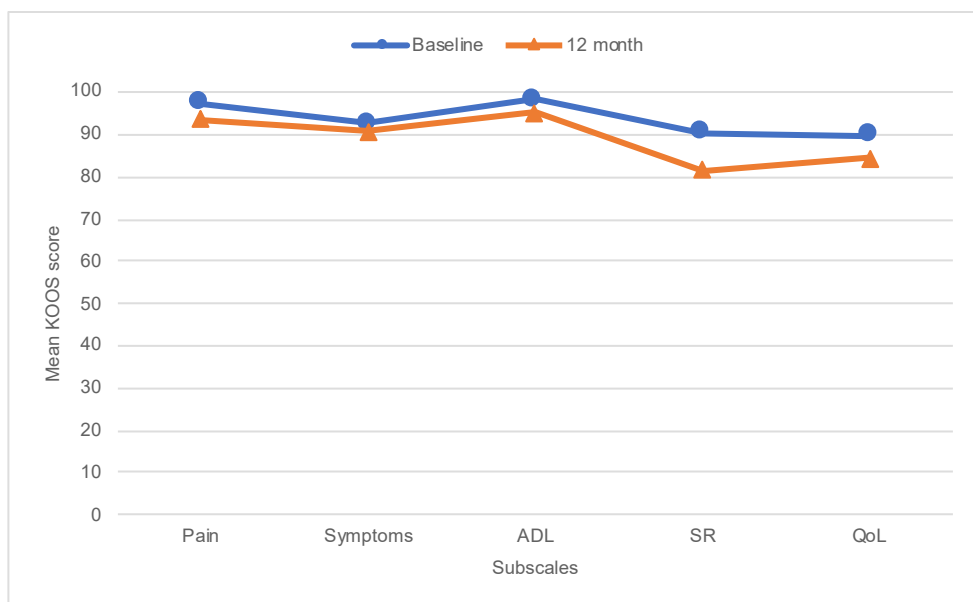
attempted but failed. Subsequently, this patient moved and was lost to follow-up. A further 3 cases of asymptomatic partial losses of reduction were noted on follow-up radiographs within 6 months post-operatively. Constant-Murely and DASH scores for the entire group operated with ACCR improved over time and were excellent at 24 months (table 4). A manuscript reporting these results has not been prepared because of the small number of patients included and the presence of other publications on the topic [139, 140].

**Table 4. Patient related outcome measures for the 16 patients operated with ACCR.**  
IQR, inter-quartile range.

	Pre-operatively	3 months	6 months	12 months	24 months
Cosnstant-Murley					
Responders (n)	16	16	15	16	13
Median score (IQR)	63 (52-73)	65 (56-82)	89 (76-90)	87 (77-92)	93 (84-95)
DASH					
Responders (n)	15	16	15	16	13
Median score (IQR)	31 (23-39)	27 (14-40)	11 (7-18)	10 (5-23)	5 (3-17)

## Paper V

The aim of paper V was to evaluate morbidity and patient related outcome after gracilis tendon harvest in patients with no previous knee problems. Analysis included 22 patients, 18 were male and 4 female and the mean age was 44 years (range 22-62). Pre-operative KOOS scores were available for 17 of the patients and for the remaining 5 age and gender matched normative values were used as baseline. There were no significant differences in any of the KOOS subscales at 12 months compared to baseline values (figure 11).



**Figure 11. Baseline and 12 month KOOS profile curves.**

Activities of daily living, ADL. Sports and recreation, SR. Quality of life, QoL.

Isometric hamstring strength was tested in all patients at a mean of 26.5 months (range 14-56) post-operatively. The operated leg was significantly weaker than the non-operated and performed 93% and 83% of the force at 60° and 90°, respectively. No severe post-operative complications were noted.

# General discussion

The research questions for this thesis were designed to address clinically relevant topics where previous data was inadequate or lacking. Patients for papers I-III were prospectively recruited from a general population allowing conclusions that are broadly applicable and not restricted to selected groups, such as specific athletes. In paper I we describe the risk factors and incidence of ACJ dislocations, and traits associated with high-grade injuries. Together with reports published during the time that our studies were conducted there is now much better knowledge of the epidemiology of ACJ dislocations. In paper II a long standing controversy regarding the efficacy of weighted radiographs is investigated and we find that such images are not helpful in the classification of ACJ dislocations and advice against their use. In paper III we show that close to one third of patients with Rockwood type 1 and 2 ACJ dislocations are not satisfied with their shoulders indicating that implications of these injuries are often underestimated.

Papers IV and V included patients that were planned for surgical reconstruction of chronic ACJ dislocations. In paper IV a new surgical technique was evaluated, and we found a high complication rate. During the follow-up of our patients other authors published similar results [162, 163]. The outcome after gracilis tendon autograft harvest was reported in paper V. The certainty of our conclusion is limited by the small sample size of only 22 patients, but our results indicate that the use of gracilis tendon autografts is well tolerated.

## Epidemiology

The incidence of ACJ dislocations in paper I was 2.0 (95% CI 1.7-2.4) per 10,000 person-years for the entire cohort, decreasing with higher age (table 2). Incidences have been reported previously both in studies specifically investigating ACJ dislocations and more population based studies on shoulder injuries in general [61, 62, 73, 74]. Two studies on the same cohort reported the highest incidence in the literature, 4.5 per 10,000 person-years, more than twice compared to our study. The patients of this cohort were classified retrospectively based on radiographs and medical records, hence, classification criteria differed from ours. Regardless, the biggest difference in incidence was seen in low-grade injuries. A possible explanation is that patients in our area might have been less likely to seek care at

our department, or at all, when suffering a low-grade dislocation. Indeed, the referenced authors state that 83-86% of their population used their department in case of upper extremity injury [62, 74]. No such estimates are available for our population. Two other studies report incidences for ACJ dislocations of 0.8 and 1.8 per 10,000 person-years respectively [61, 73]. The study reporting the lowest incidence was performed in 1987 in Malmö, Sweden, an area close to where this thesis was conducted. The reason for the low incidence is difficult to determine but might be due to a definition of ACJ dislocation that relied on radiographically visible separations, thus excluding Rockwood type 1 and many type 2 injuries [73].

The typical patient with an ACJ dislocation has previously been reported as a young man injured during sports, which was confirmed in our study with men representing 89% of the patients and with 42% of the injuries occurring during sports [61, 62]. We are, however, the first to report odds ratios for Rockwood type 3-6 dislocations comparing age groups and trauma mechanisms. Our results show an increased risk for high-grade injuries with older age and when injured in traffic.

A particularly risky activity seems to be bicycling, causing 24% of all ACJ dislocations and 33% of all high-grade injuries. More than three fourths of bicycle injuries were Rockwood type 3-6. It has been previously shown that bicycling is a common trauma mechanism but the frequency of high-grade injuries has not been reported before [61, 62].

## Weighted and internal rotation radiographs

Weighted radiographs have been widely recommended historically, and, while decreasing in popularity, are still in use today [30, 31, 39, 40, 96, 164, 165]. Despite their common use, evidence regarding their efficacy is scarce with only two retrospective studies presenting contradictory conclusions [37, 38]. In the study by Bossart et al. 83 pairs of weighted and non-weighted bilateral radiographs were studied to investigate if weighted views uncovered Rockwood type 3 dislocations not diagnosed in non-weighted radiographs. Similar to our results, they found that weights affected the CC interval in both the injured and non-injured shoulder causing both upgrades and downgrades, and recommend that stress views should be abandoned. Unfortunately, patients with Rockwood type 4 and 5 injuries were excluded from the analysis limiting the conclusion [38]. In paper II we show that similar observations can be made when all Rockwood types are included.

In a study of 59 pairs of weighted and non-weighted bilateral radiographs Ibrahim et al. conclude that weighted radiographs are important to correctly diagnose Rockwood type 5 injuries as they found 10 cases of upgrades from type 3 to type 5 and no downgrades at all. This is in stark contrast to our results where we found as many

upgrades as downgrades. We have no explanation for this difference as our method of analysing the radiographs was similar to that reported by Ibrahim et al [37].

Internal rotation radiographs have been suggested as an alternative to weighted views based on the results of a laboratory study of 3 cadaveric shoulders [41]. In paper II we found no evidence to support this recommendation, on the contrary, internal rotation views caused more downgrades than upgrades compared to non-weighted views. It is possible that more exaggerated internal rotation with the patients' hands placed on the back could have given a different result, but this position is often very painful after an acute ACJ dislocation and compliance would likely be a problem.

Another way of using the radiographs is to compare the measurements of the injured CC intervals in the weighted and internal rotation views to the non-weighted views. Identification of injuries that are more vertically unstable than visible on non-weighted radiographs would thus be possible. We found a mean CC interval increase of 0.5 mm in the weighted views and 0.2 mm in the internal rotation views compared to the non-weighted radiographs. While these differences were statistically significant, they were clinically irrelevant.

In 2 American shoulder and elbow surgeons surveys the reported use of weighted radiographs is declining. In 1999 43% out of 105 responders used weighted views, however, out of these only 49% stated that the weighted views would change their initial treatment choice [39]. In a similar study from 2018 only 14% out of 37 responders preferred weighted views, although 73% reported that weighted views were obtained at their institution, ordered by other providers [40]. With the conclusions from paper II we provide evidence to support this decline in the popularity of weighted radiographs.

## Outcome after Rockwood type 1 and 2 ACJ dislocations

In Rockwood type 1 and 2 injuries the ACJ is not properly dislocated and treatment is always conservative in the acute phase. These injuries are therefore easily misconceived as benign when most studies on the subject, in fact, present a considerable frequency of sequela [78-80, 83, 84]. However, the majority of these reports suffer from suspected sampling bias or consist of small, retrospective case series, and more high-quality evidence is warranted. In our study we confirm previous observations and show that one third of the patients with low-grade ACJ dislocations are unsatisfied with their shoulder 2 years after the injury.

In two previous studies on samples of navy servicemen residual symptoms were reported in 36-39% of patients with Rockwood type 1 injuries and 48-65% of patients with type 2 injuries. These are the highest frequencies of sequela in the



literature and the only reports where differences between Rockwood types have been noted [83, 84].

We found no difference in PROMs based on the presence of radiographic findings and no association between radiographic findings and satisfaction with the shoulder, results that are in line with previous publications [82-84]. However, in all reports on the subject, the radiographic findings were pooled into a binary variable and not separately evaluated. It is possible that certain radiographic changes are associated with symptoms while the majority is not, and further research would be needed to answer this.

In paper II 7 out of 65 patients underwent surgery because of pain and impaired shoulder function before final follow-up. A lateral clavicle excision was performed in all cases. This was considered an endpoint and the patients were not followed further. The need for surgery has only been reported in one previous study where 9 out of 33 patients were operated, the high frequency of surgical treatment in this report compared to our study is possibly explained by the inclusion of younger patients and more athletes [78].

## Surgical treatment of chronic ACJ dislocations

The treatment of chronic ACJ dislocations is challenging which is reflected by the abundance of operative procedures available [5-7, 131]. When paper IV was designed we were searching for a better surgical technique at our institution as we were not satisfied the Weaver-Dunn procedure despite modifications with different augmentations. The AC-GraftRope (Arthrex Inc. Naples, FL) technique was described in a case series of 10 patients with no complications and excellent outcome [166]. After practicing with the device in a laboratory setting on cadaveric shoulders our prospective case series was planned. The trial was halted prematurely after reduction was lost in 4 out of 8 patients.

Three out of 4 losses of reduction were caused by fractures through the bone tunnels in the coracoid process and CT scans of all patients revealed that the drill tunnels were non-central in 6 out of 8 patients. Research published after our trial had been halted helps to explain the mechanisms behind our failures [167-169]. As the required drill diameter is 6 mm and the average coracoid width is 15 mm a central tunnel placement is critical to avoid an increased fracture risk [168, 170]. Studies on CT models show that separate drilling of the clavicle and coracoid process is necessary to achieve an approximately anatomic position of the drill tunnels and allow the graft to pass near the path of the native CC ligaments. When using a drill guide in arthroscopically assisted surgery only straight trajectory drilling through all four cortices of the clavicle and the coracoid process is possible, making anatomic tunnel placement impossible [167, 169].

Paper IV is not the only clinical trial to report adverse events with the AC-GraftRope device. Two studies reports loss of reduction in 8 out of 10 patients respectively, both due to coracoid fractures and other modes of failure [162, 163]. In an evaluation of a surgical technique where 4.5 mm bone tunnels are used 6 out of 63 patients suffered fractures of the coracoid process [171]. The TightRope (Arthrex Inc. Naples, FL) is another device used to treat acute ACJ dislocations without incorporating a tendon graft. In this technique 4 mm bone tunnels are used and coracoid fractures have been reported but are uncommon [122, 172]. This possibly indicates that bone tunnels with a diameter greater than 4 mm constitute a fracture risk.

After ceasing to use the AC-GraftRope device we adopted the ACCR technique. The amount of mechanical failures was still high with losses of reduction in 7 out of 16 patients. However, only 1 patient suffered a complete loss of reduction with severe symptoms, a further 3 were partial losses of reduction with mild symptoms and 3 were completely asymptomatic only diagnosed on follow-up radiographs. The consequences of these mechanical failures thus seem less serious compared to the patients who suffered failures after AC-GraftRope surgery. The PROMs for the ACCR group improved over time and were excellent 2 years post-operatively. These findings with high complication rates but good outcomes are supported by other reports [131, 139, 140, 173].

## Outcome after gracilis tendon harvest

In paper V the outcome after gracilis tendon harvest from patients with no previous knee complaints was investigated. In a previous retrospective study 22 patients were evaluated. The authors concluded that 95% of the patients were satisfied with the result, but knee flexion strength was decreased. The strength of the conclusion is limited by a loss to follow-up of almost 50%, but similar to our results [174]. Recently, a study very similar to paper V was published. In this report 12 patients who had undergone ACJ reconstruction using gracilis tendon autografts were retrospectively evaluated to assess the effects of tendon harvest from a healthy knee. Similar to paper V excellent PROMs were reported, but unlike our results there was no decrease in knee flexion strength [175]. Paper V and the two studies referenced above are unique in that they evaluate the effects of gracilis tendon harvest from a knee with no pre-existing morbidity and where no further surgery is planned. The common conclusion is that subjective knee function is not affected by the procedure, while the results regarding knee flexion strength differ. Since autografts are commonly used in reconstructive surgery the results of these reports are of interest to the entire orthopaedic community.

In paper V KOOS was analysed 12 months post-operatively and no significant differences from baseline scores were identified for any of the subscales. There are 2 studies evaluating patients after anterior cruciate ligament reconstructions where

the gracilis and semitendinosus tendons were harvested from the contralateral leg. In one of these subjective symptoms had resolved within 3 months post-operatively and in the other improvement was seen up to, but not after, 12 months [176, 177]. Together with our results this indicates that recovery after gracilis tendon harvest is complete within one year post-operatively.

However, in paper V the post-operative KOOS values were slightly lower for all the subscales compared to baseline. This was most visible in the sports and recreation subscale, indicated by a bump in the KOOS profile curves (figure 11). With a larger sample size it is possible that these differences would have been significant and for certain patients graft harvest might be less well tolerated.

## Limitations

This thesis has several limitations and for details the reader is referred to the attached papers.

In the acute cohort that formed the patient sample for papers I-III we have several indications that inclusion was incomplete, likely due to some patients not being referred to our institution and others not seeking care at all. In a Norwegian population based study the incidence of low-grade injuries was 3 times higher than ours while the incidence of high-grade injuries was similar [74]. It is unlikely that this is due to an actual difference in injury pattern and we probably have a skewed inclusion with relatively few low-grade injuries. We have also included conspicuously few patients from the elite football and ice-hockey teams in the area and the teams own medical staff have perhaps handled some injuries without referral to us. For this reason, the incidence presented in paper I should be considered a minimal estimate with the true incidence likely being higher, especially for Rockwood type 1 and 2 dislocations. Potentially, this also affects the conclusions of paper III as the patients that did not seek care could have less symptoms, and thus the analysis of the included patients might overestimate sequela after low-grade ACJ dislocations. The clinical relevance of this may, however, be questioned, as the results of paper III should be used to improve counselling and the conclusions should be considered applicable only to the patients that do seek care following ACJ injury.

Our inclusion criteria also limited the cohorts to patients aged 18-75 years and it is possible that certain injuries were thereby missed. However, ACJ dislocations are pathoanatomically different in the skeletally immature where the periosteal tube is ruptured instead of the ligaments and it is therefore reasonable to have 18 years as the lower age limit despite the risk of missing some older adolescents with adult type injuries [178]. ACJ dislocations are also virtually non-existent in patients older than 75 years [61, 74].

Horizontal instability after dislocation of the ACJ has been shown to affect outcome but there is controversy regarding the optimal method to diagnose such instability [35, 42-44, 49, 56, 96]. At our institution standard radiographs to assess suspected ACJ dislocations do not include images to evaluate horizontal instability, and as no study on the topic was planned for the thesis, we chose not to include such radiographs. Horizontal instability was clinically evaluated by the orthopaedic surgeon at patient inclusion.

In papers III-V PROMs were used to evaluate the patients at follow-up. While common in orthopaedic literature their use has both pros and cons. When the work on this thesis was started there were no ACJ specific outcome measures available and we were referred to using other tools. The Constant-Murley score was chosen as it is the most commonly reported outcome measure in studies on ACJ dislocations. The DASH score was used because it is a well-studied general upper extremity score. For assessing patients after gracilis tendon harvest in paper V the KOOS was chosen as it is thoroughly evaluated and widely used. Despite motivated choices, none of the scores were validated for our specific conditions and it is therefore possible that they were not sensitive enough accurately measure relevant outcome.

In paper III we had methodological limitations. Firstly, we failed to obtain pre-injury PROMs which could have been easily done at inclusion by asking the patients to answer the questions as if not yet injured. This would have provided a baseline to which follow-up values could be compared. Secondly, surgery was considered an endpoint and the 7 patients operated were not further evaluated. It is possible that an intention to treat follow-up protocol would have been more suitable. The 7 patients had severe symptoms and as they were excluded evaluation of the remaining patients likely underestimates sequela after low-grade ACJ dislocations. If the operated patients had been included in the final follow-up the uncertainty of how these patients would affect the overall results could have been controlled for.

In paper V there are methodological limitations as this paper was designed a few months after we had started the surgical study for paper IV. Therefore, the first 5 patients were included retrospectively, and preoperative PROMs were not available. An option would have been to exclude these patients but as ACJ reconstructions are quite rare that would have resulted in a relatively large loss of information.



# Conclusions

- The incidence of ACJ dislocations is 2.0 per 10,000 person-years in a general population, decreasing with higher age. Male gender and sports are risk factors for injury, while old age and traffic accidents are risk factors for high-grade dislocations.
- Weighted and internal rotation radiographs are not useful in the classification of ACJ dislocations and we advise against their use.
- Almost one third of patients with Rockwood type 1 and 2 ACJ dislocations are unsatisfied with their shoulder 2 years after the injury.
- We advise against using the AC-GraftRope device with 6 mm bone tunnels in the coracoid process because of the high risk of fracture.
- Gracilis tendon harvest results in a decrease in knee flexion strength but not in KOOS and this procedure is likely well tolerated.



# Future perspectives

In certain aspects research on ACJ dislocations is challenging and many questions remain unanswered. To enable future high-quality studies some new key evidence is needed. To allow better evaluation of treatment methods, further development of ACJ specific outcome measures is warranted. Today there are ACJ specific PROMs but these need to be translated to various languages and more thoroughly validated. It is also necessary to continue the development of radiographic techniques, specifically to evaluate horizontal instability of the ACJ as this seems to affect outcome. There are publications describing simple and reproducible methods, but validation studies are needed.

When improved diagnostics and outcome measures are in place the possibility of conducting quality treatment studies will be much improved. Since surgical treatment is relatively rare prospective multi-centre trials will be necessary to further develop and evaluate reconstructive techniques and, in the end, maybe find a method that can be considered a gold standard. Improved diagnostics and outcome measures will also help conduct important longitudinal research on large patient groups with the aim of identifying factors associated with poor outcome, thus maybe enabling us to identify patients in need of surgery earlier.

Another aspect that could be further researched are the methods for conservative treatment. Today, evidence is very limited and developing better physiotherapy regimes may be beneficial. An interesting study would be to randomize patients between a best practice ACJ specific physiotherapy program and routine treatment where patients are advised to find a physiotherapist on their own. The results could be used to improve the treatment of the majority of patients with ACJ dislocations.





# Acknowledgements

I want to express my sincere gratitude to all who have supported me and made this thesis possible. Special thanks to the following.

**Karl Lunsjö**, my supervisor, for introducing me to the world of clinical research, for innumerable emails, texts, interesting talks and invaluable support. You are an inspiration and have a truly unique ability to see the big picture and turn adversity into possibility. From my first job interview, conducted in an operating theatre during the Christmas holiday of 2010, to enjoying international scientific congresses, working with you has been a pleasure.

**Ola Olsson**, my co-supervisor, for invaluable advice on sound scientific reasoning and counselling in concise and clear academic writing. A wiser person is hard to find.

**Richard Frobell**, my co-supervisor during the beginning of the thesis. Thank you for helping with study design and sharing your experience of knee related research.

**Knut Aagaard**, colleague, co-author and fellow researcher. Many thanks for excellent advice and for sharing your great knowledge of shoulder surgery.

**Anna Lönnberg, Frida Jönsson** and previous colleagues at the physiotherapy department at Helsingborg hospital. Thank you for your competent and hard work with including and following the research patients.

**Anders Hauggaard, Karin Wattsgård** and **Torsten Boegård**, Radiology department at Helsingborg hospital. Thank you for valuable advice regarding all radiographic matters and for your help with co-authoring, designing and performing measurements for paper 2.

**Felicia Mogioanos**, for your hard and excellent work with paper 2 during your time as a medical student at Helsingborg hospital.

**Tommy Schyman**, for valuable advice on statistics.

**Marie, Helena**, and other involved radiographers at the Radiology department, Helsingborg hospital. Thank you for your competent opinions regarding the imaging procedure and for performing all the radiographic examinations.

**Christel, Malin** and **Towe**, for helping me keep track of the study patients and their follow-up.

**Lena and Magnus**, my parents, and **Sofia**, my sister, for all your love and support.

**Louise**, the love of my life, for always supporting me and for helping me with illustrations. Without you this thesis would not have been possible.

**Alfred and Moa**, my children, I love you!

**To all of my colleagues** at the Department of Orthopaedics, Helsingborg hospital, the best co-workers one could wish for. Thank you for all the laughs, support, discussions and good times. The solutions to both complex orthopaedic cases, world conflicts, climate change and relationship issues can be found in our lunch room.

# References

- [1] Adams F. The Genuine Works of Hippocrates. New York: William Wood; 1886.
- [2] Rutkow IM. The History of Surgery in the United States 1775-1900. San Fransisco: Norman Publishing; 1992.
- [3] Cadenat FM. The treatment of dislocations and fractures of the outer end of the clavicle. *Int Clin.* 1917;1:145-69.
- [4] Weaver JK, Dunn HK. Treatment of acromioclavicular injuries, especially complete acromioclavicular separation. *J Bone Joint Surg Am.* 1972;54:1187-94.
- [5] Johansen JA, Grutter PW, McFarland EG, Petersen SA. Acromioclavicular joint injuries: indications for treatment and treatment options. *J Shoulder Elbow Surg.* 2011;20:S70-82.
- [6] Cook JB, Krul KP. Challenges in Treating Acromioclavicular Separations: Current Concepts. *J Am Acad Orthop Surg.* 2018;26:669-77.
- [7] Frank RM, Cotter EJ, Leroux TS, Romeo AA. Acromioclavicular Joint Injuries: Evidence-based Treatment. *J Am Acad Orthop Surg.* 2019;27:e775-e88.
- [8] Crönlein M, Postl L, Beirer M, Pförringer D, Lang J, Greve F, et al. Analysis of the bony geometry of the acromio-clavicular joint. *Eur J Med Res.* 2018;23:50.
- [9] Keats TE, Pope TL. The acromioclavicular joint: normal variation and the diagnosis of dislocation. *Skeletal Radiol.* 1988;17:159-62.
- [10] Nourissat G, Henon A, Debet-Mejean A, Clement P, Dumontier C, Sautet A, et al. Three-Dimensional Computed Tomographic Scan of the External Third of the Clavicle. *Arthroscopy.* 2007;23:29-33.
- [11] Keener JD. Acromioclavicular Joint Anatomy and Biomechanics. *Oper Tech Sports Med.* 2014;22:210-3.
- [12] Petersson CJ. Degeneration of the acromioclavicular joint. A morphological study. *Acta Orthop Scand.* 1983;54:434-8.
- [13] Fukuda K, Craig EV, An KN, Cofield RH, Chao EY. Biomechanical study of the ligamentous system of the acromioclavicular joint. *J Bone Joint Surg Am.* 1986;68:434-40.
- [14] Nakazawa M, Nimura A, Mochizuki T, Koizumi M, Sato T, Akita K. The Orientation and Variation of the Acromioclavicular Ligament: An Anatomic Study. *Am J Sports Med.* 2016;44:2690-5.
- [15] Salter EG, Jr., Nasca RJ, Shelley BS. Anatomical observations on the acromioclavicular joint and supporting ligaments. *Am J Sports Med.* 1987;15:199-206.
- [16] Rios CG, Arciero RA, Mazzocca AD. Anatomy of the Clavicle and Coracoid Process for Reconstruction of the Coracoclavicular Ligaments. *Am J Sports Med.* 2007;35:811-7.

- [17] Czerwonatis S, Dehghani F, Steinke H, Hepp P, Bechmann I. Nameless in anatomy, but famous among surgeons: The so called "deltotrapezoid fascia". *Ann Anat.* 2020;231:151488.
- [18] Pastor MF, Averbek AK, Welke B, Smith T, Claassen L, Wellmann M. The biomechanical influence of the deltoid fascia on horizontal and vertical acromioclavicular joint stability. *Arch Orthop Trauma Surg.* 2016;136:513-9.
- [19] Inman VT, Saunders JB. Observations on the Function of the Clavicle. *Calif Med.* 1946;65:158-66.
- [20] Sahara W, Sugamoto K, Murai M, Yoshikawa H. Three-dimensional clavicular and acromioclavicular rotations during arm abduction using vertically open MRI. *J Orthop Res.* 2007;25:1243-9.
- [21] Saccomanno MF, Ieso DC, Milano G. Acromioclavicular joint instability: anatomy, biomechanics and evaluation. *Joints.* 2014;2:87-92.
- [22] Dawson PA, Adamson GJ, Pink MMPT, Kornswiet M, Lin S, Shankwiler JA, et al. Relative contribution of acromioclavicular joint capsule and coracoclavicular ligaments to acromioclavicular stability. *J Shoulder Elbow Surg.* 2009;18:237-44.
- [23] Lee KW, Debski RE, Chen CH, Woo SL, Fu FH. Functional evaluation of the ligaments at the acromioclavicular joint during anteroposterior and superoinferior translation. *Am J Sports Med.* 1997;25:858-62.
- [24] Costic RS, Labriola JE, Rodosky MW, Debski RE. Biomechanical rationale for development of anatomical reconstructions of coracoclavicular ligaments after complete acromioclavicular joint dislocations. *Am J Sports Med.* 2004;32:1929-36.
- [25] Debski RE, Parsons IMt, Woo SL, Fu FH. Effect of capsular injury on acromioclavicular joint mechanics. *J Bone Joint Surg Am.* 2001;83:1344-51.
- [26] Costic RS, Jari R, Rodosky MW, Debski RE. Joint compression alters the kinematics and loading patterns of the intact and capsule-transected AC joint. *J Orthop Res.* 2003;21:379-85.
- [27] Gerber C, Galantay RV, Hersche O. The pattern of pain produced by irritation of the acromioclavicular joint and the subacromial space. *J Shoulder Elbow Surg.* 1998;7:352-5.
- [28] Markel J, Schwarting T, Malcherczyk D, Peterlein CD, Ruchholtz S, El-Zayat BF. Concomitant glenohumeral pathologies in high-grade acromioclavicular separation (type III - V). *BMC Musculoskelet Disord.* 2017;18:439.
- [29] Edgar C, DeGiacomo A, Lemos MJ, Mazzocca AD. Acromioclavicular joint injuries. In: Court-Brown CM, Heckman JD, McQueen MM, Ricci WM, Tornetta III P, editors. *Rockwood and Green's: Fractures in Adults.* 8 ed. Philadelphia, Pennsylvania, USA: Wolters Kluwer Health; 2015.
- [30] Rockwood AC, Jr. Subluxations and dislocations about the shoulder: injuries to the acromioclavicular joint. In: Rockwood AC, Jr, Green DP, editors. *Fractures in adults.* 2 ed. Philadelphia, PA: JB Lippincott Company; 1984. p. 860-910.
- [31] Allman FL, Jr. Fractures and ligamentous injuries of the clavicle and its articulation. *J Bone Joint Surg Am.* 1967;49:774-84.
- [32] Zanca P. Shoulder Pain: Involvement of the Acromioclavicular Joint. *AJR Am J Roentgenol.* 1971;112:493-506.
- [33] Ernberg LA, Potter HG. Radiographic evaluation of the acromioclavicular and sternoclavicular joints. *Clin Sports Med.* 2003;22:255-75.

- [34] Nguyen V, Williams G, Rockwood C. Radiography of acromioclavicular dislocation and associated injuries. *Crit Rev Diagn Imaging*. 1991;32:191-228.
- [35] Gastaud O, Raynier JL, Duparc F, Baverel L, Andrieu K, Tarissi N, et al. Reliability of radiographic measurements for acromioclavicular joint separations. *Orthop Traumatol Surg Res*. 2015;101:291-5.
- [36] Tornetta P, Ricci W, Court-Brown CM, McQueen MM, McKee M. Rockwood and Green's: Fractures in Adults. Philadelphia, PA, USA: Wolters Kluwer Health, Inc.; 2015.
- [37] Ibrahim EF, Forrest NP, Forester A. Bilateral weighted radiographs are required for accurate classification of acromioclavicular separation: an observational study of 59 cases. *Injury*. 2015;46:1900-5.
- [38] Bossart PJ, Joyce SM, Manaster BJ, Packer SM. Lack of efficacy of 'weighted' radiographs in diagnosing acute acromioclavicular separation. *Ann Emerg Med*. 1988;17:20-4.
- [39] Yap JLL, Curl LA, Kvitne RS, McFarland EG. The value of weighted views of the acromioclavicular joint - Results of a survey. *Am J Sports Med*. 1999;27:806-9.
- [40] Shaw KA, Synovec J, Eichinger J, Tucker CJ, Grassbaugh JA, Parada SA. Stress radiographs for evaluating acromioclavicular joint separations in an active-duty patient population: what have we learned? *J Orthop*. 2018;15:159-63.
- [41] Vanarthos WJ, Ekman EF, Bohrer SP. Radiographic diagnosis of acromioclavicular joint separation without weight bearing: Importance of internal rotation of the arm. *AJR Am J Roentgenol*. 1994;162:120-2.
- [42] Aliberti GM, Kraeutler MJ, Trojan JD, Mulcahey MK. Horizontal instability of the acromioclavicular joint: a systematic review. *Am J Sports Med*. 2020;48:504-10.
- [43] Rahm S, Wieser K, Spross C, Vich M, Gerber C, Meyer DC. Standard axillary radiographs of the shoulder may mimic posterior subluxation of the lateral end of the clavicle. *J Orthop Trauma*. 2013;27:622-6.
- [44] Tauber M, Koller H, Hitzl W, Resch H. Dynamic radiologic evaluation of horizontal instability in acute acromioclavicular joint dislocations. *Am J Sports Med*. 2010;38:1188-95.
- [45] Cho CH, Hwang I, Seo JS, Choi CH, Ko SH, Park HB, et al. Reliability of the classification and treatment of dislocations of the acromioclavicular joint. *J Shoulder Elbow Surg*. 2014;23:665-70.
- [46] Zumstein MA, Schiessl P, Ambuehl B, Bolliger L, Weihs J, Maurer MH, et al. New quantitative radiographic parameters for vertical and horizontal instability in acromioclavicular joint dislocations. *Knee Surg Sports Traumatol Arthrosc*. 2018;26:125-35.
- [47] Schaefer FK, Schaefer PJ, Brossmann J, Hilgert RE, Heller M, Jahnke T. Experimental and clinical evaluation of acromioclavicular joint structures with new scan orientations in MRI. *Eur Radiol*. 2006;16:1488-93.
- [48] Antonio GE, Cho JH, Chung CB, Trudell DJ, Resnick D. Pictorial essay. MR imaging appearance and classification of acromioclavicular joint injury. *AJR Am J Roentgenol*. 2003;180:1103-10.
- [49] Pogorzelski J, Beitzel K, Ranuccio F, Woertler K, Imhoff AB, Millett PJ, et al. The acutely injured acromioclavicular joint - which imaging modalities should be used

- for accurate diagnosis? A systematic review. *BMC Musculoskelet Disord.* 2017;18:515.
- [50] Nemec U, Oberleitner G, Nemec SF, Gruber M, Weber M, Czerny C, et al. MRI versus radiography of acromioclavicular joint dislocation. *AJR Am J Roentgenol.* 2011;197:968-73.
  - [51] Takase K. MRI evaluation of coracoclavicular ligament injury in acromioclavicular joint separation. *Eur J Orthop Surg Traumatol.* 2011;21:563.
  - [52] Bilfeld MF, Lapegue F, Gandois HC, Bayol MA, Bonneville N, Sans N. Ultrasound of the coracoclavicular ligaments in the acute phase of an acromioclavicular dislocation: Comparison of radiographic, ultrasound and MRI findings. *Eur Radiol.* 2017;27:483-90.
  - [53] Hobusch GM, Fellingner K, Schoster T, Lang S, Windhager R, Sabeti-Aschraf M. Ultrasound of horizontal instability of the acromioclavicular joint. *Wiener klinische Wochenschrift.* 2019;131:81-6.
  - [54] Tossy JD, Mead NC, Sigmund HM. Acromioclavicular separations: useful and practical classification for treatment. *Clin Orthop Relat Res.* 1963;28:111-9.
  - [55] Gorbaty JD, Hsu JE, Gee AO. Classifications in brief: Rockwood classification of acromioclavicular joint separations. *Clin Orthop Relat Res.* 2017;475:283-7.
  - [56] Beitzel K, Mazzocca AD, Bak K, Itoi E, Kibler WB, Mirzayan R, et al. ISAKOS upper extremity committee consensus statement on the need for diversification of the Rockwood classification for acromioclavicular joint injuries. *Arthroscopy.* 2014;30:271-8.
  - [57] Tamaoki MJ, Lenza M, Matsunaga FT, Belloti JC, Matsumoto MH, Faloppa F. Surgical versus conservative interventions for treating acromioclavicular dislocation of the shoulder in adults. *Cochrane Database Syst Rev.* 2019;10:Cd007429.
  - [58] Schneider M, Balke M, Koenen P, Fröhlich M, Wafaisade A, Bouillon B, et al. Inter- and intraobserver reliability of the Rockwood classification in acute acromioclavicular joint dislocations. *Knee Surg Sports Traumatol Arthrosc.* 2016;24:2192-6.
  - [59] Ringenber JD, Foughty Z, Hall AD, Aldridge JM, Wilson JB, Kuremsky MA. Interobserver and intraobserver reliability of radiographic classification of acromioclavicular joint dislocations. *J Shoulder Elbow Surg.* 2018;27:538-44.
  - [60] Collins DN. Disorders of the Acromioclavicular Joint. In: Rockwood CA, Matsen FA, Wirth MA, Lippitt SB, Fehring EV, Sperling JW, editors. *Rockwood and Matsen's The Shoulder* 2017. p. 365-451.e17.
  - [61] Chillemi C, Franceschini V, Giudici LD, Alibardi A, Santone FS, Ramos Alday LJ, et al. Epidemiology of Isolated Acromioclavicular Joint Dislocation. *Emerg Med Int.* 2013;1-5.
  - [62] Skjaker SA, Enger M, Engebretsen L, Brox JI, Bøe B. Young men in sports are at highest risk of acromioclavicular joint injuries: a prospective cohort study. *Knee Surg Sports Traumatol Arthrosc.* 2020: Online ahead of print.
  - [63] Goldstein Y, Dolkart O, Kaufman E, Amar E, Sharfman ZT, Rath E, et al. Bicycle-Related Shoulder Injuries: Etiology and the Need for Protective Gear. *Isr Med Assoc J.* 2016;18:23-6.
  - [64] Headey J, Brooks JH, Kemp SPT. The epidemiology of shoulder injuries in English professional rugby union. *Am J Sports Med.* 2007;35:1537-43.

- [65] Goodman AD, Twomey-Kozak J, DeFroda SF, Owens BD. Epidemiology of shoulder and elbow injuries in National Collegiate Athletic Association wrestlers, 2009-2010 through 2013-2014. *The Physician And Sportsmedicine*. 2018;46:361-6.
- [66] Melvin PR, Souza S, Mead RN, Smith C, Mulcahey MK. Epidemiology of Upper Extremity Injuries in NCAA Men's and Women's Ice Hockey. *Am J Sports Med*. 2018;46:2521-9.
- [67] Melvin PR, Souza S, Mead RN, Smith C, Mulcahey MK. Epidemiology of Upper Extremity Injuries in NCAA Men's and Women's Ice Hockey: Addendum. *Am J Sports Med*. 2018;46:NP69-NP72.
- [68] Kelly BT, Barnes RP, Powell JW, Warren RF. Shoulder Injuries to Quarterbacks in the National Football League. *Am J Sports Med*. 2004;32:328-31.
- [69] Tummala SV, Hartigan DE, Patel KA, Makovicka JL, Chhabra A. Shoulder Injuries in National Collegiate Athletic Association Quarterbacks: 10-Year Epidemiology of Incidence, Risk Factors, and Trends. *Orthop J Sports Med*. 2018;6:2325967118756826.
- [70] Flik K, Lyman S, Marx RG. American Collegiate Men's Ice Hockey. *Am J Sports Med*. 2005;33:183-7.
- [71] McCall D, Safran MR. Injuries about the shoulder in skiing and snowboarding. *Br J Sports Med*. 2009;43:987-92.
- [72] Idzikowski JR, Janes PC, Abbott PJ. Upper extremity snowboarding injuries. Ten-year results from the Colorado snowboard injury survey. *Am J Sports Med*. 2000;28:825-32.
- [73] Nordqvist A, Petersson CJ. Incidence and causes of shoulder girdle injuries in an urban population. *J Shoulder Elbow Surg*. 1995;4:107-12.
- [74] Enger M, Skjaker SA, Melhuus K, Nordsletten L, Pripp AH, Moosmayer S, et al. Shoulder injuries from birth to old age: a 1-year prospective study of 3031 shoulder injuries in an urban population. *Injury*. 2018;49:1324-9.
- [75] Virk MS, Apostolakos J, Cote MP, Baker B, Beitzel K, Mazzocca AD. Operative and Nonoperative Treatment of Acromioclavicular Dislocation: A Critical Analysis Review. *JBJS reviews*. 2015;3.
- [76] Beitzel K, Cote MP, Apostolakos J, Solovyova O, Judson CH, Ziegler CG, et al. Current Concepts in the Treatment of Acromioclavicular Joint Dislocations. *Arthroscopy*. 2013;29:387-97.
- [77] Reid D, Polson K, Johnson L. Acromioclavicular Joint Separations Grades I–III. *Sports Med*. 2012;42:681-96.
- [78] Mouhsine E, Garofalo R, Crevoisier X, Farron A. Grade I and II acromioclavicular dislocations: results of conservative treatment. *J Shoulder Elbow Surg*. 2003;12:599-602.
- [79] Shaw MBK, McInerney JJ, Dias JJ, Evans PA. Acromioclavicular joint sprains: the post-injury recovery interval. *Injury*. 2003;34:438-42.
- [80] Mikek M. Long-term shoulder function after type I and II acromioclavicular joint disruption. *Am J Sports Med*. 2008;36:2147-50.
- [81] Mascioli AA. Acute Dislocations. In: Azar FM, Beaty JH, Canale ST, editors. *Campbell's Operative Orthopaedics* 2017. p. 3117-36.e4.
- [82] Bjerneld H, Hovelius L, Thorling J. Acromioclavicular Separations Treated Conservatively: A 5-year Follow-up Study. *Acta Orthop Scand*. 1983;54:743-5.



- [83] Cox JS. The fate of the acromioclavicular joint in athletic injuries. *Am J Sports Med.* 1981;9:50-3.
- [84] Bergfeld JA, Andrish JT, Clancy WG. Evaluation of the acromioclavicular joint following first- and second-degree sprains. *Am J Sports Med.* 1978;6:153-9.
- [85] Petersson CJ. Resection of the Lateral End of the Clavicle: A 3 to 30-Year Follow-Up. *Acta Orthop Scand.* 1983;54:904-7.
- [86] Cook FF, Tibone JE. The Mumford procedure in athletes. An objective analysis of function. *Am J Sports Med.* 1988;16:97-100.
- [87] Gstettner C, Tauber M, Hitzl W, Resch H. Rockwood type III acromioclavicular dislocation: surgical versus conservative treatment. *J Shoulder Elbow Surg.* 2008;17:220-5.
- [88] Gumina S, Carbone S, Postacchini F. Scapular dyskinesis and SICK scapula syndrome in patients with chronic type III acromioclavicular dislocation. *Arthroscopy.* 2009;25:40-5.
- [89] Burkhart SS, Morgan CD, Kibler WB. The disabled throwing shoulder: spectrum of pathology Part III: The SICK scapula, scapular dyskinesis, the kinetic chain, and rehabilitation. *Arthroscopy.* 2003;19:641-61.
- [90] Carbone S, Postacchini R, Gumina S. Scapular dyskinesis and SICK syndrome in patients with a chronic type III acromioclavicular dislocation. Results of rehabilitation. *Knee Surg Sports Traumatol Arthrosc.* 2015;23:1473-80.
- [91] Glick JM, Milburn LJ, Haggerty JF, Nishimoto D. Dislocated acromioclavicular joint: follow-up study of 35 unreduced acromioclavicular dislocations. *Am J Sports Med.* 1977;5:264-70.
- [92] Dias JJ, Steingold RF, Richardson RA, Tesfayohannes B, Gregg PJ. The conservative treatment of acromioclavicular dislocation. Review after five years. *J Bone Joint Surg Br.* 1987;69:719-22.
- [93] Bannister GC, Wallace WA, Stableforth PG, Hutson MA. The management of acute acromioclavicular dislocation. A randomised prospective controlled trial. *J Bone Joint Surg Br.* 1989;71:848-50.
- [94] Schlegel TF, Burks RT, Marcus RL, Dunn HK. A prospective evaluation of untreated acute grade III acromioclavicular separations. *Am J Sports Med.* 2001;29:699-703.
- [95] Petri M, Warth RJ, Greenspoon JA, Horan MP, Abrams RF, Kokmeyer D, et al. Clinical Results After Conservative Management for Grade III Acromioclavicular Joint Injuries: Does Eventual Surgery Affect Overall Outcomes? *Arthroscopy.* 2016;32:740-6.
- [96] Minkus M, Hann C, Scheibel M, Kraus N. Quantification of dynamic posterior translation in modified bilateral Alexander views and correlation with clinical and radiological parameters in patients with acute acromioclavicular joint instability. *Arch Orthop Trauma Surg.* 2017;137:845-52.
- [97] Feichtinger X, Dahm F, Schallmayer D, Boesmueller S, Fialka C, Mittermayr R. Surgery improves the clinical and radiological outcome in Rockwood type IV dislocations, whereas Rockwood type III dislocations benefit from conservative treatment. *Knee Surg Sports Traumatol Arthrosc.* 2020.
- [98] Virtanen KJ, Remes VM, Tulikoura ITA, Pajarinen JT, Savolainen VT, Björkenheim J-MG, et al. Surgical treatment of Rockwood grade-V acromioclavicular joint dislocations. *Acta Orthop.* 2013;84:191-5.

- [99] Dunphy TR, Damodar D, Heckmann ND, Sivasundaram L, Omid R, Hatch GF, 3rd. Functional Outcomes of Type V Acromioclavicular Injuries With Nonsurgical Treatment. *J Am Acad Orthop Surg*. 2016;24:728-34.
- [100] Joukainen A, Kröger H, Niemitukia L, Mäkelä EA, Väättäin U. Results of Operative and Nonoperative Treatment of Rockwood Types III and V Acromioclavicular Joint Dislocation: A Prospective, Randomized Trial With an 18- to 20-Year Follow-up. *Orthop J Sports Med*. 2014;2:2325967114560130.
- [101] Natera Cisneros L, Sarasquete Reiriz J, Abat F, Besalduch M, Monllau J, Videla S. Acute unstable acromioclavicular joint injuries: quality of life comparison between patients managed operatively with a coracoclavicular suspension device arthroscopically placed versus patients managed non-operatively. *Eur Orthop Traumatol*. 2015;6:343.
- [102] Larsen E, Bjerg-Nielsen A, Christensen P. Conservative or surgical treatment of acromioclavicular dislocation. A prospective, controlled, randomized study. *J Bone Joint Surg Am*. 1986;68:552-5.
- [103] McKee M, Pelet S, McCormack RG, Harvey E, Papp S, Rouleau D, et al. Multicenter Randomized Clinical Trial of Nonoperative Versus Operative Treatment of Acute Acromio-Clavicular Joint Dislocation. *J Orthop Trauma*. 2015;29:479-87.
- [104] Walsh WM, Peterson DA, Shelton G, Neumann RD. Shoulder strength following acromioclavicular injury. *Am J Sports Med*. 1985;13:153-8.
- [105] Calvo E, López-Franco M, Arribas IM. Clinical and radiologic outcomes of surgical and conservative treatment of type III acromioclavicular joint injury. *J Shoulder Elbow Surg*. 2006;15:300-5.
- [106] Fremerey R, Freitag N, Bosch U, Lobenhoffer P. Complete dislocation of the acromioclavicular joint: Operative versus conservative treatment. *J Orthop Traumatol*. 2005;6:174-8.
- [107] Galpin RD, Hawkins RJ, Grainger RW. A comparative analysis of operative versus nonoperative treatment of grade III acromioclavicular separations. *Clin Orthop Relat Res*. 1985;150-5.
- [108] Taft TN, Wilson FC, Oglesby JW. Dislocation of the acromioclavicular joint. An end-result study. *J Bone Joint Surg Am*. 1987;69:1045-51.
- [109] Constant CR, Gerber C, Emery RJ, Søjbjerg JO, Gohlke F, Boileau P. A review of the Constant score: modifications and guidelines for its use. *J Shoulder Elbow Surg*. 2008;17:355-61.
- [110] Weinstein DM, McCann PD, McIlveen SJ, Flatow EL, Bigliani LU. Surgical treatment of complete acromioclavicular dislocations. *Am J Sports Med*. 1995;23:324-31.
- [111] Dumontier C, Sautet A, Man M, Apoil A. Acromioclavicular dislocations: treatment by coracoacromial ligamentoplasty. *J Shoulder Elbow Surg*. 1995;4:130-4.
- [112] Rolf O, Hann von Weyhern A, Ewers A, Boehm TD, Gohlke F. Acromioclavicular dislocation Rockwood III–V: results of early versus delayed surgical treatment. *Arch Orthop Trauma Surg*. 2008;128:1153-7.
- [113] von Heideken J, Bostrom Windhamre H, Une-Larsson V, Ekelund A. Acute surgical treatment of acromioclavicular dislocation type V with a hook plate: superiority to late reconstruction. *J Shoulder Elbow Surg*. 2013;22:9-17.

- [114] Natera Cisneros L, Sarasquete Reiriz J. Unstable acromioclavicular joint injuries: Is there really a difference between surgical management in the acute or chronic setting? *J Orthop.* 2017;14:10-8.
- [115] Hegazy G, Safwat H, Seddik M, Al-Shal EA, Al-Sebai I, Negm M. Modified Weaver-Dunn Procedure Versus The Use of Semitendinosus Autogenous Tendon Graft for Acromioclavicular Joint Reconstruction. *Open Orthop J.* 2016;10:166-78.
- [116] Michlitsch MG, Adamson GJ, Pink M, Estess A, Shankwiler JA, Lee TQ. Biomechanical Comparison of a Modified Weaver-Dunn and a Free-Tissue Graft Reconstruction of the Acromioclavicular Joint Complex. *Am J Sports Med.* 2010;38:1196-203.
- [117] Tauber M, Gordon K, Koller H, Fox M, Resch H. Semitendinosus tendon graft versus a modified Weaver-Dunn procedure for acromioclavicular joint reconstruction in chronic cases: a prospective comparative study. *Am J Sports Med.* 2009;37:181-90.
- [118] Bosworth BM. Acromioclavicular separation new method of repair. *Surg Gynecol Obstet.* 1941;73:866-71.
- [119] Bosworth BM. Acromioclavicular Dislocation: End-Results of Screw Suspension Treatment. *Ann Surg.* 1948;127:98-111.
- [120] Tsou PM. Percutaneous cannulated screw coracoclavicular fixation for acute acromioclavicular dislocations. *Clin Orthop Relat Res.* 1989;112-21.
- [121] Sundaram N, Patel DV, Porter DS. Stabilization of acute acromioclavicular dislocation by a modified Bosworth technique: a long-term follow-up study. *Injury.* 1992;23:189-93.
- [122] Darabos N, Vlahovic I, Gusic N, Darabos A, Bakota B, Miklic D. Is AC TightRope fixation better than Bosworth screw fixation for minimally invasive operative treatment of Rockwood III AC joint injury? *Injury.* 2015;46 Suppl 6:S113-8.
- [123] Phemister DB. The treatment of dislocation of the acromioclavicular joint by open reduction and threaded-wire fixation. *J Bone Joint Surg.* 1942;24:166-8.
- [124] Verdano MA, Pellegrini A, Zanelli M, Paterlini M, Ceccarelli F. Modified Phemister procedure for the surgical treatment of Rockwood types III, IV, V acute acromioclavicular joint dislocation. *Musculoskelet Surg.* 2012;96:213-22.
- [125] Tauber M. Management of acute acromioclavicular joint dislocations: current concepts. *Arch Orthop Trauma Surg.* 2013;133:985-95.
- [126] Norrell H, Jr., Llewellyn RC. Migration of a Threaded Steinmann Pin from an Acromioclavicular Joint into the Spinal Canal. A Case Report. *J Bone Joint Surg Am.* 1965;47:1024-6.
- [127] Kienast B, Thietje R, Queitsch C, Gille J, Schulz AP, Meiners J. Mid-term results after operative treatment of rockwood grade III-V acromioclavicular joint dislocations with an AC-hook-plate. *Eur J Med Res.* 2011;16:52-6.
- [128] Chaudhary D, Jain V, Joshi D, Jain JK, Goyal A, Mehta N. Arthroscopic fixation for acute acromioclavicular joint disruption using the TightRope device. *J Orthop Surg (Hong Kong).* 2015;23:309-14.
- [129] De Carli A, Lanzetti RM, Ciompi A, Lupariello D, Rota P, Ferretti A. Acromioclavicular third degree dislocation: surgical treatment in acute cases. *J Orthop Surg Res.* 2015;10:145-59.

- [130] Horst K, Dienstknecht T, Pishnamaz M, Sellei RM, Kobbe P, Pape H-C. Operative treatment of acute acromioclavicular joint injuries graded Rockwood III and IV: risks and benefits in tight rope technique vs. k-wire fixation. *Patient Saf Surg.* 2013;7:1-6.
- [131] Sircana G, Saccomanno MF, Mocini F, Campana V, Messinese P, Monteleone A, et al. Anatomic reconstruction of the acromioclavicular joint provides the best functional outcomes in the treatment of chronic instability. *Knee Surg Sports Traumatol Arthrosc.* 2020: Online ahead of print.
- [132] Mazzocca AD, Santangelo SA, Johnson ST, Rios CG, Dumonski ML, Arciero RA. A Biomechanical Evaluation of an Anatomical Coracoclavicular Ligament Reconstruction. *Am J Sports Med.* 2006;34:236-46.
- [133] Grutter PW, Petersen SA. Anatomical acromioclavicular ligament reconstruction: a biomechanical comparison of reconstructive techniques of the acromioclavicular joint. *Am J Sports Med.* 2005;33:1723-8.
- [134] Lee SJ, Nicholas SJ, Akizuki KH, McHugh MP, Kremenich IJ, Ben-Avi S. Reconstruction of the coracoclavicular ligaments with tendon grafts: a comparative biomechanical study. *Am J Sports Med.* 2003;31:648-55.
- [135] Deshmukh AV, Wilson DR, Zilberfarb JL, Perlmutter GS. Stability of acromioclavicular joint reconstruction: biomechanical testing of various surgical techniques in a cadaveric model. *Am J Sports Med.* 2004;32:1492-8.
- [136] Gowd AK, Liu JN, Cabarcas BC, Cvetanovich GL, Garcia GH, Manderle BJ, et al. Current Concepts in the Operative Management of Acromioclavicular Dislocations: A Systematic Review and Meta-analysis of Operative Techniques. *Am J Sports Med.* 2019;47:2745-58.
- [137] Boström Windhamre HA, von Heideken JP, Une-Larsson VE, Ekelund AL. Surgical treatment of chronic acromioclavicular dislocations: A comparative study of Weaver-Dunn augmented with PDS-braid or hook plate. *J Shoulder Elbow Surg.* 2010;19:1040.
- [138] Borbas P, Churchill J, Ek ET. Surgical management of chronic high-grade acromioclavicular joint dislocations: a systematic review. *J Shoulder Elbow Surg.* 2019;28:2031-8.
- [139] Cerciello S, Berthold DP, Uyeki C, Kia C, Cote MP, Imhoff AB, et al. Anatomic coracoclavicular ligament reconstruction (ACCR) using free tendon allograft is effective for chronic acromioclavicular joint injuries at mid-term follow-up. *Knee Surg Sports Traumatol Arthrosc.* 2020: Online ahead of print.
- [140] Millett PJ, Horan MP, Warth RJ. Two-Year Outcomes After Primary Anatomic Coracoclavicular Ligament Reconstruction. *Arthroscopy.* 2015;31:1962-73.
- [141] Motta P, Marra F, Maderni A, Vasario G, Sisto R, Jawahar M, et al. The long-term efficacy of the GraftRope technique. *J Shoulder Elbow Surg.* 2020;29:2143-8.
- [142] Jensen G, Katthagen JC, Alvarado L, Lill H, Voigt C. Arthroscopically assisted stabilization of chronic AC-joint instabilities in GraftRope™ technique with an additive horizontal tendon augmentation. *Arch Orthop Trauma Surg.* 2013;133:841-51.
- [143] Yoo J-C, Ahn J-H, Yoon J-R, Yang J-H. Clinical results of single-tunnel coracoclavicular ligament reconstruction using autogenous semitendinosus tendon. *Am J Sports Med.* 2010;38:950-7.

- [144] Mazzocca AD, Conway JE, Johnson S, Rios CG, Dumonski ML, Santangelo SA, et al. The anatomic coracoclavicular ligament reconstruction. *Oper Tech Sports Med.* 2004;12:56-61.
- [145] Carofino BC, Mazzocca AD. The anatomic coracoclavicular ligament reconstruction: Surgical technique and indications. *J Shoulder Elbow Surg.* 2010;19 Suppl2:37-46.
- [146] Moatshe G, Kruckeberg BM, Chahla J, Godin JA, Cinque ME, Provencher MT, et al. Acromioclavicular and Coracoclavicular Ligament Reconstruction for Acromioclavicular Joint Instability: A Systematic Review of Clinical and Radiographic Outcomes. *Arthroscopy.* 2018;34:1979-95.e8.
- [147] Fauci F, Merolla G, Paladini P, Campi F, Porcellini G. Surgical treatment of chronic acromioclavicular dislocation with biologic graft vs synthetic ligament: a prospective randomized comparative study. *J Orthop Traumatol.* 2013;14:283-90.
- [148] Muench LN, Kia C, Jerliu A, Murphy M, Berthold DP, Cote MP, et al. Functional and Radiographic Outcomes After Anatomic Coracoclavicular Ligament Reconstruction for Type III/V Acromioclavicular Joint Injuries. *Orthop J Sports Med.* 2019;7:2325967119884539.
- [149] Beitzel K, Obopilwe E, Apostolakis J, Cote MP, Russell RP, Charette R, et al. Rotational and Translational Stability of Different Methods for Direct Acromioclavicular Ligament Repair in Anatomic Acromioclavicular Joint Reconstruction. *Am J Sports Med.* 2014;42:2141.
- [150] Jordan RW, Malik S, Bentick K, Saithna A. Acromioclavicular joint augmentation at the time of coracoclavicular ligament reconstruction fails to improve functional outcomes despite significantly improved horizontal stability. *Knee Surg Sports Traumatol Arthrosc.* 2019;27:3747-63.
- [151] Reintgen C, Gerlach EB, Schoch BS, Mamelson K, Wright TW, Farmer KW, et al. What Outcome Measures Are Reported in the Management of Acromioclavicular Joint Injuries? *Orthop J Sports Med.* 2020;8:2325967119892322-.
- [152] Barwood SA, French JA, Watson LA, Balster SM, Hoy GA, Pizzari T. The Specific AC Score (SACS): a new and validated method of assessment of isolated acromioclavicular joint pathology. *J Shoulder Elbow Surg.* 2018;27:2214-23.
- [153] Charles ER, Kumar V, Blacknall J, Edwards K, Geoghegan JM, Manning PA, et al. A validation of the Nottingham Clavicle Score: a clavicle, acromioclavicular joint and sternoclavicular joint-specific patient-reported outcome measure. *J Shoulder Elbow Surg.* 2017;26:1732-9.
- [154] Scheibel M, Dröschel S, Gerhardt C, Kraus N. Arthroscopically assisted stabilization of acute high-grade acromioclavicular joint separations. *Am J Sports Med.* 2011;39:1507-16.
- [155] Davis AM, Beaton DE, Hudak P, Amadio P, Bombardier C, Cole D, et al. Measuring disability of the upper extremity: a rationale supporting the use of a regional outcome measure. *J Hand Ther.* 1999;12:269-74.
- [156] Roy JS, MacDermid JC, Woodhouse LJ. Measuring shoulder function: a systematic review of four questionnaires. *Arthritis Rheum.* 2009;61:623-32.
- [157] Dowrick AS, Gabbe BJ, Williamson OD, Cameron PA. Outcome instruments for the assessment of the upper extremity following trauma: a review. *Injury.* 2005;36:468-76.

- [158] Roos EM, Lohmander LS. The Knee injury and Osteoarthritis Outcome Score (KOOS): from joint injury to osteoarthritis. *Health Qual Life Outcomes*. 2003;1:1-8.
- [159] Collins NJ, Prinsen CAC, Christensen R, Bartels EM, Terwee CB, Roos EM. Knee Injury and Osteoarthritis Outcome Score (KOOS): systematic review and meta-analysis of measurement properties. *Osteoarthritis Cartilage*. 2016;24:1317-29.
- [160] Grobet C, Marks M, Tecklenburg L, Audigé L. Application and measurement properties of EQ-5D to measure quality of life in patients with upper extremity orthopaedic disorders: a systematic literature review. *Arch Orthop Trauma Surg*. 2018;138:953-61.
- [161] Lord JP, Aitkens SG, McCrory MA, Bernauer EM. Isometric and isokinetic measurement of hamstring and quadriceps strength. *Arch Phys Med Rehabil*. 1992;73:324-30.
- [162] Cook JB, Shaha JS, Rowles DJ, Bottoni CR, Shaha SH, Tokish JM. Early failures with single clavicular transosseous coracoclavicular ligament reconstruction. *J Shoulder Elbow Surg*. 2012;21:1746-52.
- [163] Milewski MD, Tompkins M, Giugale JM, Carson EW, Miller MD, Diduch DR. Complications Related to Anatomic Reconstruction of the Coracoclavicular Ligaments. *Am J Sports Med*. 2012;40:1628.
- [164] Post M. Current concepts in the diagnosis and management of acromioclavicular dislocations. *Clin Orthop Relat Res*. 1985;200:234-47.
- [165] Kim AC, Matcuk G, Patel D, Itamura J, Forrester D, White E, et al. Acromioclavicular joint injuries and reconstructions: a review of expected imaging findings and potential complications. *Emerg Radiol*. 2012;19:399-413.
- [166] DeBerardino TM, Pensak MJ, Ferreira J, Mazzocca AD. Arthroscopic stabilization of acromioclavicular joint dislocation using the AC graftrope system. *J Shoulder Elbow Surg*. 2010;19:47-52.
- [167] Xue C, Song L-J, Li X, Zhang G-Y, Fang J-H. Coracoclavicular ligaments anatomical reconstruction: a feasibility study. *Int J Med Robot*. 2015;11:181-7.
- [168] Ferreira JV, Chowaniec D, Obopilwe E, Nowak MD, Arciero RA, Mazzocca AD. Original Article: Biomechanical Evaluation of Effect of Coracoid Tunnel Placement on Load to Failure of Fixation During Repair of Acromioclavicular Joint Dislocations. *Arthroscopy*. 2012;28:1230-6.
- [169] Coale RM, Hollister SJ, Dines JS, Allen AA, Bedi A. Anatomic considerations of transclavicular-transcoracoid drilling for coracoclavicular ligament reconstruction. *J Shoulder Elbow Surg*. 2013;22:137-44.
- [170] Armitage MS, Elkinson I, Giles JW, Athwal GS. An anatomic, computed tomographic assessment of the coracoid process with special reference to the congruent-arc latarjet procedure. *Arthroscopy*. 2011;27:1485-9.
- [171] Schliemann B, Rosslenbroich SB, Schneider KN, Theisen C, Petersen W, Raschke MJ, et al. Why does minimally invasive coracoclavicular ligament reconstruction using a flip button repair technique fail? An analysis of risk factors and complications. *Knee Surg Sports Traumatol Arthrosc*. 2015;23:1419-25.
- [172] Gupta P, Kansal G, Srivastav S, Agarwal S. Original Article: Arthroscopic fixation using TightRope device for acute acromioclavicular joint disruptions. *Journal of Arthroscopy and Joint Surgery*. 2016;3:7-12.

- [173] Baran S, Belisle JG, Granger EK, Tashjian RZ. Functional and Radiographic Outcomes After Allograft Anatomic Coracoclavicular Ligament Reconstruction. *J Orthop Trauma*. 2018;32:204-10.
- [174] Cody EA, Karnovsky SC, DeSandis B, Tychanski Papson A, Deland JT, Drakos MC. Hamstring Autograft for Foot and Ankle Applications. *Foot Ankle Int*. 2018;39:189-95.
- [175] Flies A, Scheibel M, Kraus N, Kruppa P, Provencher MT, Becker R, et al. Isolated gracilis tendon harvesting is not associated with loss of strength and maintains good functional outcome. *Knee Surg Sports Traumatol Arthrosc*. 2020;28:637-44.
- [176] Yasuda K, Tsujino J, Ohkoshi Y, Tanabe Y, Kaneda K. Graft site morbidity with autogenous semitendinosus and gracilis tendons. *Am J Sports Med*. 1995;23:706-14.
- [177] McRae S, Leiter J, McCormack R, Old J, MacDonald P. Ipsilateral versus contralateral hamstring grafts in anterior cruciate ligament reconstruction: a prospective randomized trial. *Am J Sports Med*. 2013;41:2492-9.
- [178] Bishop JY, Flatow EL. Pediatric shoulder trauma. *Clin Orthop Relat Res*. 2005;41-8.

# Paper I









# Acromioclavicular joint dislocations: incidence, injury profile, and patient characteristics from a prospective case series

Jonas S. Nordin, MD<sup>\*</sup>, Ola Olsson, MD, PhD, Karl Lunsjö, MD

Department of Orthopedics, Lund University, Helsingborg Hospital, Helsingborg, Sweden

## ARTICLE INFO

### Keywords:

Acromioclavicular joint  
dislocation  
separation  
epidemiology  
incidence  
classification

Level of evidence: Level III; Cross-Sectional  
Design; Epidemiology Study

**Background:** Acromioclavicular joint (ACJ) dislocations are common but evidence regarding the epidemiology of these injuries is incomplete. This study aims to describe the incidence, injury mechanisms, distribution of classifications, risk factors, and patient characteristics for ACJ dislocations in a general population.

**Methods:** Inclusion was performed prospectively during a 4-year period with the following criteria; age 18–75 years, shoulder trauma within 2 weeks, a clinical suspicion of ACJ dislocation, and radiographs that excluded fracture. The injuries were classified according to the Rockwood system, and epidemiologic variables were obtained. Rockwood types 1–2 were defined as low-grade injuries and types 3–6 as high-grade. Age groups were defined with a young group (18–39 years), an intermediate group (40–59), and an old group (60–75).

**Results:** A total of 158 patients were included; 139 were male and the mean age was 39 years (range 18–74). There were 73 low-grade and 85 high-grade injuries. The incidence was 2.0 [95% confidence interval (CI) = 1.7–2.4] per 10,000 person-years, gradually decreasing with higher age, groupwise. The incidence rate ratio (IRR) for men vs. women was 7.6 (95% CI = 4.7–12.6) and IRR >1 was seen comparing younger age groups to older. Odds ratio calculations showed that risk factors for high-grade injury were older age and traffic accidents.

**Conclusion:** The incidence of ACJ dislocations was 2.0 per 10,000 person-years in a general population. Male gender and younger age group were risk factors for injury, whereas the risk for high-grade injuries were greater in older patients and after traffic accidents.

© 2020 The Author(s). Published by Elsevier Inc. on behalf of American Shoulder and Elbow Surgeons. This is an open access article under the CC BY-NC-ND license (<http://creativecommons.org/licenses/by-nc-nd/4.0/>).

Acromioclavicular joint (ACJ) dislocations are common, representing 10% of all shoulder injuries in an urban population.<sup>3</sup> A direct force to the superior acromion is the most common trauma mechanism, and with increasing force the soft tissues stabilizing the joint are assumed to be disrupted sequentially in the following order: the acromioclavicular (AC) ligaments, the coracoclavicular ligaments, and the deltoid trapezoidal fascia. Depending on the extent of soft tissue injury, ACJ dislocations are classified using radiographs and clinical examination into 6 different types according to Rockwood.<sup>5,11,12</sup>

Despite the common occurrence of ACJ dislocations, we have found only 1 previous study presenting detailed epidemiologic data and an incidence of 1.8 per 10,000 person-years.<sup>2</sup> It used a retrospective database search to identify participants, but no

prospective study has confirmed the results. Two further studies covering the epidemiology of all shoulder girdle injuries in 2 urban populations report incidences for ACJ dislocations of 4.6 and 0.8 per 10,000 person-years, respectively.<sup>3,10</sup>

Although evidence from a general population is limited to the studies above, the epidemiology of ACJ dislocations in selected populations of sports participants is more thoroughly described. The injury is common in contact sports such as American football, rugby, and ice hockey.<sup>6,8,9,13</sup> It is also common in noncontact, high-speed sports such as skiing and cycling.<sup>4,7</sup>

The aim of this study was to describe the incidence, injury mechanism, patient characteristics, and classification of ACJ dislocations in a general urban population and suggest risk factors associated with this injury.

## Materials and methods

Between January 2013 and December 2016, patients were prospectively included according to the following inclusion criteria: age 18–75 years, shoulder trauma within 2 weeks, a clinical

The study was approved by the Regional Ethical Review Board in Lund (Dnr 2012/454).

<sup>\*</sup> Corresponding author: Jonas S. Nordin, MD, Ortopedmottagningen, Helsingborgs lasarett, Charlotte Yhlens gata 10, 251 87 Helsingborg, Sweden.

E-mail address: [jonas.nordin@med.lu.se](mailto:jonas.nordin@med.lu.se) (J.S. Nordin).

<https://doi.org/10.1016/j.jseint.2020.01.009>

2666-6383/© 2020 The Author(s). Published by Elsevier Inc. on behalf of American Shoulder and Elbow Surgeons. This is an open access article under the CC BY-NC-ND license (<http://creativecommons.org/licenses/by-nc-nd/4.0/>).

suspicion of ACJ dislocation, and initial radiographs that excluded fracture. The study was conducted in the south of Sweden at Helsingborg hospital with a catchment area that consists of 8 neighboring municipalities of mainly urban population with a total of 280,251 inhabitants on December 31, 2016. The hospital has the only orthopedic emergency department in the area, and the staff working there were continuously informed about the study. To further increase recruitment, information was given to all primary care facilities and physical therapists in the area, and they were encouraged to refer patients meeting the inclusion criteria to us.

Eligible patients were identified and routine treatment was initiated, after which the patients were referred to one of 4 different study group physiotherapists with special shoulder training. They confirmed the suspicion of ACJ dislocation, acquired written consent to participate, and ordered study radiographs where both ACJ were exposed in a nonweighted panorama view. The patients were then seen by one of the study group orthopedic surgeons, who confirmed the diagnosis and classified the injury according to Rockwood using clinical examination and radiographs (Table 1). Epidemiologic data including gender, age, injury mechanism, and type of trauma were acquired. Injury mechanism was divided into direct and indirect force, and type of trauma was defined as the activity during which the injury occurred.

The patients were subdivided into 3 age groups: the young group, 18–39 years; the intermediate group, 40–59 years; and the old group, 60–75 years.<sup>2</sup> Type of trauma was grouped into 4 different categories: traffic accidents, sports, falls, and miscellaneous. Traffic accidents included all injuries to patients traveling in or on vehicles, both motorized and nonmotorized. Injuries during bicycle riding were divided according to the purpose of the ride between the sports and traffic accidents categories. We defined Rockwood type 1 and 2 as low-grade injuries and type 3–6 as high-grade injuries.

The population at risk was defined as the sum of persons aged 18–75 years living in the catchment area on December 31 for each of the studied years 2013–2016. The catchment area consisted of the municipalities Bjuv, Båstad, Helsingborg, Höganäs, Klippan, Åstorp, Ängelholm, and Örkelljunga. Population data were retrieved from Statistics Sweden, the government agency responsible for statistics regarding the Swedish society.

## Statistics

The incidence was calculated by dividing the total number of cases by the total number of person-years at risk and presented as number of cases per 10,000 person-years. An adjusted logistic regression model was used to calculate the odds ratios for high-grade injury depending on the epidemiologic variables of gender, age group, and type of trauma. Poisson regression was used to calculate incidence rate ratios (IRR) between genders and age groups; 95% confidence intervals (CI) were used throughout.

Calculations were performed using SAS 9.4 (SAS Institute Inc., Cary, NC, USA).

## Results

One hundred sixty-six patients were included and, from among them, 9 were subsequently excluded, leaving 157 patients in the study (Fig. 1). The mean age was 39 years (range 18–74), and 139 of the patients (89%) were male. For the male patients, the mean age was 35 years (range 18–74), and for female patients, it was 45 years (range 27–64).

The overall incidence was 2.0 (CI 1.7–2.4) per 10,000 person-years, gradually decreasing with higher age, groupwise (Table II). There were 21 Rockwood type 1 ACJ dislocations (13%), 51 type 2 (32%), 52 type 3 (33%), 2 type 4 (1%), and 31 type 5 (20%). In total, there were 72 low-grade (46%) and 85 high-grade injuries (54%).

ACJ dislocations were more common in the younger age groups and in males, with an IRR of 7.6 (95% CI 4.7–12.6) for men vs. women (Table III). Although more common in younger patients, the severity of the injuries increased with age, with an odds ratio for high-grade injury of 2.6 (95% CI 1.2–5.4) comparing the intermediate to the young age group, and similar trends when comparing the old age group to the intermediate, odds ratio 3.6 (95% CI 0.89–14.1) (Table IV).

The patients were most commonly injured during sporting activities or traffic accidents, with the 2 categories representing 66 (42%) and 54 (34%) of cases respectively (Table V). A direct force to the shoulder was the cause of injury in 150 of the cases (96%). Although injuries during sports were the most common, traffic accidents held the greatest risk of causing a high-grade dislocation when compared to the other types of mechanisms (Table IV).

In the young age group injuries during sports were most common, in the intermediate age group traffic accidents, and in the old age group falls (Table VI).

## Discussion

This is the only prospective study that in detail describes the epidemiology of ACJ dislocations in a general population. We calculated the incidence to 2.0 per 10,000 person-years for people aged 18–75 years and found that male gender and young age were risk factors. The risk of high-grade dislocation was greater in older patients and when injured in traffic accidents.

The incidence of ACJ dislocations in a general population has been previously described in 3 studies.<sup>2,5,10</sup> The most recent of these, by Enger et al.,<sup>3</sup> was prospective and aimed at presenting the profile of shoulder injuries in a general population. They divided the ACJ dislocations into 2 groups, “AC contusion/sprain/strain” and “AC separation/dislocation”; in the contusion/sprain/strain group, radiographs were normal, and in the separation/dislocation group, there was widening of the ACJ or coracoclavicular interval. These

**Table 1**  
Definition of Rockwood classification

Rockwood type	AC ligaments	CC ligaments	Deltotrapezoid fascia	Radiographs	Clinical examination of ACJ
1	Intact or partial injury	Intact	Intact	Normal	Stable
2	Torn	Intact or partial injury	Intact	Normal or widening of ACJ and/or slight increase in CC distance	Horizontal instability
3	Torn	Torn	Lateral avulsion	25%–100% increase in CC distance	Horizontal and vertical instability
4	Torn	Torn	Dorsal injury	Increased or normal CC distance. Possibly visible on lateral or axillary view	Large horizontal instability
5	Torn	Torn	Torn	>100% increased CC distance	Horizontal and large vertical instability
6	Torn	Torn	Torn	Inferior dislocation of clavicle	High risk of neurovascular insult

AC, acromioclavicular; CC, coracoclavicular; ACJ, acromioclavicular joint.

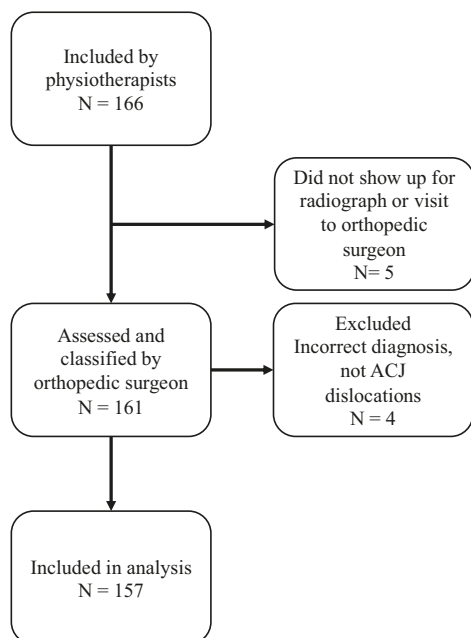


Figure 1 Flow chart describing inclusion of patients.

subgroups were similar but not identical to our low- and high-grade groups. An incidence of 4.6 per 10,000 person-years was reported, more than twice compared to our study. This high incidence appears to be explained by a large number of AC contusions/sprains/strains, 3.1 per 10,000 person-years compared to our

Table II

Overall incidence per gender and age group

Variables	Cases, n	Person-years at risk, 10 <sup>3</sup>	Incidence (95% CI)
Total	157	781	2.0 (1.7, 2.4)
Injury type			
Low grade	72	781	0.92 (0.73, 1.2)
High grade	85	781	1.1 (0.88, 1.3)
Gender			
Female	18	390	0.46 (0.29, 0.73)
Male	139	391	3.6 (3.0, 4.2)
Age group			
18–39 y	82	290	2.8 (2.3, 3.5)
40–59 y	61	288	2.1 (1.6, 2.7)
60–75 y	14	203	0.69 (0.41, 1.2)
Gender and age group			
Female			
18–39 y	5	142	0.35 (0.15, 0.84)
40–59 y	10	144	0.70 (0.38, 1.3)
60–75 y	3	103	0.29 (0.09, 0.90)
Male			
18–39 y	77	147	5.2 (4.2, 6.5)
40–59 y	51	144	3.5 (2.7, 4.7)
60–75 y	11	100	1.1 (0.61, 2.0)

CI, confidence interval.

Person-years at risk is the sum of population in our catchment area. Incidence was calculated as cases per 10,000 person-years.

Table III

Incidence rate ratios (IRRs) for subgroup comparisons

Variable	Comparison	IRR (95% CI)
Gender	Male vs. female	7.6 (4.7, 12.6)
Age group, y	18–39 vs. 40–59	1.3 (0.95, 1.8)
	18–39 vs. 60–75	4.0 (2.3, 7.0)
	40–59 vs. 60–75	3.0 (1.7, 5.4)

CI, confidence interval.

Calculations using adjusted poisson regression.

results for low-grade injuries of 0.93 per 10,000 person-years. The AC contusion/sprain/strain group of Enger et al includes all Rockwood type 1 and many of the Rockwood type 2 injuries, almost identical to our low-grade group, making the large difference in incidence between our studies peculiar. The incidence of high-grade injuries differed less, 1.4 compared to 1.1. To what extent these results reflect a true difference in incidence in the 2 studied populations, possibly related to demographic factors or different sporting or traffic habits, cannot be determined. However, we believe it likely that some patients with low-grade injuries were missed in our study because of patients seeking care elsewhere or not seeking care at all. Enger et al presented data to suggest that 83%–86% of their catchment population used their department in case of upper extremity injuries. No data were available to make similar estimates regarding our geographical area.

The study by Nordqvist and Petersson presented an incidence of ACJ dislocations of 0.8 per 10,000 person-years, which is the lowest in the literature.<sup>10</sup> The reason for the relatively low incidence cannot be determined. However, it is possible that a different definition of ACJ dislocation, which relied on the presence of pathologic radiographic findings, was used, and this would exclude many low-grade injuries.

The only previous study aiming to investigate the epidemiology of ACJ dislocations in more detail in a general population was published by Chillemi et al.<sup>2</sup> The study was retrospective, and patients were included using a database search and assessment of radiographs by 2 of the authors. Despite the difference in design, their results were comparable to ours with an incidence of 1.8 per 10,000 person-years and similar ratios of low- to high-grade injuries as well as the male-to-female injury rate.

The study included 108 patients with a mean age of 37.5 (13–69) years; 51% of the injuries occurred in those between 20–39 years old, and 90% of the patients were men. It was concluded that male gender and age between 20–39 years were significant demographic risk factors for ACJ dislocations, although statistical calculations were not provided to support the latter part of this statement. We confirmed these conclusions by showing higher IRR for males vs. females and for younger age groups compared with older.

Chillemi et al<sup>2</sup> did not find any significant association between type of trauma or age and Rockwood classification. In our material, we found that the risk of high-grade injury increased with age, groupwise, and injuries from traffic accidents caused more severe

Table IV

Odds ratios (ORs) for high-grade ACJ dislocation

Subgroup	Comparison	OR (95% CI)
Age group, y	40–59 vs. 18–39	2.6 (1.2, 5.4)
	60–75 vs. 18–39	3.6 (0.89, 14.1)
Gender	Male vs. female	1.3 (0.43, 3.8)
Type of trauma	Traffic accident vs. fall	3.8 (1.5, 10)
	Traffic accident vs. sport	2.3 (1.1, 5.3)
	Traffic accident vs. miscellaneous	7.7 (0.74, 100)

ACJ, acromioclavicular joint; CI, confidence interval.

Calculations using adjusted logistic regression model including all subgroups.

**Table V**  
Trauma mechanisms and the distribution of low-/high-grade dislocations

Type of trauma	Total, %	Low-grade injury, %	High-grade injury, %
Activities			
Total	157	72 (46)	85 (54)
Soccer	19 (12)	11 (15)	8 (9)
Martial arts	11 (7)	8 (11)	3 (4)
Skiing	9 (6)	3 (4)	6 (7)
Bicycle sport	8 (5)	4 (6)	4 (5)
Ice hockey	6 (4)	4 (6)	2 (2)
Floorball	4 (3)	2 (3)	2 (2)
Horseback riding	5 (3)	1 (1)	4 (5)
Rugby/American football	3 (2)	1 (1)	2 (2)
Parkour	1 (1)	1 (1)	0
Bicycle transport	29 (19)	5 (7)	24 (28)
Motorcycle/moped	16 (10)	5 (7)	11 (13)
Car	4 (3)	2 (3)	2 (2)
Other traffic accident	5 (3)	3 (4)	2 (2)
Falls	32 (20)	18 (25)	14 (17)
Miscellaneous	5 (3)	4 (6)	1 (1)
Type of trauma subgroups			
Sports	66 (42)	35 (49)	31 (37)
Traffic accidents	54 (34)	15 (21)	39 (46)
Falls	32 (20)	18 (25)	14 (17)
Miscellaneous	5 (3)	4 (6)	1 (1)

Values are number of cases in each group. Other traffic accidents include segway, kickbike, and longboard. Miscellaneous includes, for example, getting hit by door caught by wind and failing to stand on one's hands.

dislocations than those occurring during sports or from falls. A possible reason for these differences in results may be our subgrouping of the patients according to Rockwood classification into low-grade (type 1 and 2) and high-grade (type 3–6) injuries. This subgrouping was clinically logical, as low-grade injuries are not proper dislocations and always treated conservatively, whereas high-grade injuries represent a complete dislocation of the ACJ and surgery may be considered for certain patients.<sup>12</sup> Comparing subgroups increased the ability to detect relevant relationships between the different variables.

ACJ dislocations are predominantly caused by a direct trauma to the shoulder and therefore common in activities such as contact or high-speed sports and traffic situations. Chillemi et al<sup>2</sup> were the first to report on the distribution of the type of trauma from a general population. Similar to our study, they found sports to be the most common mechanism, but the types of sports differed somewhat between our studies, probably because of local tradition and geographical differences. For example, we had injuries from both skiing and ice hockey, whereas Chillemi et al reported cases caused by rollerblades and basketball.

In both studies, more than 1 of 5 patients were injured during bicycling, and this appears to be a particularly high-risk activity with regard to the severity of the injury. Seventy-six percent of the bicycle-related cases were high-grade injuries in our study. We also showed that the traffic accidents subgroup had a higher risk of high-grade injury, and in this group 54% of the cases were caused by cycling. Other research has also shown that ACJ dislocations are common during cycling.<sup>4</sup>

This study has both strengths and weaknesses. Important strengths of the study include the prospective design and well-controlled method for diagnosing and classifying the injuries. A significant weakness of the study is that the inclusion is probably incomplete, caused by patients with ACJ dislocations eligible for the study not seeking care or not being referred to our department. Supporting this is that Enger et al<sup>3</sup> showed a much higher incidence of low-grade injuries compared to our results and the fact that conspicuously few patients from the major elite ice hockey and soccer teams in our catchment area were included in our study. The

**Table VI**  
Type of trauma per age group

Age group	Sports, %	Traffic accidents, %	Falls, %	Miscellaneous, %
18–39 (n = 82)	45 (55)	22 (27)	11 (13)	4 (5)
40–59 (n = 61)	20 (33)	25 (41)	15 (25)	1 (2)
60–75 (n = 14)	1 (7)	7 (50)	6 (43)	0

Values are total number of cases in each subgroup.

incidence presented should therefore be considered as the minimal true incidence. Further, patients in Sweden are allowed to seek care where they please, and the catchment area is located in a densely populated part of Sweden where commuting is common. It is therefore possible that patients from other catchment areas have chosen to seek care at our institution. We have not excluded these patients as the probability of the opposite, a patient from our area seeking care elsewhere, should be similar. We also limited our inclusion to people between 18–75 years. This was done for both practical reasons and the fact that ACJ dislocations in the skeletally immature have different pathoanatomy than in adults, and existing data indicate that the injuries are uncommon in younger people and virtually nonexistent in those older than 75 years.<sup>1–3</sup>

## Conclusion

The incidence of ACJ dislocations was 2.0 per 10,000 person-years in a general adult population. Male gender and young age were risk factors, and most injuries occurred during sports. However, the risk of high-grade dislocations was higher in older patients and when injured in traffic accidents.

## Acknowledgments

The authors thank the shoulder physiotherapists at Helsingborg hospital for their hard work and commitment; Peter Bengtsson, medical student, for help with data compilation and analysis; and the foundations Thelma Zoégas fond för medicinsk forskning and Stig och Ragna Gorthons stiftelse for funding the study.

## Disclaimer

The study has been supported by research grants from the foundations Thelma Zoégas fond för medicinsk forskning and Stig och Ragna Gorthons stiftelse.

The authors, their immediate families, and any research foundations with which they are affiliated have not received any financial payments or other benefits from any commercial entity related to the subject of this article.

## References

- Bishop JV, Flatow EL. Pediatric shoulder trauma. Clin Orthop Relat Res 2005; 41–8. <https://doi.org/10.1097/01.blo.0000156005.01503.43>.
- Chillemi C, Franceschini V, Giudici LD, Alibardi A, Santone PS, Ramos Alday IJ, et al. Epidemiology of isolated acromioclavicular joint dislocation. Emerg Med Int 2013;2013:171609. <https://doi.org/10.1155/2013/171609>.
- Enger M, Skjaker SA, Melhuus K, Nordsletten L, Pripp AH, Moosmayer S, et al. Shoulder injuries from birth to old age: a 1-year prospective study of 3031 shoulder injuries in an urban population. Injury 2018;49:1324–9. <https://doi.org/10.1016/j.injury.2018.05.013>.
- Goldstein Y, Dolikart O, Kaufman E, Amar E, Sharfman ZT, Rath E, et al. Bicycle-related shoulder injuries: etiology and the need for protective gear. Isr Med Assoc J 2016;18:23–6.
- Gorbaty JD, Hsu JE, Gee AO. Classifications in brief: Rockwood classification of acromioclavicular joint separations. Clin Orthop Relat Res 2017;475:283–7. <https://doi.org/10.1007/s11999-016-5079-6>.
- Headley J, Brooks JH, Kemp SPT. The epidemiology of shoulder injuries in English professional rugby union. Am J Sports Med 2007;35:1537–43. <https://doi.org/10.1177/0363546507300691>.

7. McCall D, Safran MR. Injuries about the shoulder in skiing and snowboarding. *Br J Sports Med* 2009;43:987–92. <https://doi.org/10.1136/bjsm.2009.068767>.
8. Melvin PR, Souza S, Mead RN, Smith C, Mulcahey MK. Epidemiology of upper extremity injuries in NCAA men's and women's ice hockey. *Am J Sports Med* 2018;46:2521–9. <https://doi.org/10.1177/0363546518781338>.
9. Melvin PR, Souza S, Mead RN, Smith C, Mulcahey MK. Epidemiology of upper extremity injuries in NCAA men's and women's ice hockey: addendum. *Am J Sports Med* 2018;46:NP69–72. <https://doi.org/10.1177/0363546518800700>.
10. Nordqvist A, Petersson CJ. Incidence and causes of shoulder girdle injuries in an urban population. *J Shoulder Elbow Surg* 1995;4:107–12.
11. Rockwood AC Jr. Subluxations and dislocations about the shoulder: injuries to the acromioclavicular joint. In: Rockwood Jr AC, Green DP, editors. *Fractures in adults*. Philadelphia: JB Lippincott; 1984. p. 860–910.
12. Tauber M. Management of acute acromioclavicular joint dislocations: current concepts. *Arch Orthop Trauma Surg* 2013;133:985–95. <https://doi.org/10.1007/s00402-013-1748-z>.
13. Tummala SV, Hartigan DE, Patel KA, Makovicka JL, Chhabra A. Shoulder injuries in National Collegiate Athletic Association quarterbacks: 10-year epidemiology of incidence, risk factors, and trends. *Orthop J Sports Med* 2018;6: 2325967118756826. <https://doi.org/10.1177/2325967118756826>.




## Paper II







# Weighted or internal rotation radiographs are not useful in the classification of acromioclavicular joint dislocations

Acta Radiologica  
0(0) 1–8  
© The Foundation Acta Radiologica  
2020  
Article reuse guidelines:  
sagepub.com/journals-permissions  
DOI: 10.1177/0284185120939270  
journals.sagepub.com/home/acr  


Jonas S Nordin<sup>1</sup> , Felicia Mogianos<sup>2</sup>, Anders Hauggaard<sup>3</sup> and Karl Lunsjö<sup>1</sup>

## Abstract

**Background:** Weighted radiographs are performed to classify acromioclavicular joint dislocations; however, the evidence regarding their usefulness is conflicting. Laboratory studies suggest that internal rotation views can replace weighted radiographs, but this has not been clinically evaluated.

**Purpose:** To evaluate whether weighted or internal rotation radiographs uncovers more high-grade acromioclavicular joint dislocations than non-weighted radiographs.

**Material and Methods:** A total of 162 patients with acromioclavicular joint dislocations were prospectively included. After applying exclusion criteria, 140 remained. Three panorama radiographs, including both coracoclavicular intervals, were completed of each participant: first, a weighted radiograph with 5-kg weights suspended from the wrists; second, a non-weighted radiograph; and third, an internal rotation radiograph. The coracoclavicular intervals were measured by two radiologists independently, and measurements were translated into Rockwood classifications. The classifications and measurements derived from the different radiographic views were compared.

**Results:** Weighted radiographs caused no significant changes in classification. For the internal rotation views, there was a significant change in classification for radiologist 2; however, the reason was that more injuries were downgraded compared to the non-weighted views. Relative to the non-weighted radiographs, the mean increase of the coracoclavicular interval on the injured side in the weighted view was 0.5 mm (95% confidence interval [CI] 0.37–0.65) and in the internal rotation view 0.2 mm (95% CI 0.04–0.33). While these changes were statistically significant, they were small and not clinically important.

**Conclusion:** This study does not support the use of weighted and internal rotation radiographs in the classification of acromioclavicular joint dislocations.

## Keywords

Conventional radiography, shoulder, joints, athletic injuries, trauma, comparative studies

Date received: 20 March 2020; accepted: 2 June 2020

## Introduction

Acromioclavicular joint (ACJ) dislocations account for up to 10% of shoulder injuries and primarily affect patients of working age (1). Most of these injuries can be treated conservatively with good results but for some patients, especially those with high grade dislocations, surgical treatment is indicated (2).

The Rockwood classification is the most widely used classification system for ACJ injuries today.

<sup>1</sup>Department of Orthopedics, Helsingborg Hospital, Lund University, Helsingborg, Sweden

<sup>2</sup>Halland Hospital Halmstad, Halmstad, Sweden

<sup>3</sup>Radiology Department, Helsingborg Hospital, Lund University, Helsingborg, Sweden

### Corresponding author:

Jonas S Nordin, Ortopedmottagningen, Helsingborgs lasarett, Charlotte Yhlens gata 10, 251 87 Helsingborg, Sweden.  
Email: jonas.nordin@med.lu.se

It categorizes the dislocations into six types according to the extent of injury to the structures stabilizing the joint. These structures are assumed to be disrupted sequentially in the following order: the acromioclavicular (AC) ligaments; the coracoclavicular (CC) ligaments; and, finally, the deltatrapezoidal fascia (Table 1) (3). The distance between the superior coracoid process and the inferior clavicle, the CC interval, is measured bilaterally on radiographs and used to assess vertical instability. The increase of this distance on the injured side compared to the healthy one is considered to correlate with the extent of the injury to the stabilizing soft tissues and used to classify the injury (3,4).

It has been suggested that radiographs with weights suspended from the patients' arms are necessary to counteract muscle spasms about the shoulder and reveal the true vertical instability of the injured ACJ joint, thus increasing the accuracy of the classification (5,6). Historically such images have been widely recommended in the literature (7,8). Today, surveys have shown that the use of weighted radiographs is decreasing among American shoulder surgeons (9,10); however, these are still used internationally and, by some, recommended (11–13). The evidence regarding weighted radiographs is controversial with only two previous studies with contradictory conclusions available (12,14).

Horizontal instability of the injured ACJ has been shown to affect outcome and many radiographic techniques have been proposed to evaluate the position of the clavicle in the anteroposterior (AP) plane. However, the optimal method is still debated, and, to date, there is no validated gold standard (5,6,13,15–18).

Radiographs with the shoulders in internal rotation have been studied in cadaver models and results show that this technique might replace weighted views when

searching for occult high-grade ACJ dislocations. The proposed mechanism is that internal rotation in the shoulder protracts the scapula moving the acromion towards the clavicle which, in turn, is pushed superiorly (19). The efficacy of internal rotation radiographs has not been confirmed in a clinical study.

The aim of the present study was to evaluate whether weighted or internal rotation radiographs are useful in the classification of ACJ dislocations by investigating if they uncover more high-grade dislocations than standard non-weighted radiographs.

## Material and Methods

### Participants

This cross-sectional, single center study was performed between January 2013 and October 2016. The study was approved by the Regional Ethical Review Board in Lund (Dnr 2012/454) after input from the regional committee for radiation safety. A total of 162 patients were prospectively identified as eligible for this study. Inclusion criteria were as follows: aged 18–75 years; shoulder trauma within the last 14 days; radiographic examination that excluded fracture; and a clinical suspicion of an ACJ dislocation. Exclusion criteria were as follows: previous ACJ dislocation on either side; clavicle fracture malunion on either side; other ongoing shoulder problems; and mental disorders or language barriers preventing the patient from understanding or cooperating with study protocol.

After primary assessment and initiation of treatment at the emergency department or primary care facility, patients eligible for the study were referred to our shoulder physiotherapists who confirmed the suspicion

**Table 1.** The Rockwood classification system.

Rockwood type	AC ligaments	CC ligaments	Deltotrapezoidal fascia	Radiographs	Clinical examination of ACJ
1	Intact or partial injury	Intact	Intact	Normal	Stable
2	Torn	Intact or partial injury	Intact	Normal or widening of ACJ and/or <25% increase in CC distance	Horizontal instability
3	Torn	Torn	Lateral avulsion	25%–100% increase in CC distance	Horizontal and vertical instability
4	Torn	Torn	Dorsal injury	Increased or normal CC distance. Possibly visible on lateral or axillary view	Large horizontal instability
5	Torn	Torn	Torn	>100% increased CC distance	Horizontal and large vertical instability
6	Torn	Torn	Torn	Inferior dislocation of clavicle	High risk of neurovascular insult

AC, acromioclavicular; ACJ, acromioclavicular joint; CC, coracoclavicular.

of an ACJ dislocation and secured informed written consent. Radiographic examination according to the study protocol was ordered by the physiotherapist.

After completion of radiographs, the patients were seen by one of four orthopedic surgeons involved in the study who confirmed the diagnosis and, if needed, amended the treatment received after the primary assessment. Five patients did not complete either the radiographs or the visit to the orthopedic surgeon and a further 17 patients were excluded (Fig. 1). This left 140 patients (123 [88%] men; mean age = 40 years; age range = 18–74 years) and the dominant shoulder was injured in 83 (59%).

### Radiographic examinations

The examinations were performed in a standardized fashion with the patients standing, their scapulae supported against a vertical surface, and their feet shoulder width apart. The patients did not move between exposures and were asked to relax the muscles in their upper body. Three panorama radiographs with a 10° cephalic tilt including both CC intervals were taken. A lead shield was used for thyroid protection. First, a weighted view was taken using bilateral 5-kg weight bracelets attached to the patients' wrists. The patients remained in position and the radiographer removed the weights and obtained a non-weighted radiograph. After this, an internal rotation radiograph was obtained where the patients' hands were both positioned on the abdomen (Fig. 2). This order of performing the radiographs minimized patient movement and produced as similar projections as possible.

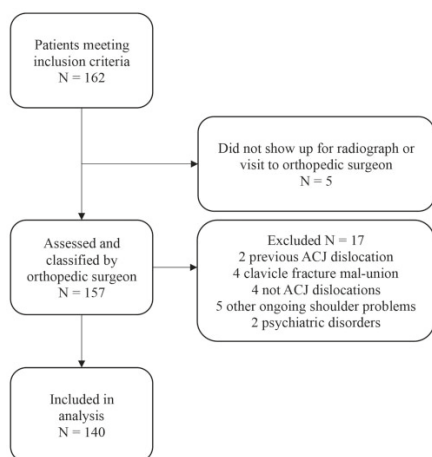


Fig. 1. Flow chart describing inclusion of patients.

Two senior radiologists assessed all the radiographs and the CC intervals were measured bilaterally. This interval was defined as the closest distance between the superior margin of the coracoid process and the inferior clavicle cortex. Measurements were performed using the digital ruler in the image viewing software (Sectra PACS, Sectra AB, Sweden) of the department and registered in millimeters. The difference between the CC interval on the injured side and the non-injured side was calculated in percent and measurements were translated into a Rockwood classification according to the following definition: an increase of <25% on the injured side was classified as a low-grade ACJ dislocation, a group that included both Rockwood type 1 and type 2 injuries since they cannot be accurately separated without a clinical examination; an increase of 25%–100% was classified as a Rockwood type 3 ACJ dislocation; and an increase of >100% was classified as type 5.

Rockwood type 4 injuries were diagnosed using clinical examination during the visit to the orthopedic surgeon; three patients were found to have this type of injury and were treated accordingly. For study purposes, they were included in the material and their radiographs were reviewed as described above.

There were no Rockwood type 6 dislocations in our material.

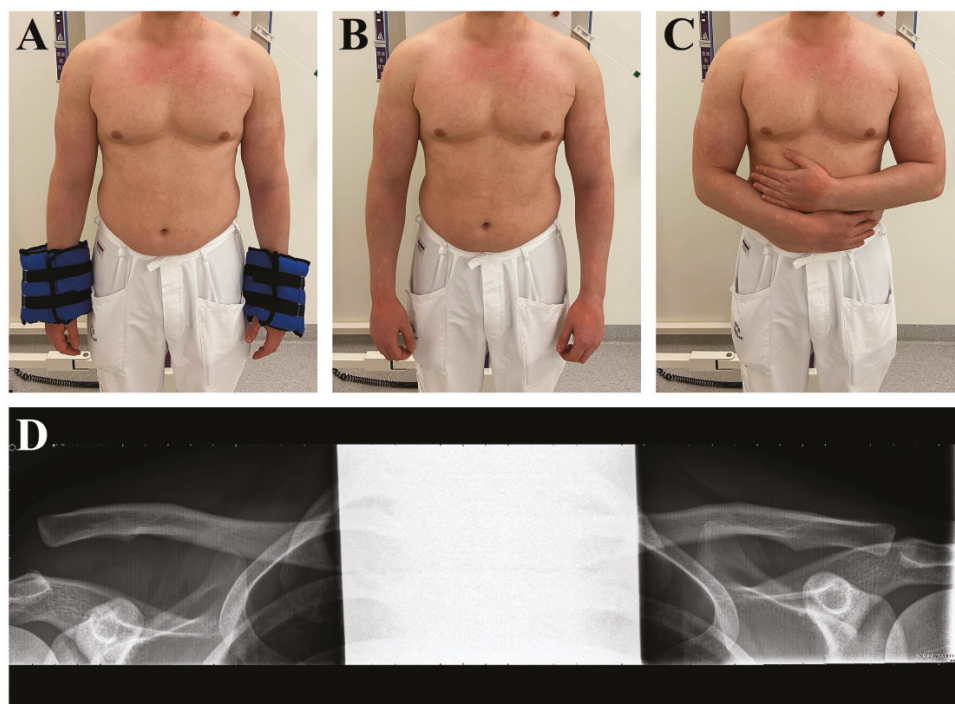
### Outcome measurements

The classifications acquired from the different radiographic projections were compared. The non-weighted view was used as a baseline and any differences in classification in the other radiographs were registered. Where a change in classification was noted, the measurements of the CC interval on all the radiographs were examined to determine the cause of the change (CC interval decreased or increased on the injured or uninjured side); a measurement was considered to have changed if the difference between radiographs was  $\geq 0.2$  mm.

To further analyze the effects of weighted and internal rotation views, the measurements of the CC intervals on the injured sides were compared between the three radiographs for each patient.

### Statistics

Wilcoxon signed rank test was used to analyze if there was a difference in classification between the different radiographic projections. A mixed model linear regression calculation was used to compare the measurements of the CC intervals of the injured shoulders between radiographic projections. All statistical calculations were made using SAS 9.4 (SAS Institute Inc., Cary, NC, USA). 95% CIs were used and  $P < 0.05$  was



**Fig. 2.** Photographs showing patient positioning for the weighted (a), non-weighted (b), and internal rotation (c) panorama radiographs. Example non-weighted radiograph (d).

**Table 2.** Patients (n) with each Rockwood type.

Rockwood type	Non-weighted view (n = 138)		Weighted view (n = 137)		Internal rotation view (n = 128)	
	Radiologist 1	Radiologist 2	Radiologist 1	Radiologist 2	Radiologist 1	Radiologist 2
Low grade	52	52	52	54	54	56
Type 3	47	45	47	41	35	35
Type 5	39	41	38	42	39	37

considered statistically significant. Original data can be accessed by reasonable demand to the corresponding author.

## Results

Radiographs were obtained at a mean of 16 days (range = 2–68 days) after the injury; 10 (7%) patients were radiographed later than 30 days and 2 (1%) patients later than 40 days after the injury. One patient was only able to complete the non-weighted view due to pain and one had incorrectly marked radiographs;

these could not be included in the analysis. In 11 patients only two radiographic projections were available; in one of these cases, the weighted radiograph was missing, and for the remaining 10, the internal rotation radiograph was missing. This left 403 radiographs in 138 patients to be interpreted.

The distribution of different grades sorted by radiographic view and radiologist is shown in Table 2. The three patients diagnosed with Rockwood type 4 ACJ dislocations based on clinical examination were all interpreted as a type 3 or type 5 in the study radiographs.

Comparing the weighted and internal rotation radiographs to the non-weighted views, the classifications remained unchanged in a majority of cases (Fig. 3). The number of cases upgraded versus downgraded in the weighted views were similar. Internal rotation caused more downgrades than upgrades; for radiologist 2, this difference in classification reached statistical significance ( $P = 0.015$ ).

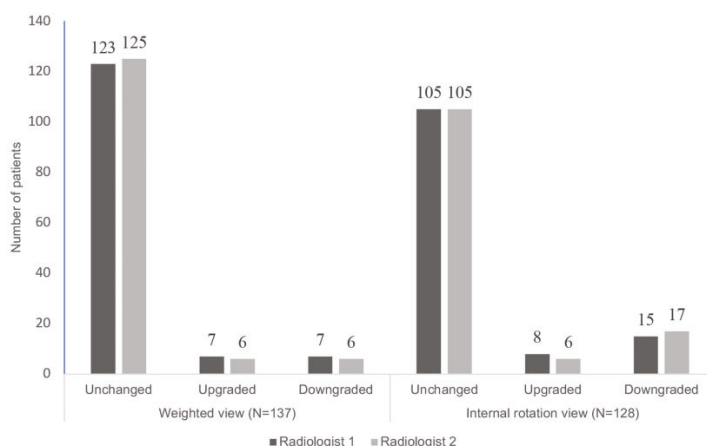
The changes in classification observed were between adjacent Rockwood types in all cases but one, where a type 5 injury in the non-weighted view was defined as low-grade in the internal rotation radiograph (Table 3). The mechanisms behind the changes in classifications were analyzed and we found that all theoretically possible reasons were represented, i.e. weighted and internal rotation views did not only affect the CC distance in the injured shoulder but also caused changes on the contralateral side and, in some cases, lead to a decrease in CC distance (Table 4).

Using the non-weighted views as baseline and comparing to the other radiographic projections, the change of the measurements of the injured CC intervals was investigated. For the weighted views, there was a mean increase of 0.5 mm (95% CI = 0.37–0.65) and for the internal rotation views 0.2 mm (95% CI = 0.04–0.33).

## Discussion

In the present study, we showed that weighted and internal rotation radiographs are not helpful in uncovering occult high-grade ACJ dislocations and therefore not useful in clinical decision-making.

Weighted radiographic images for the classification of ACJ dislocations have been recommended historically and are still in use today (3,7,8,11,13). However, there are only two previous studies investigating whether they are diagnostically helpful (12,14). In the first of



**Fig. 3.** Graph showing the distribution of changes in classification sorted by radiologist and radiographic view. The non-weighted views are used as baseline.

**Table 3.** Patients (n) with a change in classification using non-weighted radiographs as baseline.

	Weighted view (n = 137)		Internal rotation view (n = 128)	
	Radiologist 1	Radiologist 2	Radiologist 1	Radiologist 2
<i>Upgraded total</i>	7	6	8	6
Low grade to type 3	4	1	3	2
Type 3 to type 5	3	5	5	4
<i>Downgraded total</i>	7	6	15	17
Type 3 to low grade	4	3	10	9
Type 5 to type 3	3	3	5	7
Type 5 to low grade	0	0	0	1

**Table 4.** Reasons for upgrades and downgrades separated by radiologist and radiographic view.

	Weighted view		Internal rotation view	
	Radiologist 1	Radiologist 2	Radiologist 1	Radiologist 2
<i>Upgraded total</i>	7	6	8	6
CC interval increased injured side	3	3	4	1
CC interval decreased uninjured side	1	1	2	1
Combination	3	2	2	4
<i>Downgraded total</i>	7	6	15	17
CC interval decreased injured side	2	0	3	1
CC interval increased uninjured side	4	5	6	10
Combination	1	1	6	6

Values are given as n.

CC, coracoclavicular.

these, Bossart et al. (14) studied 83 pairs of bilateral weighted and non-weighted radiographs from patients with ACJ dislocation as their discharge diagnosis. Similar to our study, 10-lb (4.5-kg) weights were used, and they were either suspended from the wrists or held by the patient. The injuries were classified as grade 1, 2, or 3, where the lower grades had a normal CC interval on the injured side while it was increased by  $\geq 5$  mm or  $\geq 50\%$  in grade 3 injuries. Both upgrades and downgrades were found with weighted radiographs and, like us, they noted that the CC interval of both the injured and non-injured side could be affected by adding weights and that it sometimes paradoxically narrowed in the stress views. They conclude that weighted views should not be routinely used in the diagnosis of ACJ dislocations. Despite the differences in study design and classification system, our results support this conclusion.

The second study was published by Ibrahim et al. (12) and reaches a different conclusion. They retrospectively identified 59 sets of bilateral radiographs with and without 5-kg handheld weights and found that weighted views unmasked 10 Rockwood type 5 injuries classified as type 3 in non-weighted radiographs. Furthermore, the weighted views did not cause any downgrades or any upgrades from Rockwood type 2 to type 3. The authors recommend that weighted radiographs are used as the only AP projections for ACJ dislocations and emphasize that they are important to correctly diagnose type 5 injuries.

Our findings do not support this conclusion, as we found no significant difference in classification between weighted and non-weighted radiographs. This discrepancy in results can be partly explained by a difference in study design. Ibrahim et al. (12) retrospectively included patients that had bilateral weighted and non-weighted Zanca views and excluded those that did not have radiographic evidence of an ACJ injury. This would exclude many patients with Rockwood type

1 and 2 injuries, making it difficult to draw any conclusions regarding the ability of a weighted radiograph to unmask a Rockwood type 3 injury diagnosed as low-grade in non-weighted images. However, this does not explain why Ibrahim et al. found 10 out of 27 type 3 injuries to be upgraded and found no downgrades at all. In our material, the two radiologists found 3/47 and 5/45 type 3 injuries, respectively, to be upgraded to type 5 and as many downgrades as upgrades in the weighted radiographs compared to the non-weighted.

While evidence regarding weighted radiographs has been unclear, their use seems to have declined (9,10). In 1999, Yap et al. (9) conducted a survey where 105 members of the American Shoulder and Elbow Surgeons answered questions regarding their use of imaging for ACJ dislocations. Of them, 43% answered that they used weighted views; however, out of these, only 49% would change their initial treatment choice if weighted radiographs lead to a change in classification. In 2018, Shaw et al. (10) performed a similar study where 37 Sports Medicine and Shoulder and Elbow fellowship trained members of the Society of Military Orthopedic Surgeons responded to an online survey. Only 14% preferred to use weighted views in their clinic; however, 73% reported that these images were routinely obtained at their hospital, ordered by other providers. Both of these studies reported the subjective opinions of the participants, and the authors stress that further objective research is necessary. With the present study, we provide evidence to support the trend of a decreasing demand for weighted radiographs in the classification of ACJ dislocations.

In an attempt to further refine diagnostics, Vanarthos et al. (19) undertook a cadaver study and showed that radiographs taken with the shoulder in internal rotation were as effective as weighted radiographs in increasing the CC interval in injuries with complete tears of both the AC and CC ligaments. The authors suggest that internal rotation views are



useful in diagnosing occult high-grade injuries and that this needs to be further evaluated. In our clinical study, we found no evidence to support these findings. On the contrary, one of our radiologists found significantly more low-grade injuries in the internal rotation radiographs compared to the non-weighted images.

Comparing the classifications derived from the different radiographic projections is not the only way of analyzing our material. One could also compare the measurements of only the injured CC intervals between images to see the effects of the weights or internal rotation on the injured ACJ. This would allow illogical findings, such as the CC interval being affected on the non-injured side or paradoxically narrowed on the injured side, to be ignored. To evaluate if this way of using the radiographs would more accurately reveal vertical instability, we analyzed how the measurements of the CC intervals of the injured shoulders changed between the radiographs of each patient. When compared with non-weighted views, we found that both weighted and internal rotation radiographs caused an increase of the CC interval by a mean of 0.5 mm and 0.2 mm, respectively. This increase was statistically significant but so small it should be considered clinically irrelevant and arguably within the margin of error. It would cause a change in classification only if the patient was already near the cut-off between different Rockwood types. In such cases, it is our standpoint that the radiological classification of the injury is less important than other patient characteristics and clinical findings when deciding on treatment regime. Therefore, we do not find a rationale for this use of weighted or internal rotation views.

In the present study, we provide evidence regarding the appropriate evaluation of the vertical instability of ACJ dislocations. This is the only prospective study on the subject, and we present a large patient material; however, the study also has weaknesses. First, 17 radiographs were either missing or incorrectly marked. When designing the study, measures were taken to avoid this by using specifically chosen, and experienced, radiology nurses and appropriate patient information, but these types of human errors are difficult to completely prevent in prospective research. Furthermore, the interval of time from the day of the injury until study radiographs were obtained was quite large, 2–68 days with a mean of 16 days. While this could have affected our results as muscle shielding might diminish as pain subsides, it reflects daily clinical practice. It is also hard to predict how a change in muscle shielding would manifest itself in terms of classification. As treatment had already been initiated during the primary visit, we chose not to have a time limit for when the study radiographs were to be completed since this would risk a skewed exclusion of patients with low-grade injuries as they do not always

feel the need to attend the earliest available time at the department of radiology. Another weakness of the study is that we did not use radiographs to assess the horizontal instability of the ACJ. Instability in this plane is important to consider as it affects outcome but there is no consensus on which radiographic technique should be used (5,6,13,15–18). As the aim of the present study was to analyze the usefulness of weighted and internal rotation views and not evaluate the classification system in a broader sense, we do not believe that this makes our results less reliable.

In conclusion, we found no evidence supporting the use of weighted or internal rotation radiographs in the classification of ACJ dislocations and we recommend that these are not routinely used.

### Acknowledgements

The authors thank consultant radiologist Dr. Karin Wattsgård for her valuable work and advice.

### Declaration of conflicting interests

The authors declare no potential conflicts of interest with respect to the research, authorship, and/or publication of this article.

### Funding

The authors received the following financial support for the research, authorship, and/or publication of this article: The study has been supported by research grants from the foundations Thelma Zoëgas fond för medicinsk forskning and Stig och Ragna Gorthons stiftelse.

### ORCID iD

Jonas S Nordin  <https://orcid.org/0000-0003-1343-6260>

### References

1. Enger M, Skjaker SA, Melhuus K, et al. Shoulder injuries from birth to old age: a 1-year prospective study of 3031 shoulder injuries in an urban population. *Injury* 2018; 49:1324–1329.
2. Tauber M. Management of acute acromioclavicular joint dislocations: current concepts. *Arch Orthop Trauma Surg* 2013;133:985–995.
3. Rockwood AC Jr. Subluxations and dislocations about the shoulder: injuries to the acromioclavicular joint. In: Rockwood AC, Jr, Green DP, editors. *Fractures in adults*. 2nd edn. Philadelphia, PA: JB Lippincott Company, 1984:860–910.
4. Gorbaty JD, Hsu JE, Gee AO. Classifications in brief: Rockwood classification of acromioclavicular joint separations. *Clin Orthop Relat Res* 2017;475:283–287.
5. Beitzel K, Mazzocca AD, Bak K, et al. ISAKOS upper extremity committee consensus statement on the need for diversification of the Rockwood classification for acromioclavicular joint injuries. *Arthroscopy* 2014;30:271–278.



6. Pogorzelski J, Beitzel K, Ranuccio F, et al. The acutely injured acromioclavicular joint – which imaging modalities should be used for accurate diagnosis? A systematic review. *BMC Musculoskelet Disord* 2017;18:515.
7. Allman FL Jr. Fractures and ligamentous injuries of the clavicle and its articulation. *J Bone Joint Surg Am* 1967;49:774–784.
8. Post M. Current concepts in the diagnosis and management of acromioclavicular dislocations. *Clin Orthop Relat Res* 1985;200:234–247.
9. Yap JLL, Curl LA, Kvitne RS, et al. The value of weighted views of the acromioclavicular joint – Results of a survey. *Am J Sports Med* 1999;27:806–809.
10. Shaw KA, Synovec J, Eichinger J, et al. Stress radiographs for evaluating acromioclavicular joint separations in an active-duty patient population: what have we learned? *J Orthop* 2018;15:159–163.
11. Kim AC, Matcuk G, Patel D, et al. Acromioclavicular joint injuries and reconstructions: a review of expected imaging findings and potential complications. *Emerg Radiol* 2012;19:399–413.
12. Ibrahim EF, Forrest NP, Forester A. Bilateral weighted radiographs are required for accurate classification of acromioclavicular separation: an observational study of 59 cases. *Injury* 2015;46:1900–1905.
13. Minkus M, Hann C, Scheibel M, et al. Quantification of dynamic posterior translation in modified bilateral Alexander views and correlation with clinical and radiological parameters in patients with acute acromioclavicular joint instability. *Arch Orthop Trauma Surg* 2017;137:845–852.
14. Bossart PJ, Joyce SM, Manaster BJ, et al. Lack of efficacy of ‘weighted’ radiographs in diagnosing acute acromioclavicular separation. *Ann Emerg Med* 1988;17:20–24.
15. Rahm S, Wieser K, Spross C, et al. Standard axillary radiographs of the shoulder may mimic posterior subluxation of the lateral end of the clavicle. *J Orthop Trauma* 2013;27:622–626.
16. Tauber M, Koller H, Hitzl W, et al. Dynamic radiologic evaluation of horizontal instability in acute acromioclavicular joint dislocations. *Am J Sports Med* 2010;38:1188–1195.
17. Gastaud O, Raynier JL, Duparc F, et al. Reliability of radiographic measurements for acromioclavicular joint separations. *Orthop Traumatol Surg Res* 2015;101:291–295.
18. Aliberti GM, Kraeutler MJ, Trojan JD, et al. Horizontal instability of the acromioclavicular joint: a systematic review. *Am J Sports Med* 2020;48:504–510.
19. Vanarathos WJ, Ekman EF, Bohrer SP. Radiographic diagnosis of acromioclavicular joint separation without weight bearing: Importance of internal rotation of the arm. *AJR Am J Roentgenol* 1994;162:120–122.

## Paper IV





# Chronic acromioclavicular joint dislocations treated by the GraftRope device

## A prospective trial halted prematurely due to a high rate of complications

Jonas S NORDIN, Knut E AAGAARD, and Karl LUNSJÖ

Department of Orthopedics, Helsingborg Hospital, Sweden.

Correspondence: karl.lunsjo@skane.se

Submitted 2014-06-03. Accepted 2014-08-30.

**Background and purpose** — Surgical treatment of chronic acromioclavicular joint dislocations is challenging, and no single procedure can be considered to be the gold standard. In 2010, the GraftRope method (Arthrex Inc., Naples, FL) was introduced in a case series of 10 patients, showing good clinical results and no complications. We wanted to evaluate the GraftRope method in a prospective consecutive series.

**Patients and methods** — 8 patients with chronic Rockwood type III–V acromioclavicular joint dislocations were treated surgically using the GraftRope method. The patients were clinically evaluated and a CT scan was performed to assess the integrity of the repair.

**Results and interpretation** — In 4 of the 8 patients, loss of reduction was seen within the first 6 weeks postoperatively. A coracoid fracture was the reason in 3 cases and graft failure was the reason in 1 case. In 3 of the 4 patients with intact repairs, the results were excellent with no subjective shoulder disability 12 months postoperatively. It was our intention to include 30 patients in this prospective treatment series, but due to the high rate of complications the study was discontinued prematurely. Based on our results and other recent reports, we cannot recommend the GraftRope method as a treatment option for chronic acromioclavicular joint dislocations.

Surgical treatment of acromioclavicular joint (ACJ) dislocation sequelae is challenging, and no single procedure has been widely accepted as the gold standard. We have used both the modified Weaver and Dunn procedure, wire loops and hook plates. All gave acceptable results in many patients but there was also a high frequency of complications, as has been reported in numerous publications (Taft et al. 1987,

Bishop and Kaeding 2006, Mazzocca et al. 2007, Tamaoki et al. 2010).

In 2010, the GraftRope technique (Arthrex Inc. Naples, FL) was described and promising early results in a series of 10 patients were presented (DeBerardino et al. 2010). The GraftRope device is a double endobutton construct held together by a continuous #5 FiberWire suture. A 12- to 15-cm tendon graft is double-folded and included in the device. The whole construct is then passed through—and secured—in a transclavicular, transcoracoid bone tunnel resembling the path of the coracoclavicular (CC) ligaments. The endobutton and FiberWire construct augments the repair, allowing the tendon graft to heal into place.

To our knowledge, there have been no prospective evaluations of the GraftRope method. Our aim was to include 30 patients treated with the GraftRope method in a prospective series with 2-year follow-up.

### Patients and methods

From March 2011 to April 2012, we had operated on 8 patients with chronic, Rockwood type-III and type-V ACJ dislocations using the GraftRope method. The median age of the patients was 39 (22–63) years; 6 patients were men.

Inclusion criteria were: (1) chronic Rockwood type III–V ACJ dislocation with at least 6 months of non-operative treatment with unsatisfying result, and (2) patient age between 18 and 75 years. Exclusion criteria were: (1) major concomitant shoulder injury or disease on the affected side, (2) previous ACJ dislocation on the contralateral side, and (3) a mental or physical condition such that the patient was unable to follow the postoperative rehabilitation protocol.

All patients were followed up 3, 6, and 12 months after surgery, with clinical check-ups performed by a physiotherapist. All complications were documented. Shoulder function was assessed using the Disabilities of the Arm Shoulder and Hand (DASH) score and the Constant-Murley score. A computed tomography (CT) scan was performed 12 months postoperatively to evaluate the integrity of the repair.

The study protocol (Dnr 2012/545) was approved by the regional ethical review board in Lund and the study was conducted in accordance with the Helsinki Declaration.

### Surgery

For a detailed description of the surgical technique, see Cook et al. (2012). We used the same technique except that we used a 30-degree arthroscope instead of a 70-degree one, and we performed a distal clavicle excision in all cases and not just when reduction could not be achieved otherwise. Below is a summary of the method, with emphasis on the critical details of the procedure.

All operations were performed by 3 consultant orthopedic shoulder surgeons according to the manufacturer's instructions. The patients were placed in the beach chair position and general anesthesia was given. In a bloodless field, a 3-cm incision was made on the medial side of the tuberosity of the tibia, the gracilis tendon was identified, and a 12- to 18-cm-long gracilis tendon graft was harvested. The graft was double-folded and prepared in the GraftRope construct.

Using a 30-degree arthroscope, standard diagnostic arthroscopy was performed, confirming that no other intra-articular pathology was present. The rotator cuff interval was opened and the coracoid visualized. An incision was made over the lateral clavicle and a distal clavicle excision performed. Through an anterior portal, the lower part of an aiming guide was introduced centering on the undersurface of the coracoid, the top part centering 30 mm medial to the ACJ on the clavicle. Maintaining this position, a guide wire was introduced through the drilling guide. Care was taken to place the entry and exit holes of the guide wire centrally on the top surface of the clavicle and the undersurface of the coracoid. Fluoroscopy was not used due to the good visualization of the entry and exit points of the guide wire and the fixed trajectory between these points ensured by the aiming guide.

A 6-mm cannulated drill was advanced over the guide wire to establish the transclavicular, transcoracoid bone tunnel through which the GraftRope construct was introduced. The FiberWire of the construct was tightened and tied over the clavicular button to reduce the dislocation, and an interference screw was used to secure the gracilis graft in the clavicular bone tunnel.

The shoulder was immobilized in a sling for 4 weeks, and during this time only passive range-of-motion exercises—up to 90 degrees of abduction and elevation—were performed. Thereafter, active range of motion was initiated. Strengthening exercises began 3 months postoperatively, free range of

motion was permitted, and the patients were allowed to slowly return to full activity.

### Results

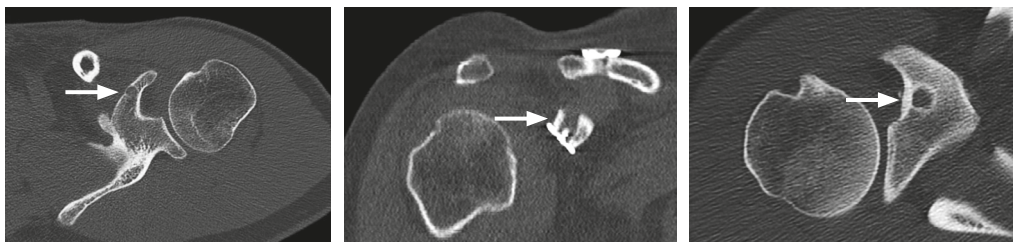
The intention in this study was to treat 30 patients, evaluate their shoulder function at 3, 6, 12, and 24 months postoperatively, and present these data along with information on the frequency of early and late complications. However, within the first year postoperatively, 4 of our 8 patients had suffered a loss of reduction. Because of this high rate of complications, the trial was halted prematurely.

The reasons for loss of reduction were a coracoid fracture in 3 cases and graft failure in 1 case. Radiographs taken immediately after surgery showed that anatomical reduction had been achieved in all patients and there were no signs of loss of reduction or coracoid fractures. All failures were noted within the first 6 weeks postoperatively. No failures were due to trauma, and there was no evidence of patients not complying with the postoperative rehabilitation protocol. 1 of the patients who suffered a loss of reduction had pain and severely impaired shoulder function, and revision surgery was required. Of the other 3 patients with failed repairs, 1 felt that the shoulder symptoms were at the same level as preoperatively, and the remaining 2 experienced improvement despite the failure of their repairs. The CT scans performed 12 months postoperatively showed that 6 of 8 patients had a non-central drill hole in the coracoid.

3 of the 4 patients who did not have any complications showed excellent results. At 1 year postoperatively, these 3 patients had returned to their pre-injury level of activity and were satisfied with their shoulder function. 1 patient in this group still experienced pain when sleeping on the injured side and when lifting the injured arm above shoulder level. This patient had, however, improved compared to preoperatively. In this group, the median DASH score was 11 (4–29) and the median Constant-Murley score was 87 (68–92) 1 year after surgery.

### Discussion

In the past decade, biomechanical research has suggested that anatomical repair with reconstruction of the ligaments supporting the ACJ is important to restore its properties. There have also been indications that biological healing of the reconstruction is important to achieve long term stability of the repair (Costic et al. 2004). The GraftRope method allows a single tendon graft to be inserted in-between drill tunnels in the clavicle and the coracoid process. This provides a biological repair that more closely mimics the native anatomy than many previous techniques (DeBerardino et al. 2010). Encouraged by the promising early results of this method, we



Postoperative computed tomography scans displaying the position of the coracoid bone tunnel (marked by a white arrow) in 3 patients. A. A mal-positioned medial tunnel breaching the medial cortex of the coracoid. B. A coronal plane view of a laterally placed bone tunnel. C. A transverse plane view of a laterally placed tunnel.

designed and started our prospective study. Our results were, however, substantially different.

Since only 8 patients were treated using this method, it is possible that the surgeon learning curve affected the outcome. However, all procedures were performed by experienced shoulder arthroscopists who had also practiced the procedure in a laboratory setting.

All but 1 of the losses of reduction were due to coracoid fracture. This leads us to assume that a 6-mm bone tunnel through the coracoid process compromises its strength sufficiently for a fracture to occur. In the CT scans performed within 1 year postoperatively, 6 of the 8 patients had a coracoid bone tunnel that was not centralized (Figure A–C). The average width of the coracoid is 15 mm, making a central tunnel placement crucial to preserve enough bone—both laterally and medially—to avoid fracture (Armitage et al. 2011). Recent biomechanical testing has supported this further, by comparing tunnel placement in cadaver shoulders. 5 different tunnel placements were tested, and load to failure was measured and compared to undrilled controls. All tunnel placements except the completely central tunnel and one with a superior medial to inferior central orientation resulted in a significantly reduced load to failure (Ferreira et al. 2012).

At drilling, the desire is to place the bone tunnel in a position originating and ending between the footprints of the 2 native CC-ligaments, thus mimicking their anatomy as much as possible. The arthroscopically assisted technique does not allow separate drilling of the coracoid and clavicle, so the positioning of one tunnel will inevitably affect the other. In a study comparing different tunnel placements in virtual models based on 3D-reconstructed CT images of the ACJ, it was shown that, using an arthroscopically assisted technique, it was not possible to achieve a near-anatomic tunnel through both the clavicle and the coracoid. The desired position of one tunnel would result in an unsatisfactory position of the other. That study also showed that the trajectory of a completely central coracoid tunnel would completely miss the clavicle in the majority of cases (Coale et al. 2013). A similar study demonstrated that separate drilling of the clavicle and coracoid is necessary to achieve near-anatomic position of the bone tun-

nels and to avoid coracoid cortical breach (Xue et al. 2013). Based on these results, as well as our own experiences, we believe that the use of 6-mm bone tunnels and non-separate drilling of the clavicle and coracoid is associated with a substantial risk of fracture or tunnel misplacement.

Our study is not the first to present adverse results in patients treated with the GraftRope method or with other methods requiring a coracoid bone tunnel. Cook et al. (2012) presented adverse results in active-duty soldiers with ACJ dislocations treated with the GraftRope method. Reduction was lost in 8 of 10 cases; in 7 of these, the reason for the failed repair was suture slippage or breakage; only 1 patient suffered a coracoid fracture. Cook and colleagues suggested that a possible reason behind their high rate of failure was that they, like us, did not use the option to let the graft tails run over the ACJ and attach to the acromion. It is possible that this could prevent suture breakage by providing extra stability to the ACJ, but it is unlikely that this extra stability would prevent coracoid fracture, which was the most common complication seen in our material.

Milewski et al. (2012) reviewed the GraftRope device further and presented a high rate of complications. In their study, 8 of 10 patients suffered a loss of reduction; both coracoid fractures and other modes of failure occurred. The authors considered transcoracoid drilling to be demanding, and possibly a procedure that not even the experienced surgeon is able to perform safely. The adverse results presented by Cook et al. (2012) and Milewski et al. (2012) were not available when we started our study.

The difficulty of transcoracoid drilling is discussed further by Schliemann et al. (2013). They treated 63 patients using a different surgical technique where the diameters of the bone tunnels were 4.5 mm. The drilling was performed using a drill guide in a straight trajectory fashion through the clavicle and coracoid. Despite the smaller diameter of the drill, 6 of the treated patients suffered a coracoid fracture.

Our study provides a detailed analysis of the difficulties of transcoracoid drilling. Based on the recent biomechanical and virtual-model research discussed above, together with the clinical and radiological follow-up of the patients in our

series, we conclude that a 6-mm bone tunnel is not a safe way to provide an anchor point in the base of the coracoid process. We cannot recommend the GraftRope device as a treatment option for chronic ACJ dislocations.

JSN: study design, data analysis, and drafting of the manuscript. KEA and KL: study design and critical revision of the manuscript. All the authors read and approved the final manuscript.

No competing interests declared.

We thank the Department of Physiotherapy, Helsingborg Hospital.

Armitage M S, Elkinson I, Giles J W, Athwal G S. An anatomic, computed tomographic assessment of the coracoid process with special reference to the congruent-arc Latarjet procedure. *Arthroscopy* 2011; 27 (11): 1485-89.

Bishop J Y, Kaeding C. Treatment of the acute traumatic acromioclavicular separation. *Sports Med Arthrosc Rev* 2006; 14 (4): 237-45.

Coale R M, Hollister S J, Dines J S, Allen A A, Bedi A. Anatomic considerations of transclavicular-transcoracoid drilling for coracoclavicular ligament reconstruction. *J Shoulder Elbow Surg* 2013; 22 (1): 137-44.

Cook J B, Shaha J S, Rowles D J, Bottoni C R, Shaha S H, Tokish J M. Early failures with single clavicular transosseous coracoclavicular ligament reconstruction. *J Shoulder Elbow Surg* 2012; 21 (12): 1746-52.

Costic R S, Labriola J E, Rodosky M W, Debski R E. Biomechanical rationale for development of anatomical reconstructions of coracoclavicular ligaments after complete acromioclavicular joint dislocations. *Am J Sports Med* 2004; 32 (8): 1929-36.

DeBerardino T M, Pensak M J, Ferreira J, Mazzocca A D. Arthroscopic stabilization of acromioclavicular joint dislocation using the AC graftrope system. *J Shoulder Elbow Surg* 2010; 19 (2 suppl): 47-52.

Ferreira J V, Chowanec D, Obopilwe E, Nowak M D, Arciero R A, Mazzocca A D. Biomechanical evaluation of effect of coracoid tunnel placement on load to failure of fixation during repair of acromioclavicular joint dislocations. *Arthroscopy* 2012; 28 (9): 1230-36.

Mazzocca A D, Arciero R A, Bicos J. Evaluation and treatment of acromioclavicular joint injuries. *Am J Sports Med* 2007; 35 (2): 316-29.

Milewski M D, Tompkins M, Giugale J M, Carson E W, Miller M D, Diduch D R. Complications related to anatomic reconstruction of the coracoclavicular ligaments. *Am J Sports Med* 2012; 40 (7): 1628-34.

Schliemann B, Roßlenbroich S B, Schneider K N, Theisen C, Petersen W, Raschke M J, Weimann A. Why does minimally invasive coracoclavicular ligament reconstruction using a flip button repair technique fail? An analysis of risk factors and complications. *Knee Surg Sports Traumatol Arthrosc* 2013 Oct 30. [Epub ahead of print.]

Taft T N, Wilson F C, Oglesby J W. Dislocation of the acromioclavicular joint. *J Bone Joint Surg Am* 1987; 69 (7): 1045-51.

Tamaoki M J S, Belloti J C, Lenza M, Matsumoto M H, Gomes dos Santos J B, Faloppa F. Surgical versus conservative interventions for treating acromioclavicular dislocation of the shoulder in adults. *Cochrane Database of Systematic Reviews* 2010; 8: CD007429.

Xue C, Zhang M, Zheng T S, Zhang G Y, Fu P, Fang J H, Li X. Clavicle and coracoid process drilling technique for truly anatomic coracoclavicular ligament reconstruction. *Injury* 2013; 44 (10): 1314-20.

Paper V








RESEARCH ARTICLE

Open Access



# The gracilis tendon autograft is a safe choice for orthopedic reconstructive procedures: a consecutive case series studying the effects of tendon harvesting

Jonas S. Nordin<sup>1,2\*</sup> , Ola Olsson<sup>1,2</sup> and Karl Lunsjö<sup>1,2</sup>

## Abstract

**Background:** The gracilis tendon is commonly used as an autograft to reconstruct torn tendons or ligaments in many parts of the body. Little is known about the subjective and functional outcome after gracilis tendon harvest. The aim of this study was to evaluate the outcome of the donor leg in patients undergoing such surgery.

**Methods:** Patients with chronic acromioclavicular joint dislocations undergoing coracoclavicular ligament reconstructions using autogenous gracilis tendon grafts were eligible for this study. The graft harvesting procedure was carried out in a standard fashion using a tendon stripper. Knee injury and Osteoarthritis Outcome Score (KOOS) were collected preoperatively and after 12 months. The first 5 patients were included retrospectively and lacked preoperative data, for these patients age- and gender matched normative KOOS scores were used as baseline values. Isometric knee flexor strength in 60° and 90° degrees of flexion was measured at final follow up at a median of 26 (14–56) months postoperatively with the non-operated leg used as reference.

**Results:** Twenty four patients were eligible for the study and 2 were excluded. The 22 patients available for analysis had a mean age of 44 (22–62) years at the time of surgery and 4 were women. There was no statistically significant change in KOOS 12 months postoperatively compared to baseline values but the patients were weaker in knee flexion in the operated leg compared to the non-operated one.

**Conclusions:** Gracilis tendon harvesting results in a weakness of knee flexion but does not impair subjective knee function and is a procedure that can be recommended when an autogenous tendon graft is needed.

**Keywords:** Gracilis autograft, Ligament reconstruction, Coracoclavicular reconstruction, Acromioclavicular dislocation, Hamstring graft

## Background

The gracilis tendon is often used as an autograft for ligament or tendon reconstruction. Most commonly it is used in combination with the semitendinosus tendon as a hamstring graft in anterior cruciate ligament (ACL) reconstructions, but it is also frequently used in other knee reconstructive procedures as well as in shoulder, elbow, hip and ankle surgery [1–6]. While allografts are an alternative to autografts there are indications that they stretch more postoperatively and they are not

readily available in all countries [7, 8]. In 2011, at our institution, we started using gracilis autografts in coracoclavicular (CC) ligament reconstructions for treatment of chronic acromioclavicular joint dislocations [9].

While graft site morbidity and knee flexor strength after ACL reconstruction using hamstring grafts has been thoroughly studied [10, 11], there is little evidence regarding the knee related outcome after isolated gracilis tendon harvesting from a limb in which no reconstructive procedure is planned. Two studies touching on this subject concern patients undergoing primary, unilateral ACL reconstructions that were randomized with regard to which leg the hamstring graft would be harvested

\* Correspondence: [jonas.nordin@med.lu.se](mailto:jonas.nordin@med.lu.se)

<sup>1</sup>Department of Orthopedics, Helsingborg Hospital, Helsingborg, Sweden

<sup>2</sup>Faculty of Medicine, Lund University, Lund, Sweden



© The Author(s). 2019 **Open Access** This article is distributed under the terms of the Creative Commons Attribution 4.0 International License (<http://creativecommons.org/licenses/by/4.0/>), which permits unrestricted use, distribution, and reproduction in any medium, provided you give appropriate credit to the original author(s) and the source, provide a link to the Creative Commons license, and indicate if changes were made. The Creative Commons Public Domain Dedication waiver (<http://creativecommons.org/publicdomain/zero/1.0/>) applies to the data made available in this article, unless otherwise stated.

from [12, 13]. Both of these trials report that graft harvesting is associated with a decrease in knee flexor strength that is resolved within 12 months postoperatively and they do not advise against using the unaffected leg as a graft donor site.

While providing important information, the trials above studied the effect of harvesting a two-tendon hamstring autograft for use in ACL-reconstruction and these results cannot be directly translated to a situation where an isolated gracilis graft is used for reconstructive procedures in other parts of the body than the knee. After reviewing the literature we could find only one study investigating this issue in which 22 patients were retrospectively included after having undergone gracilis tendon harvesting to provide grafts for various foot and ankle procedures [1]. The patients were significantly weaker in knee flexion in the donor leg compared to the contralateral one but displayed minimal donor site morbidity.

In our study we aim to present further evidence regarding the outcome and possible morbidity related to gracilis tendon harvesting. This will allow surgeons to perform a more detailed risk-benefit analysis and patients to receive a more accurate preoperative information. Our hypothesis is that gracilis tendon harvesting leads to a weakening in knee flexion but not a reduction in subjective knee function.

## Materials and methods

This study comprised 24 consecutive patients operated between 2011 and 2016 with CC ligament reconstruction using an autogenous gracilis tendon graft. The hypothesis for this study was formulated in the end of 2011 after 5 patients had already undergone surgery, only postoperative outcome measures were available for these 5 patients and the study is therefore of combined prospective and retrospective design.

## Participants

Patients between 18 and 75 years of age with chronic, symptomatic acromioclavicular joint dislocations that were planned for CC ligament reconstruction using autogenous gracilis tendon grafts were eligible for the study. Patients were excluded if they had unresolved knee injuries, ongoing joint diseases that affected the knee, previous knee surgery, other conditions that were likely to greatly effect outcome or were unable to understand or comply with postoperative rehabilitation protocols because of mental or systemic disease. The 5 patients operated before November 2011 were retrospectively included and preoperative outcome measures are therefore missing, the remaining 19 patients were prospectively included in the study.

## Surgical technique

The patients underwent CC ligament reconstruction using two different methods. The first 8 patients were operated using the GraftRope® device (Arthrex Inc., Naples, FL) and for the remaining patients the anatomic coracoclavicular reconstruction technique was used [14]. The surgical technique was changed because of shoulder related complications with the GraftRope® device [9]. To reconstruct the coracoclavicular ligaments an autogenous gracilis tendon graft was used in all cases, the surgical technique to harvest the graft was identical regardless of which reconstructive procedure was performed in the shoulder.

The tendon grafts were harvested immediately before the shoulder surgery and both the knee and shoulder were prepped and draped. Under general anesthesia and in a bloodless field a 4 cm incision was made over the pes anserinus, the saphenous nerve and infrapatellar branches were protected if located and the sartorius fascia incised. The common insertion of the semitendinosus and gracilis tendon was located and the gracilis tendon was identified as the most anterior of the two. Adhesions were bluntly dissected and the tendon was then harvested using a tendon stripper. The sartorius fascia and subcutaneous tissue was closed using absorbable sutures and the skin was closed using non-absorbable sutures. After a soft dressing was applied the tourniquet was deflated and the shoulder surgery was begun.

Full mobilization of the leg was allowed postoperatively but patients were given a crutch to allow for partial load bearing if pain required it. All patients were advised to perform physiotherapy but no supervised training was ordered as part of this study.

## Outcome measures

The primary outcome measure was the Knee injury and Osteoarthritis Outcome Score (KOOS). The questionnaire was completed 12 months postoperatively by all patients and scores were compared to preoperative ones for the prospectively included participants. For the patients included retrospectively preoperative scores were not available, therefore age- and gender matched normative values from a study of the general population were used for statistical analysis [15].

Isometric knee flexor strength was the secondary outcome measure. Testing was performed during a follow up visit for all included patients at the end of the study period. An IsoForceControl® EVO2 dynamometer (MDS Medical Device Solutions AG, Oberburg, Switzerland) was placed on a vertical surface perpendicular to the direction of the force. The patient was in a prone position on an examination table with the strap from the dynamometer around the ankle. Instructions were given to

hold on to the edges of the table and keep the pelvis low during attempts, no stabilization of the pelvis was used. After a trial attempt using submaximal force testing was performed on both the operated and non-operated leg with the knee in both 60° and 90°, three attempts per leg and angle were completed. In half of the patients the operated leg was tested first and in the other half the non-operated. The mean of the two highest values for each leg and angle was used for statistical analysis.

To find patients with clinically severe donor site related complications, such as infection, hematoma or muscle rupture, a medical journal review of the hospitals' database was performed at the end of the study period.

### Statistics

For KOOS scores each subscale was analyzed separately and change from baseline at 12 months was analyzed using the Wilcoxon signed-rank test. For the participants that did not have preoperative scores, age- and gender matched normative values were used.

For the isometric knee flexor strength all analyses are performed as paired calculations. The relative force of the operated leg was calculated by dividing the values of this leg by those of the non-operated one. The actual difference between the legs was calculated by subtracting the force of the non-operated from that of the operated one. These calculations were performed for each patient separately and these values were then used for further calculations. The Wilcoxon signed-rank test was used to analyze if the actual difference and relative force differed from 0 and 1 respectively. Statistical significance was set at  $p < 0.05$ . All analyses were performed using SAS 9.4 (SAS Institute Inc., Cary, NC, USA).

### Results

A total of 24 patients were eligible for the study and two were excluded. One due to mental illness and one because of chronic pain syndrome, both of these patients were from the group included prospectively. Out of the 22 patients available for follow up there were 4 females, the mean age was 44 years (22–62) and the graft was harvested from the right leg in 14 cases.

The five KOOS subscales, pain, symptoms, activities of daily living (ADL), sports and recreation (SR) and quality of life (QoL), were analyzed separately and the mean scores are presented in Fig. 1. There was no statistically significant change between baseline and 12 month values for any of the KOOS subscales.

Testing of isometric hamstring strength was performed at a median of 26,5 months (14–56) postoperatively and was completed by all of the 22 patients. The operated leg was significantly weaker in both 60° and 90° of flexion performing a mean force of 93 and 83% of the

non-operated leg in the two angles respectively. Complete results are shown in Table 1.

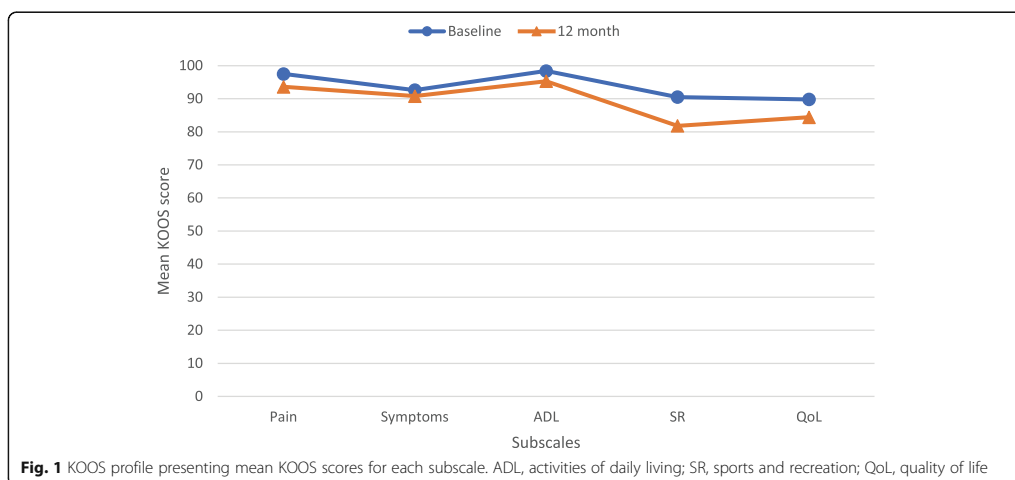
Analysis of the hospitals' medical journal database revealed that one patient had problems with a slow healing incision with no signs of infection and the same patient suffered a minor hamstring sprain after stumbling. Other than these two episodes that both resolved spontaneously no donor site complications were found.

### Discussion

This study shows that there was no statistically significant decrease in KOOS scores in any of the subscales 12 months after gracilis tendon harvesting compared to baseline values. This indicates that the use of autogenous gracilis grafts is well tolerated by patients and does not impair subjective knee function. However, the donor limb was significantly weaker in isometric knee flexion compared to the unoperated side.

While the outcome after ACL reconstruction using ipsilateral hamstring grafts has been thoroughly studied there are very few articles available on the effects of isolated gracilis tendon grafting from a knee not planned for reconstructive surgery. To our knowledge the study by Cody et al. is the only one investigating this issue [1]. In their retrospective study 70 patients had undergone hamstring tendon autografting for use in foot and ankle reconstructive procedures and in 22 of these an isolated gracilis tendon graft had been harvested. The patients were interviewed postoperatively and 95% of the patients responded that they were either satisfied or very satisfied with their operative result and all patients would recommend the surgery to someone else. There were no serious donor site sequelae and the authors conclude that hamstring autografts can be used with high patient satisfaction and minimal morbidity. The study by Cody et al. is limited by a follow up rate of only just above 50% and by the fact that they did not use a patient related outcome measure for follow up. In our study we used the validated outcome measure KOOS that provides a more comprehensive evaluation of the knee and leg function and we can confirm the findings by Cody et al. [1].

Cody et al. also measured isokinetic knee flexion strength between 13 and 56 months postoperatively [1]. They found that gracilis tendon harvest lead to a significant decrease in strength compared to the unoperated side. In our study we measured isometric and not isokinetic force but as the two are very closely related [16] our results are comparable. In accordance with Cody et al. [1] we found that the donor leg strength was 93% of the non-operated side when tested at 60° of knee flexion and 83% at 90°. Considering that both Cody et al. [1] and this study showed that the subjective outcome of the donor leg was not affected by the surgery the measurable decrease in strength seems to be clinically unimportant in



our study populations. It is, however, possible that the hamstring strength deficit might be of clinical importance in patients with very high demands such as those participating in certain sports. It has been suggested that a weakness in knee flexion might increase the risk of ACL tears [17] and it has also been shown that low hamstring strength is a risk factor for hamstring strain injuries in professional football players [18]. Structured physiotherapy has been shown effective in rebuilding hamstring strength [12] and should, therefore, be considered after gracilis tendon harvest.

There are two further studies concerning the outcome after hamstring tendon harvesting without further knee related procedures in the donor limb. In the study by Yasuda et al. 70 patients were randomized to have a two-tendon hamstring graft harvested from either the ipsilateral or contralateral leg when undergoing planned ACL-reconstructions, 34 patients were included in the contralateral group [12]. All subjective problems, such as activity related soreness, restricted range of motion, and reduction in the points in the Cincinnati sports medicine center rating scale, were resolved by 3 months postoperatively. In the second, similar, study by McRae et al., 50 patients were randomized to the contralateral

harvest group [13]. The main outcome variable was the ACL quality of life outcome measure and there was no difference between groups at any point in time during follow up. The score did increase with time at each of the three follow up visits until 12 months postoperatively but no further improvement was seen at 24 months. While our study cannot be directly compared to the two above because of the differences in tendons harvested and follow up protocols we are able to provide further evidence that the negative effects of hamstring tendon grafting are resolved by one year postoperatively.

A strength of our study is that we can confirm the previous findings of Cody et al. [1] that isolated gracilis tendon harvesting leads to a reduction of knee flexion strength. We also deepen the understanding of the subjective outcome after this procedure by being the only study presenting the results of a validated patient related outcome measure. As gracilis autografts are widely used in orthopedic procedures outside of knee surgery these results are important to establish the safety and outcome of the harvesting procedure in such settings and allow surgeons to provide patients a detailed preoperative information [1–6].

**Table 1** Isometric knee flexion strength

Angle		Operated leg (N)	Non-operated leg (N)	Actual difference (N)	Relative difference
60°	Mean Force (SD)	199.7 (78.2)	212.4 (76.1)	−12.7 (21.6)	0.93 (0.1)
	P-value			0.0051	0.0025
90°	Mean Force (SD)	123.1 (54.6)	145.9 (54.7)	−22.7 (27.0)	0.83 (0.19)
	P-value			0.0002	0.0002

Mean force is presented in Newtons. Actual difference is calculated by subtracting the force of the non-operated leg from that of the operated leg. Relative difference is calculated by dividing the force of the operated leg by that of the non-operated leg. SD standard deviation. *p*-values from the paired Wilcoxon signed-rank test

The main weakness of this study is that 5 of the 22 patients underwent surgery before the study was started and are therefore lacking preoperative outcome measures. In these 5 cases we compared postoperative KOOS scores to age and gender matched normative values acquired from a population based study of 568 persons [15]. Further, while there was no statistically significant decrease in KOOS scores one year postoperatively we did see a slight reduction in each of the five subscales and with a larger sample size this might have turned out to be significant. The differences were, however, not larger than what is considered the minimal clinically important change in any of the subscales [19]. Another weakness is that we did not systematically examine the donor site in the post operative period to look for local complications such as wound infection, hematoma or muscle rupture. Instead we used medical journal review in the Hospitals' database to register complications that the patients sought care for. It is possible that patients with complications have been treated at other caregivers but this is unlikely as we are the only orthopedic clinic in the area and postoperative complications are usually referred to us. Further, we only measured isometric knee flexion strength and did not assess isokinetic performance, but as the two are closely related and our results are in accordance with other studies we do not believe this choice of method to have caused erroneous conclusions [1, 16].

## Conclusion

Gracilis tendon harvesting results in a weakness of knee flexion but does not have significant impact on subjective knee function and is a procedure that can be recommended when an autogenous tendon graft is needed.

## Abbreviations

ACL: Anterior cruciate ligament; ADL: Activities of daily living; CC: Coracoclavicular; KOOS: Knee injury and Osteoarthritis Outcome Score; QoL: Quality of life; SR: Sports and recreation

## Acknowledgements

Physiotherapists Anna Lönnberg and Frida Jönsson at the department of physiotherapy, Helsingborg Hospital. For performing follow up visits of the study patients and collecting KOOS scores. Jonathan Nohage, medical student. For performing isometric knee flexor strength measurements. Tommy Schyman, Statistician, Clinical Studies Sweden – Forum South, Skåne University Hospital. For help with the statistical analyses.

## Funding

This study was supported by grants from the Stig and Ragna Gorthon Foundation and the Thelma Zoëga foundations for medical research. The funding bodies had no role in the design of the study or in collection, analysis, interpretation or presentation of data.

## Availability of data and materials

The datasets used and analyzed during the current study are available from the corresponding author on reasonable request.

## Authors' contributions

JN and KL designed the study. JN collected, compiled and analysed data under the supervision KL and OO. JN, KL and OO participated in data reviewal and interpretation. JN drafted the manuscript which was reviewed and revised by all authors. All authors read and approved the final manuscript.

## Ethics approval and consent to participate

This study has been approved by the Regional Ethical Review Board in Lund. (Dnr 2012/454, Dnr 2016/491, Dnr 2016/962).

All participants in this study has received oral and written information about the study and signed a consent form.

## Consent for publication

Not applicable.

## Competing interests

The authors declare that they have no competing interests.

## Publisher's Note

Springer Nature remains neutral with regard to jurisdictional claims in published maps and institutional affiliations.

Received: 30 November 2018 Accepted: 21 March 2019

Published online: 30 March 2019

## References

- Cody EA, Karnovsky SC, DeSandis B, Tychanski Papson A, Deland JT, Drakos MC. Hamstring autograft for foot and ankle applications. *Foot Ankle Int.* 2018;39(2):189–95.
- Karnovsky SC, Desandis B, Papson AK, O'Malley Q, DiGiacomo R, O'Malley MJ, Cabe TN, Drakos MC. Tibialis anterior reconstruction with hamstring autograft using a minimally invasive approach. *Foot Ankle Int.* 2018;39(5):535–41.
- Hagemeyer NC, Claessen FMAP, de Haan R, Riedijk R, Eygendaal DE, van den Bekerom MP. Graft site morbidity in elbow ligament reconstruction procedures: a systematic review. *Am J Sports Med.* 2017;45(14):3382–7.
- Schöttle P, Schmeling A, Romero J, Weiler A. Anatomical reconstruction of the medial patellofemoral ligament using a free gracilis autograft. *Arch Orthop Trauma Surg.* 2009;129(3):305–9.
- Matsuda DK, Burchette RJ. Arthroscopic hip labral reconstruction with a Gracilis autograft versus labral Refixation: 2-year minimum outcomes. *Am J Sports Med.* 2013;41(5):980–7.
- Moloney C, O'Sullivan K, O'Farrell D, Louw Q, Clifford AM. Hamstring muscle strength before and after anterior cruciate ligament reconstruction: a systematic review. *Isokinet Exerc Sci.* 2014;22(3):225–36.
- Belk JW, Kraeutler MJ, Purcell JM, McCarty EC. Autograft versus allograft for posterior cruciate ligament reconstruction: an updated systematic review and meta-analysis. *Am J Sports Med.* 2018;46(7):1752–7.
- Tian S, Wang B, Liu L, Wang Y, Ha C, Li Q, Yang X, Sun K. Irradiated hamstring tendon allograft versus autograft for anatomic double-bundle anterior cruciate ligament reconstruction: midterm clinical outcomes. *Am J Sports Med.* 2016;44(10):2579–88.
- Nordin JS, Aagaard KE, Lunsjö K. Chronic acromioclavicular joint dislocations treated by the GraftRope device: a prospective trial halted prematurely due to a high rate of complications. *Acta Orthop.* 2015;86(2):225–8.
- Hardy A, Casabianca L, Andrieu K, Baverel L, Noailles T. Complications following harvesting of patellar tendon or hamstring tendon grafts for anterior cruciate ligament reconstruction: systematic review of literature. *Orthop Traumatol Surg Res.* 2017;103(Suppl8):245–8.
- Landes S, Nyland J, Elminger B, Tillett E, Caborn D. Knee flexor strength after ACL reconstruction: comparison between hamstring autograft, tibialis anterior allograft, and non-injured controls. *Knee Surg Sports Traumatol Arthrosc.* 2010;18(3):317–24.
- Yasuda K, Tsujino J, Ohkoshi Y, Tanabe Y, Kaneda K. Graft site morbidity with autogenous semitendinosus and gracilis tendons. *Am J Sports Med.* 1995;23(6):706–14.
- McRae S, Leiter J, McCormack R, Old J, MacDonald P. Ipsilateral versus contralateral hamstring grafts in anterior cruciate ligament reconstruction: a prospective randomized trial. *Am J Sports Med.* 2013;41(11):2492–9.

14. Carofino BC, Mazzocca AD. The anatomic coracoclavicular ligament reconstruction: surgical technique and indications. *J Shoulder Elb Surg.* 2010;19(Suppl2):37–46.
15. Paradowski PT, Bergman S, Sundén-Lundius A, Lohmander LS, Roos EM. Knee complaints vary with age and gender in the adult population. Population-based reference data for the knee injury and osteoarthritis outcome score (KOOS). *BMC Musculoskelet Disord.* 2006;7:38.
16. Lord JP, Aitkens SG, McCrory MA, Bernauer EM. Isometric and isokinetic measurement of hamstring and quadriceps strength. *Arch Phys Med Rehabil.* 1992;73(4):324–30.
17. Hughes G, Watkins J. A risk-factor model for anterior cruciate ligament injury. *Sports Med.* 2006;36(5):411–28.
18. Lee JWY, Mok KM, Chan HCK, Yung PSH, Chan KM. Eccentric hamstring strength deficit and poor hamstring-to-quadriceps ratio are risk factors for hamstring strain injury in football: a prospective study of 146 professional players. *J Sci Med Sport.* 2018;21(8):789–93.
19. Roos EM, Lohmander LS. The knee injury and osteoarthritis outcome score (KOOS): from joint injury to osteoarthritis. *Health Qual Life Outcomes.* 2003;1(1):1–8.

**Ready to submit your research? Choose BMC and benefit from:**

- fast, convenient online submission
- thorough peer review by experienced researchers in your field
- rapid publication on acceptance
- support for research data, including large and complex data types
- gold Open Access which fosters wider collaboration and increased citations
- maximum visibility for your research: over 100M website views per year

**At BMC, research is always in progress.**

Learn more [biomedcentral.com/submissions](https://biomedcentral.com/submissions)







